

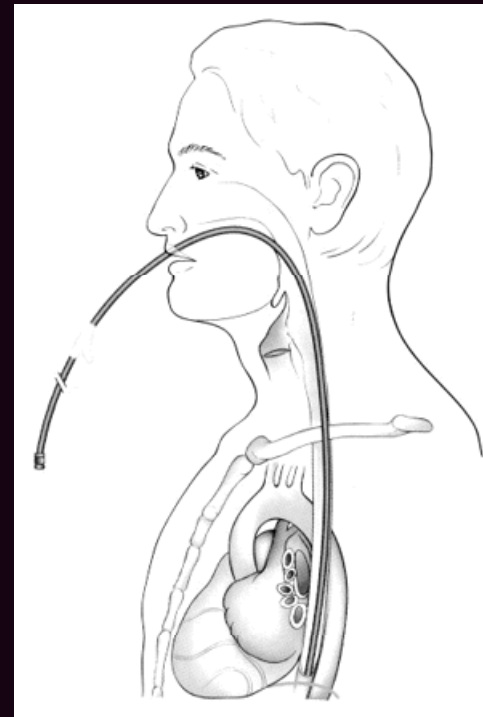
Imaging Study in Adult Congenital Heart Disease

울산의대 서울아산병원 심장내과

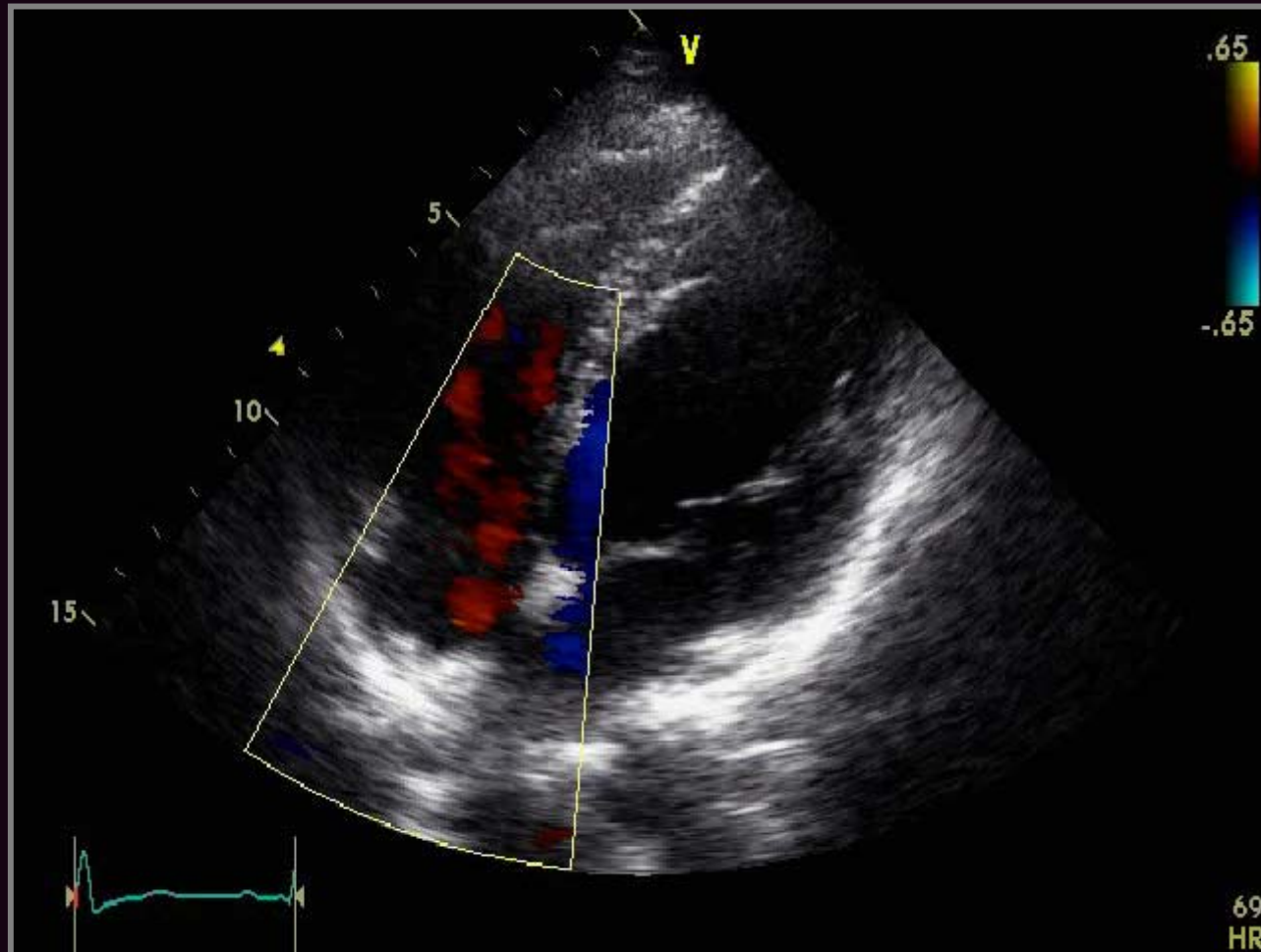
송종민

Echo for Adult Congenital Heart Disease

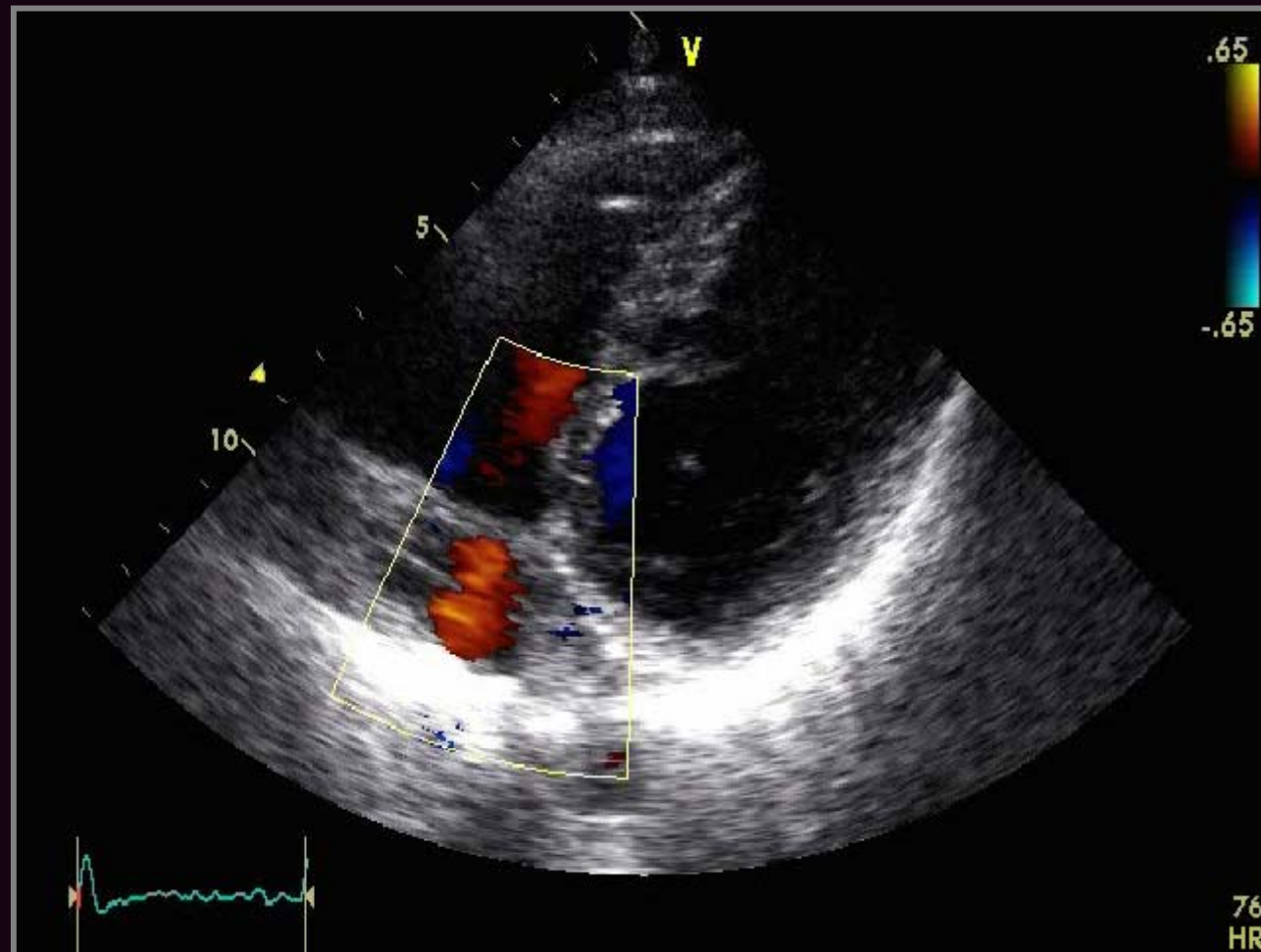
잘 안 보인다... 경험이 별로 없다... TT



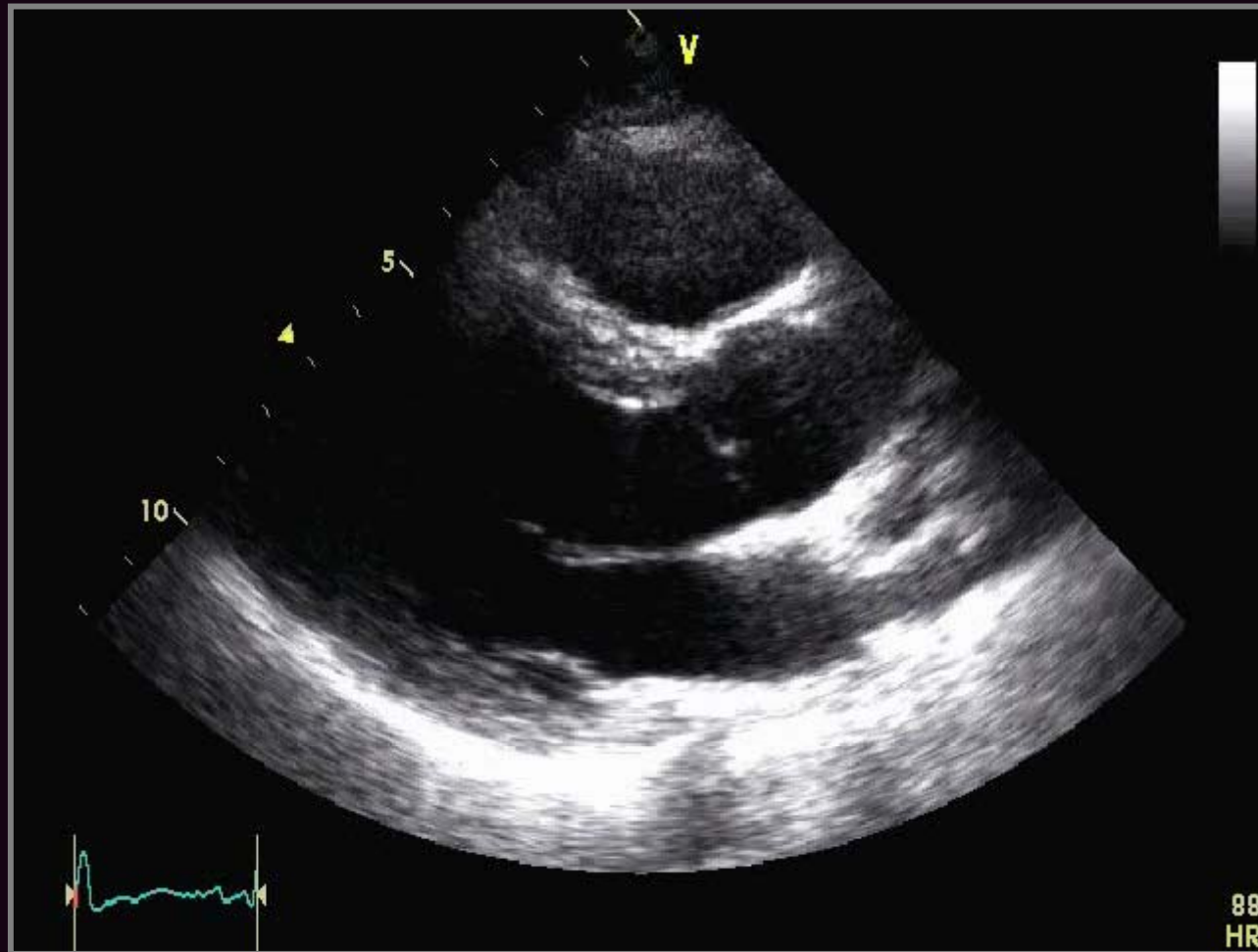
Atrial Septal Defect ?!



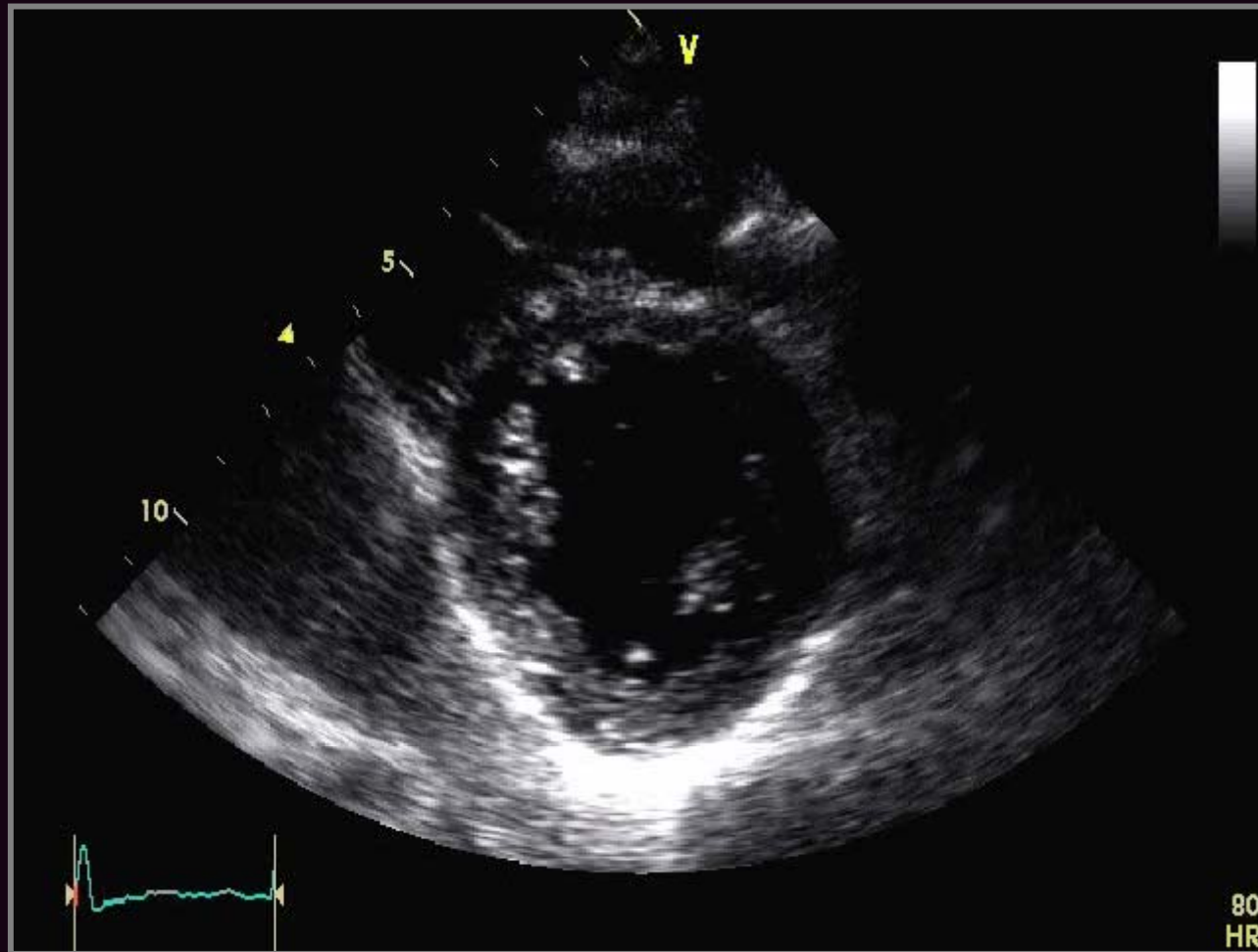
NO Atrial Septal Defect



NO Atrial Septal Defect



NO Atrial Septal Defect



Atrial Septal Defect

PA

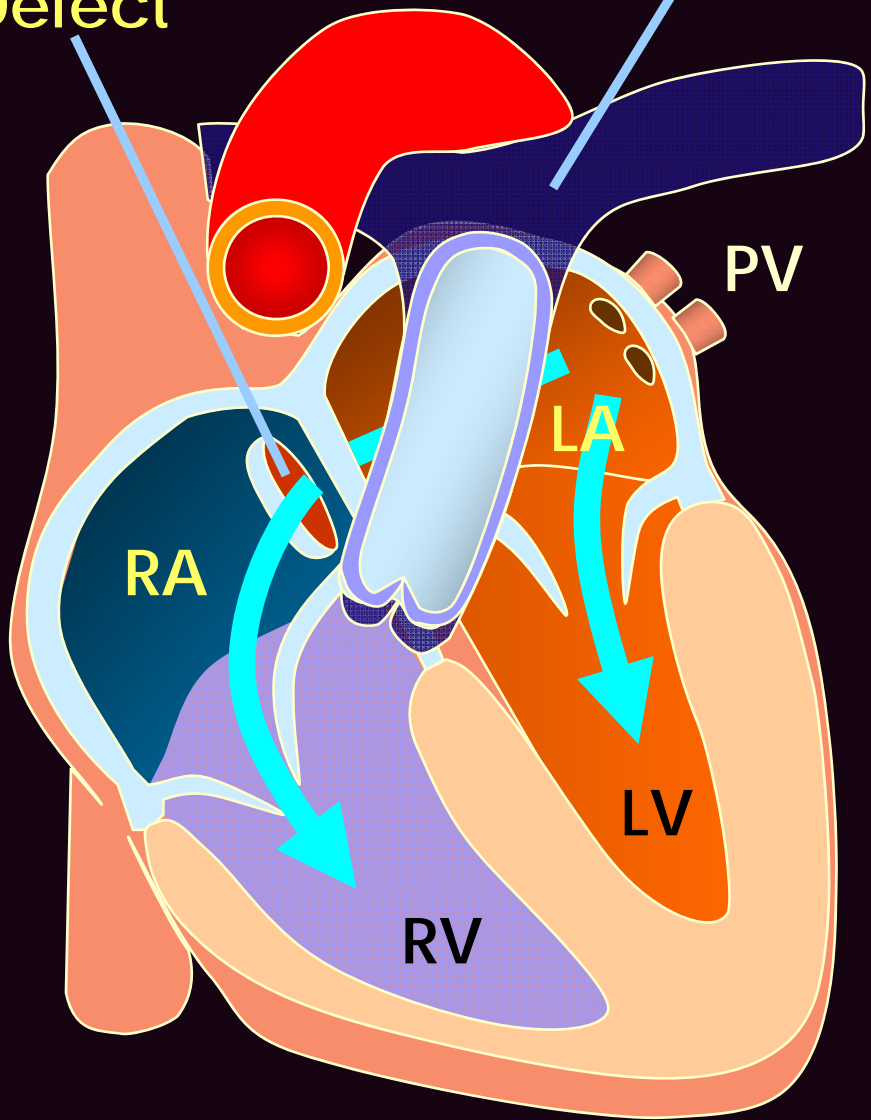
PV

LA

RA

LV

RV

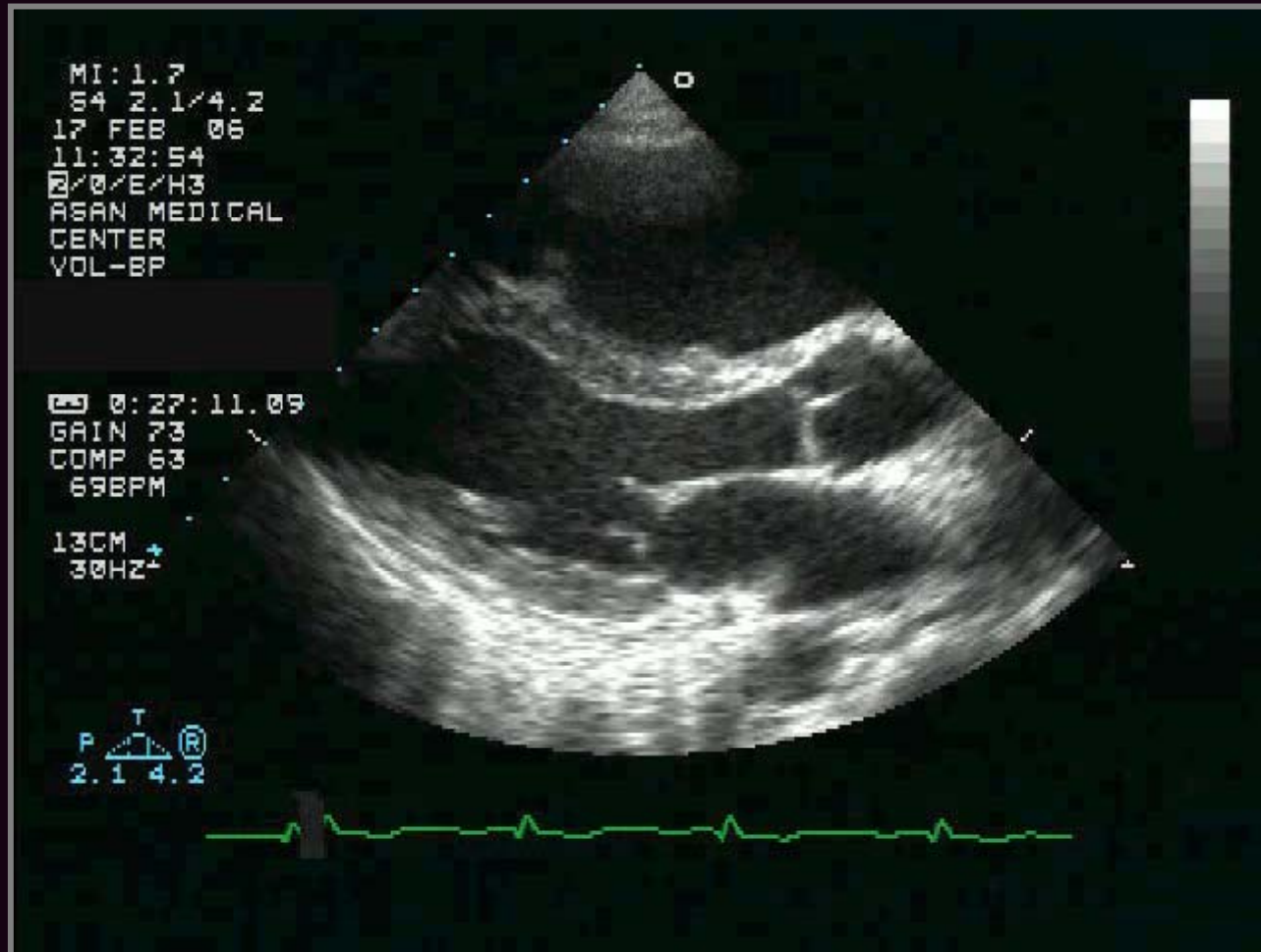


Atrial Septal Defect

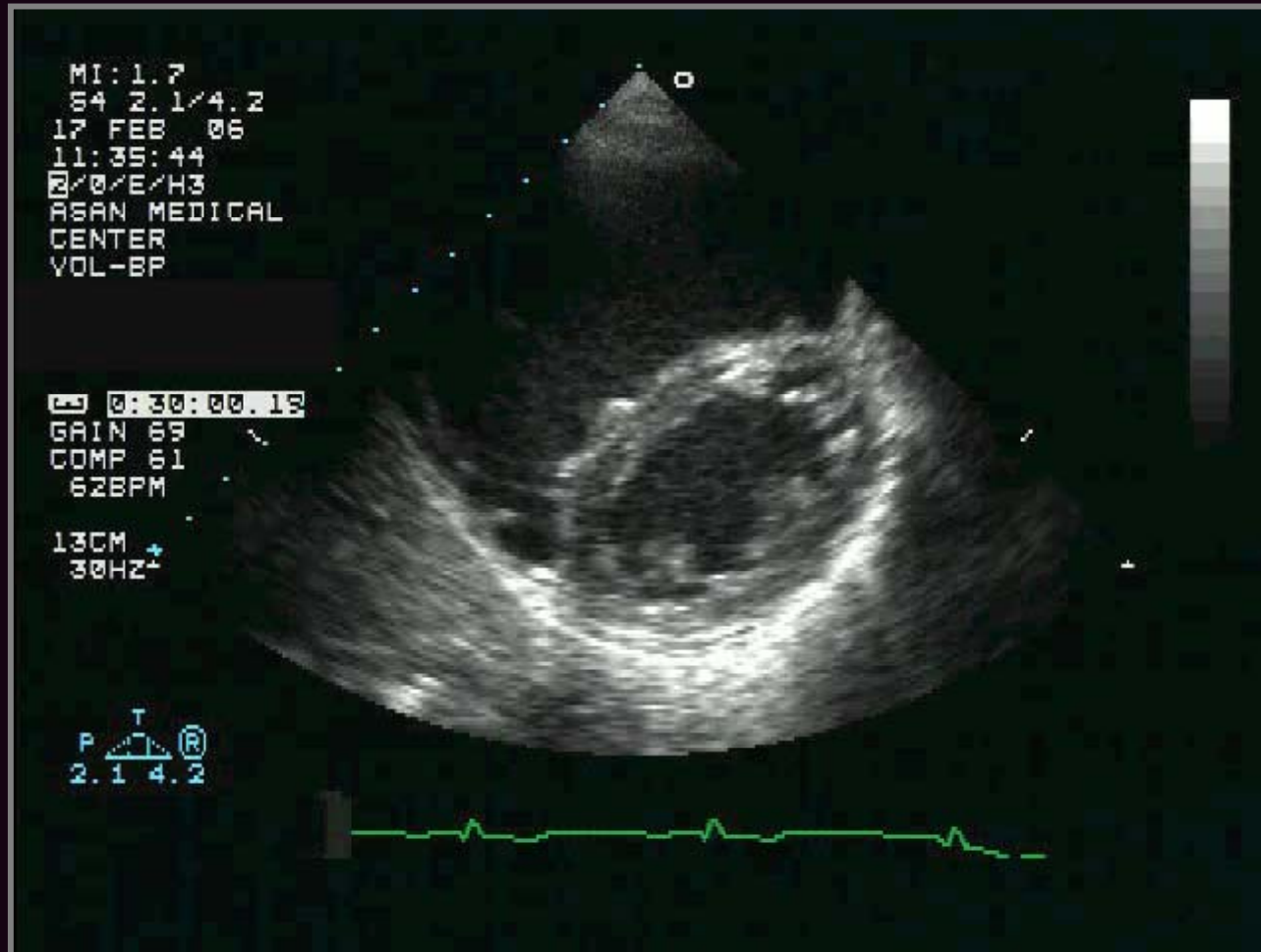
□ Right ventricular volume overload

- Increased size of right atrium and right ventricle
- Paradoxical septal motion

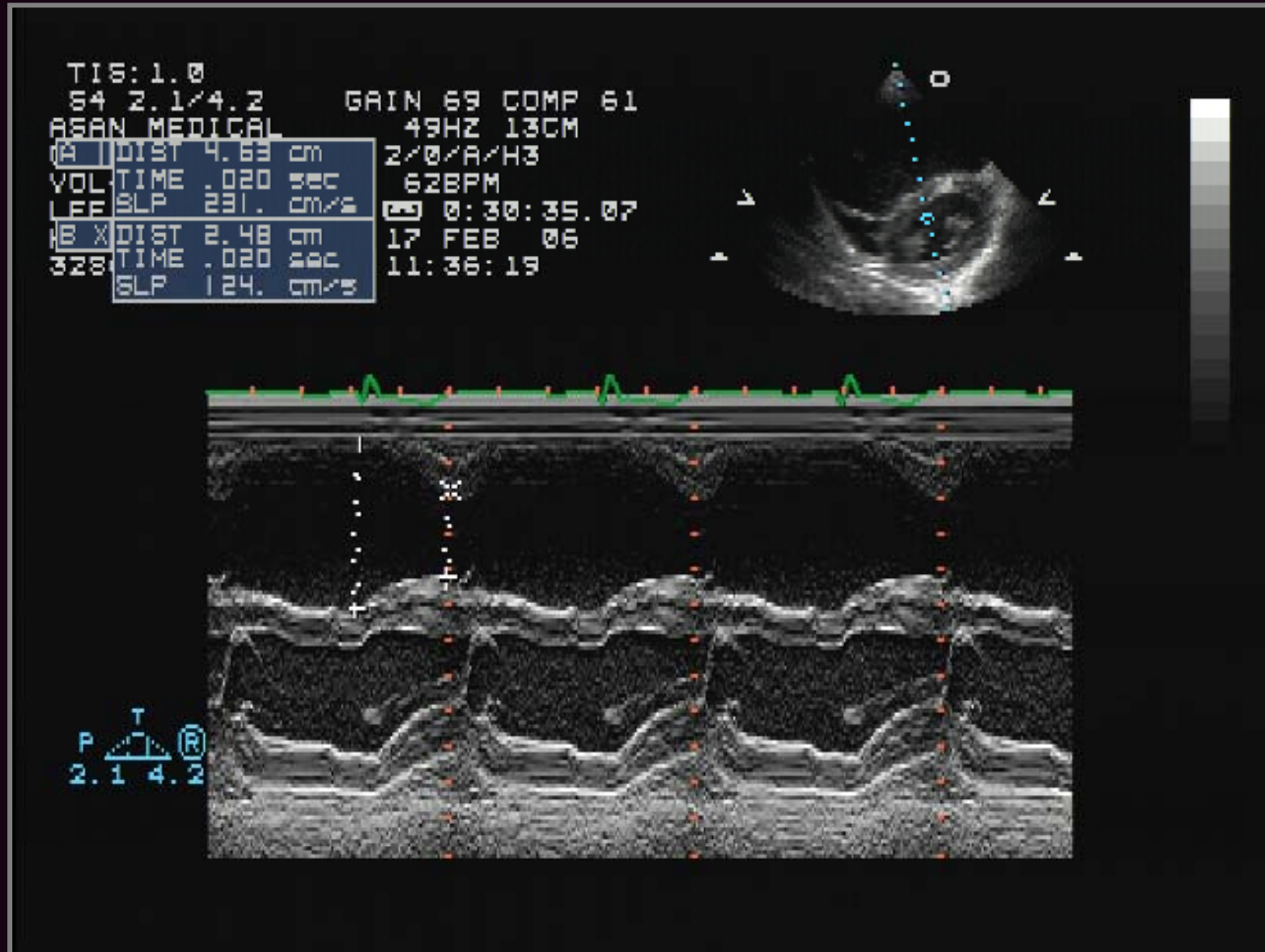
Atrial Septal Defect



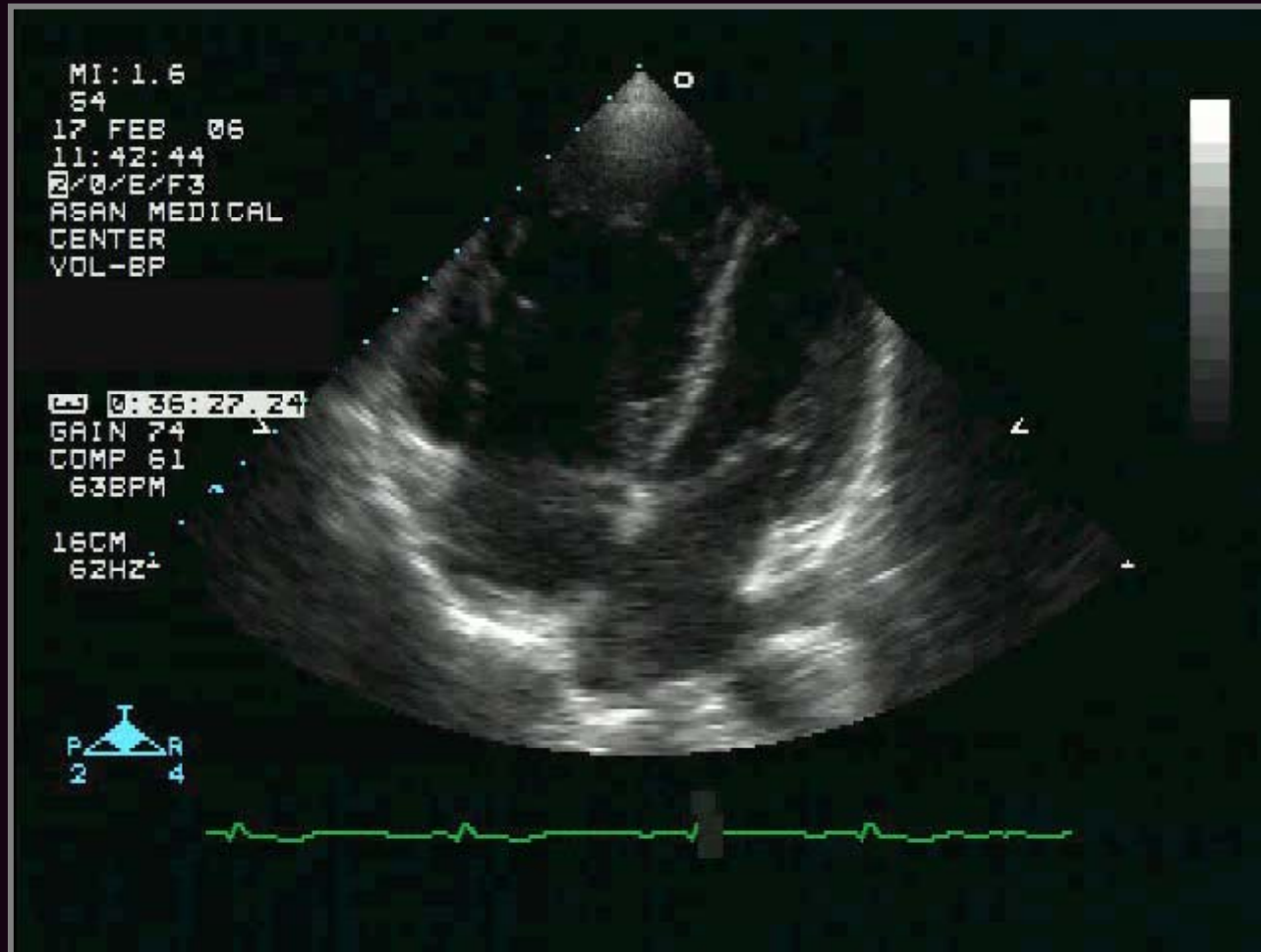
Atrial Septal Defect



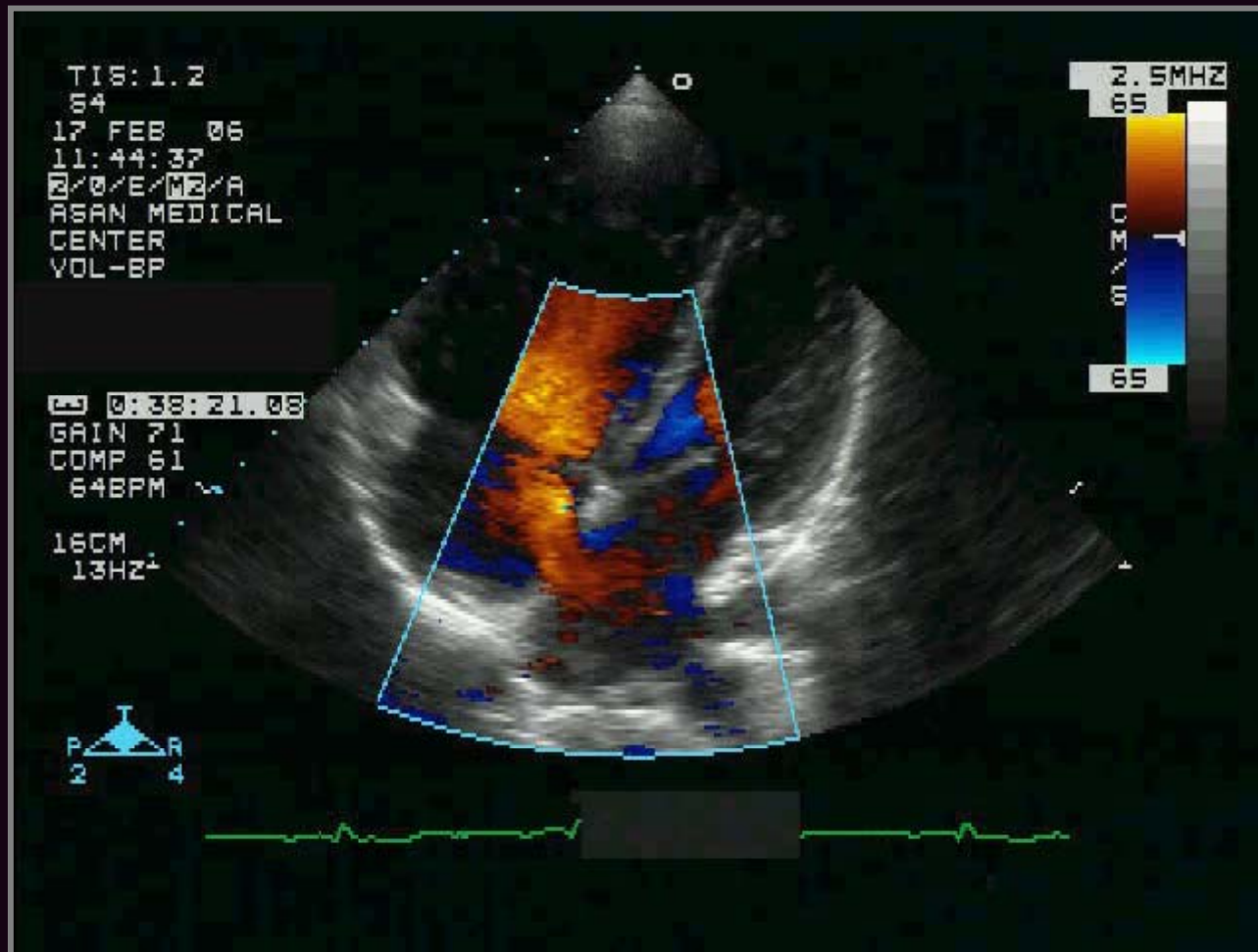
Atrial Septal Defect



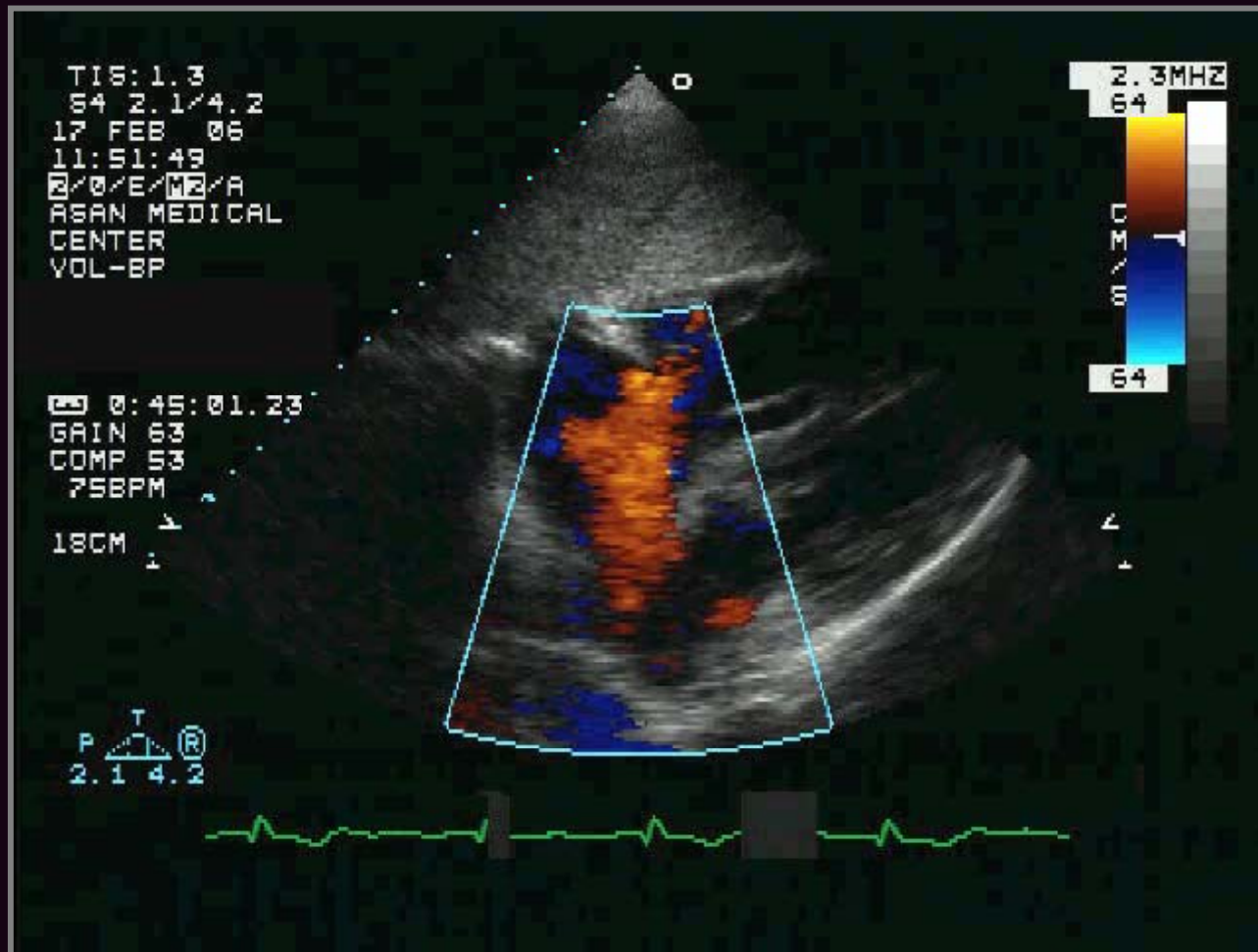
Atrial Septal Defect



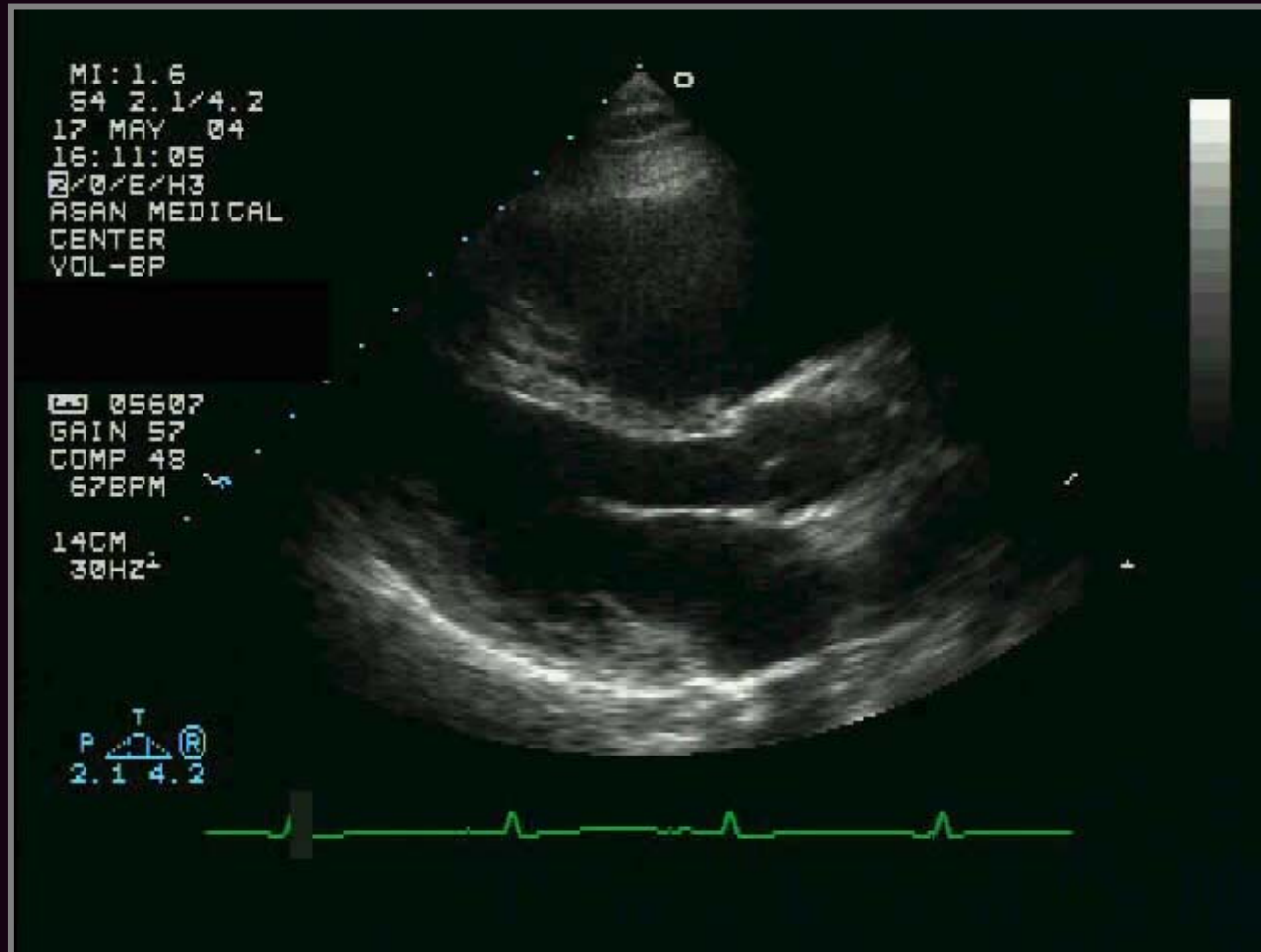
Atrial Septal Defect



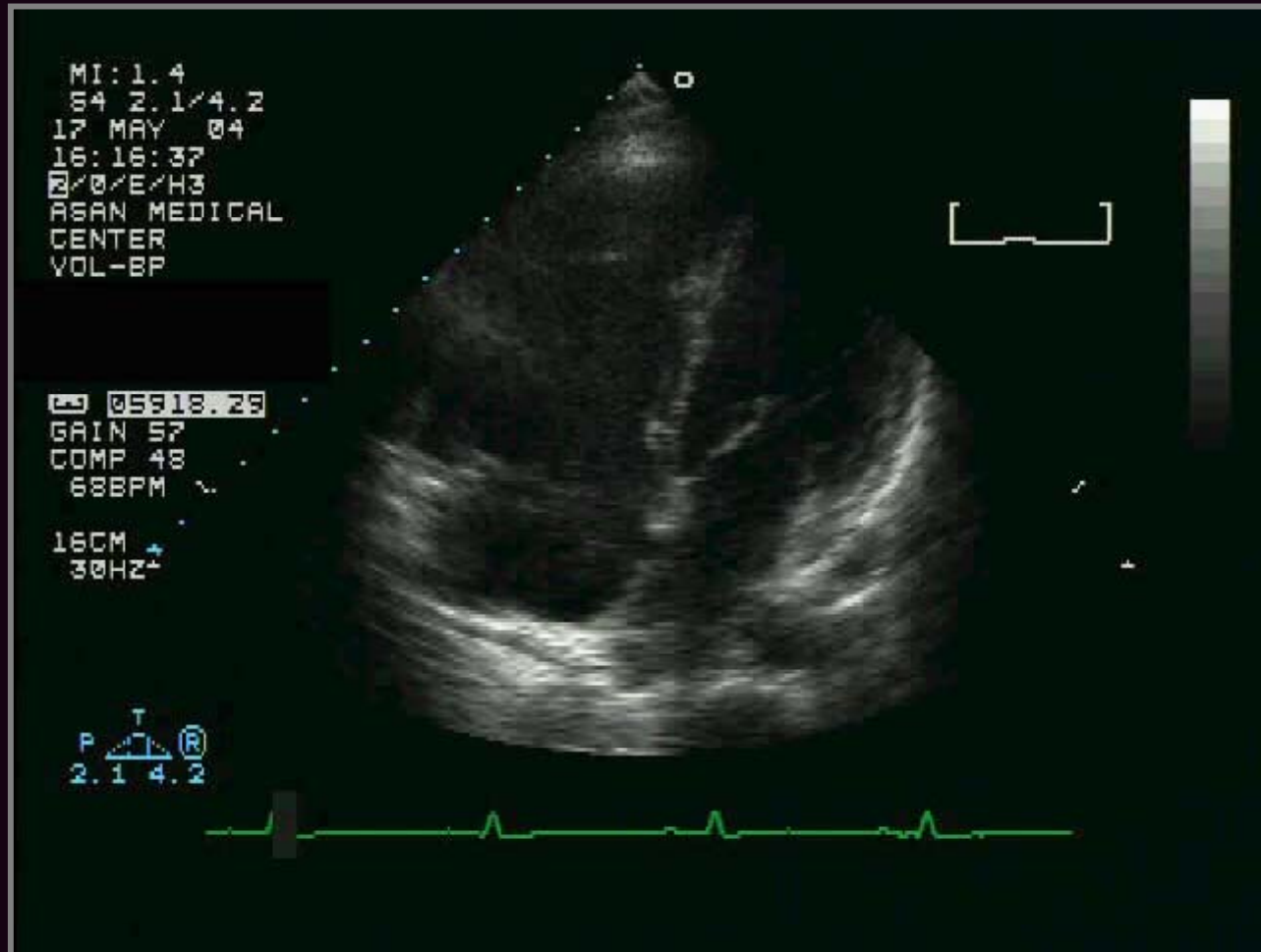
Atrial Septal Defect



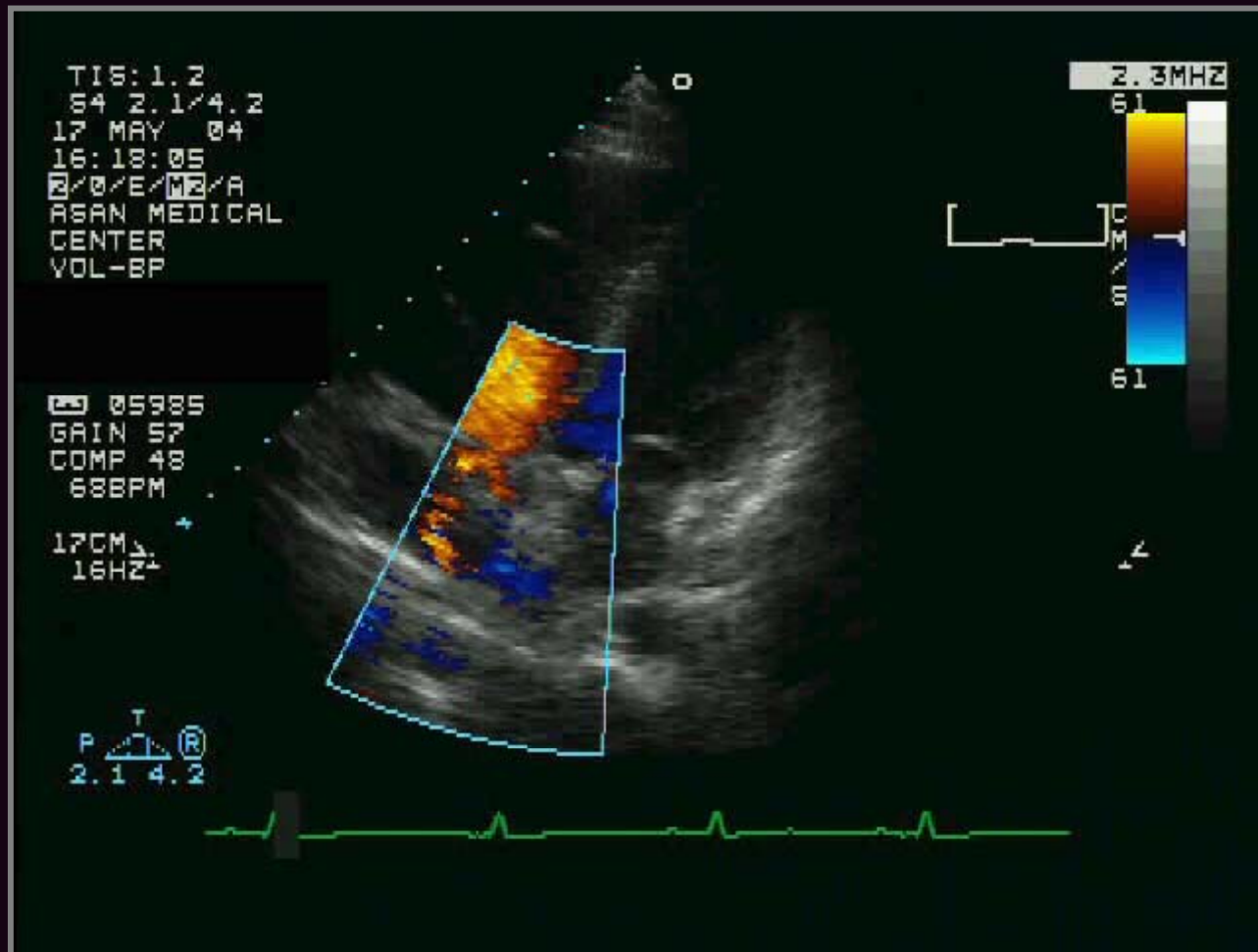
Atrial Septal Defect ?!



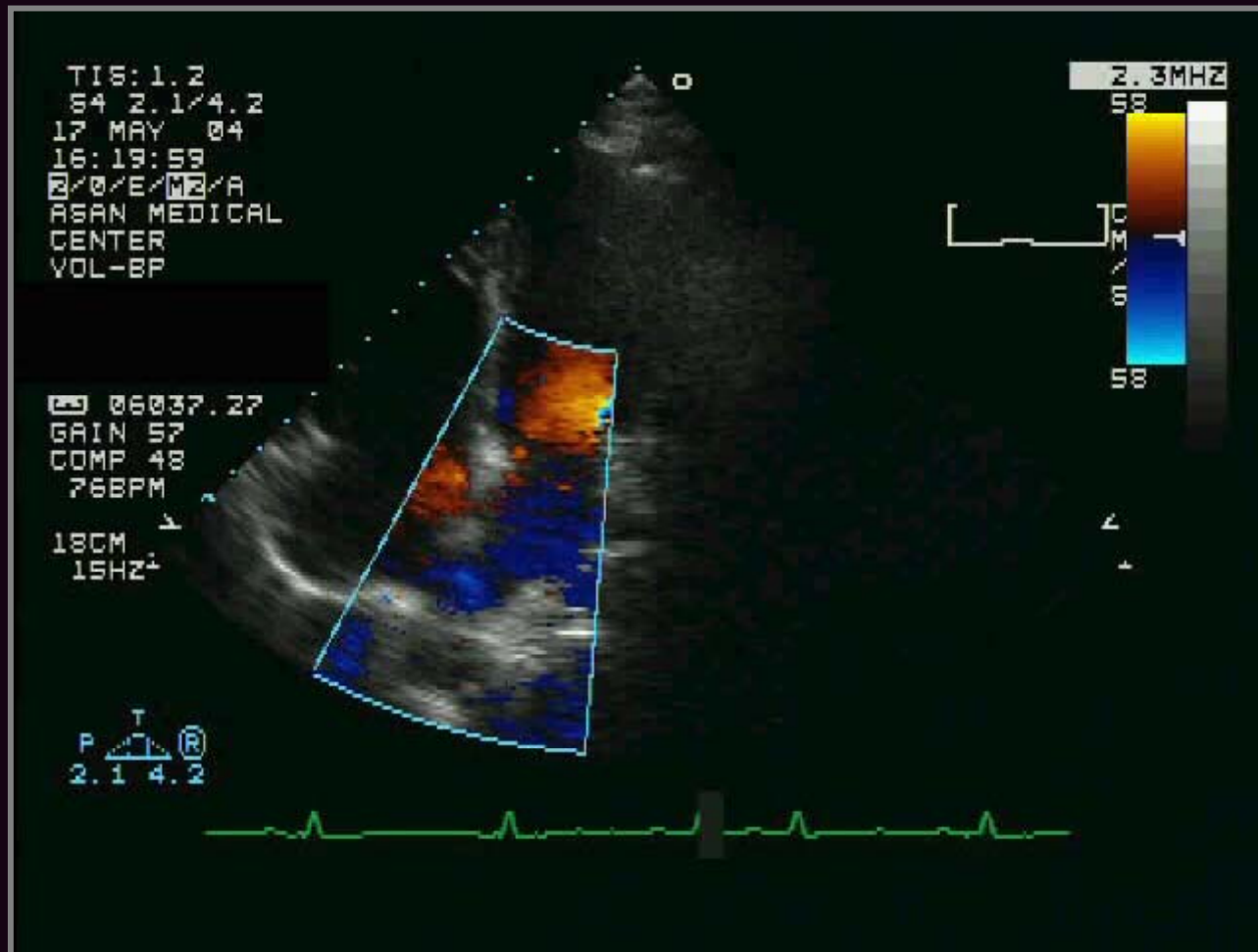
Atrial Septal Defect ?!



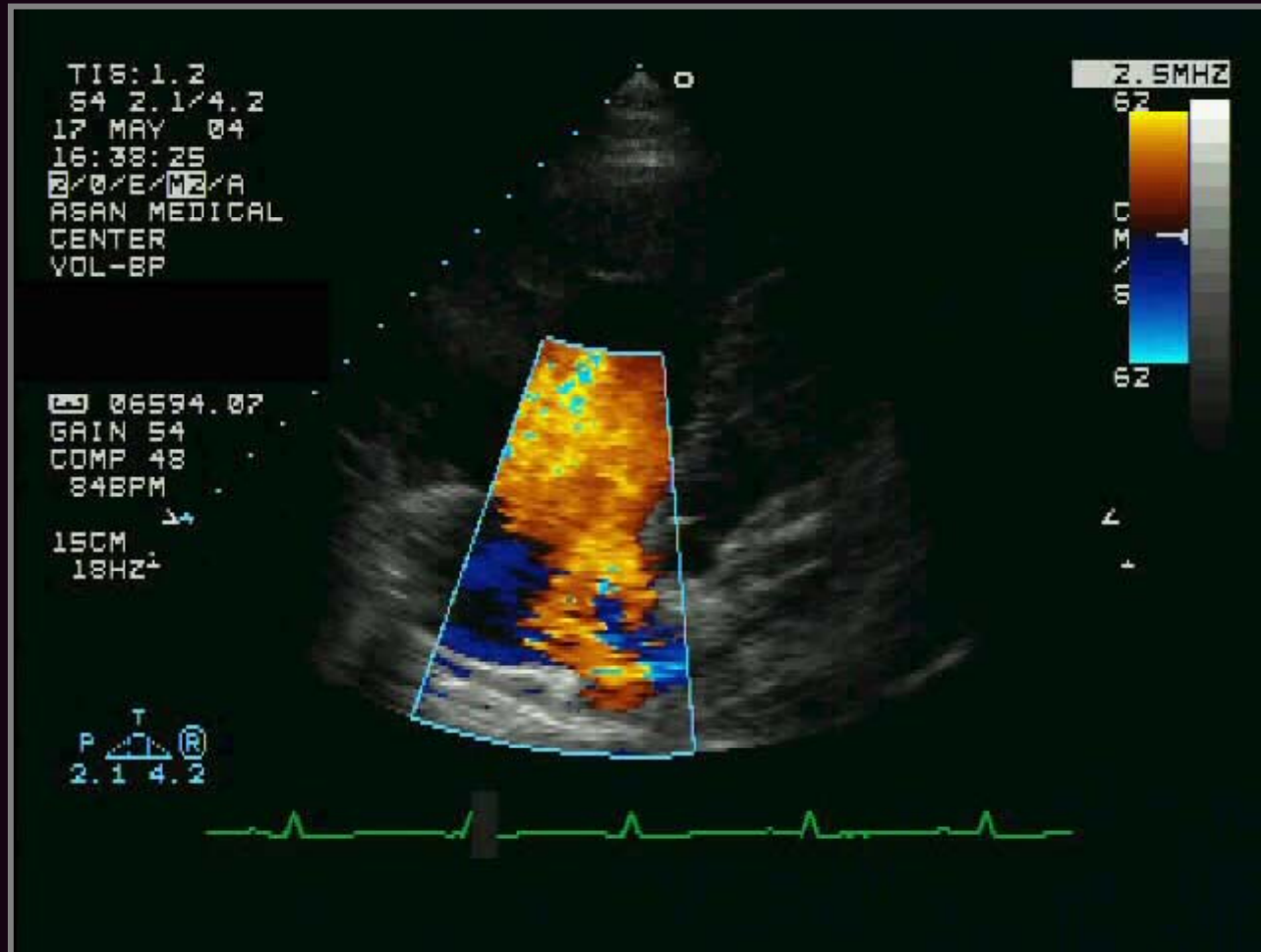
Atrial Septal Defect ?!



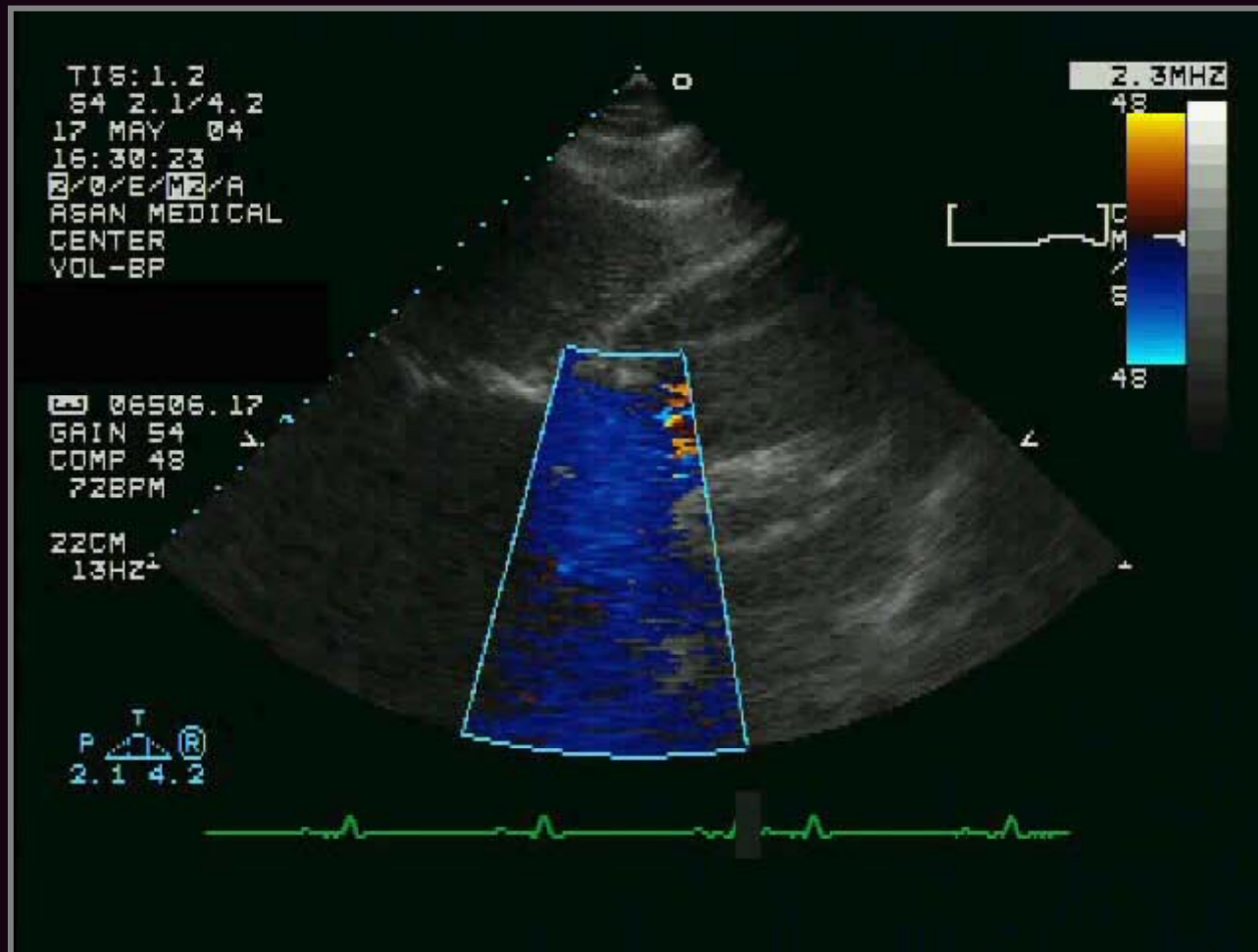
Atrial Septal Defect ?!



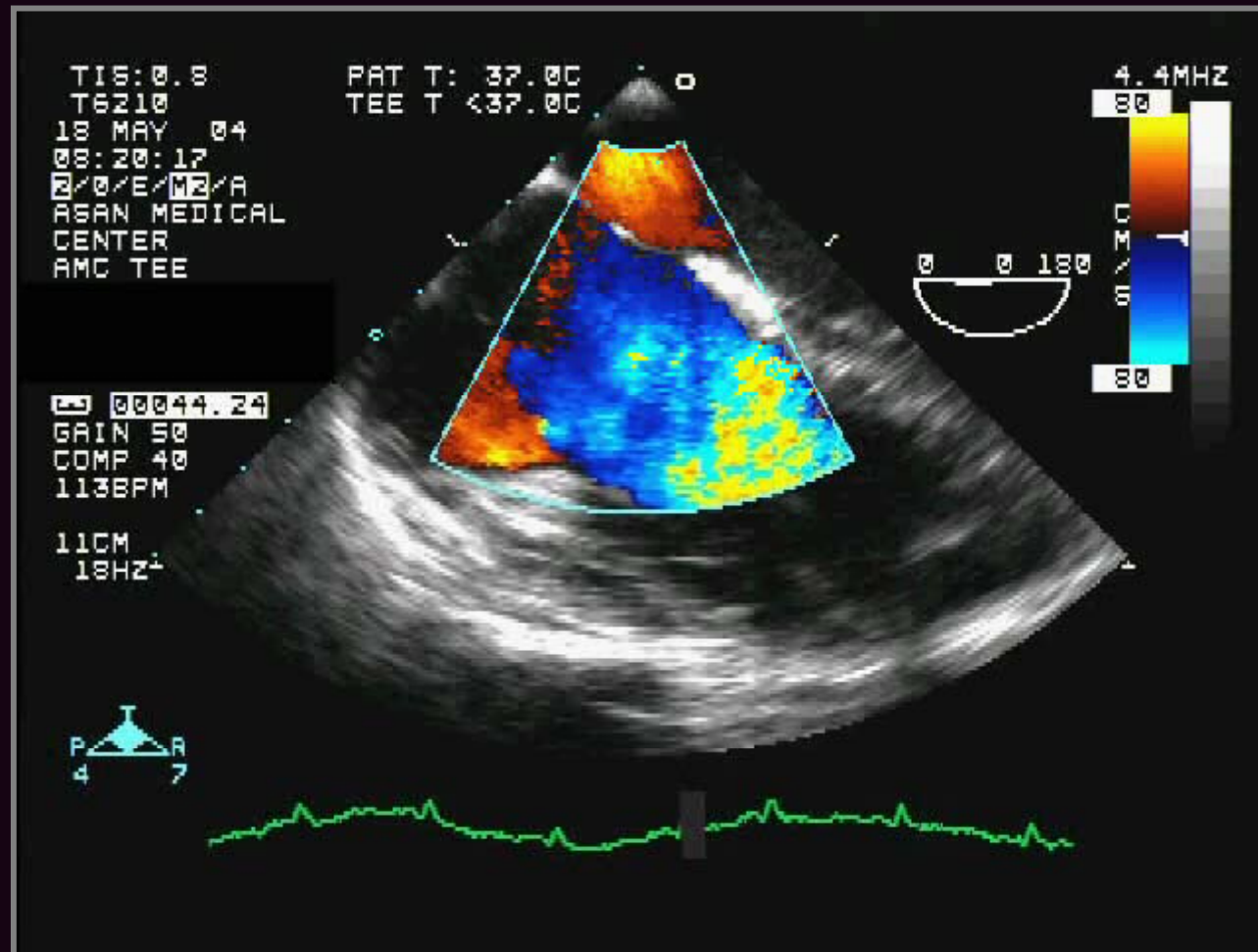
Atrial Septal Defect ?!



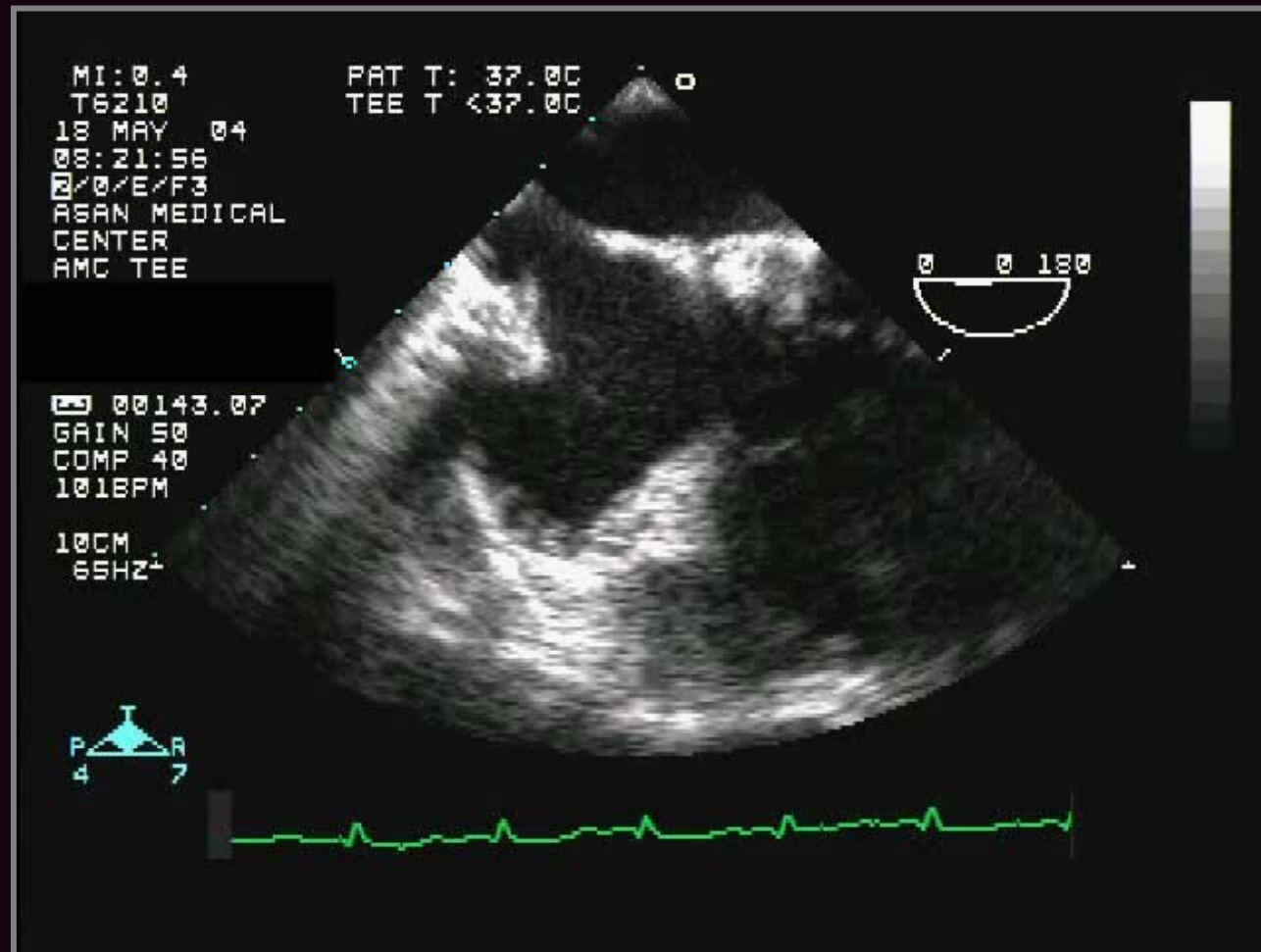
Atrial Septal Defect ?!



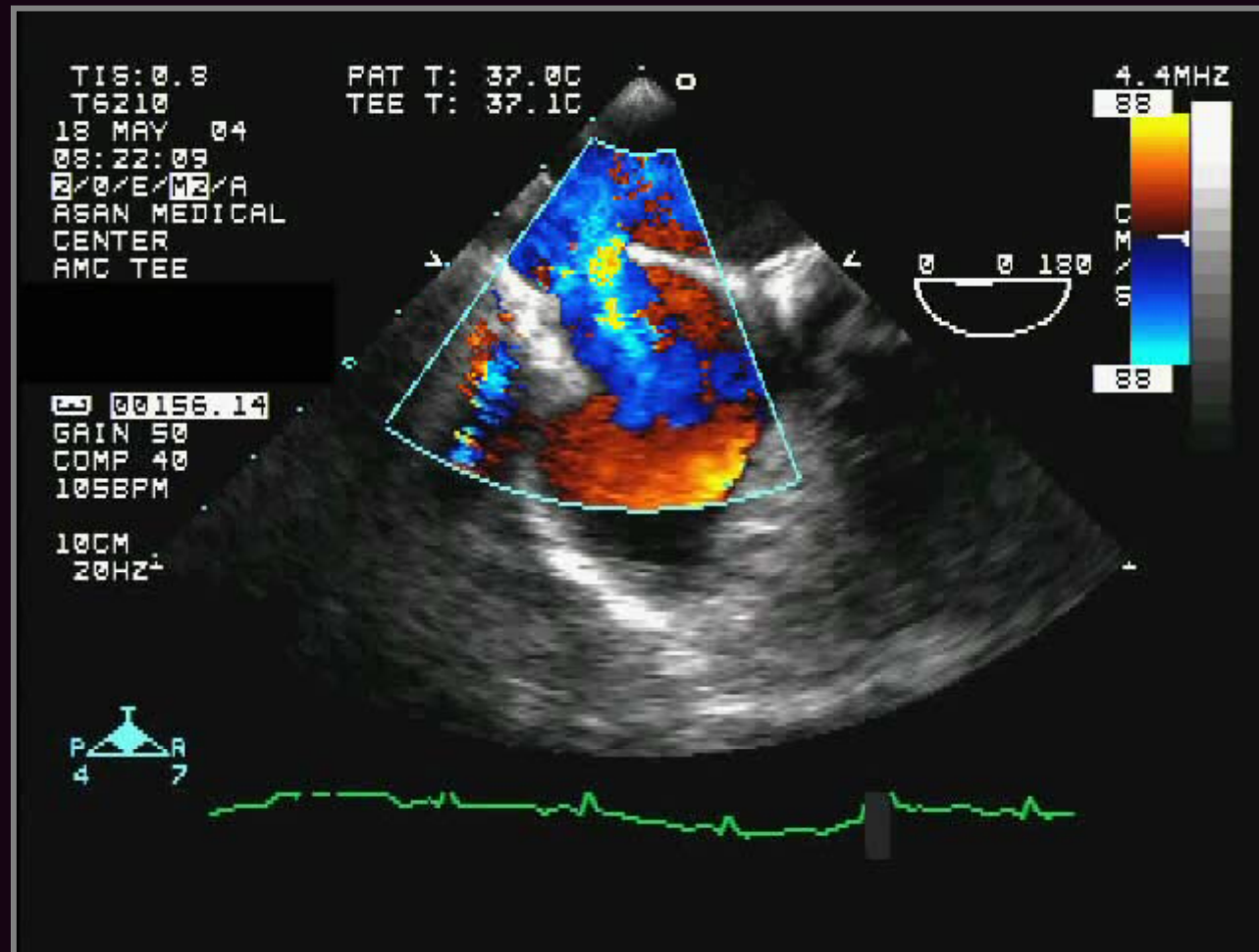
Atrial Septal Defect ?!



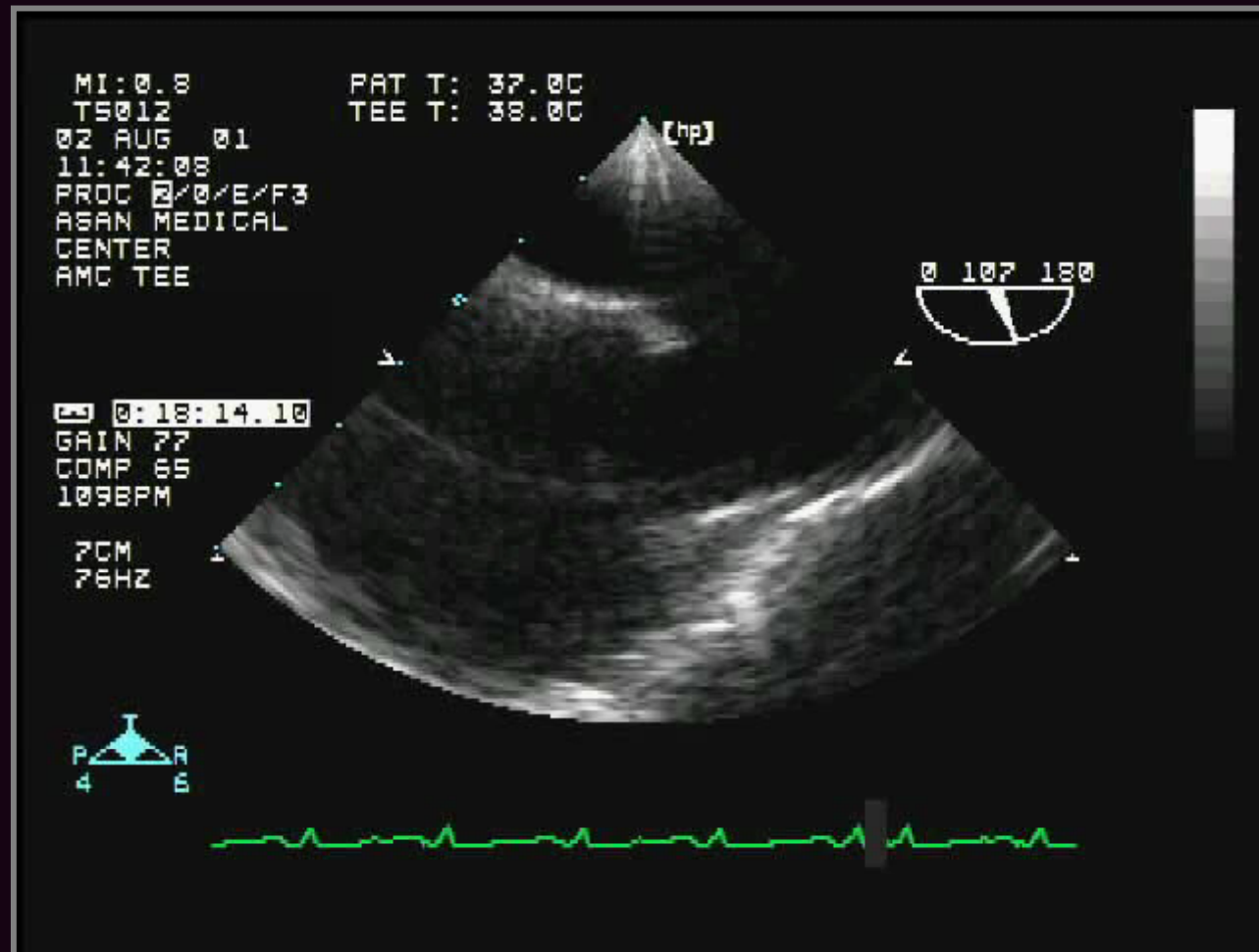
Atrial Septal Defect



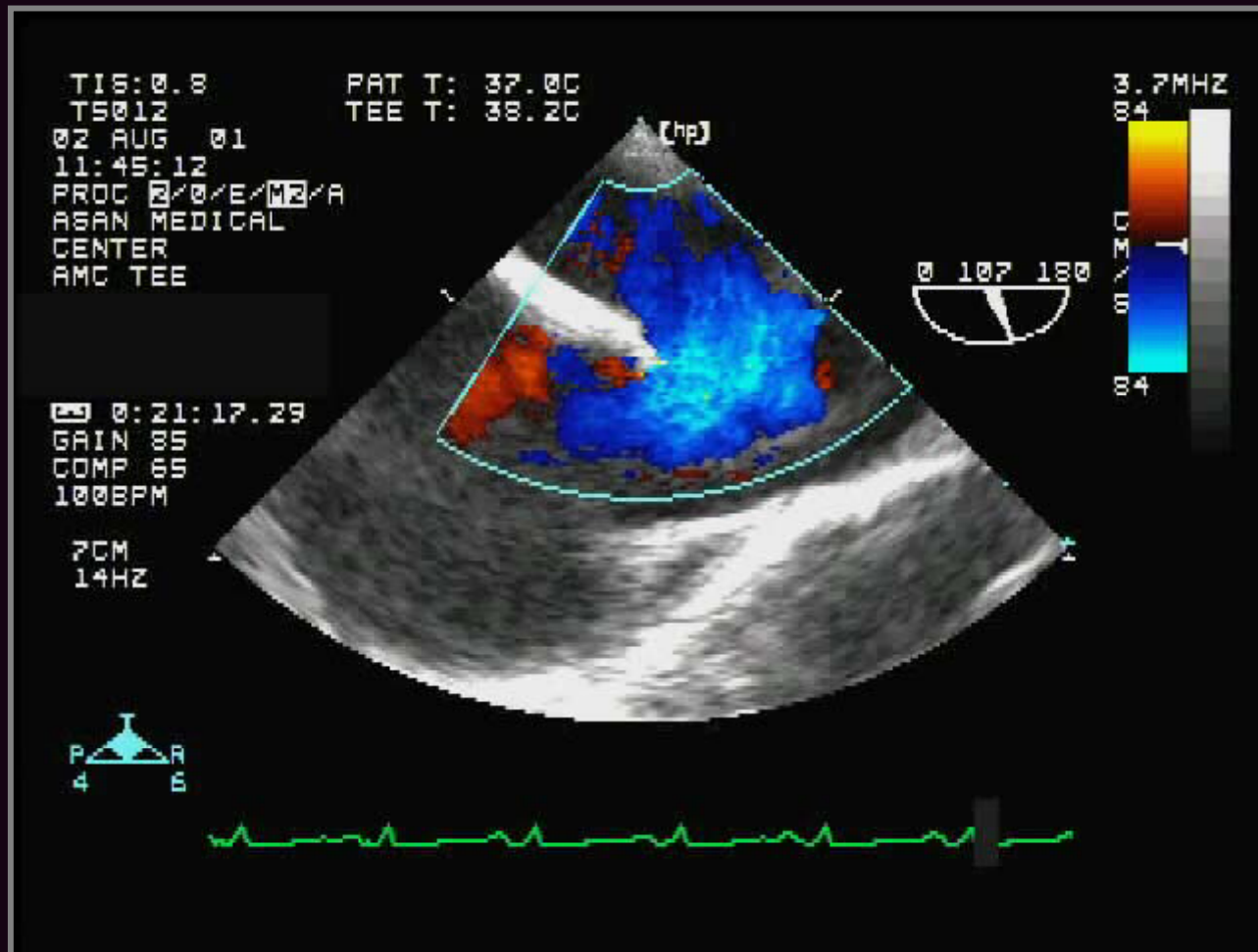
Sinus Venosus Type ASD



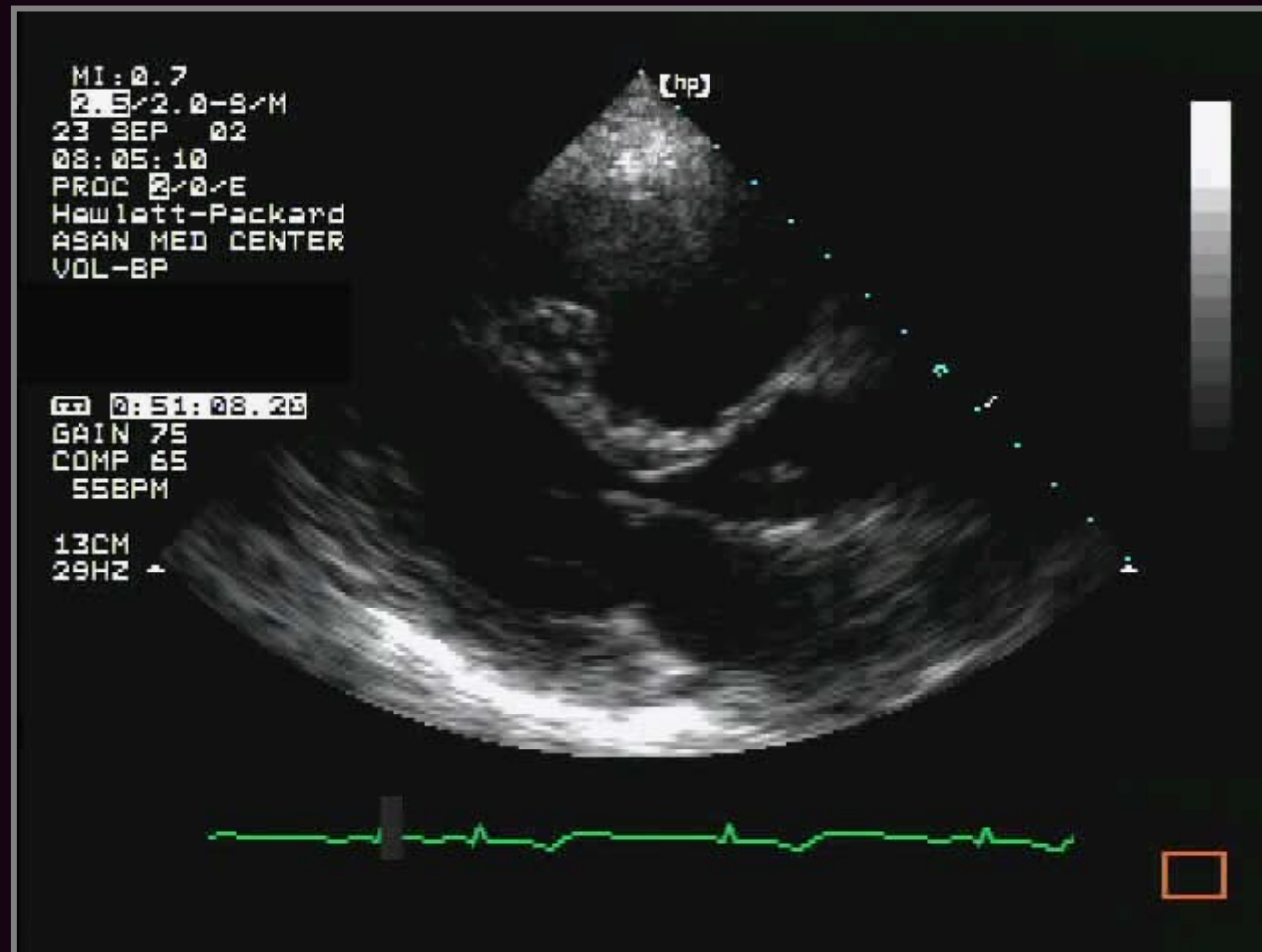
Sinus Venosus Type ASD



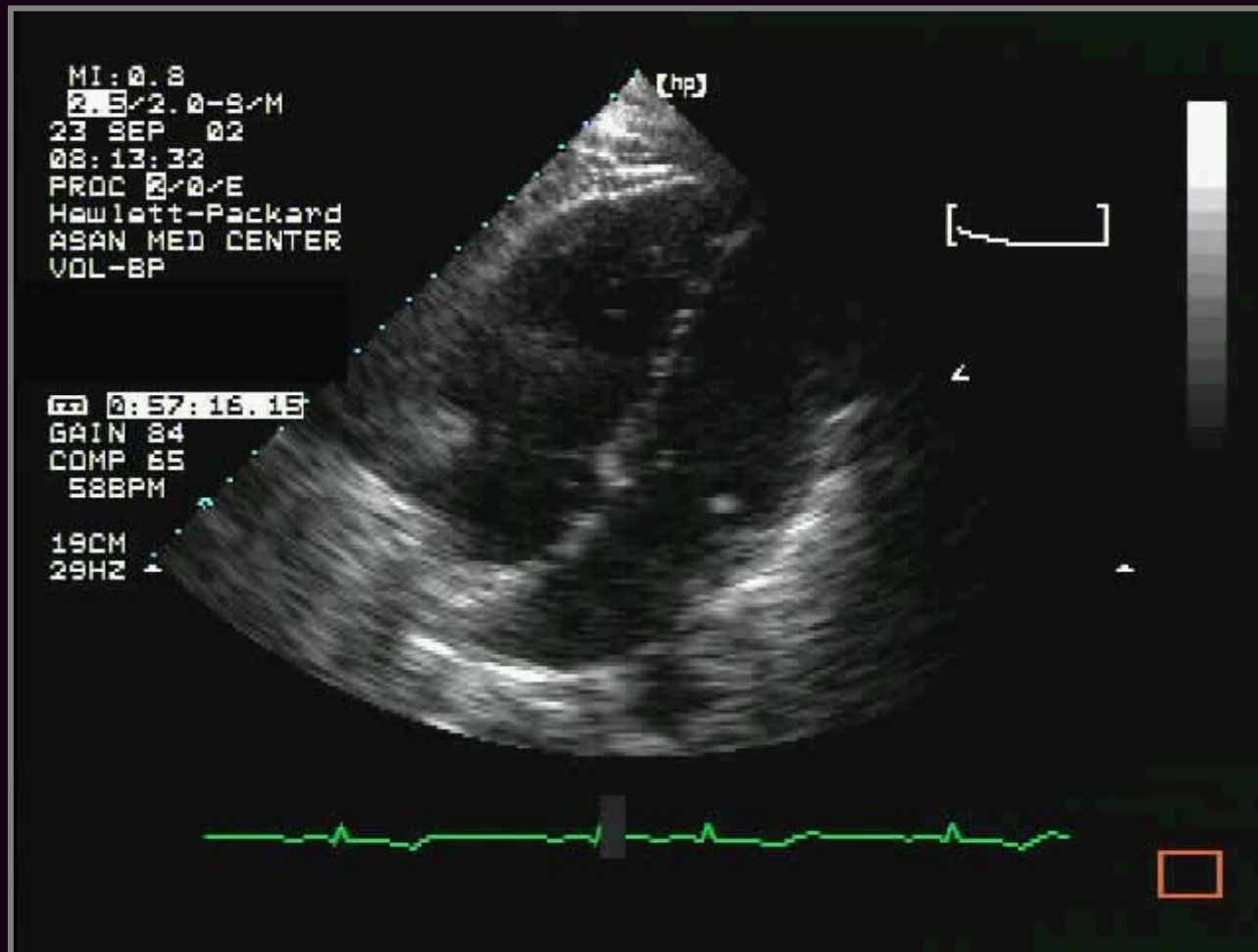
Sinus Venosus Type ASD



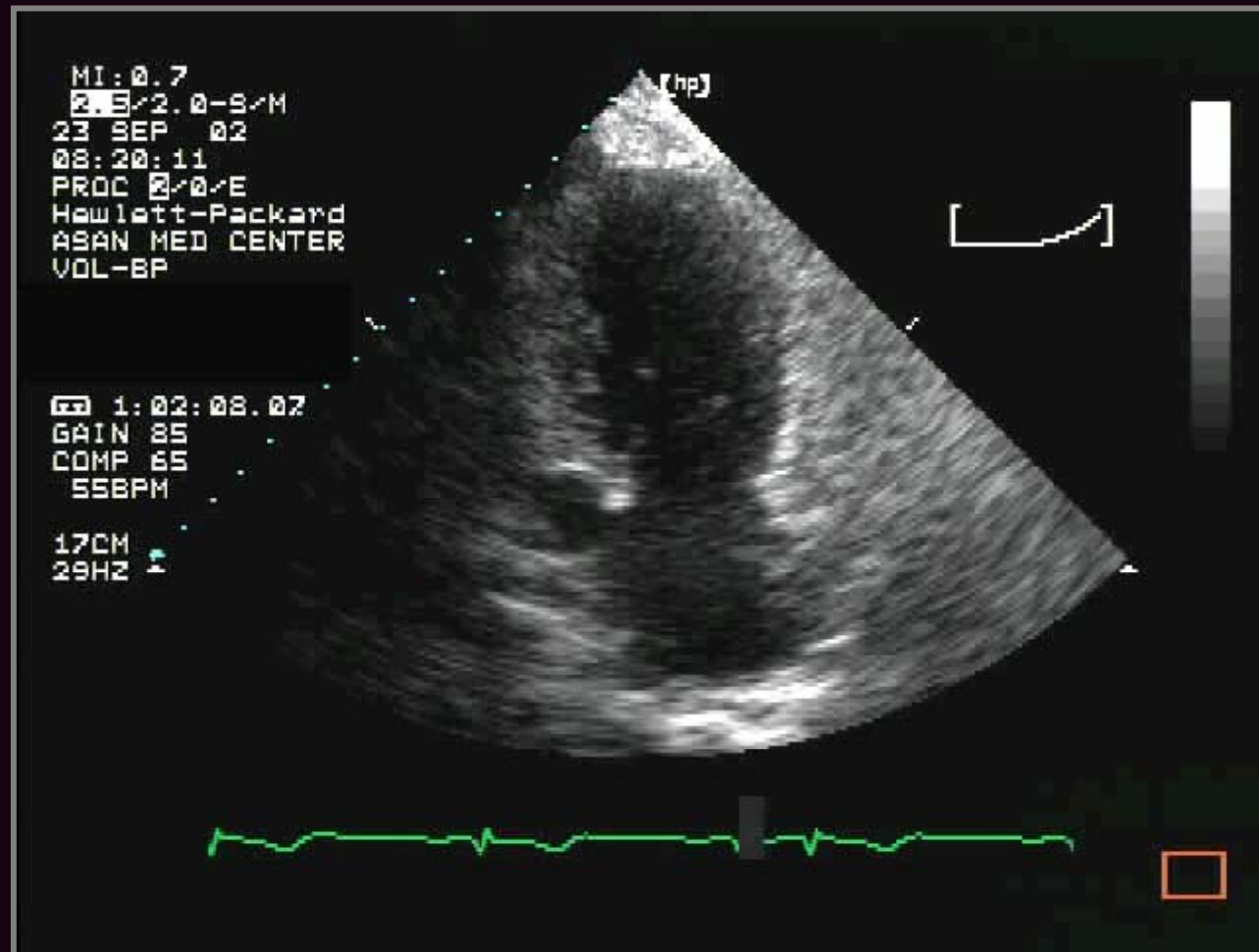
Atrial Septal Defect ?!



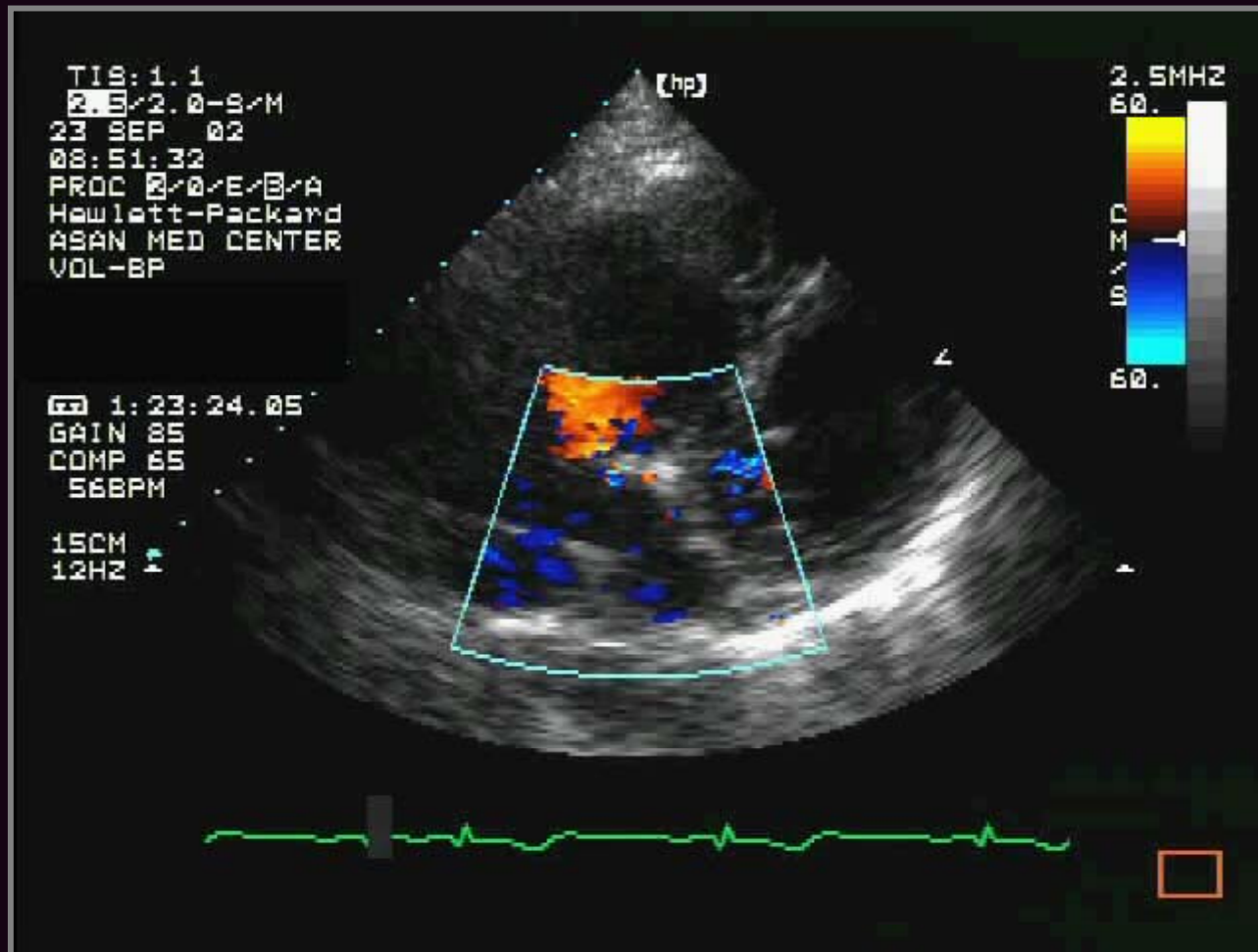
Atrial Septal Defect ?!



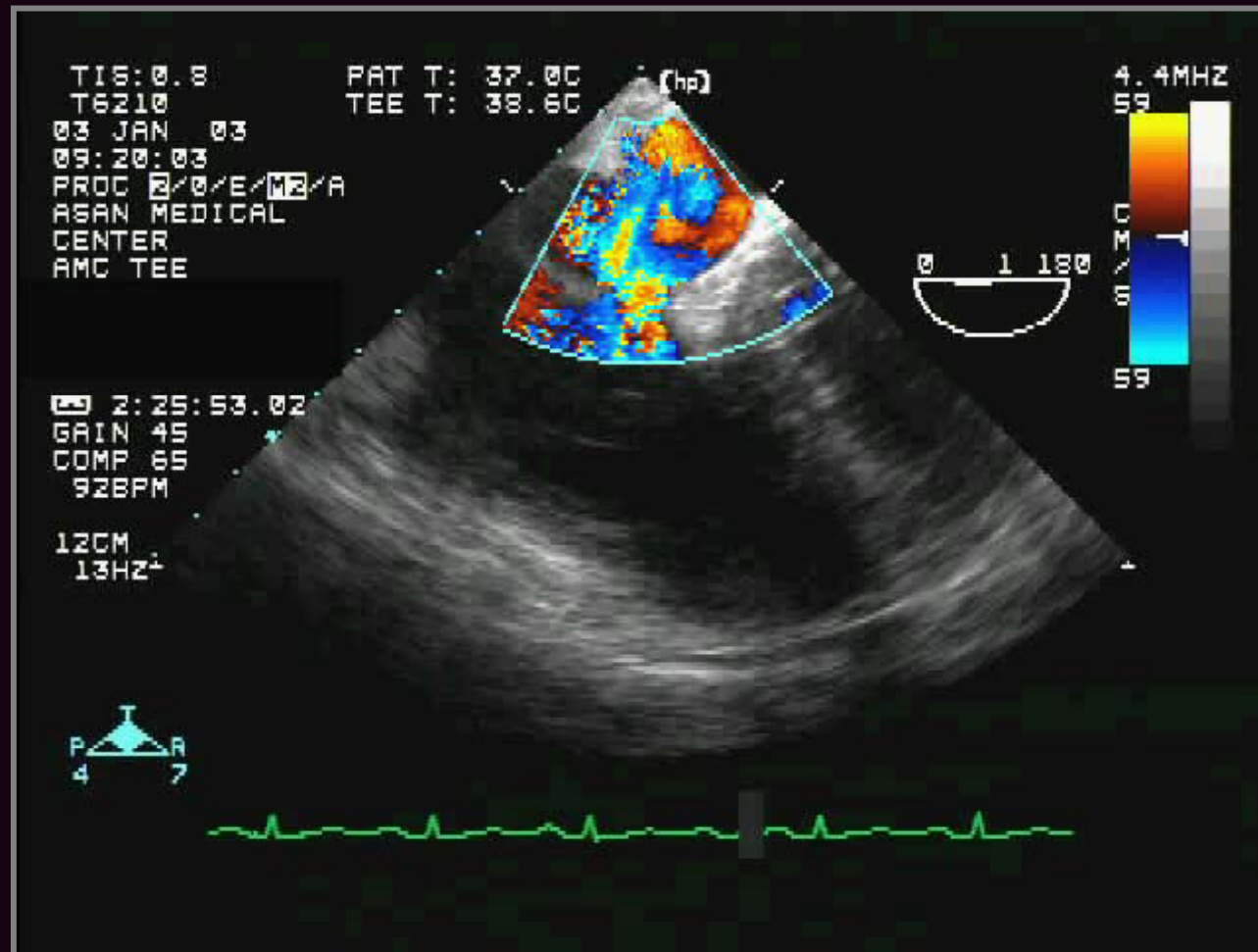
Atrial Septal Defect ?!



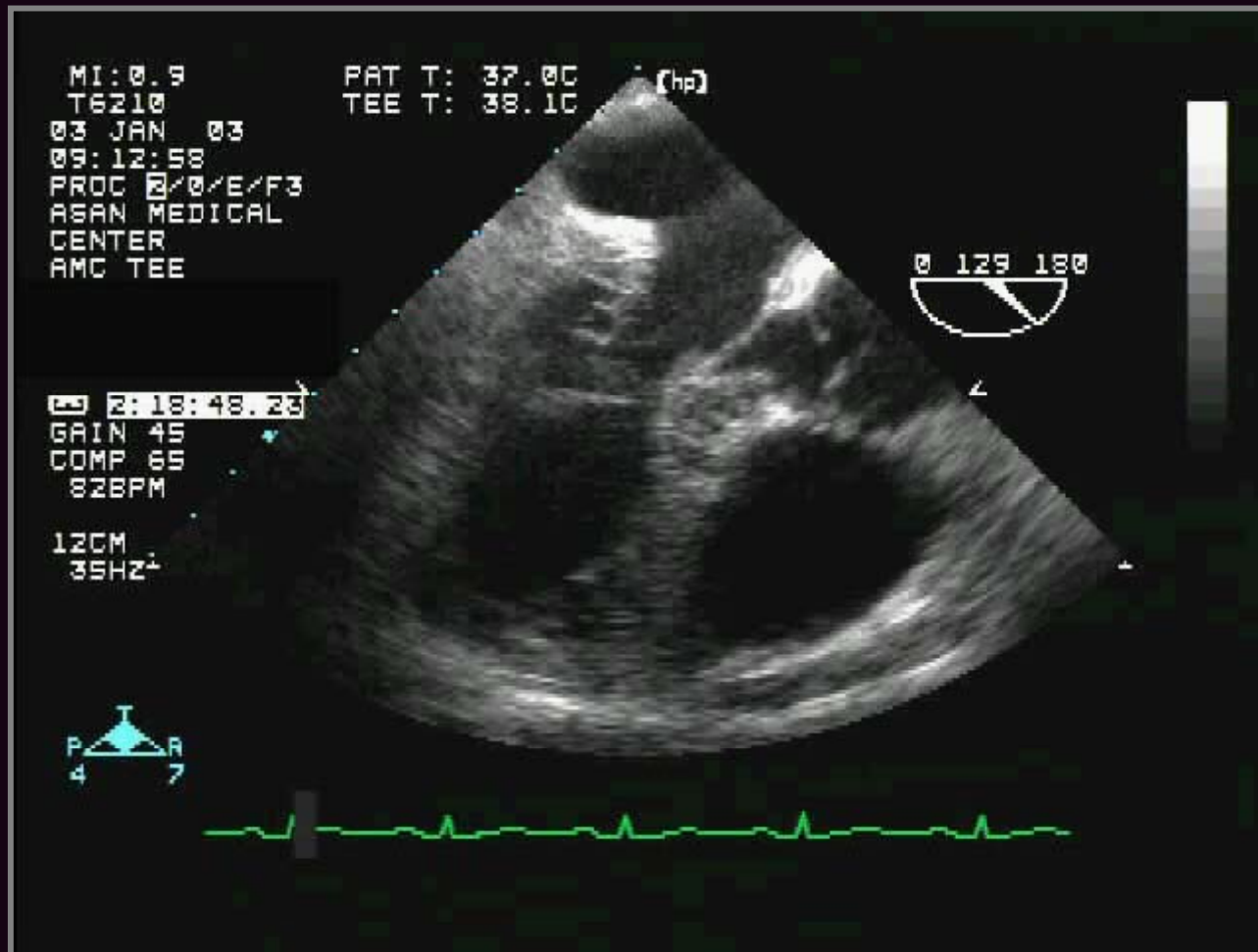
Atrial Septal Defect ?!



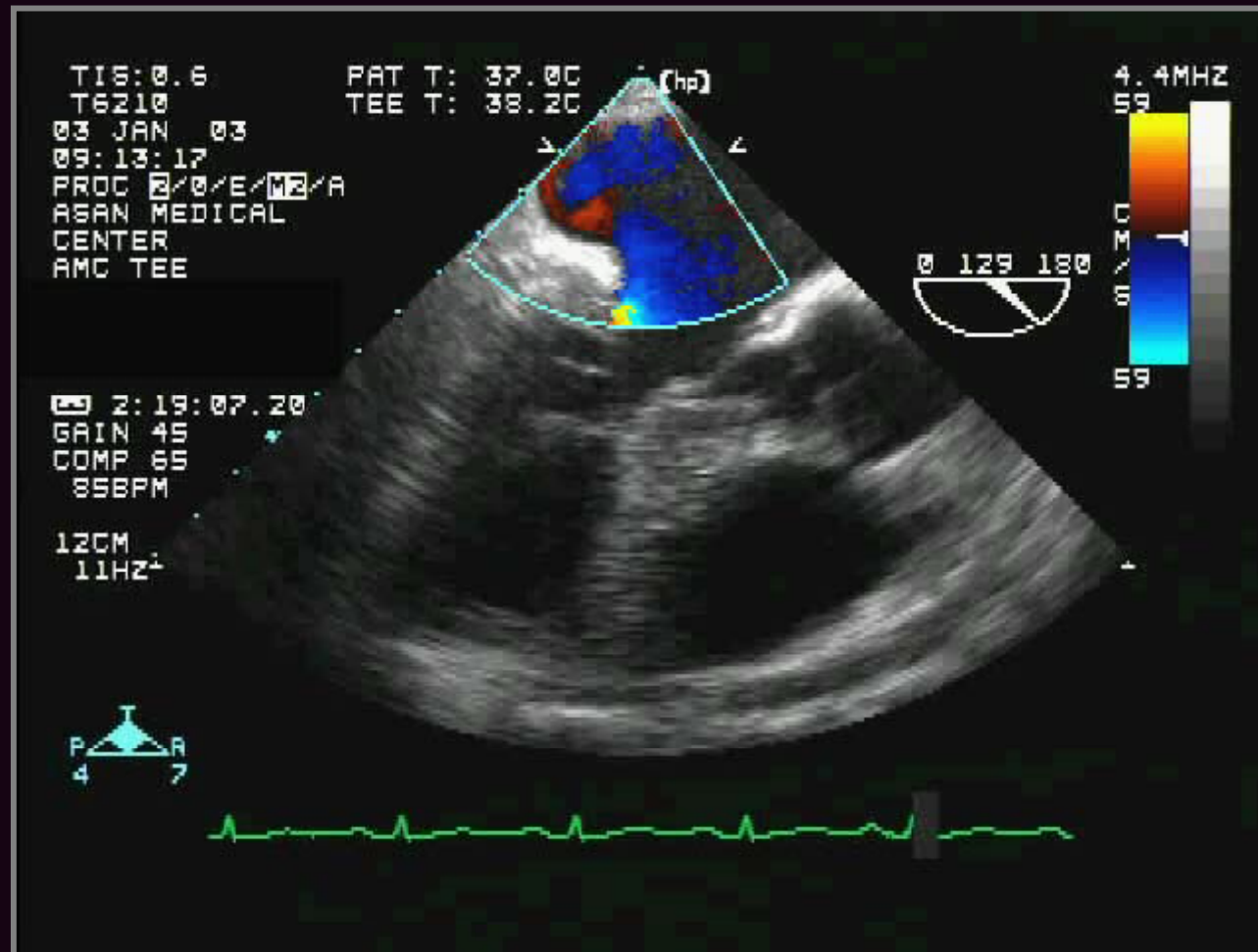
Atrial Septal Defect ?!

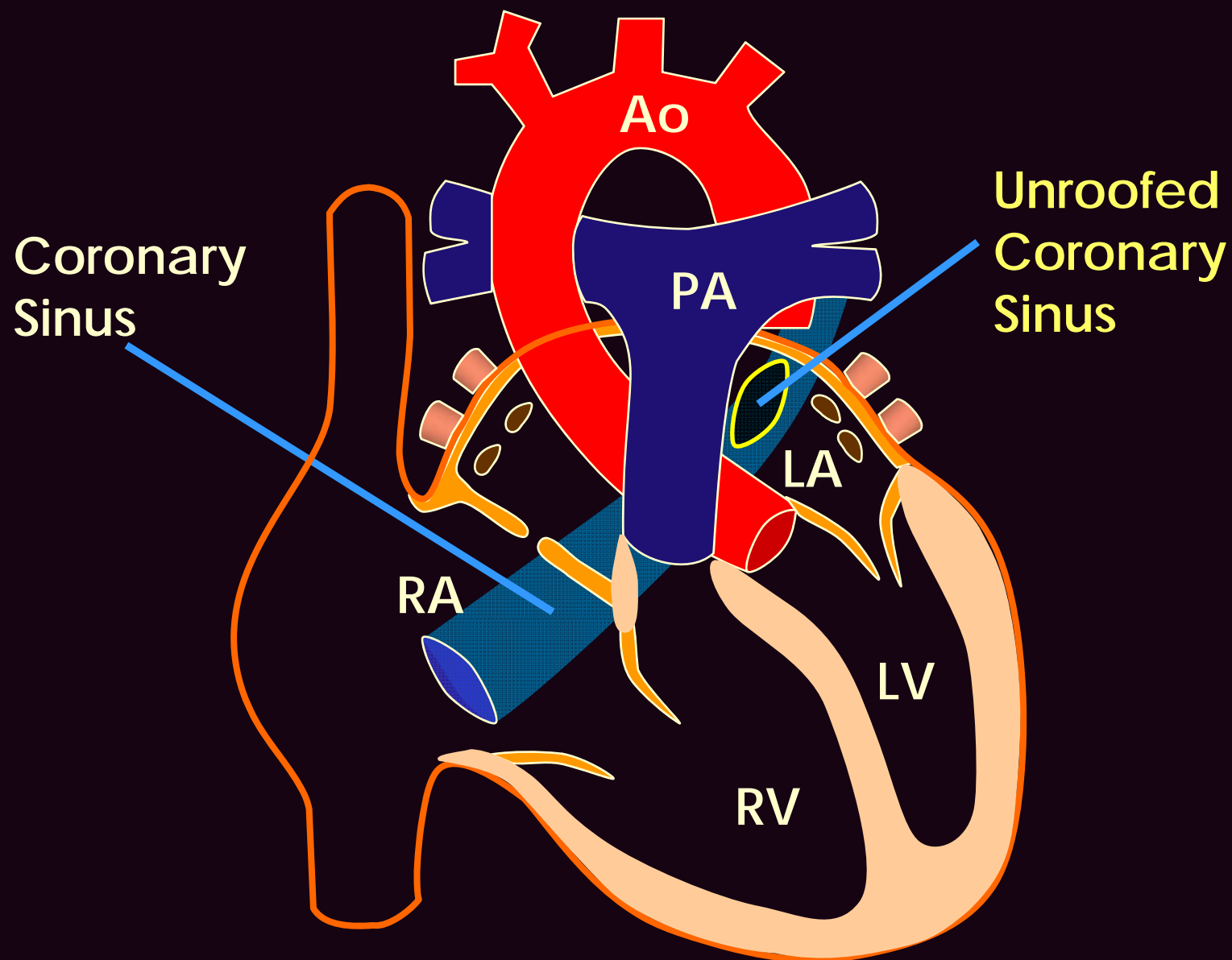


Coronary Sinus Type ASD



Coronary Sinus Type ASD





Coronary Sinus

Unroofed Coronary Sinus

Ao

PA

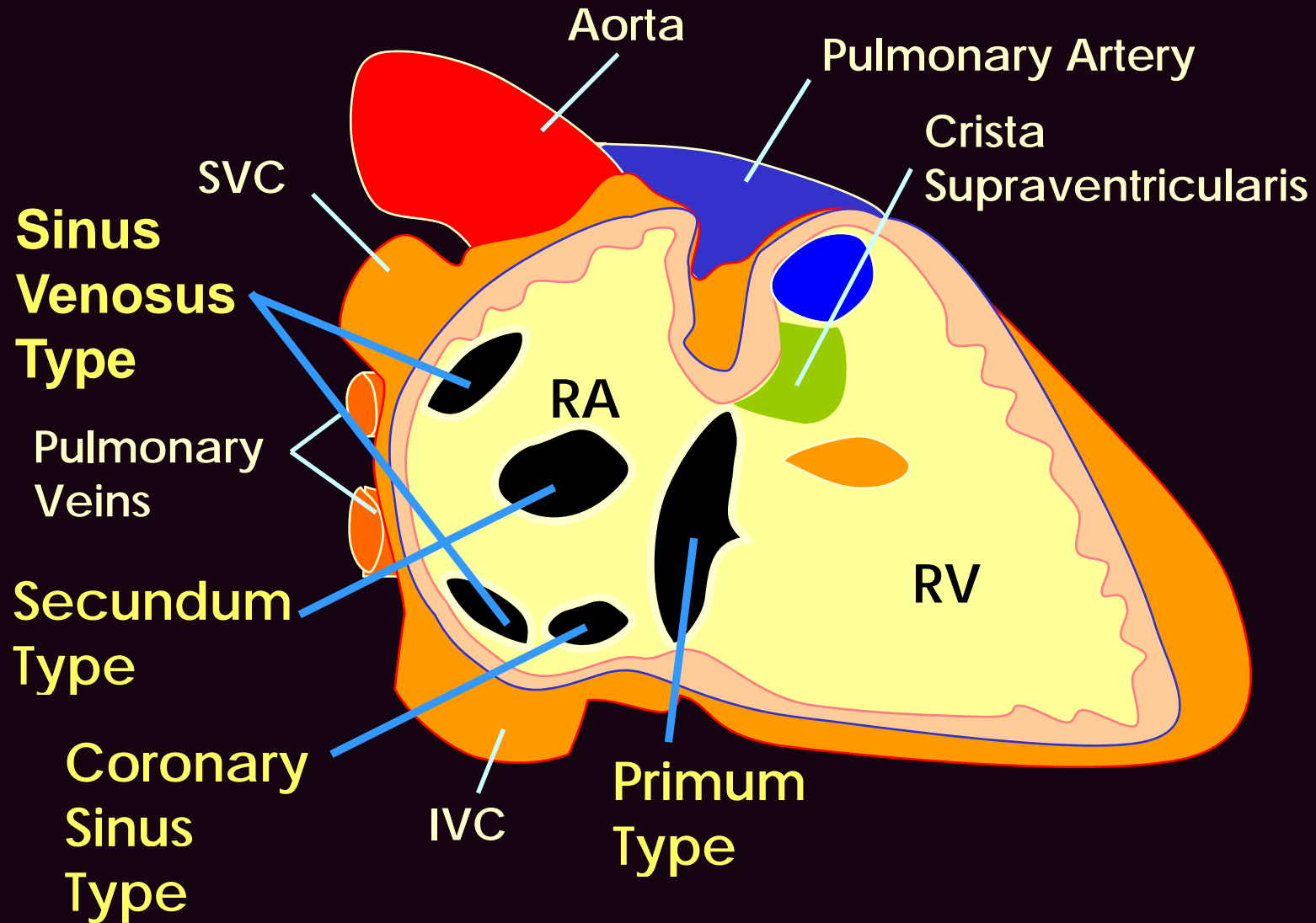
LA

RA

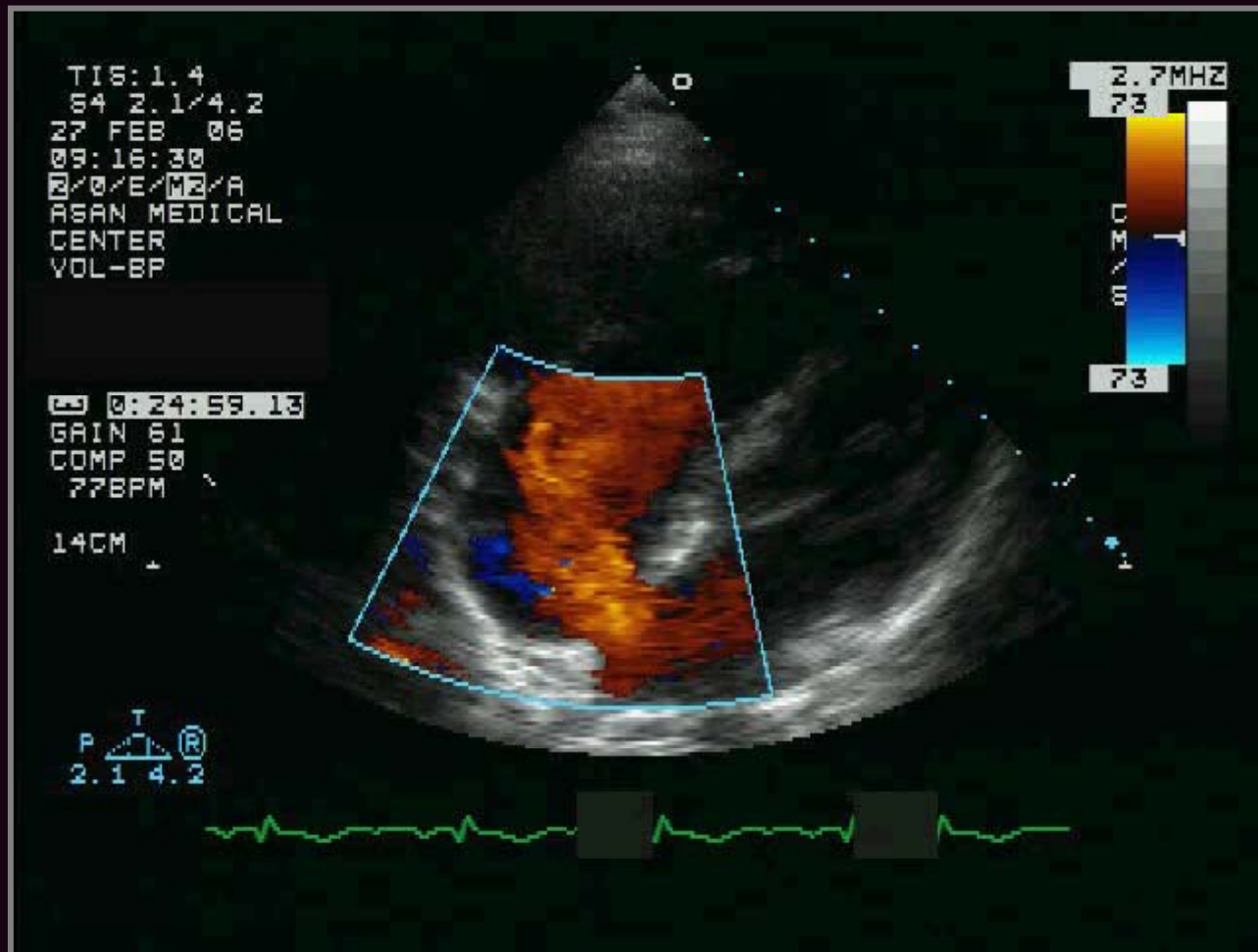
LV

RV

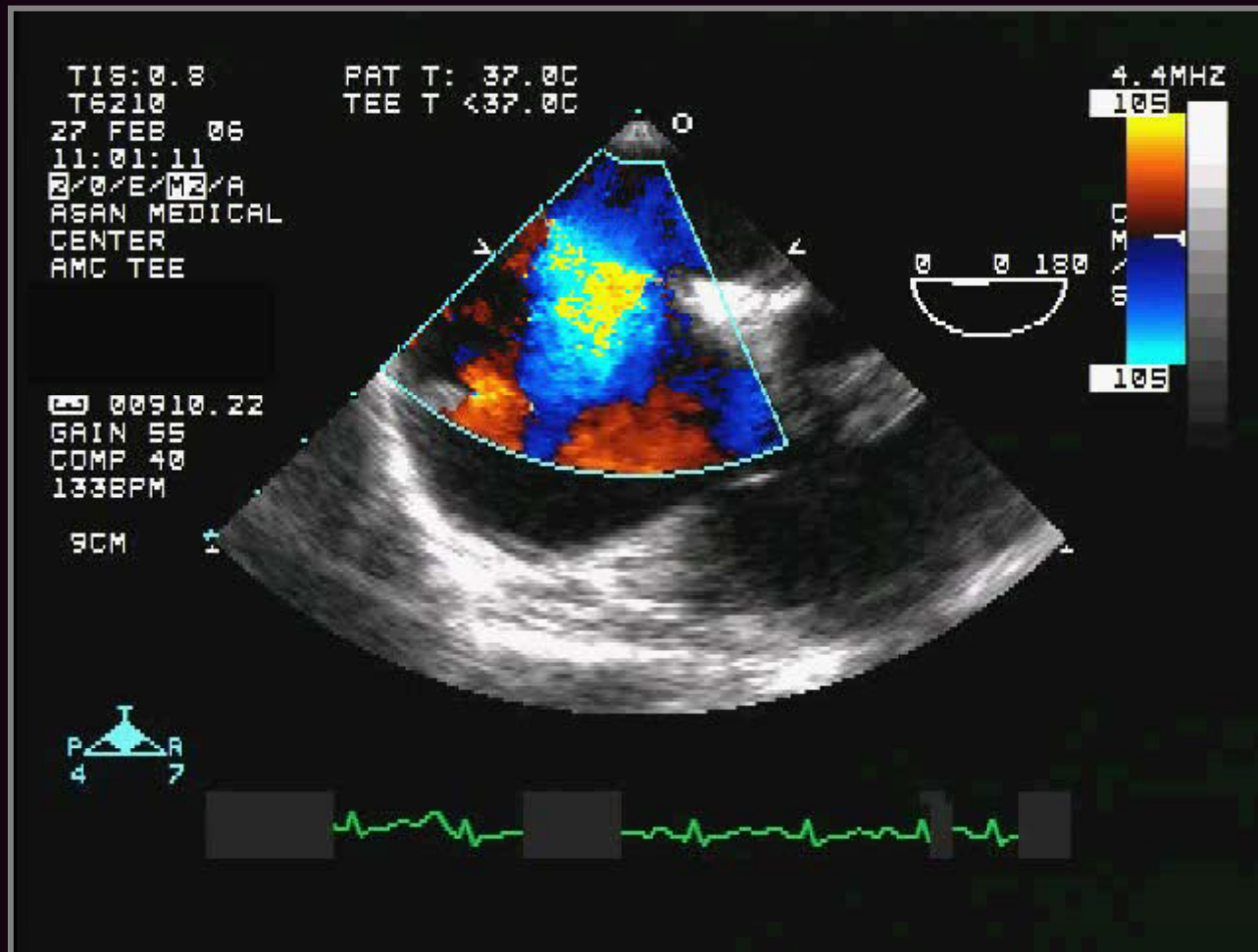
Atrial Septal Defect



Secundum ASD (29/F)



Secundum ASD (29/F)

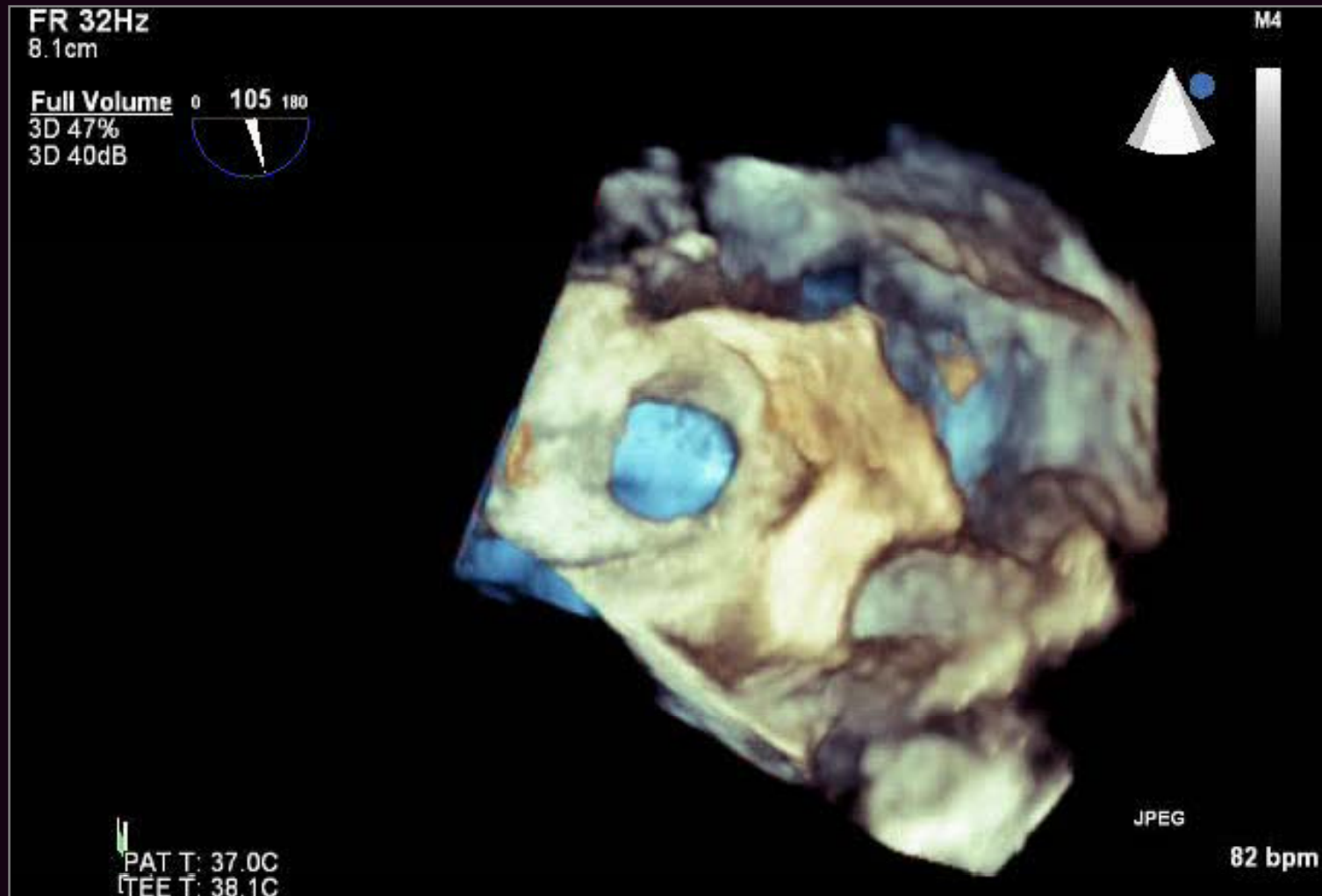


Secundum ASD (29/F)

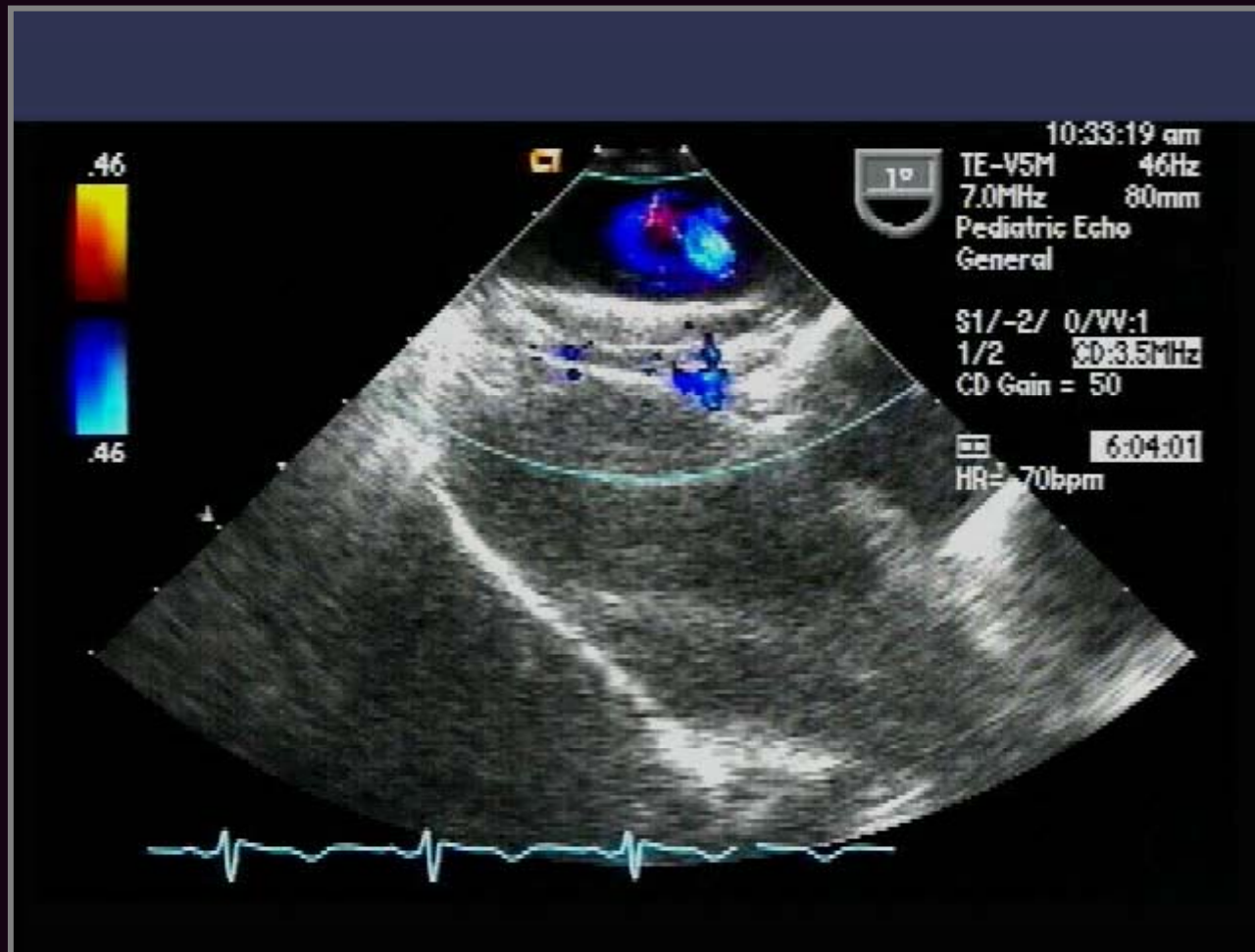
□ 환자에게 가장 적절한 치료는?

1. Open heart surgery (patch closure)
2. Device closure
3. Heart lung transplantation
4. Medical management

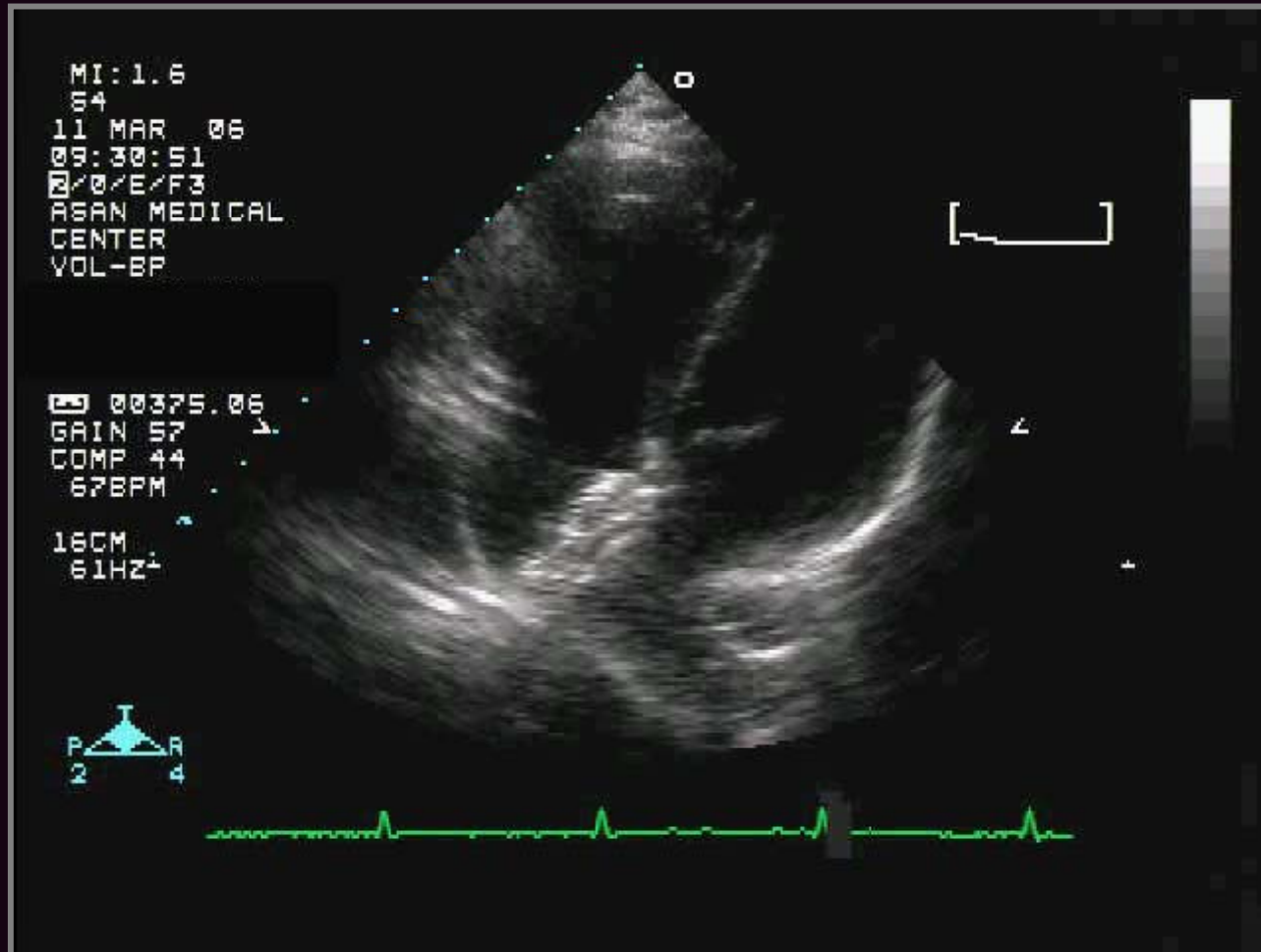
Atrial Septal Defect



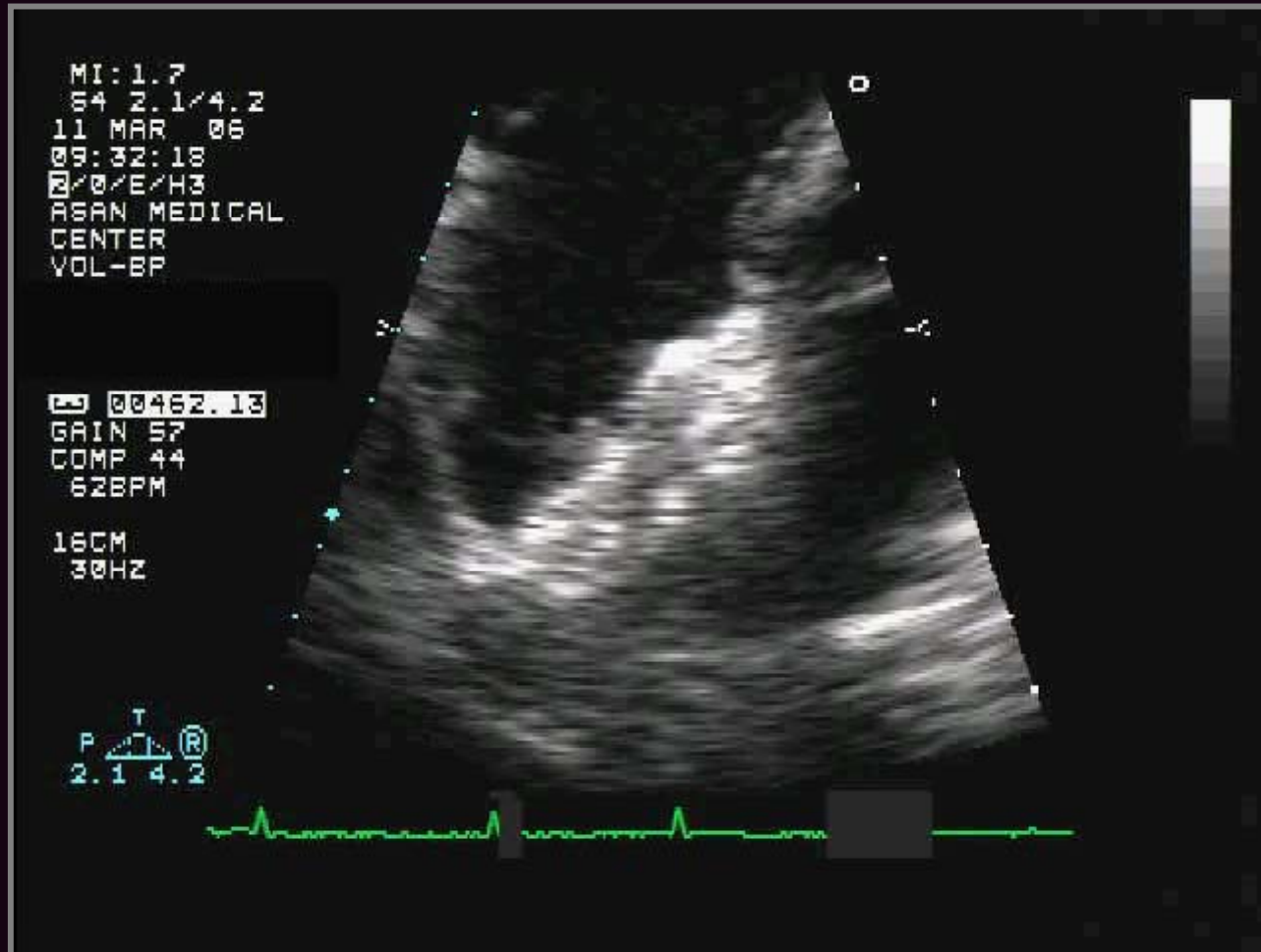
Device Closure of ASD



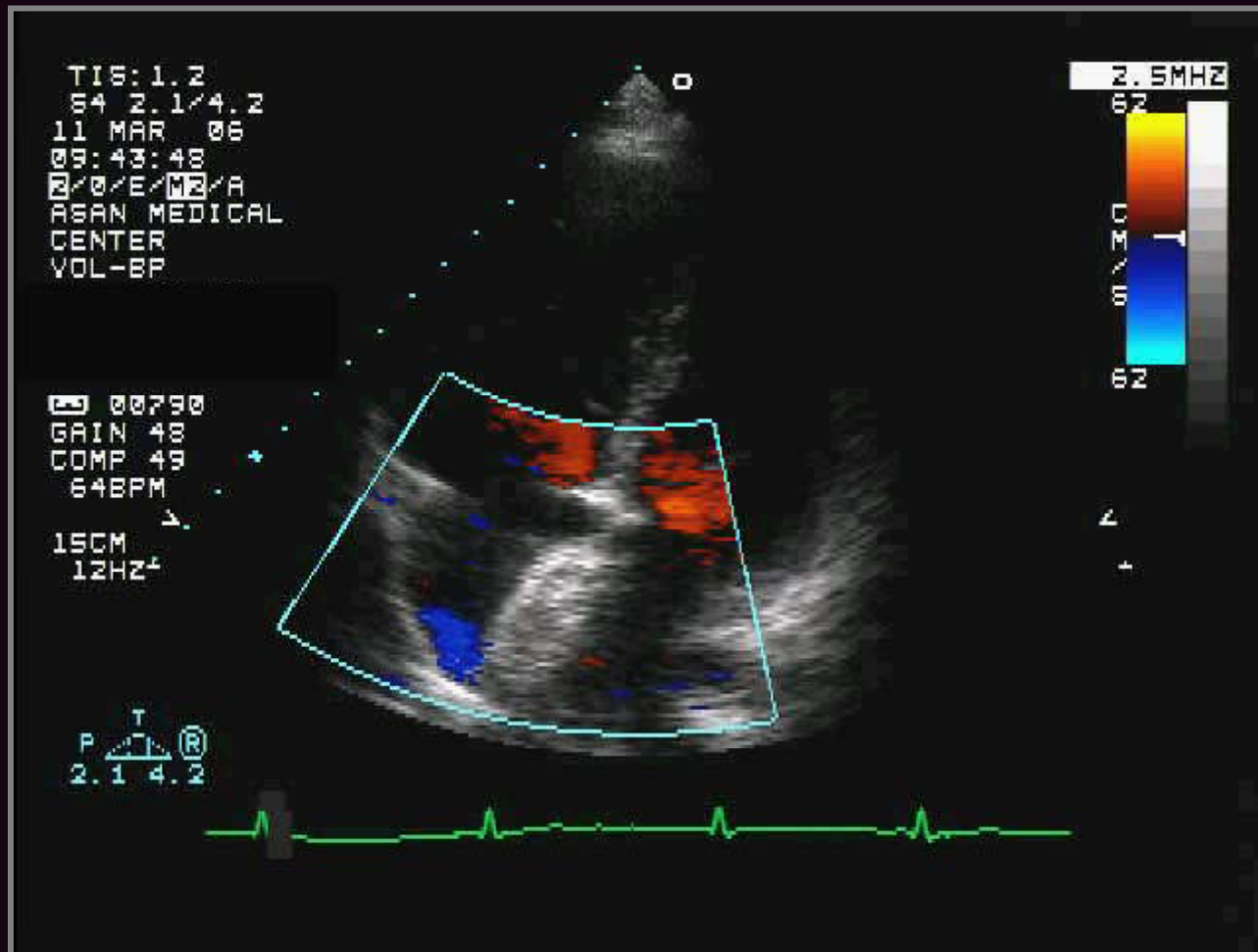
Device Closure of ASD



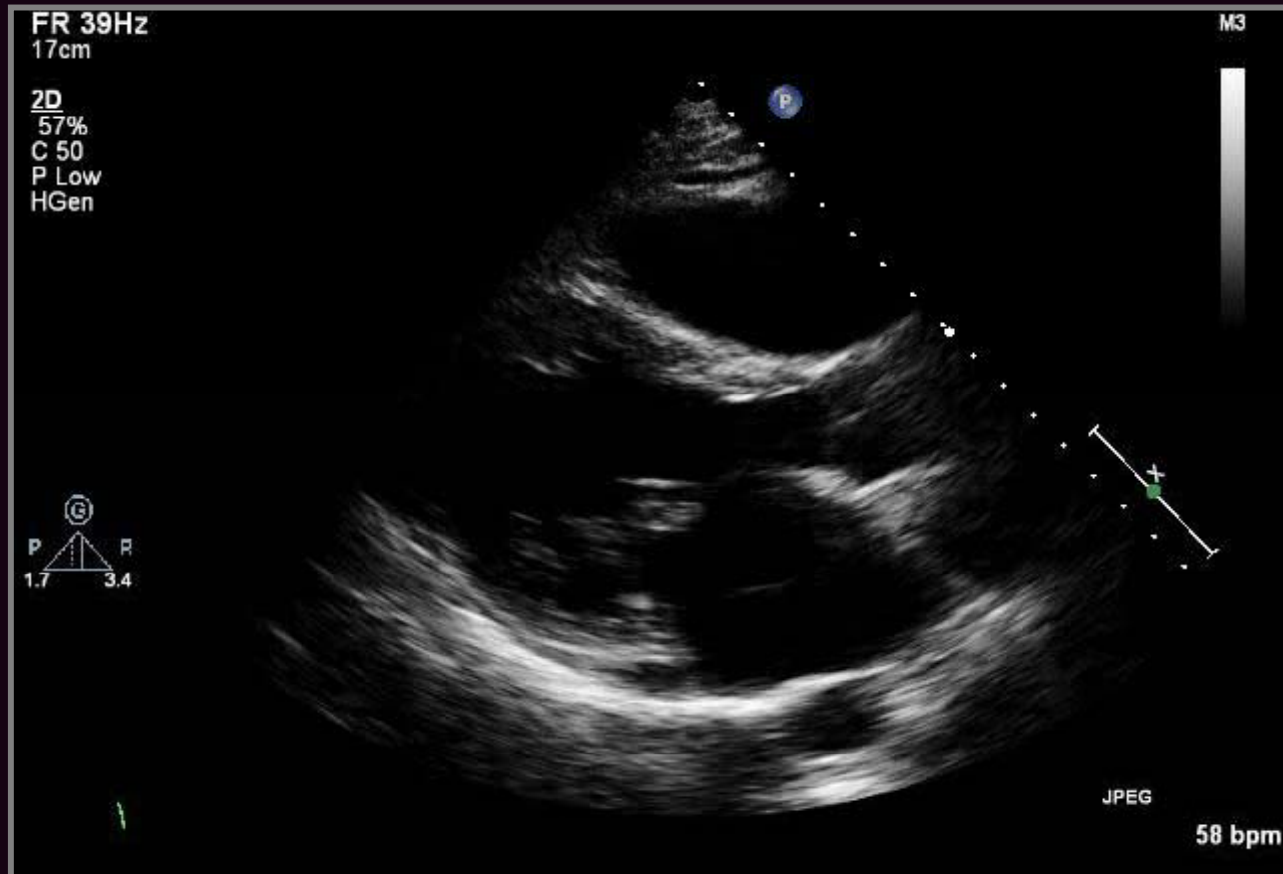
Device Closure of ASD



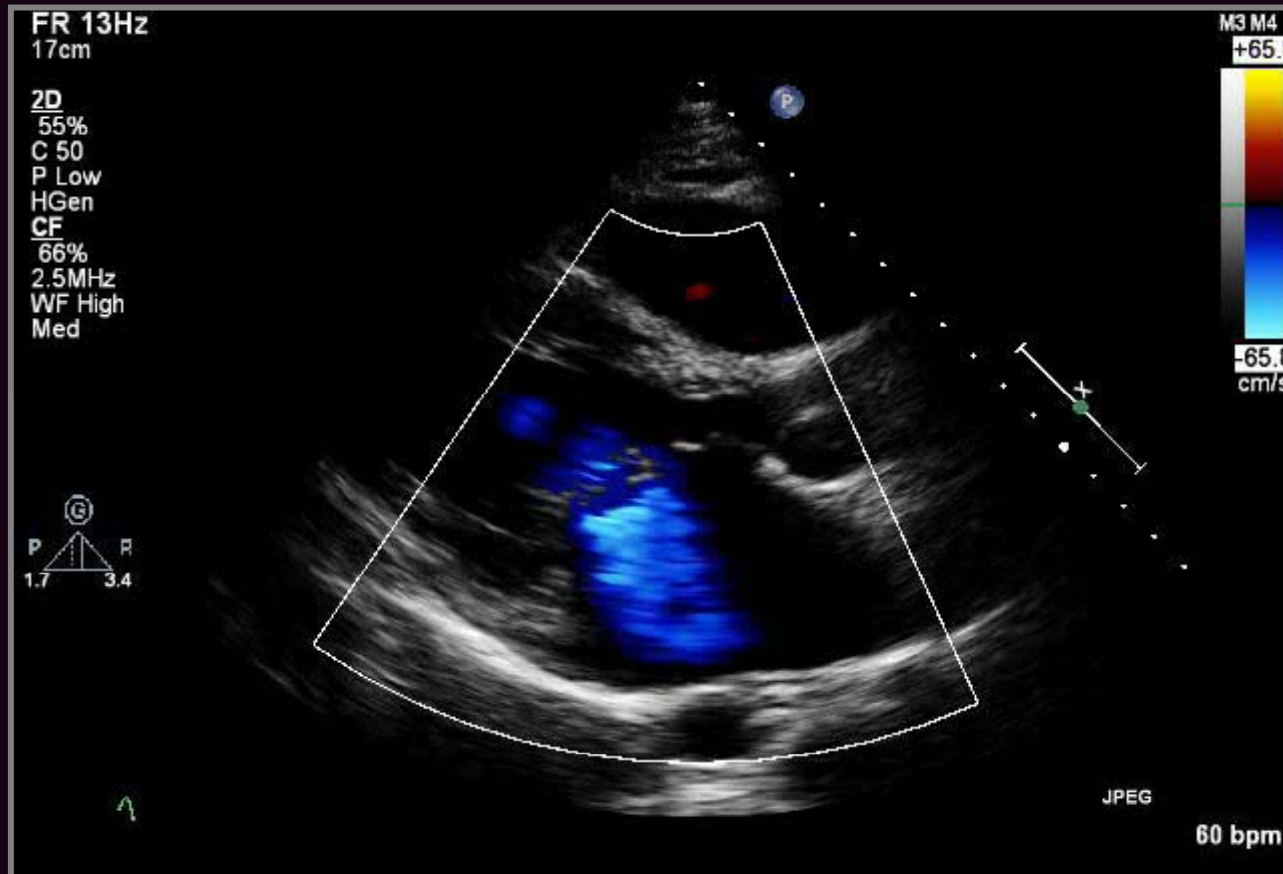
Device Closure of ASD



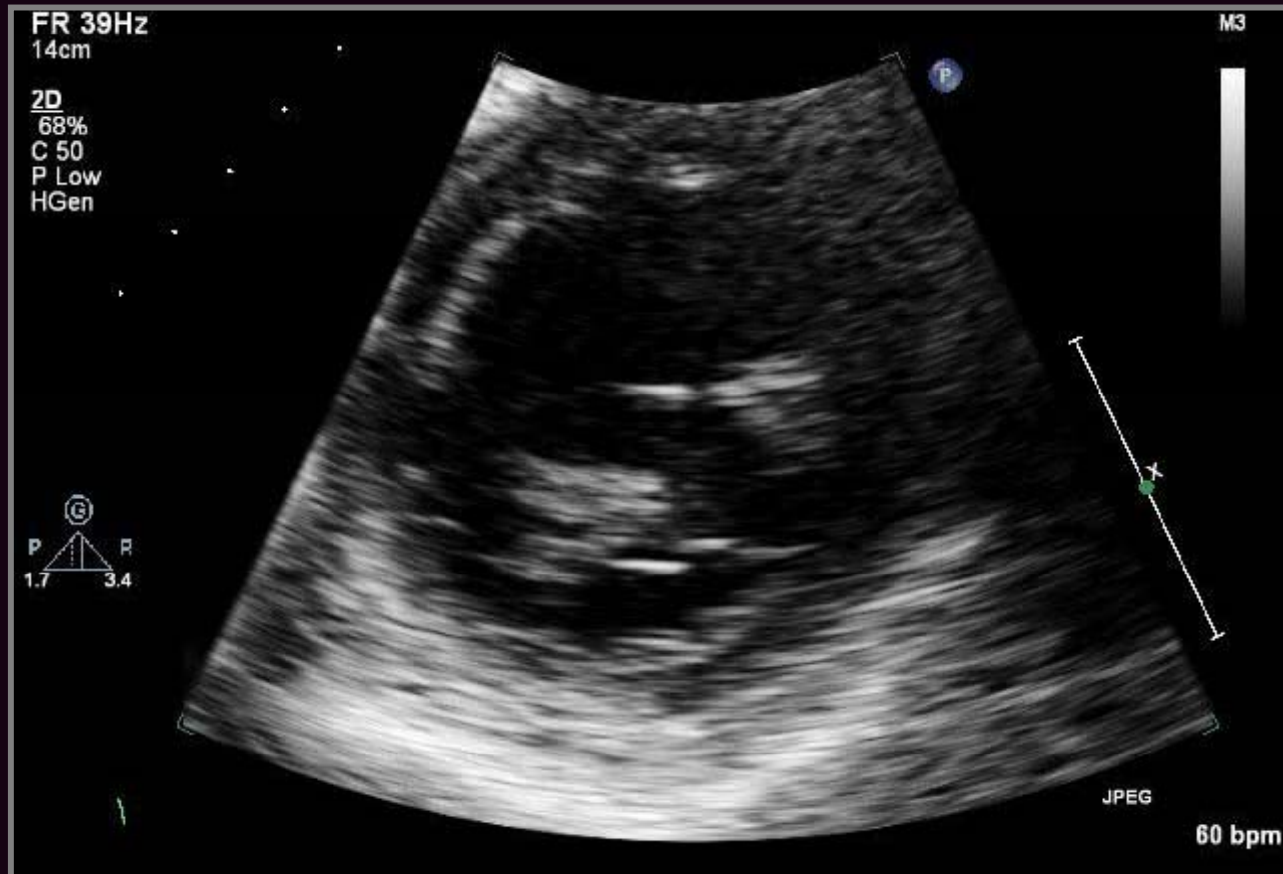Cause of Mitral Regurgitation



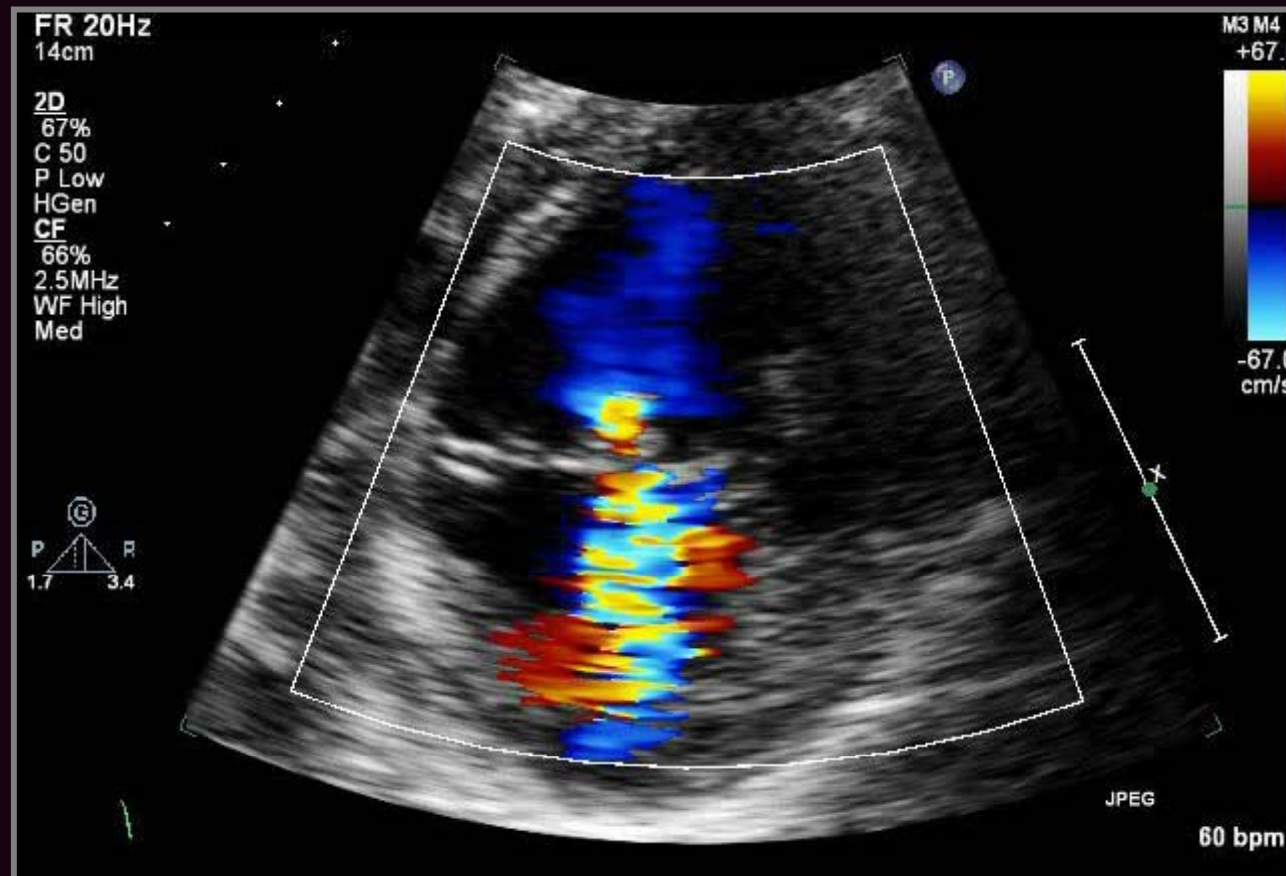
Cause of Mitral Regurgitation



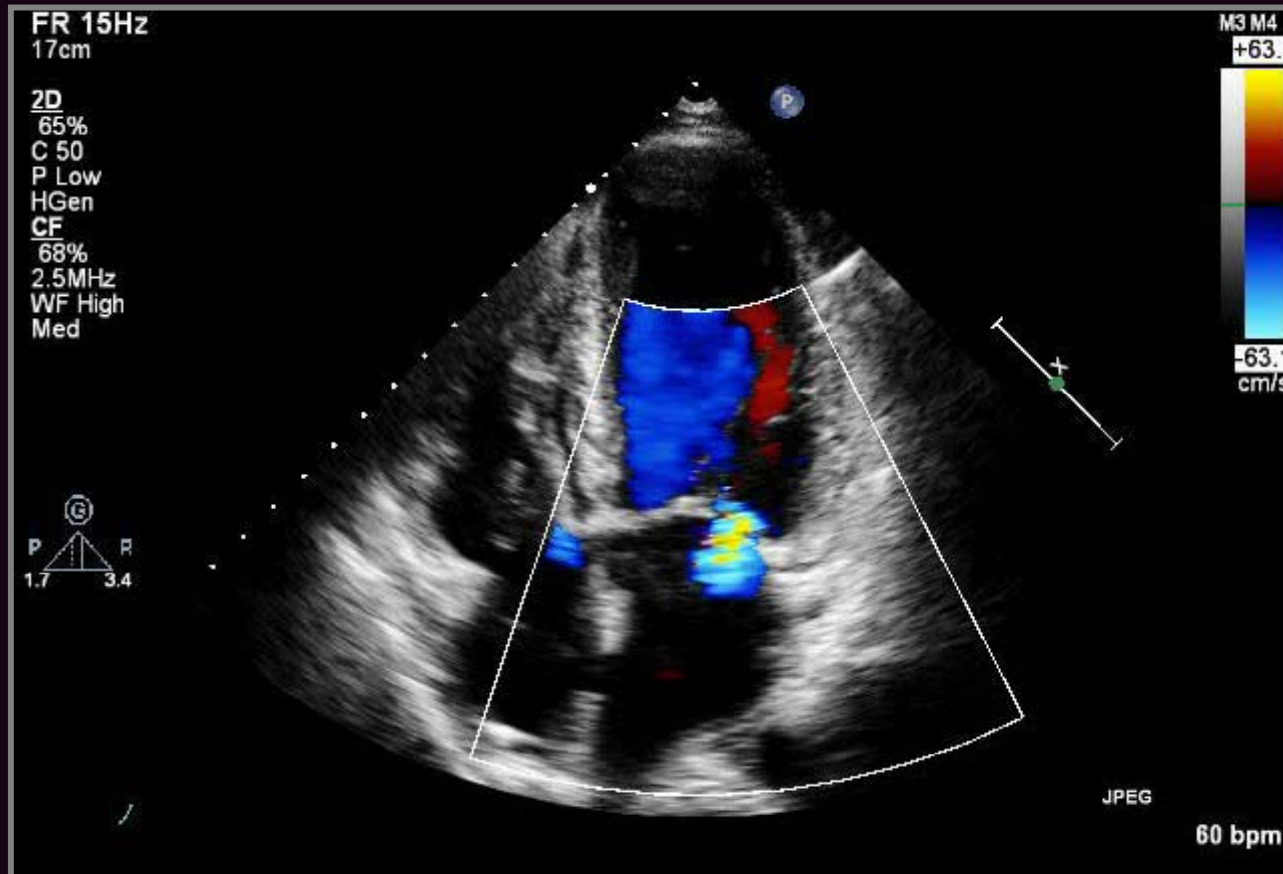
Cause of Mitral Regurgitation



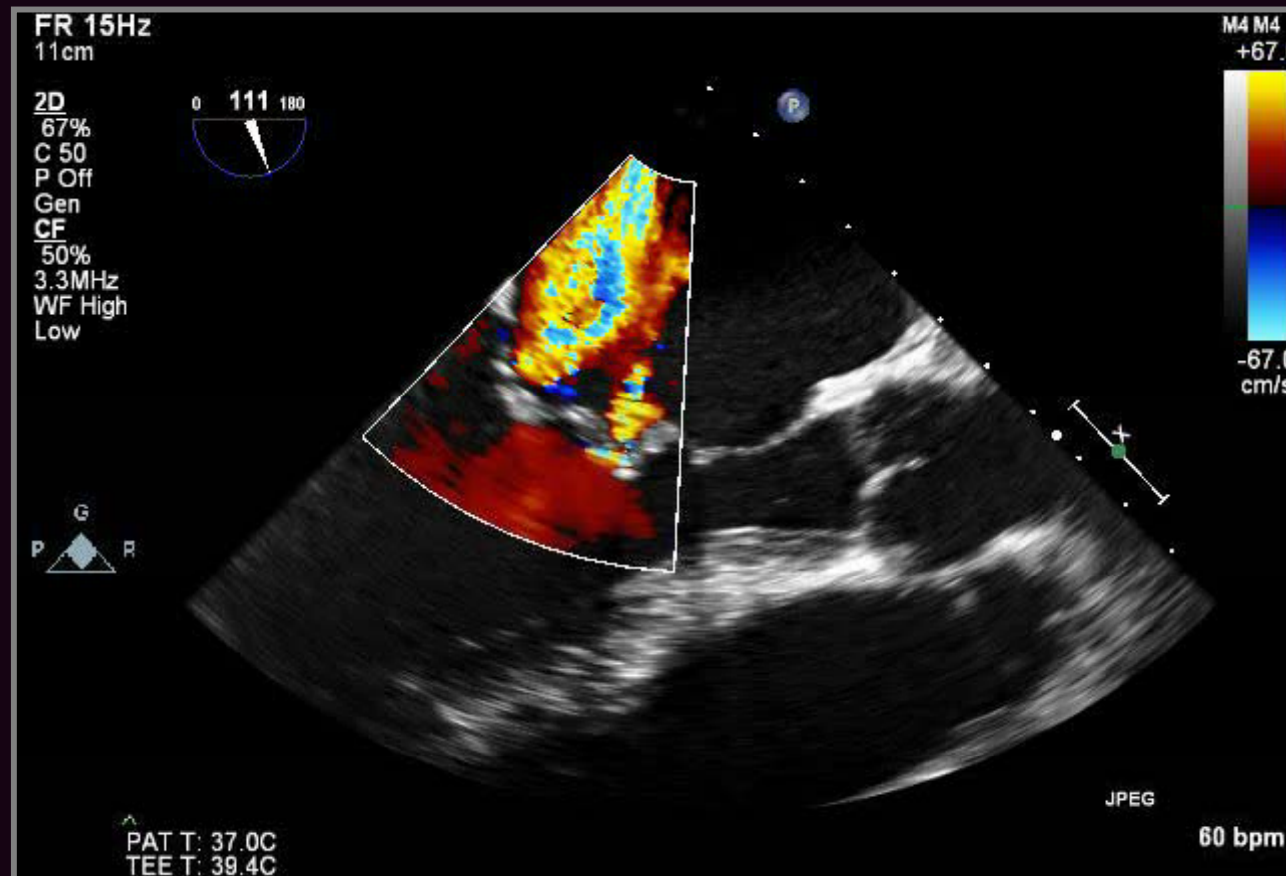
Cause of Mitral Regurgitation



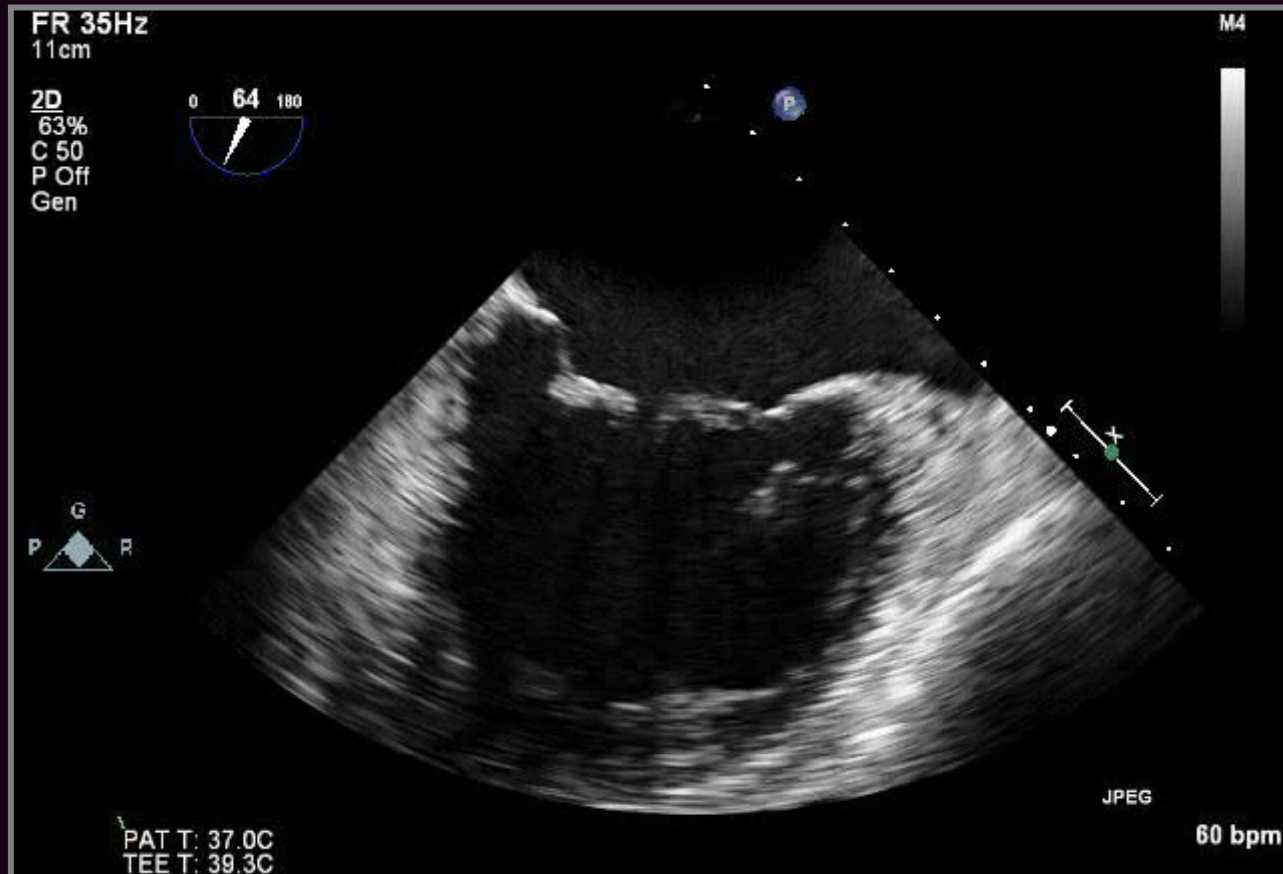
Cause of Mitral Regurgitation



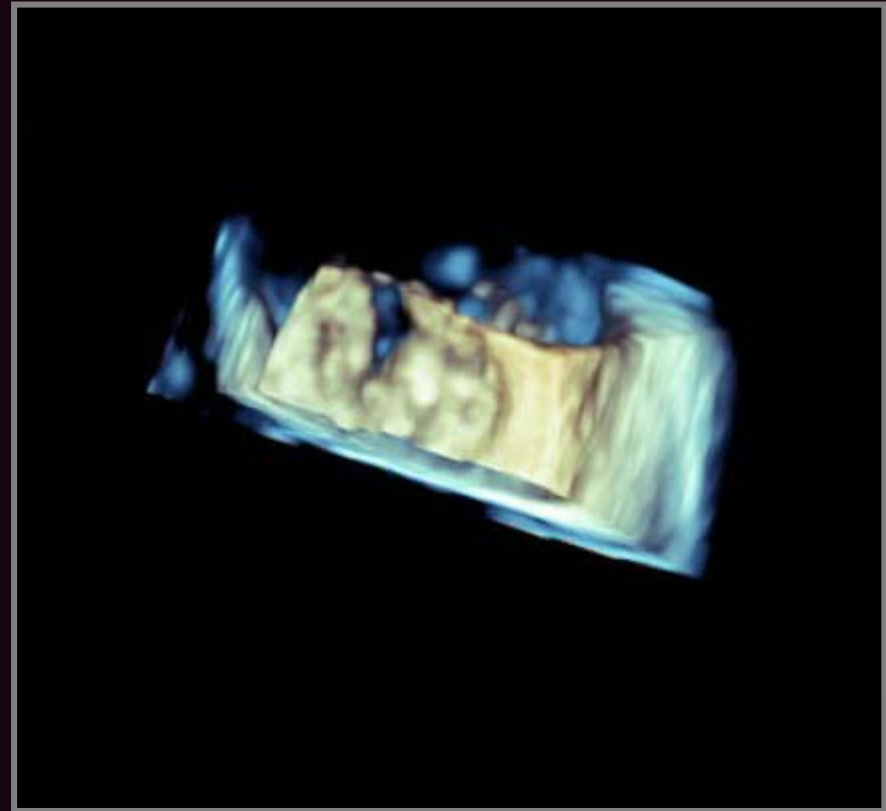
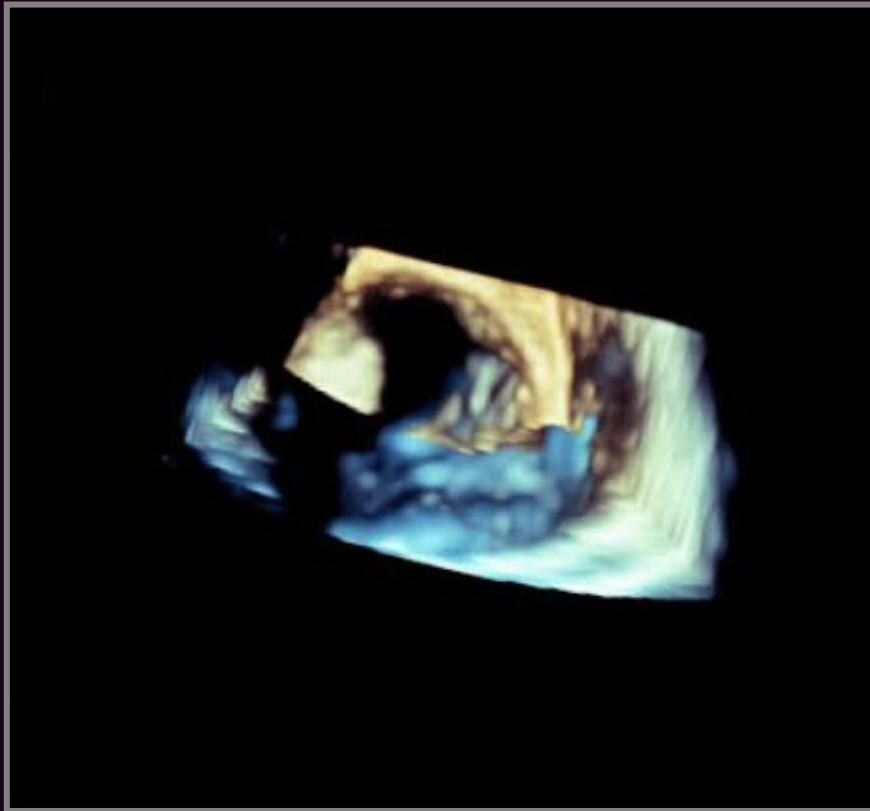Cause of Mitral Regurgitation



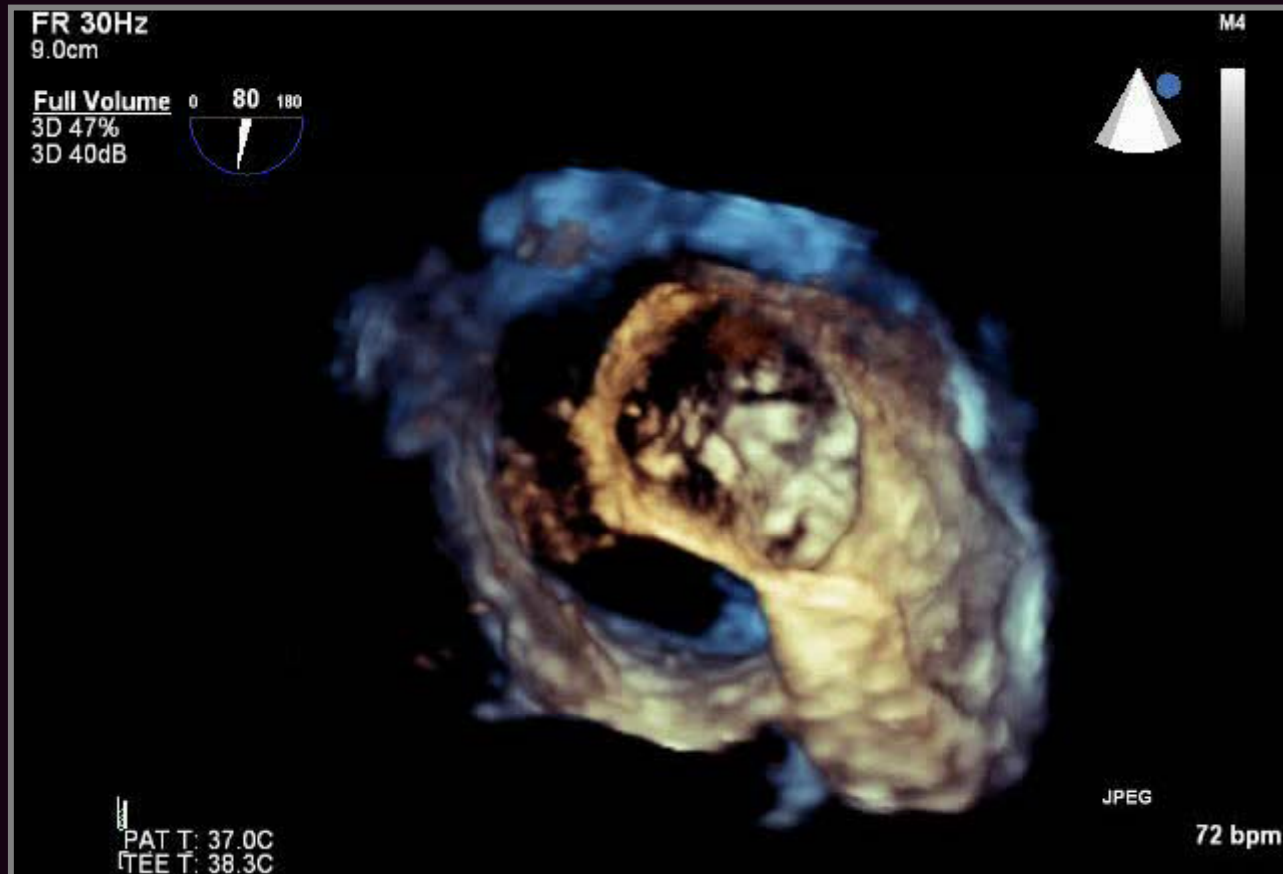
Cause of Mitral Regurgitation



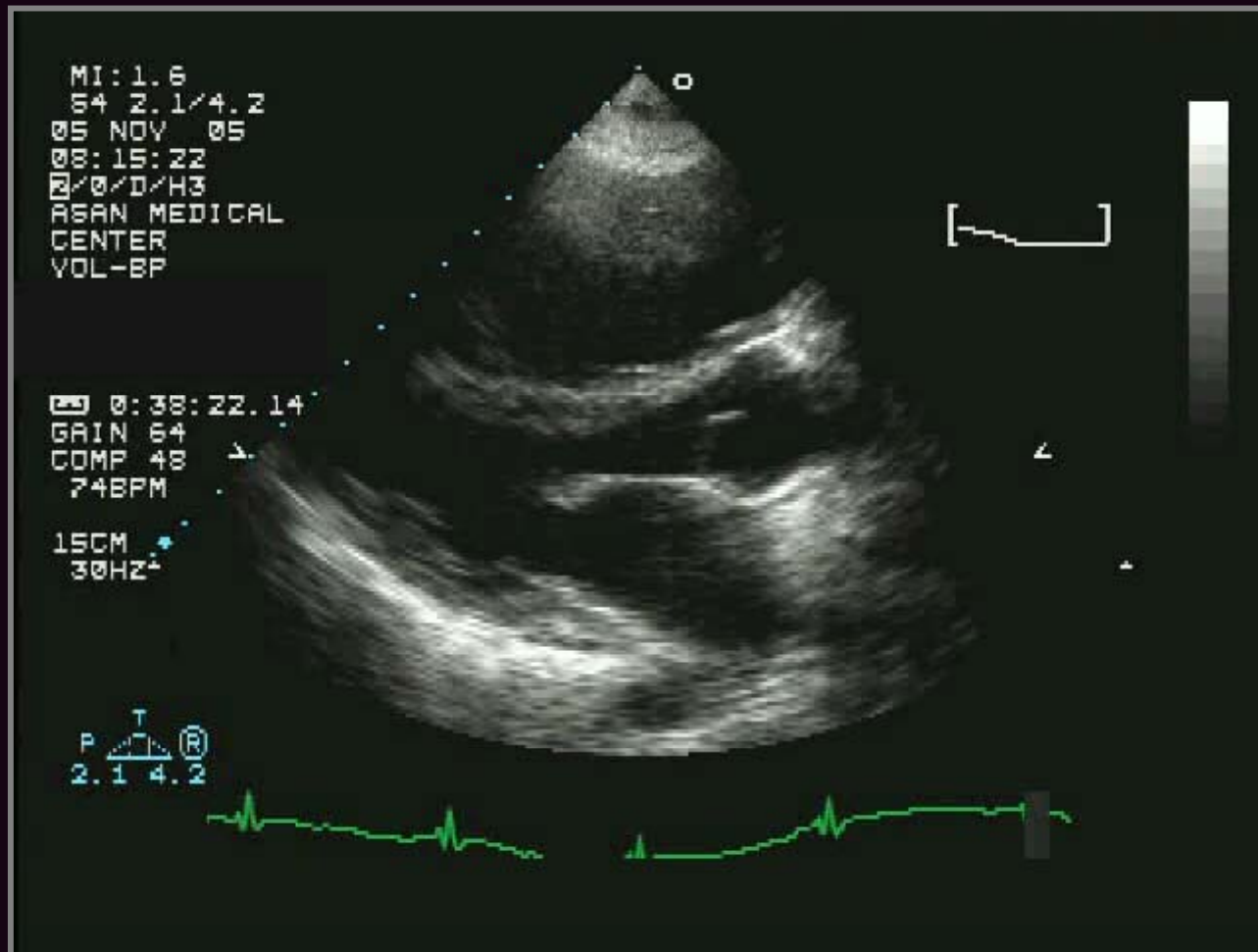
Cleft Mitral Valve



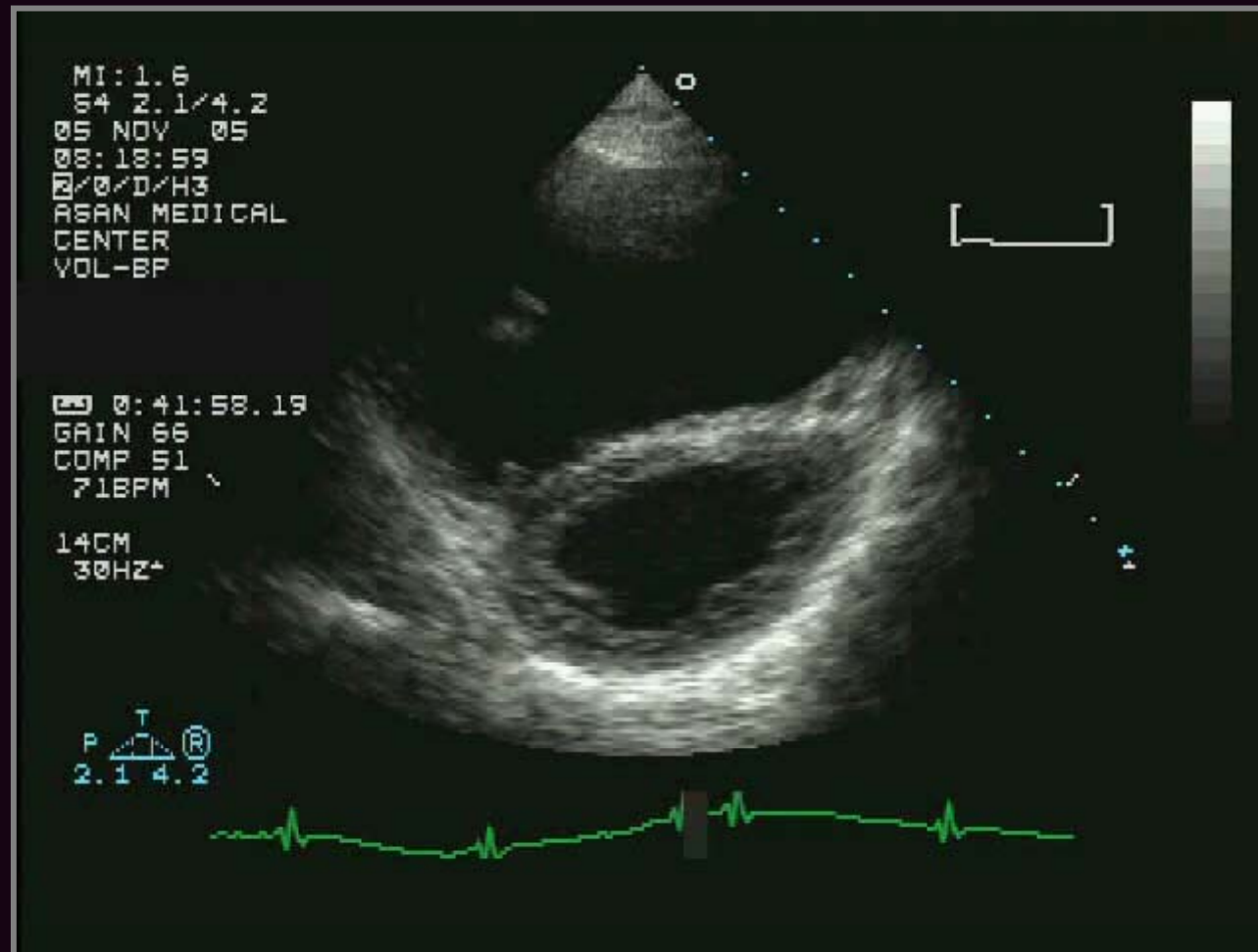
Double-Orifice MV



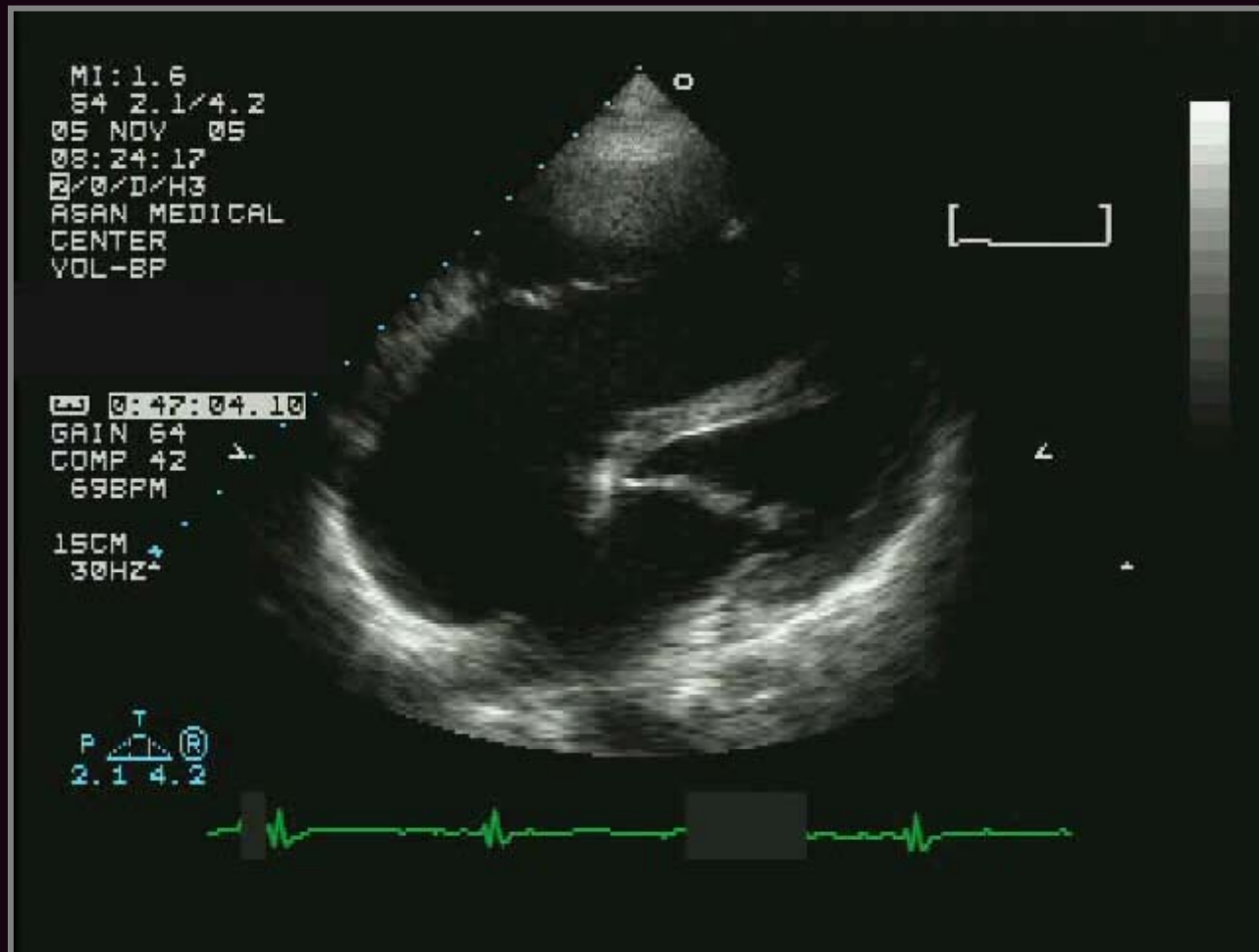
Atrial Septal Defect (28/F)



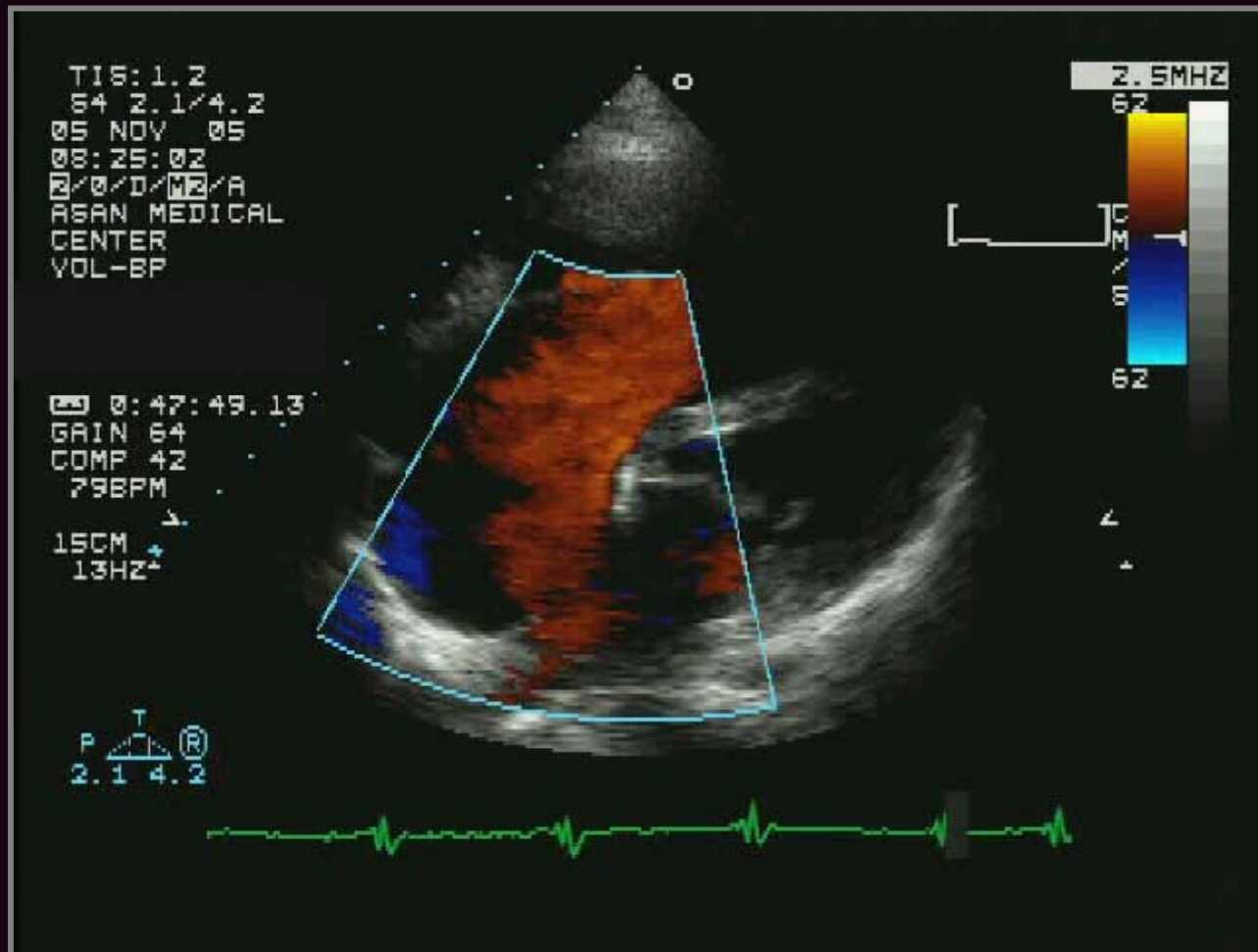
Atrial Septal Defect (28/F)



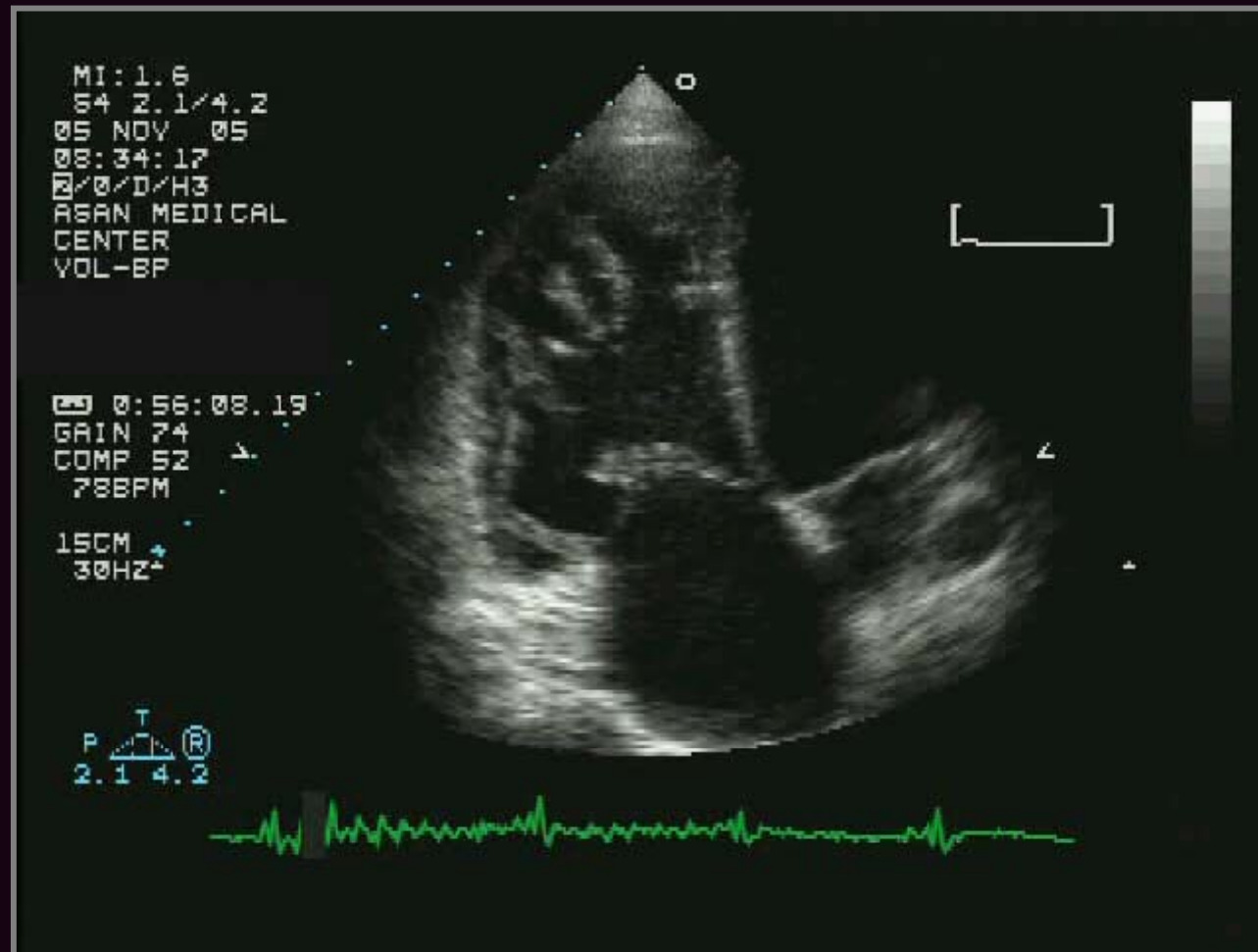
Atrial Septal Defect (28/F)



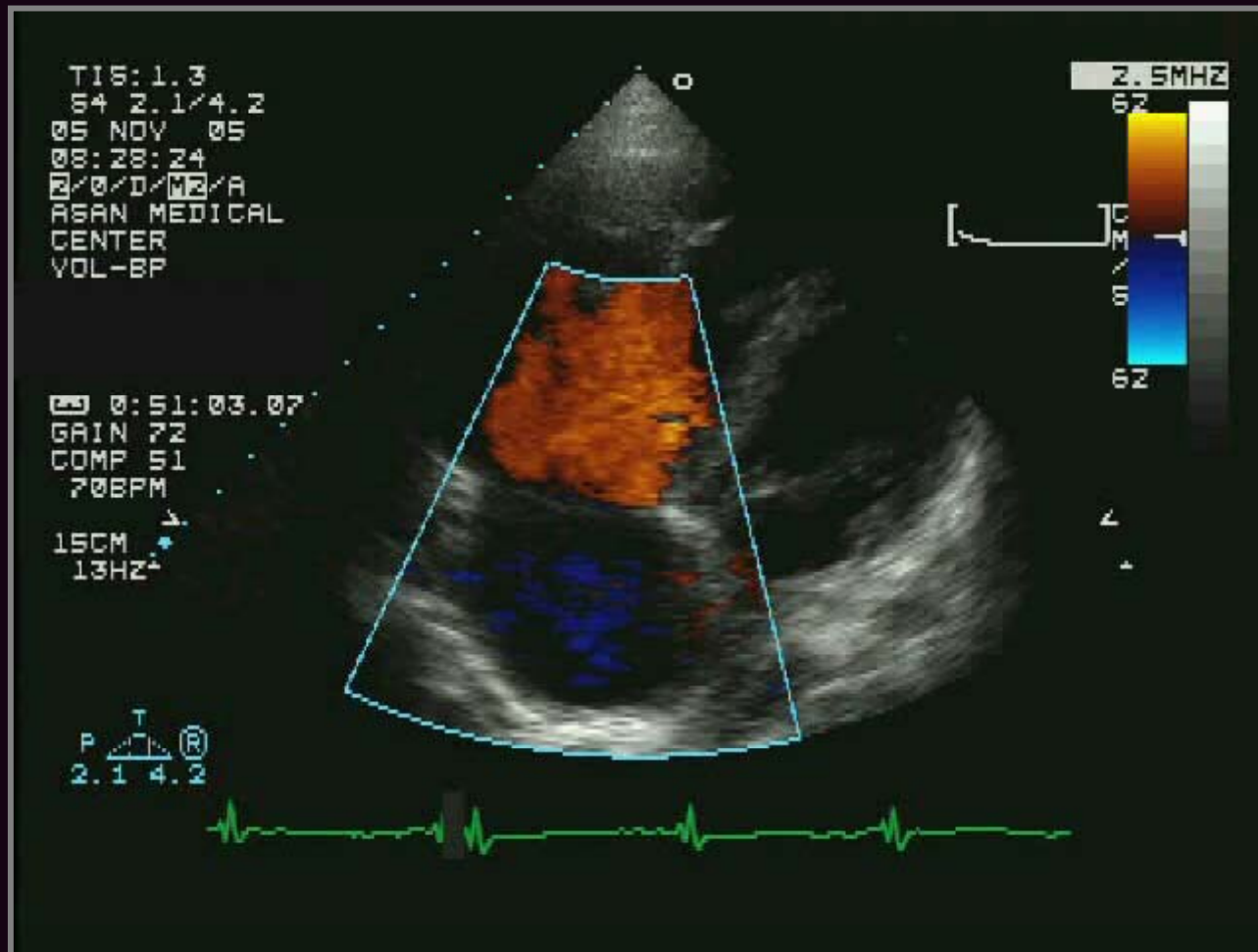
Atrial Septal Defect (28/F)



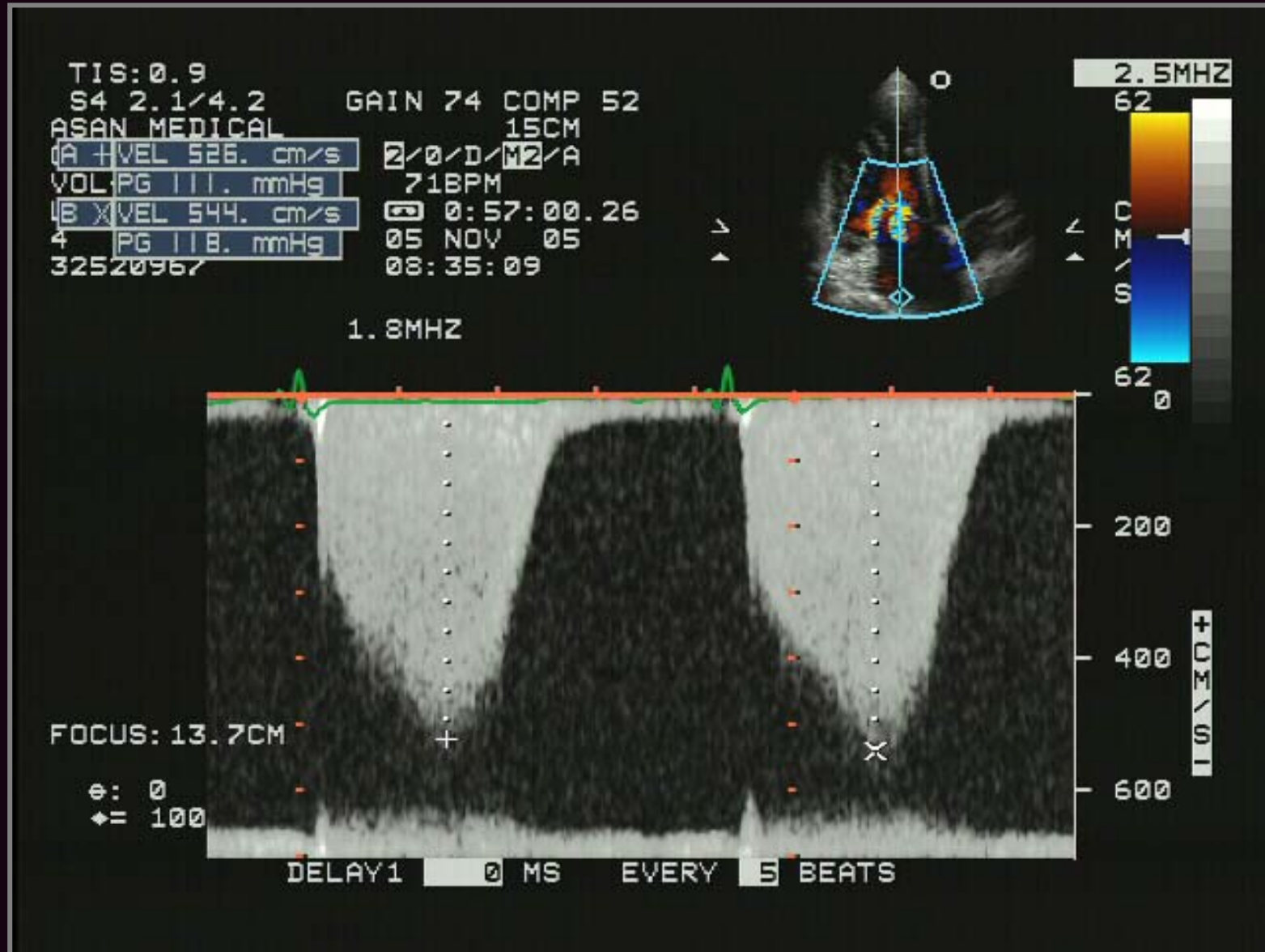
Atrial Septal Defect (28/F)



Atrial Septal Defect (28/F)



Atrial Septal Defect (28/F)



Atrial Septal Defect (28/F)

□ Cardiac catheterization

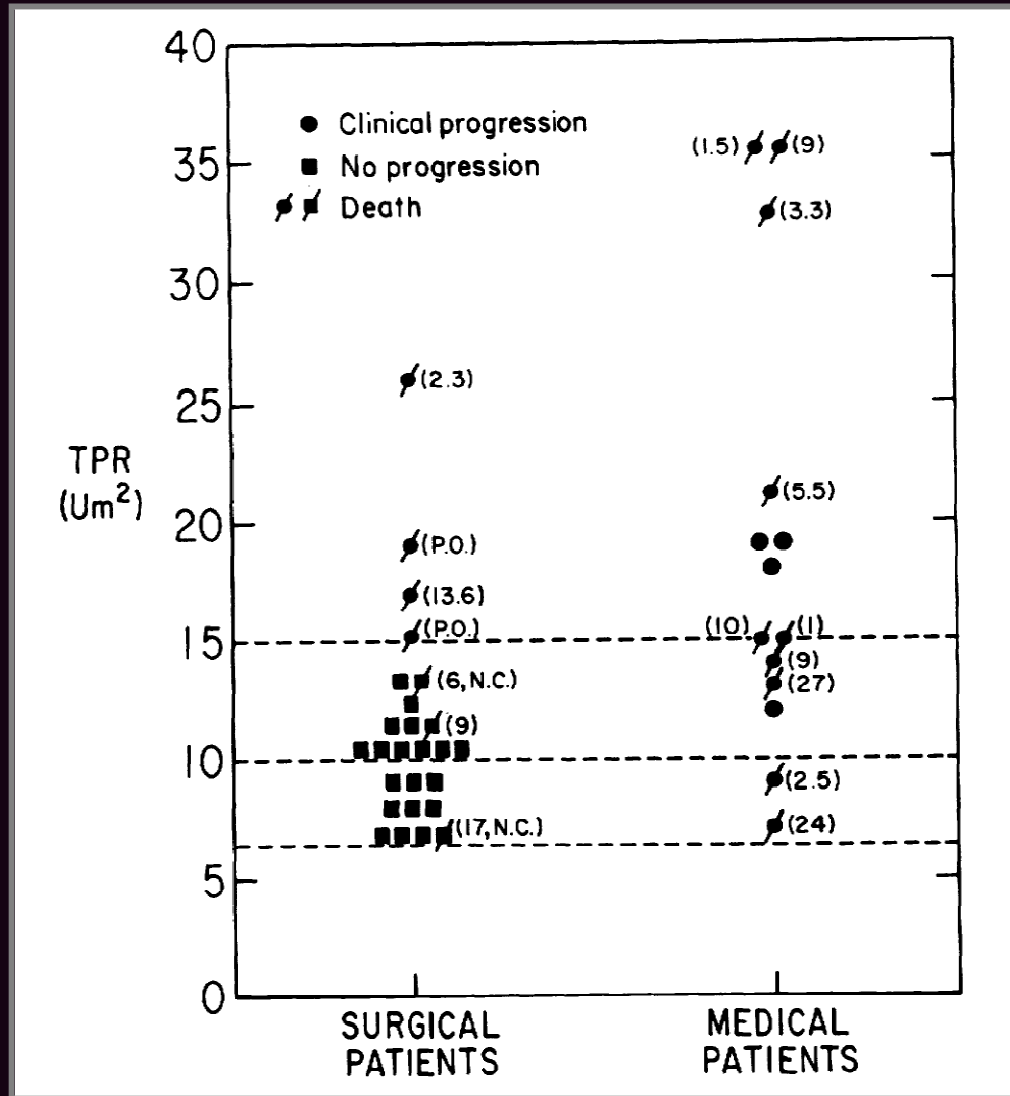
	Pre-O ₂	Post-O ₂
Aorta SaO ₂ (%)	91.5	97.6
Aorta (S/D/M)(mmHg)	114/69/ 87	106/66/ 82
Main PAP (S/D/M)(mmHg)	88/35/ 52	81/35/ 51
Total PVR (UnitxM ²)	16.7	14.0
Pul. arteriolar R (UnitxM ²)	15.1	12.6
SVR (UnitxM ²)	40.9	29.7
Qp/Qs	1.55	1.39
Rp/Rs	0.37	0.43

Atrial Septal Defect (28/F)

□ 환자에게 가장 적절한 치료는?

1. Open heart surgery (patch closure)
2. Device closure
3. Heart lung transplantation
4. Medical management

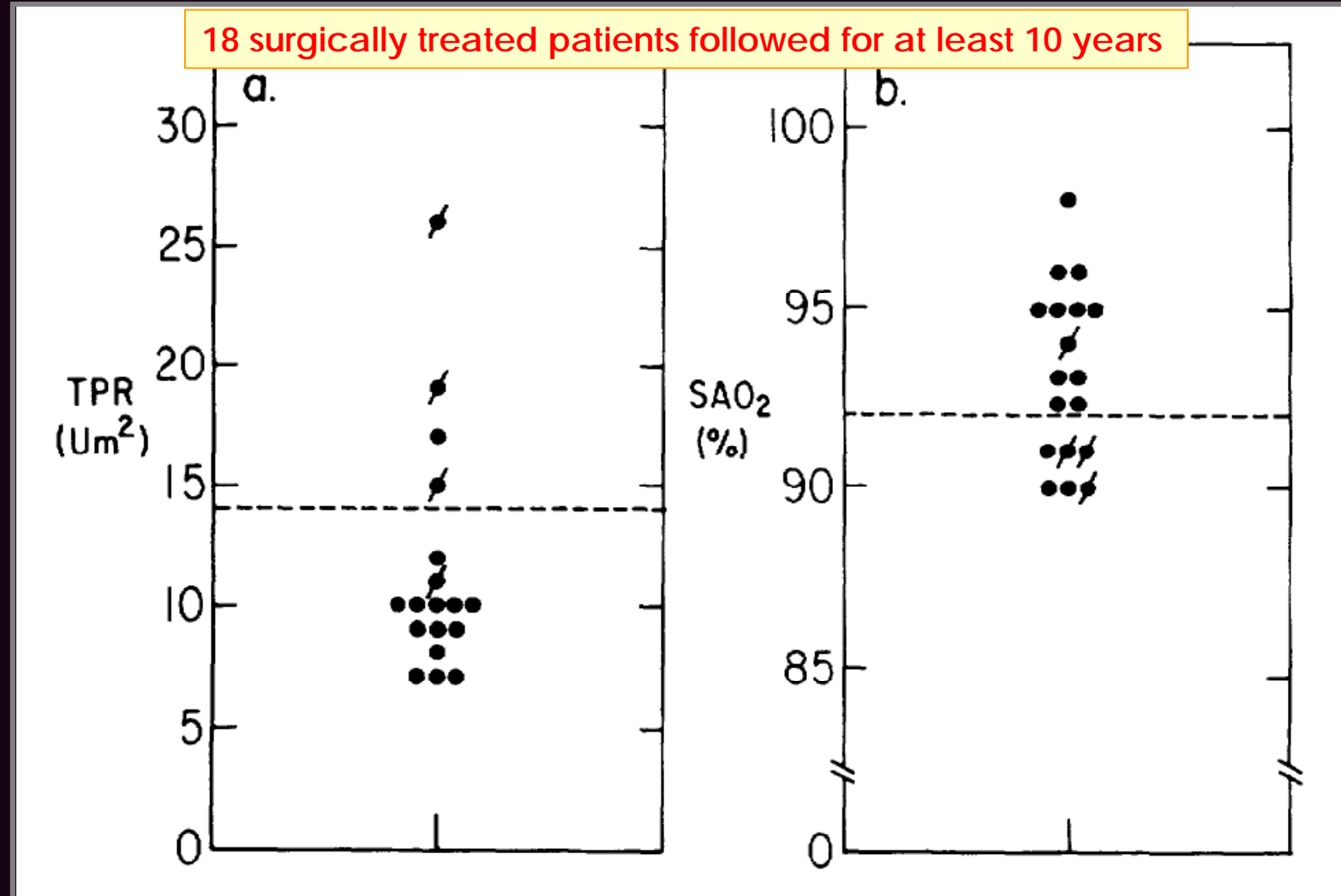
ASD with Severe Pulmonary HT



Circulation 1987;76:1037-1042

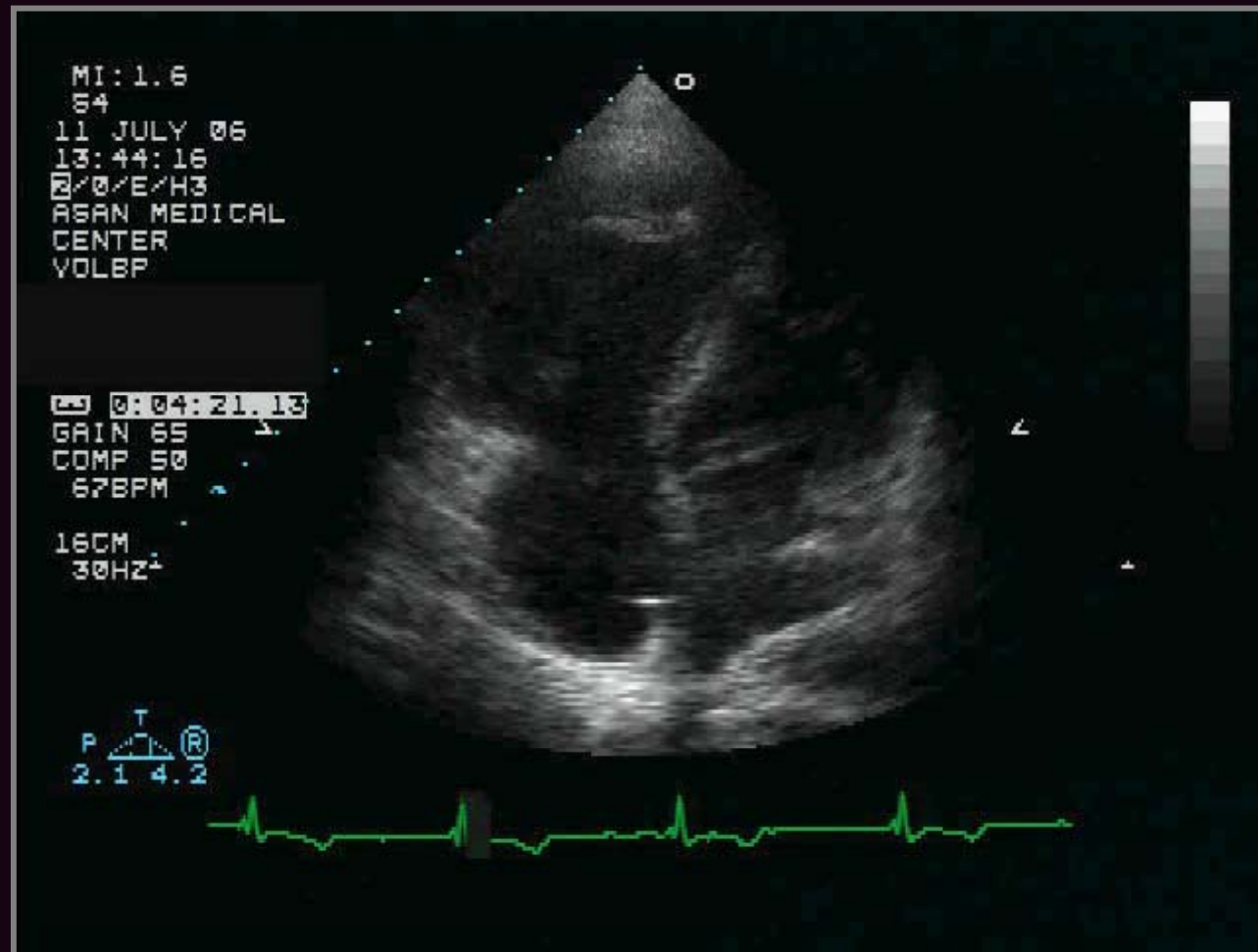
ASD with Severe Pulmonary HT

18 surgically treated patients followed for at least 10 years



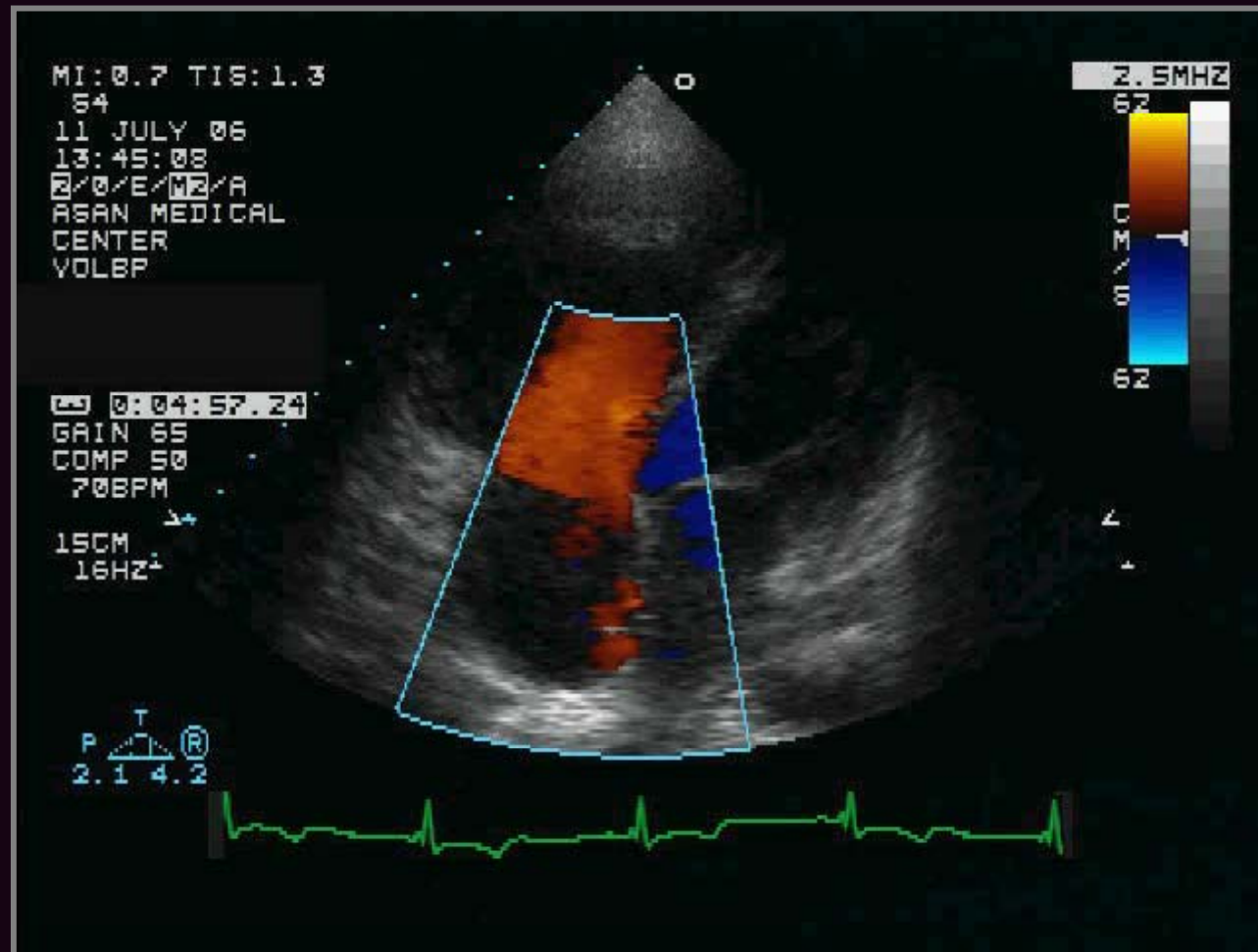
Circulation 1987;76:1037-1042

Atrial Septal Defect (28/F)



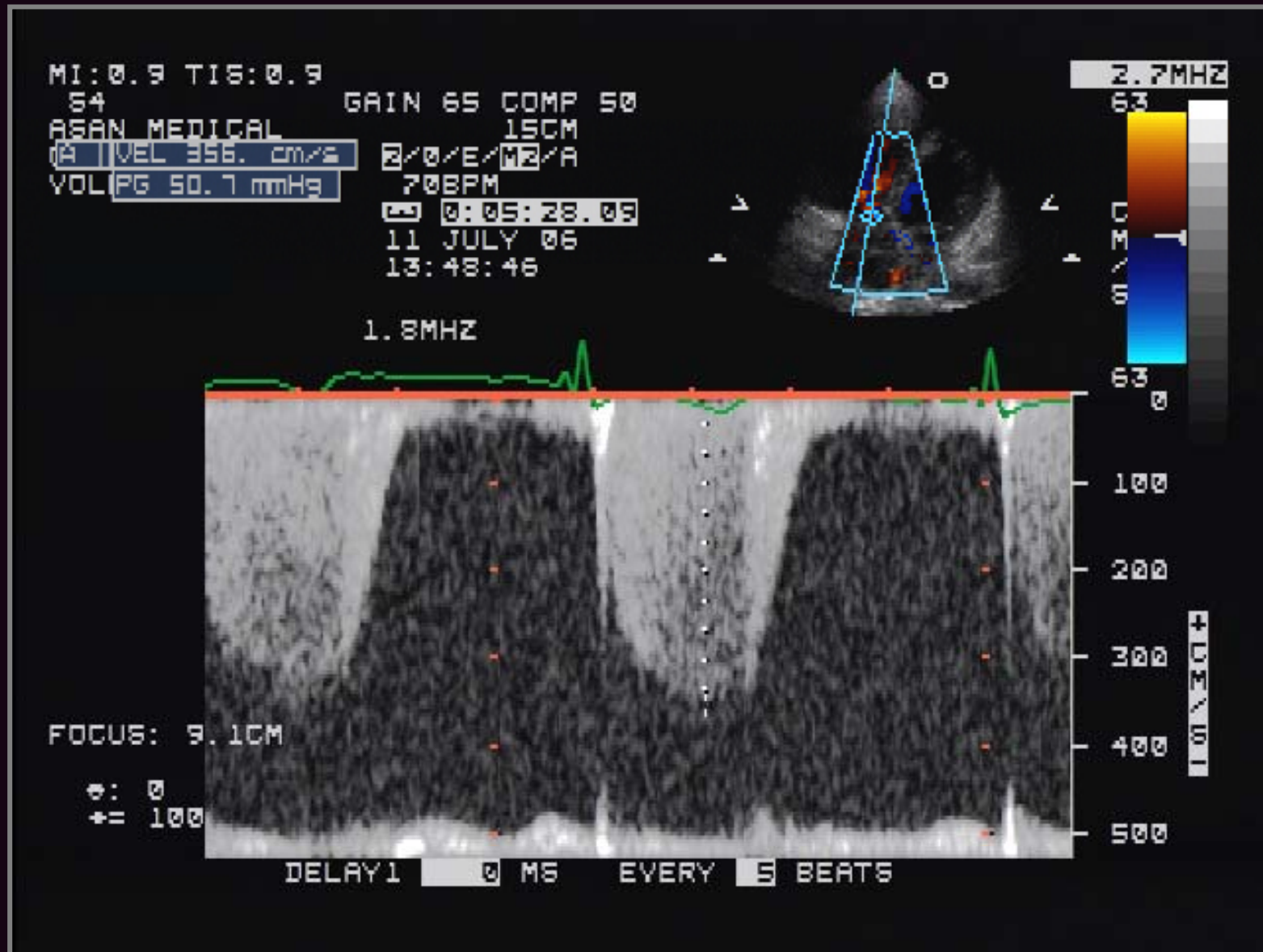
8 months after surgery

Atrial Septal Defect (28/F)



8 months after surgery

Atrial Septal Defect (28/F)



Adult Ventricular Septal Defect

□ **Small VSD** ($Q_p/Q_s < 1.5$)

- risk of Eisenmenger syndrome : negligible
- Observation

□ **Large VSD**

- Most adult patients show Eisenmenger syndrome
- $R_p/R_s > 0.7$: inoperable

Ventricular Septal Defect (61/M)

- C.C : cough & dyspnea
- PMHx :
 - 12세 때 VSD 진단 받음
 - 35세 때 pulmonary Tbc, pleurisy 로 medication (1.5 yrs)
 - 40세 때 pulmonary Tbc 로 medication (1.5 yrs)
 - 2001.10 pseudomonas pneumonia 로 치료
 - 최근 dyspnea & cough 심해져서 타 병원 방문
 - VSD with Eisenmenger syndrome 진단
 - VSD 에 대한 further work-up 위해 내원

Ventricular Septal Defect (61/M)

- Initial lab findings

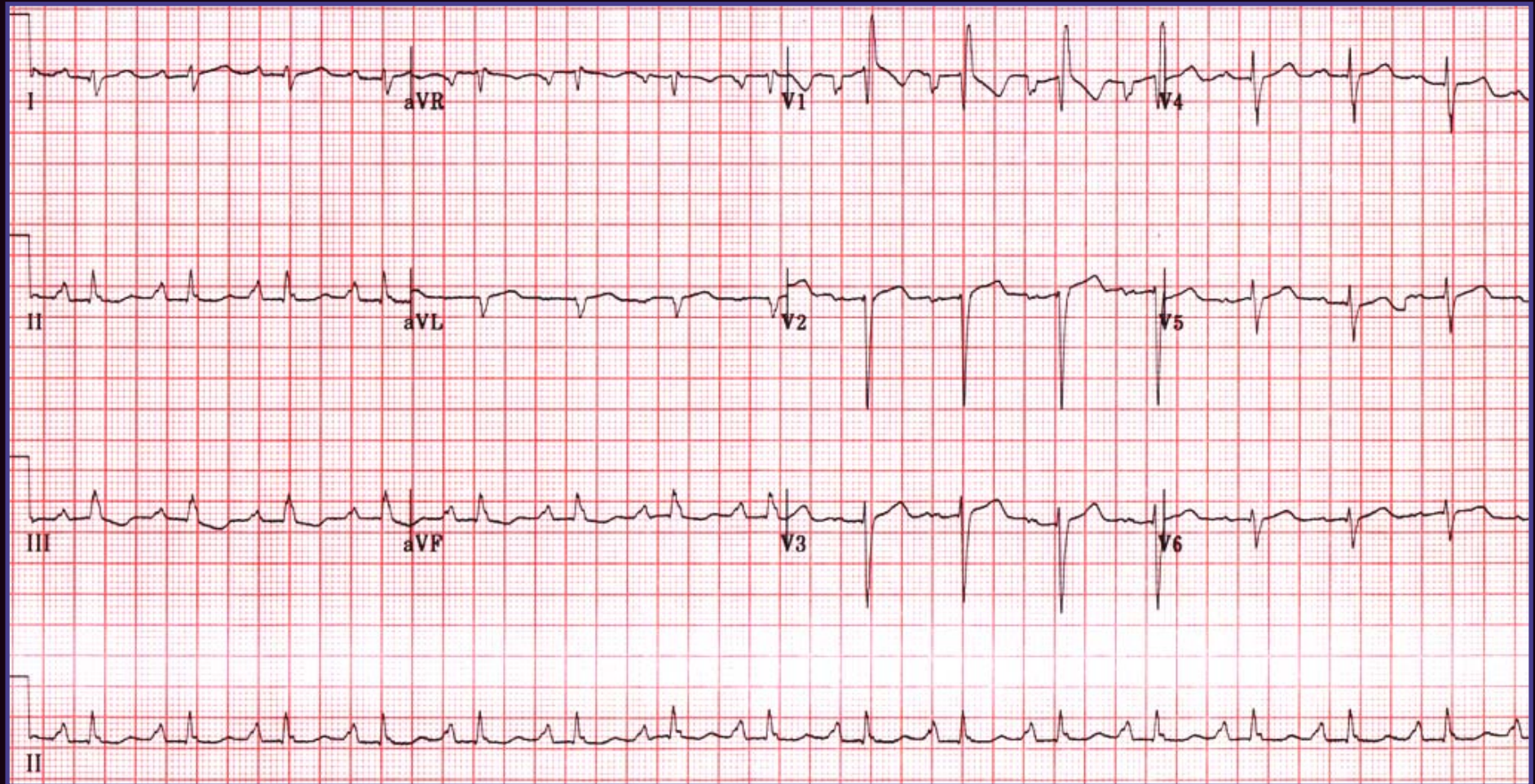
- Hb : 13.1 g/dl
- WBC : 11,600/mm³
- Platelet : 290K/mm³

- ESR : 85 mm/hr CRP : 21.68 mg/dl

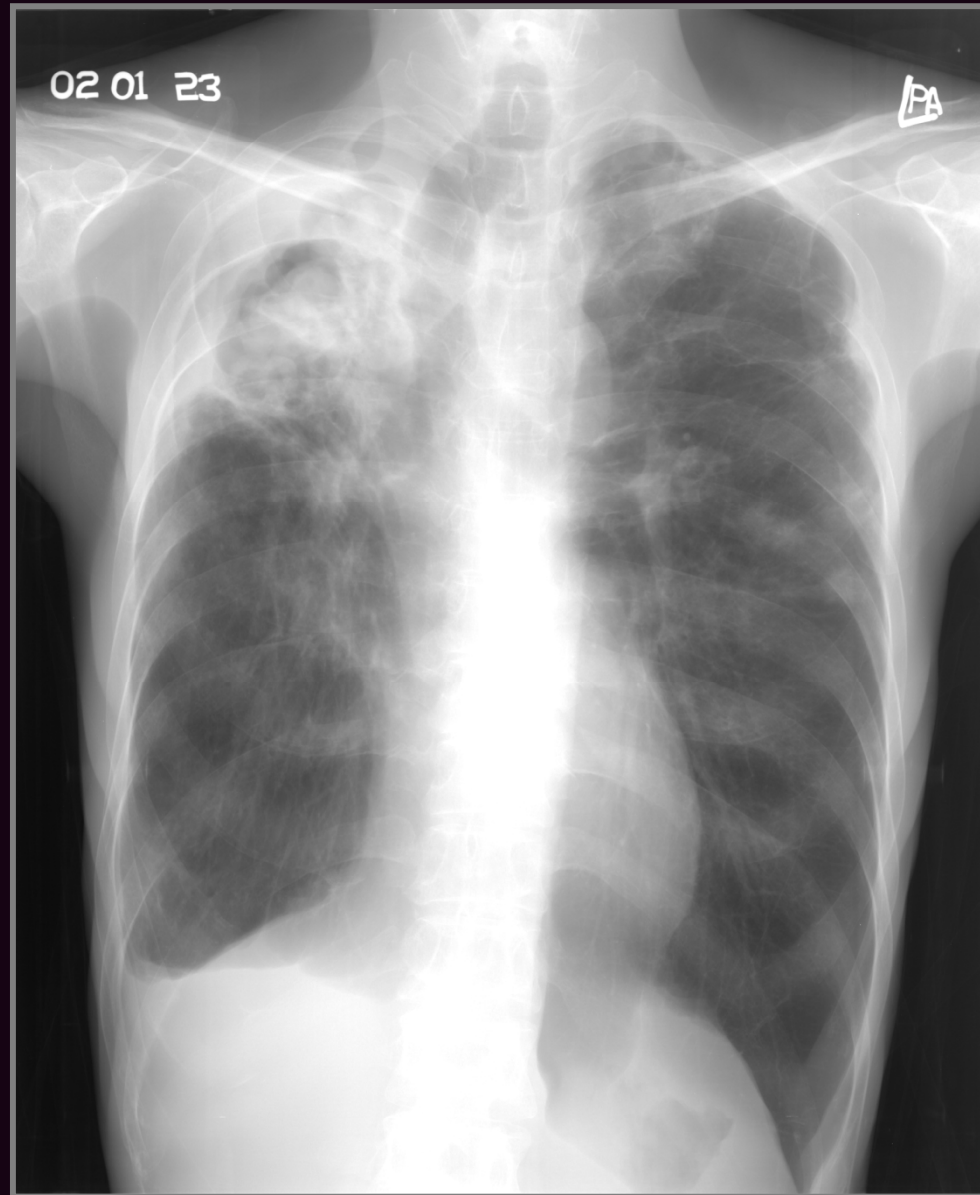- T.prot / alb : 8.1 / 2.4 g/dl
- BUN / Cr : 13 / 1.0 mg/dl

- Electrolytes : 130-4.3-93-24.4 eEq/l
- ABGA : 7.50-31.8-47.6-24.9 (SaO₂ : 87%)

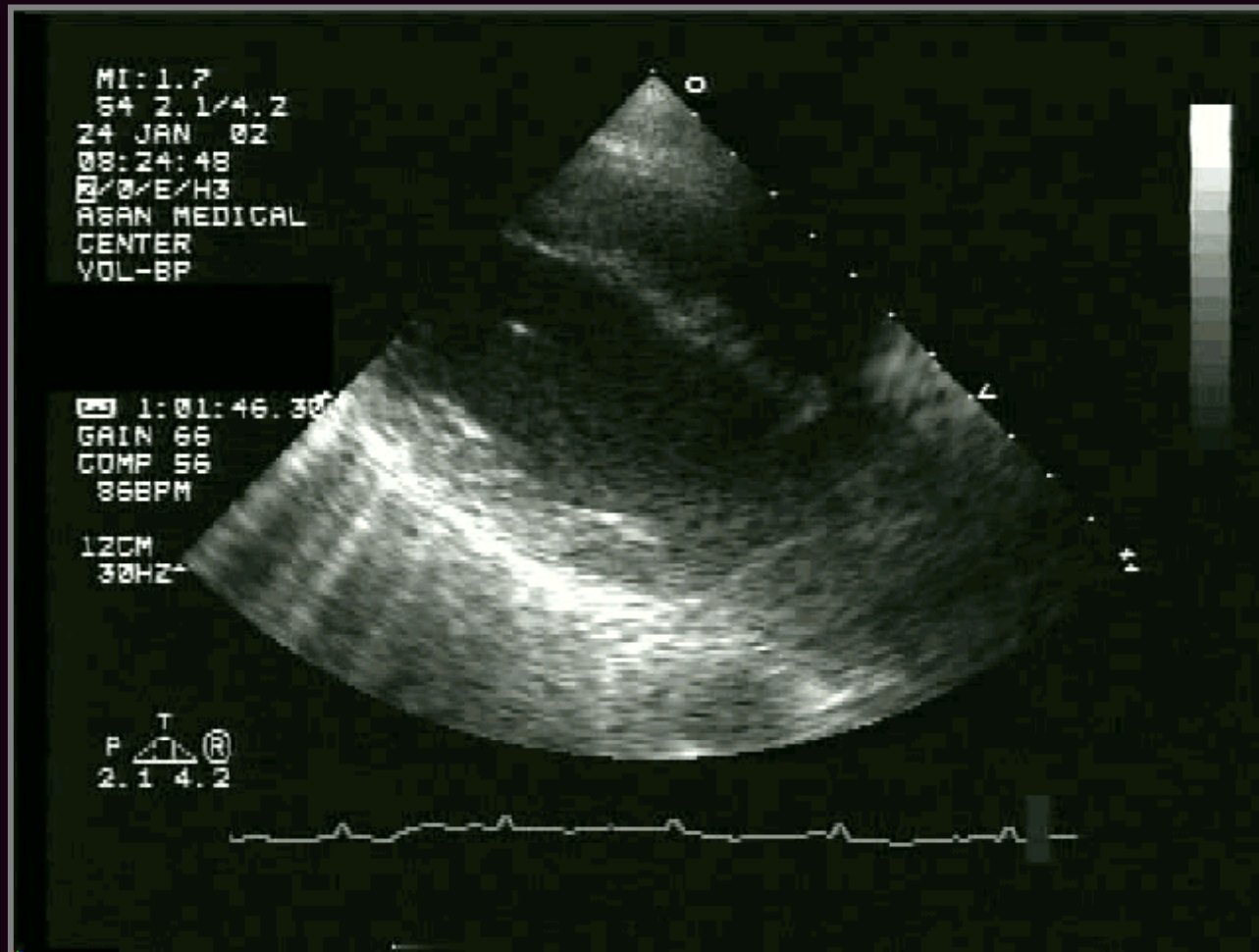
Ventricular Septal Defect (61/M)



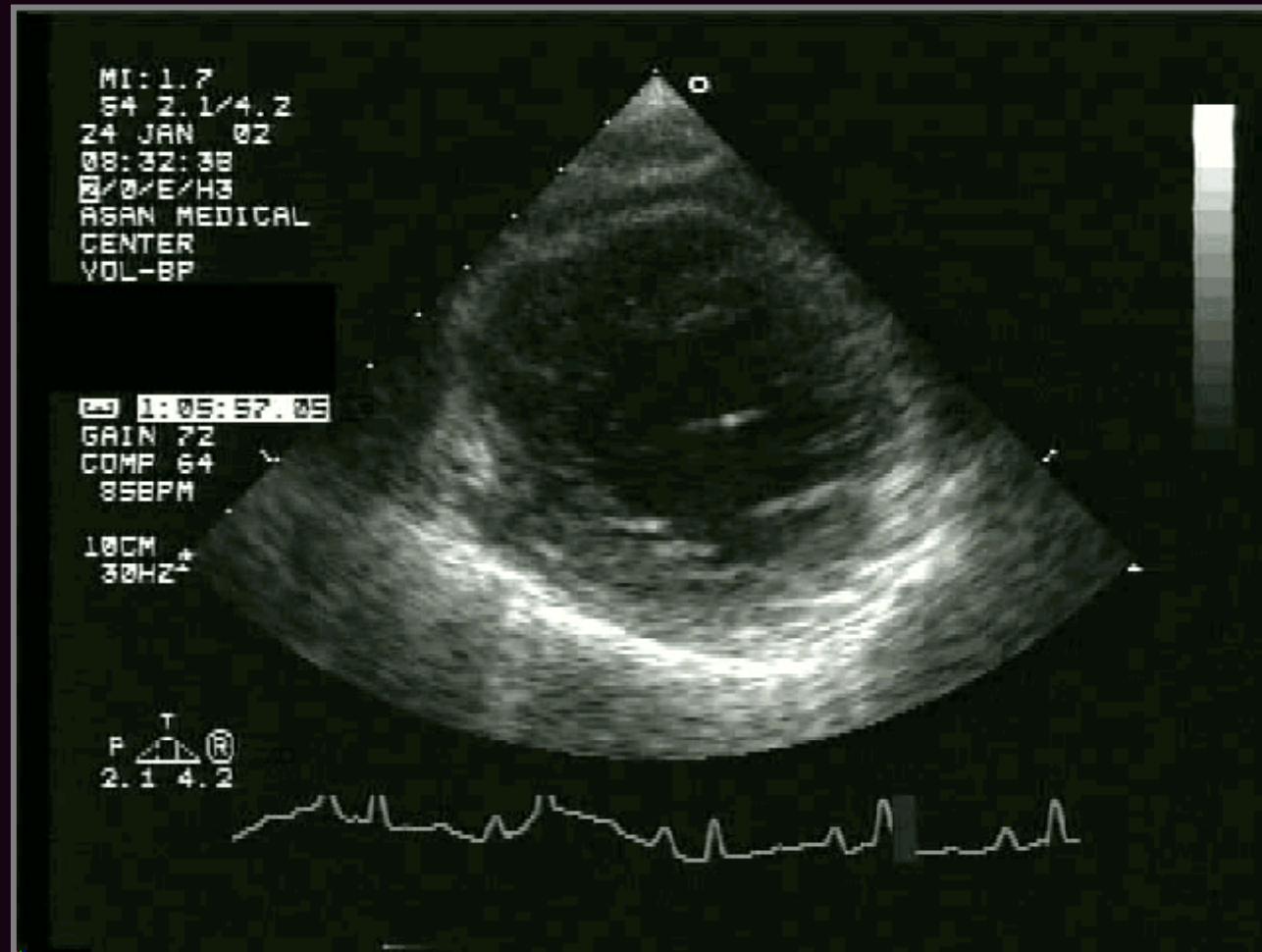
Ventricular Septal Defect (61/M)



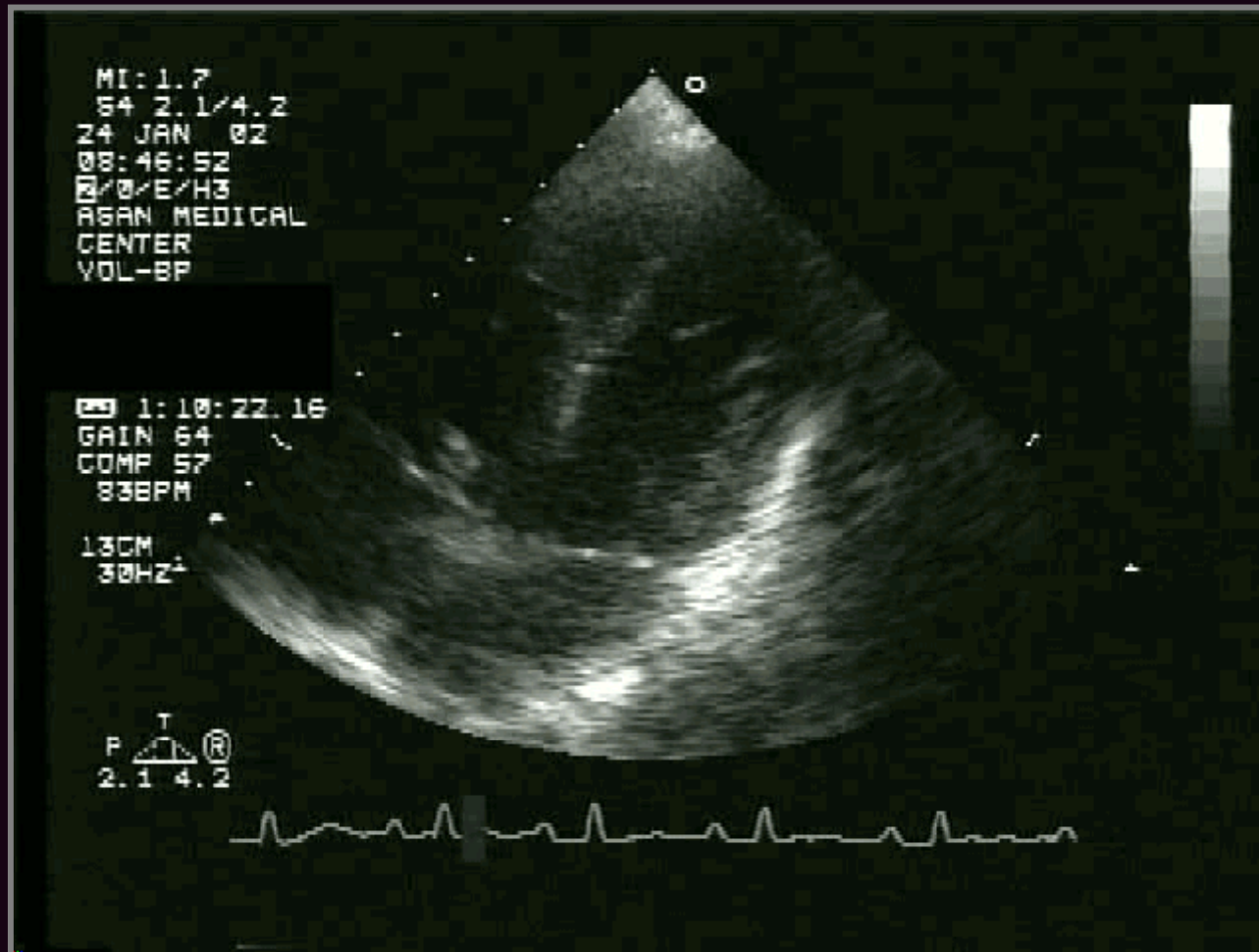
Ventricular Septal Defect (61/M)



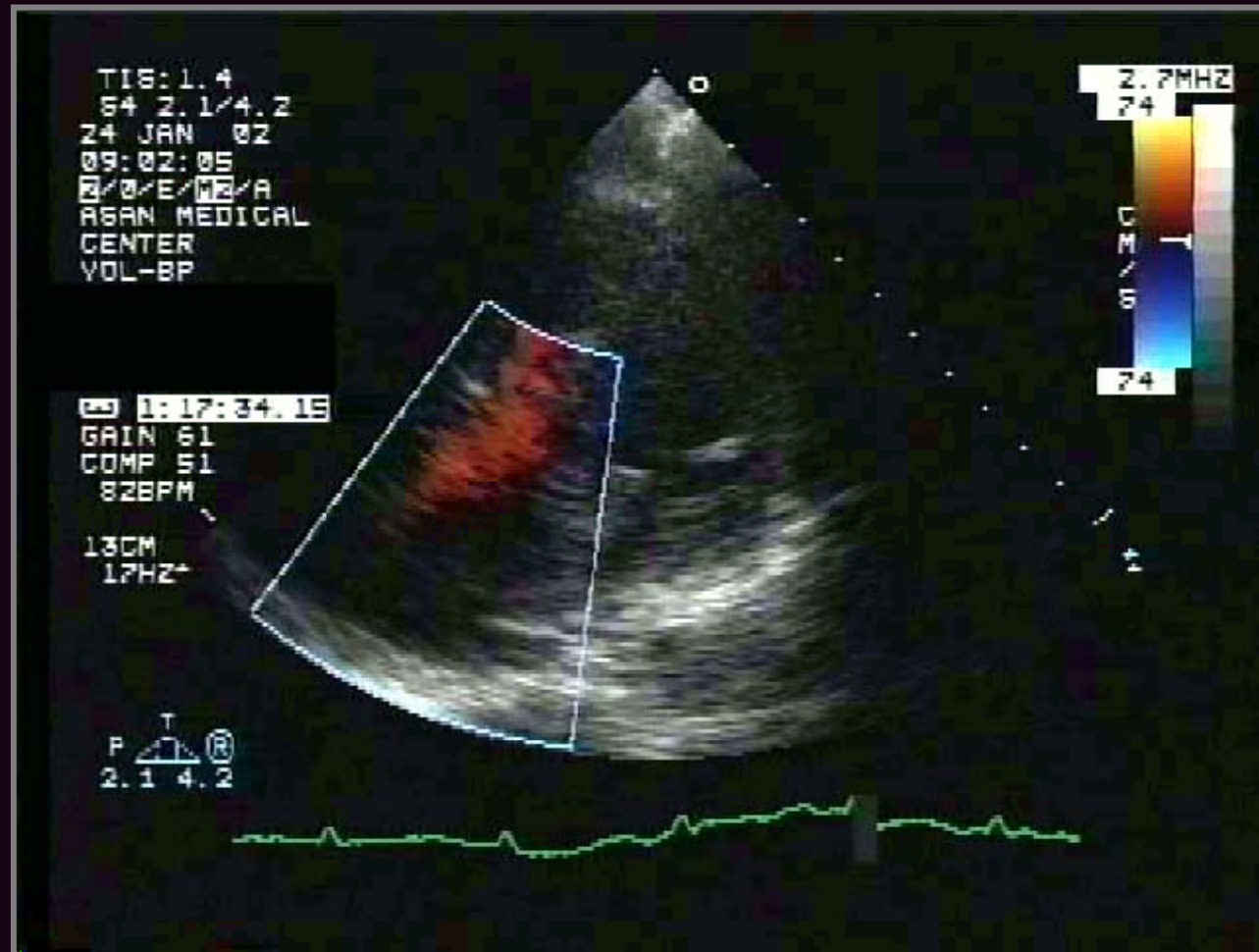
Ventricular Septal Defect (61/M)



Ventricular Septal Defect (61/M)



Ventricular Septal Defect (61/M)

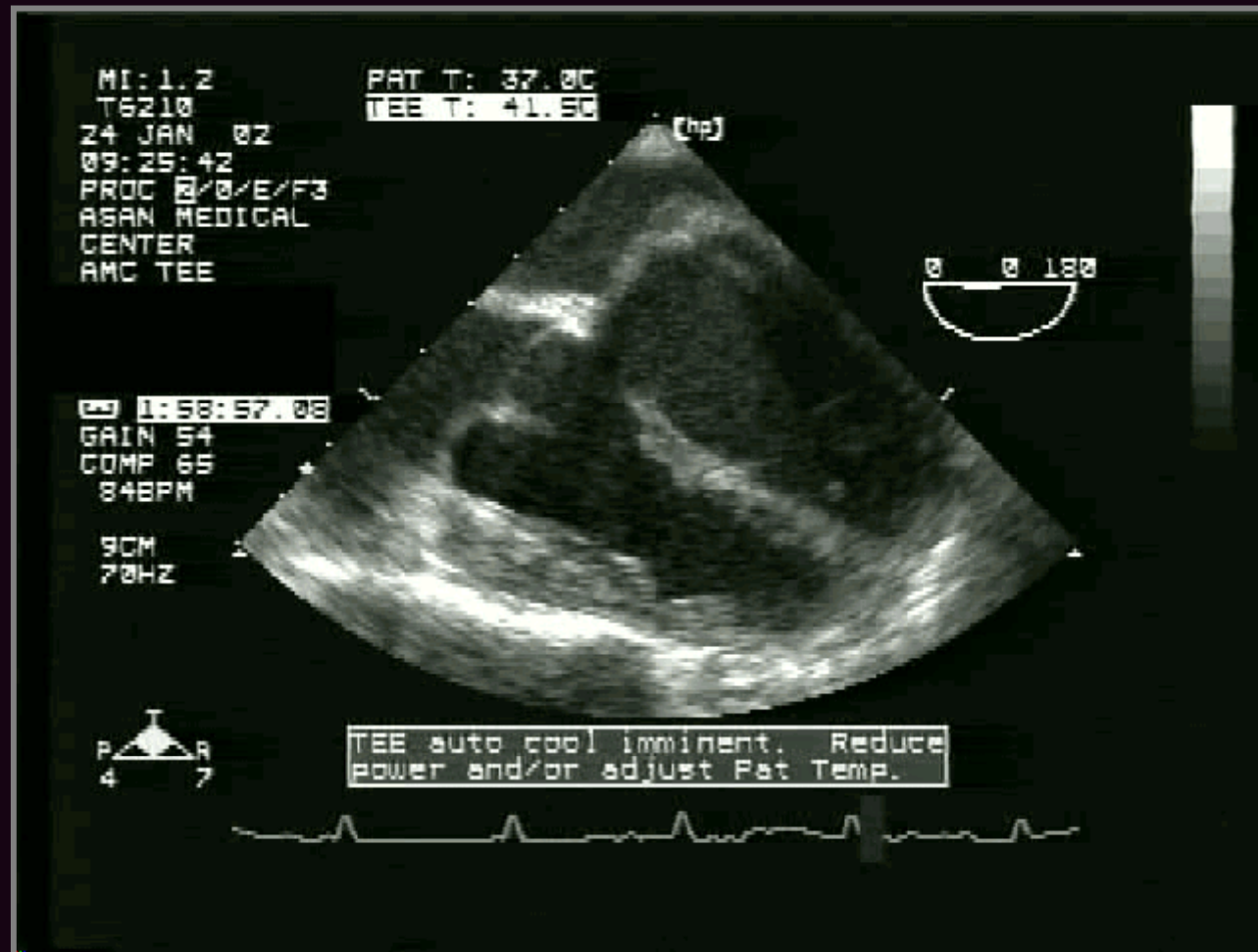


Ventricular Septal Defect (61/M)

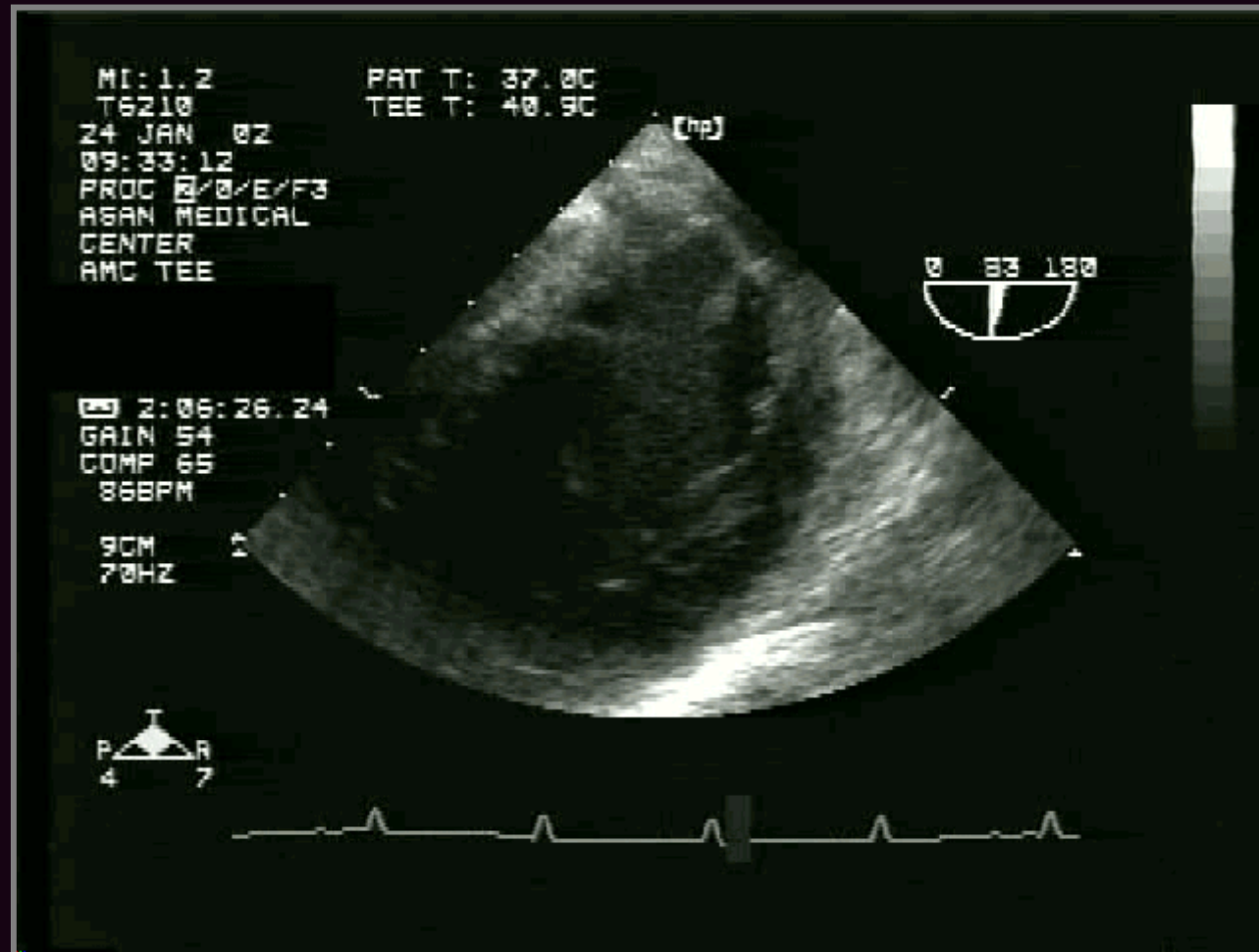
□ 다음으로 해야 할 검사 및 조치는?

1. Supportive management
2. Transesophageal echocardiography
3. Cardiac catheterization and coronary angiography
4. VSD patch closure
5. Heart-lung transplantation

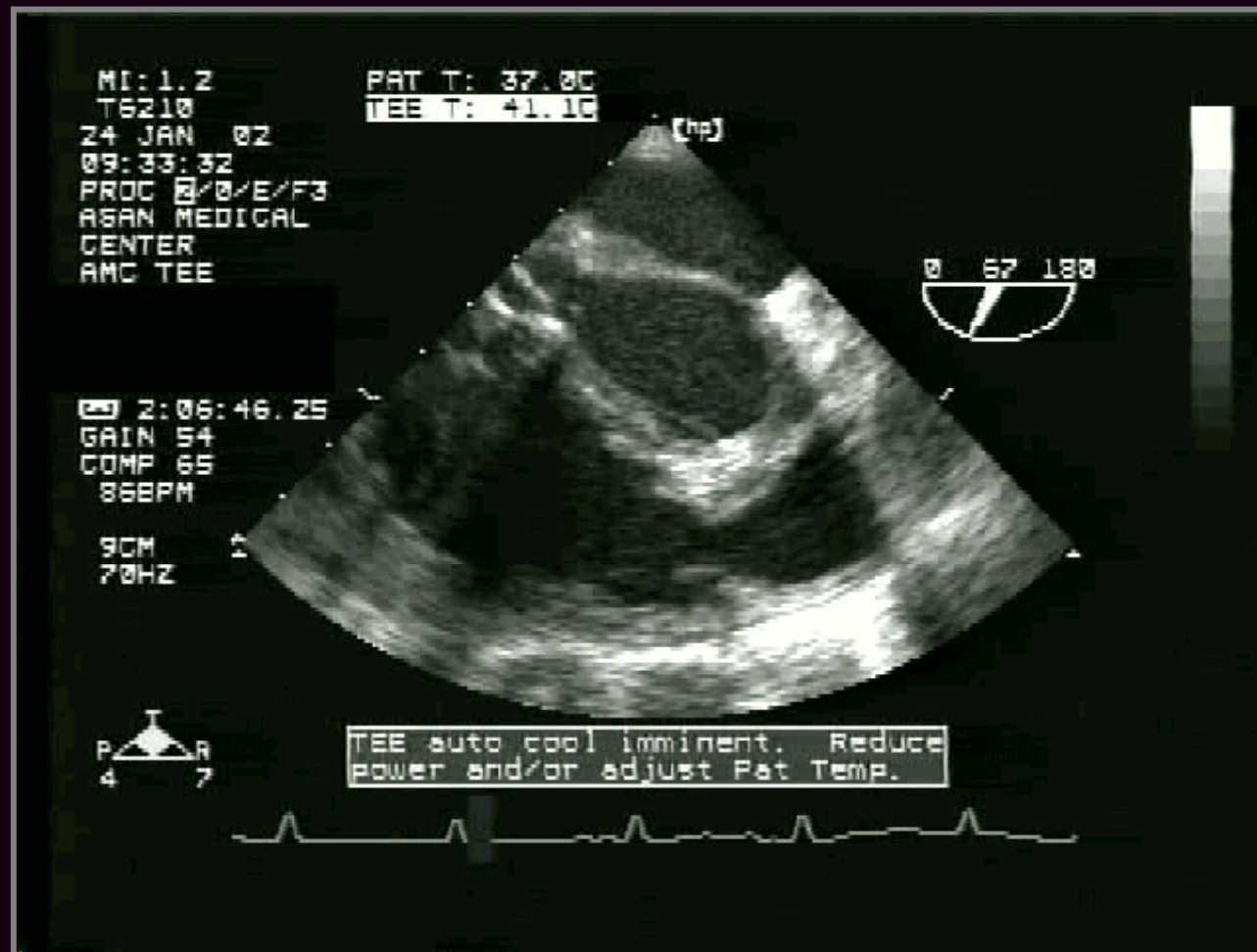
Ventricular Septal Defect (61/M)



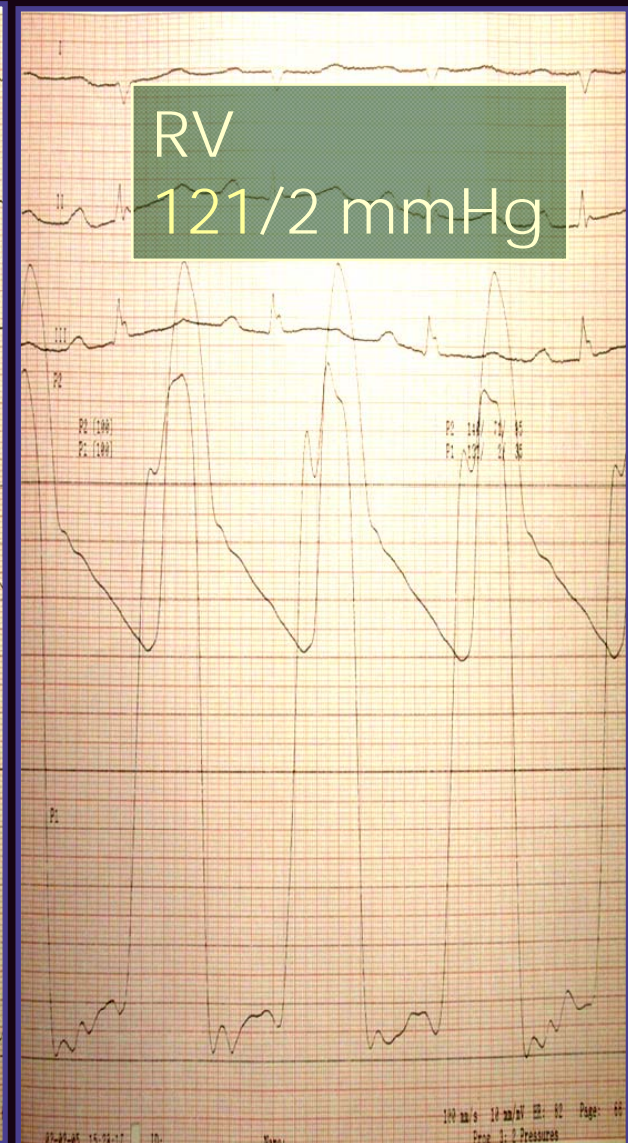
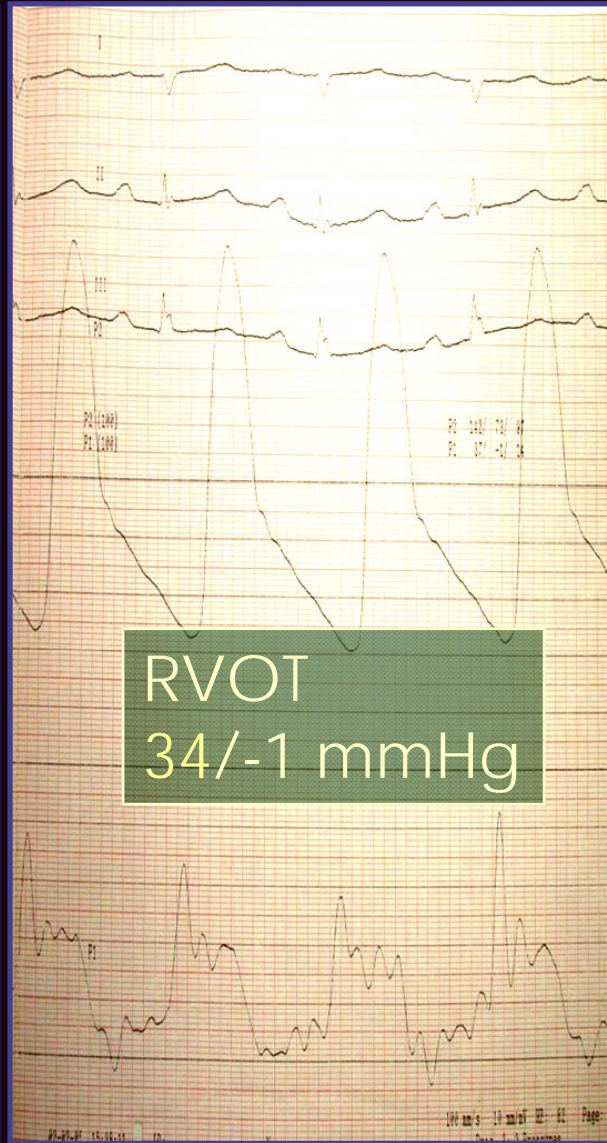
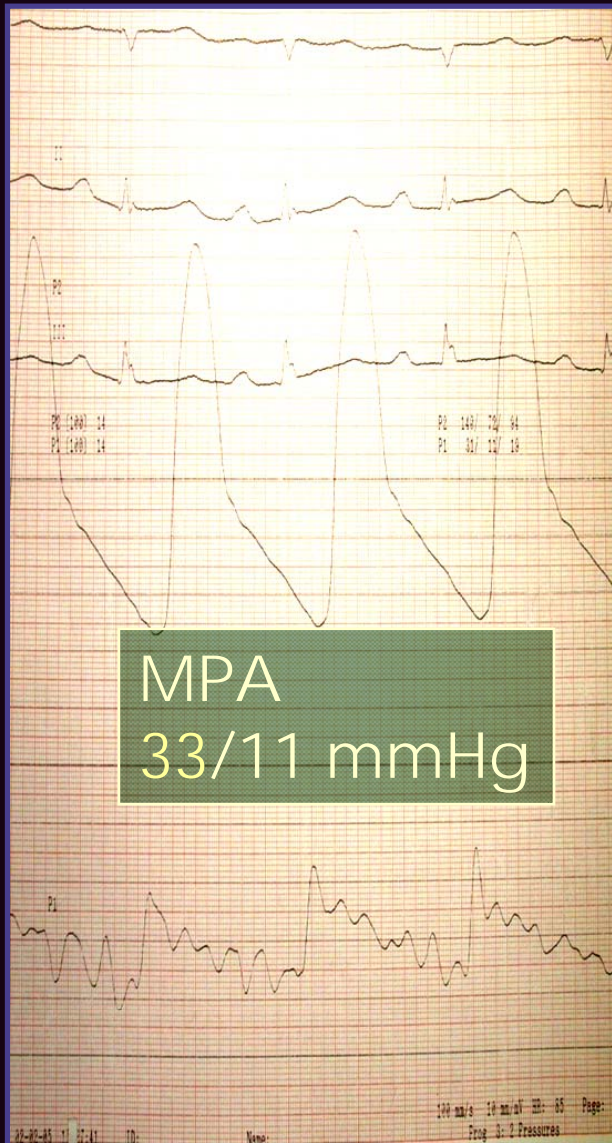
Ventricular Septal Defect (61/M)



Ventricular Septal Defect (61/M)



Ventricular Septal Defect (61/M)

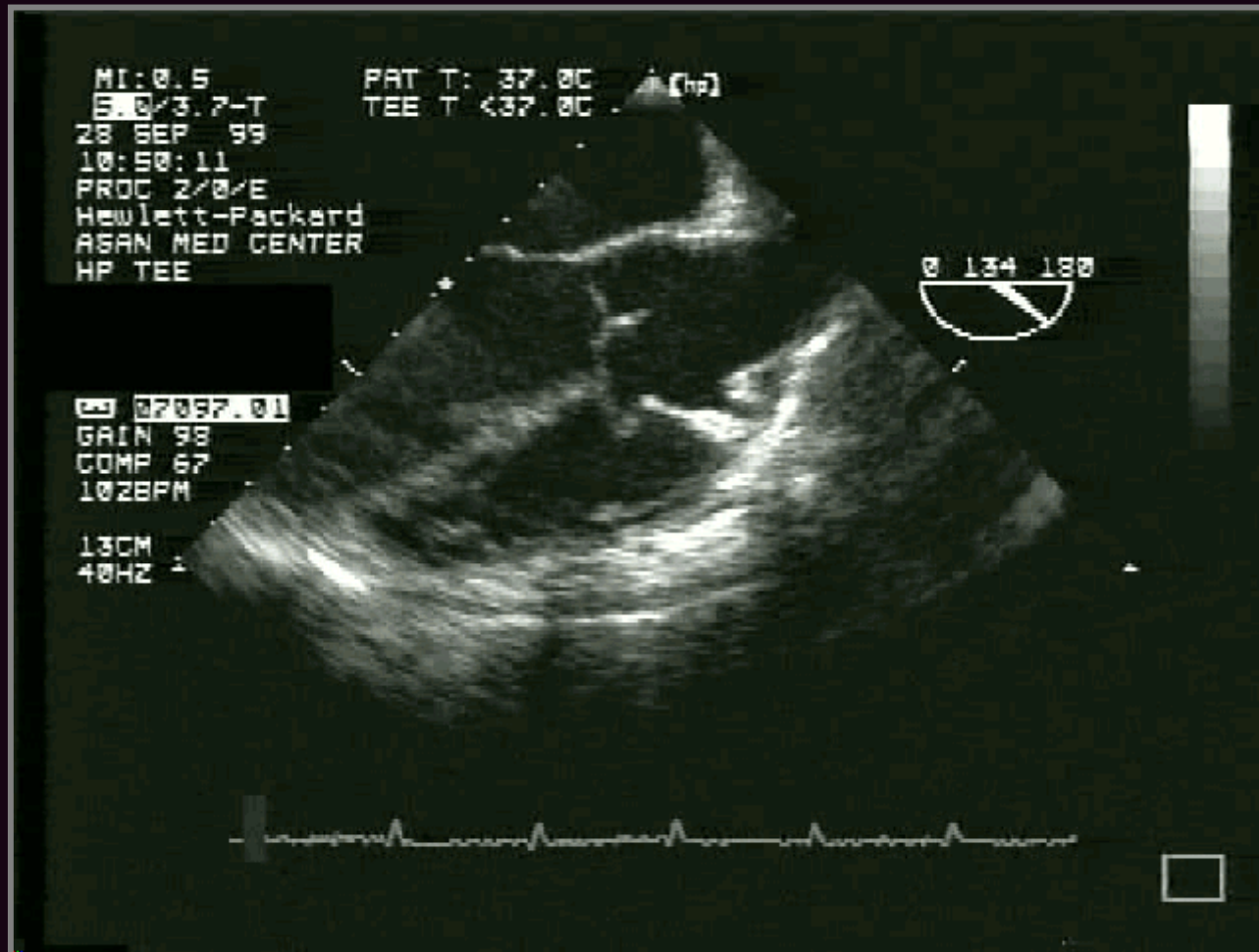


VSD with high TR Velocity

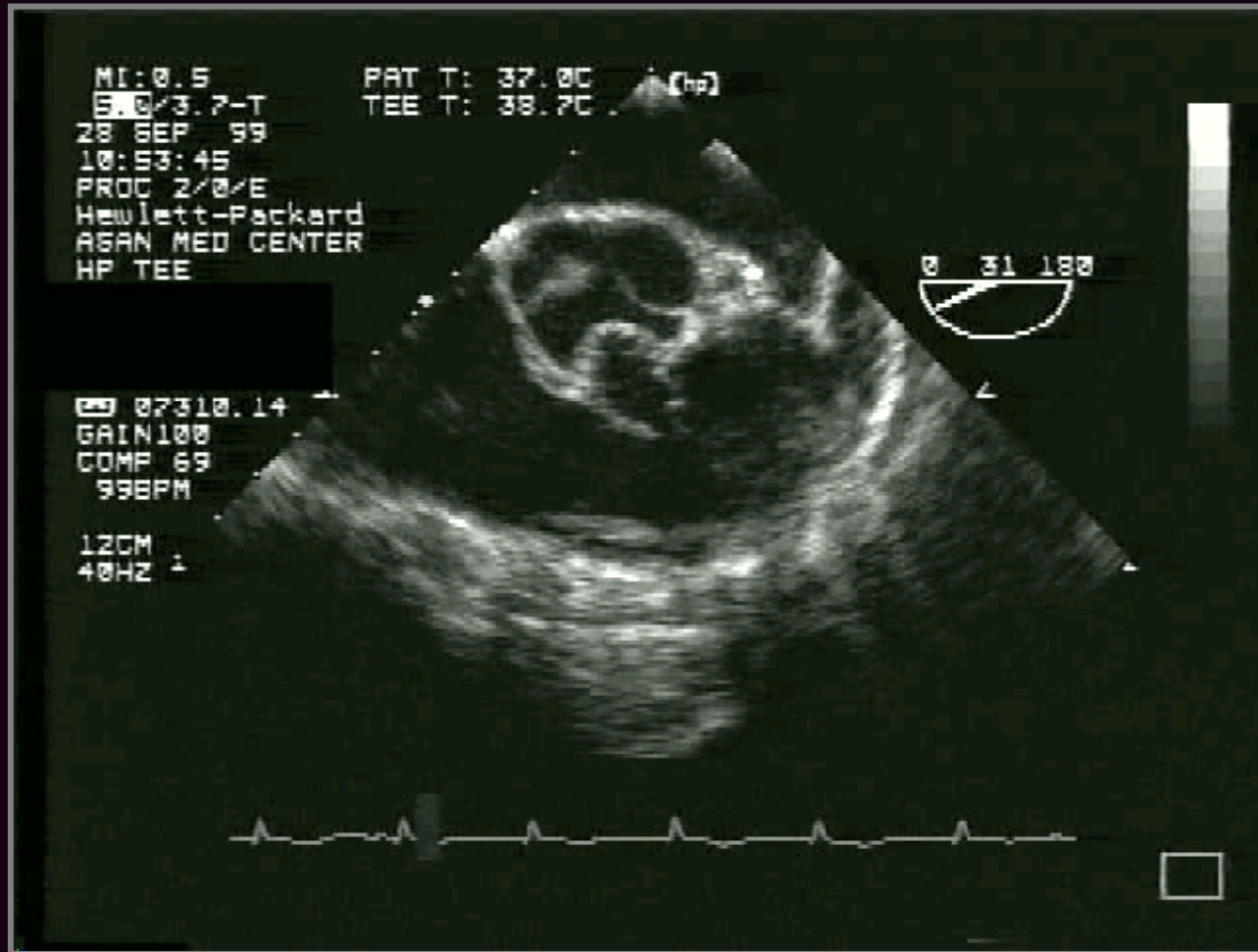
□ Differential diagnosis

- Eisenmenger syndrome
- Valvular or infundibular PS (5-10%)
- Double chamber right ventricle (DCRV)
- Pulmonary artery stenosis

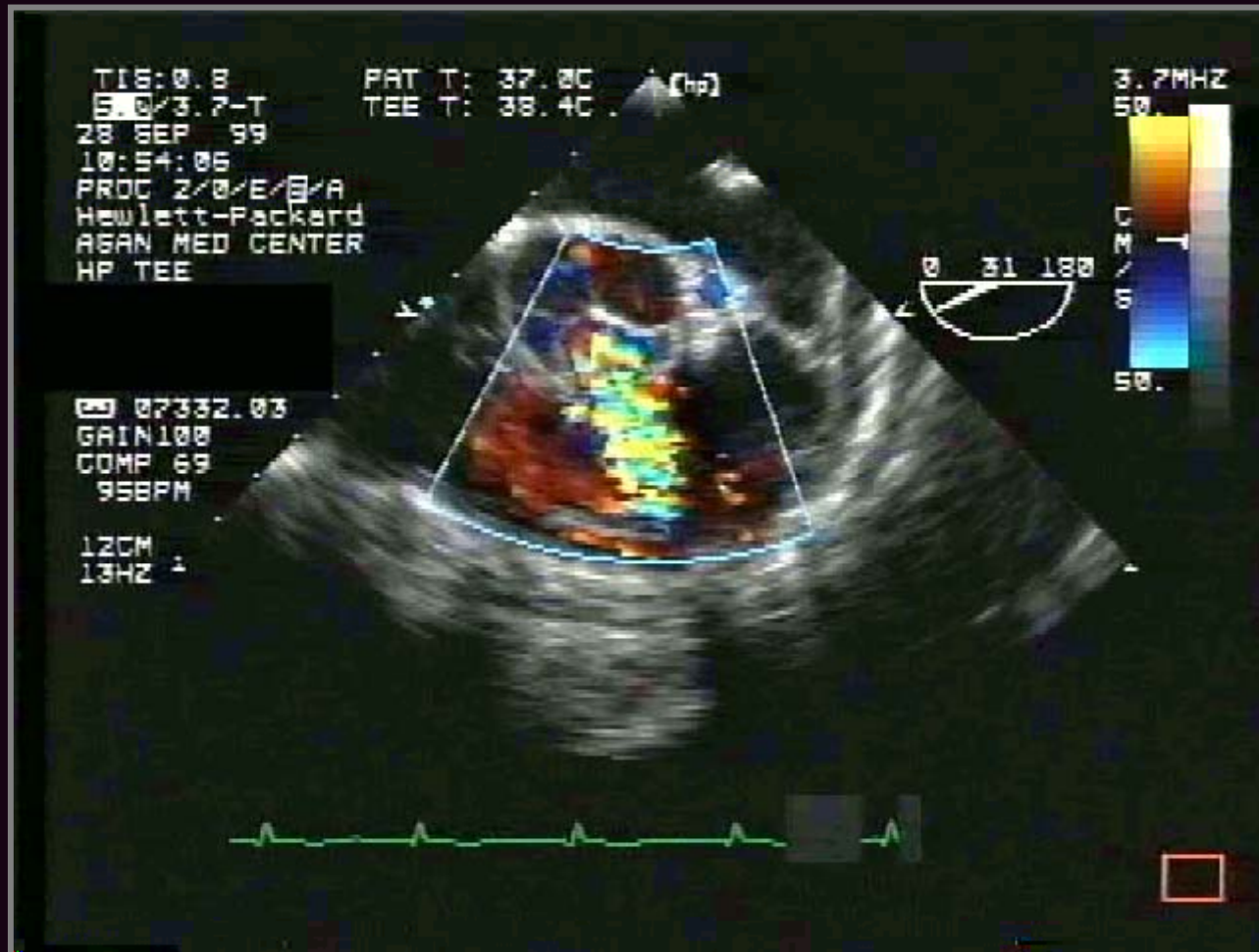
Sinus Valsalva Rupture (24/F)



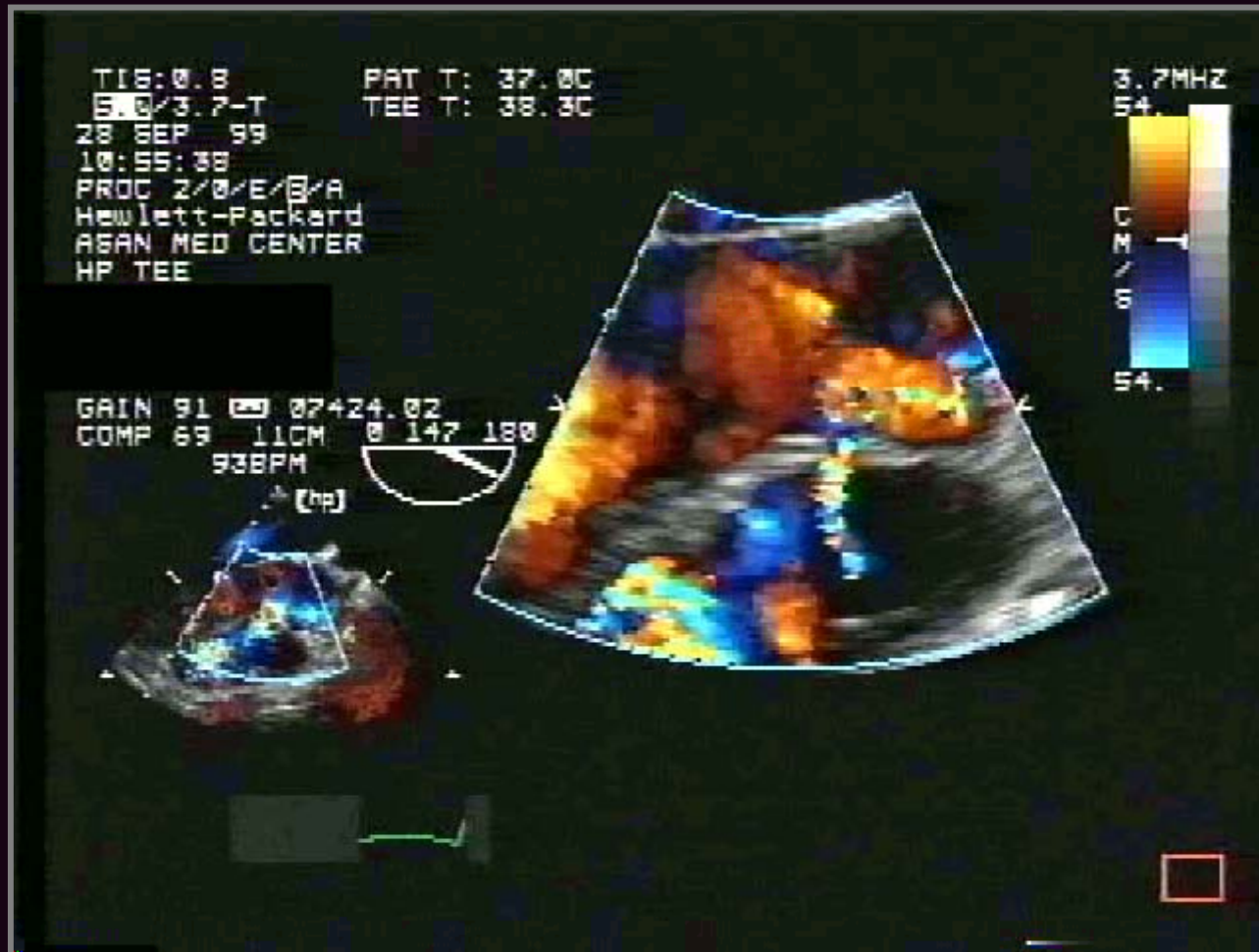
Sinus Valsalva Rupture (24/F)



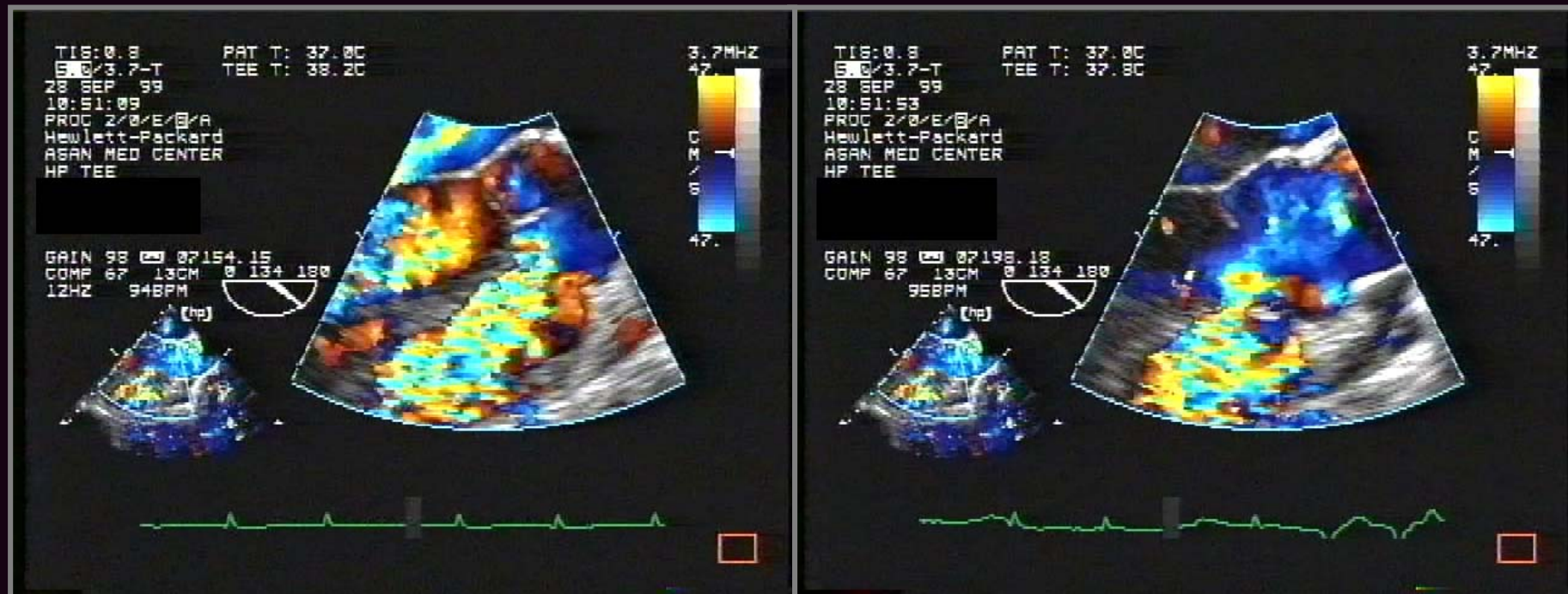
Sinus Valsalva Rupture (24/F)



Sinus Valsalva Rupture (24/F)



Sinus Valsalva Rupture (24/F)



Sinus Valsalva Aneurysm & VSD

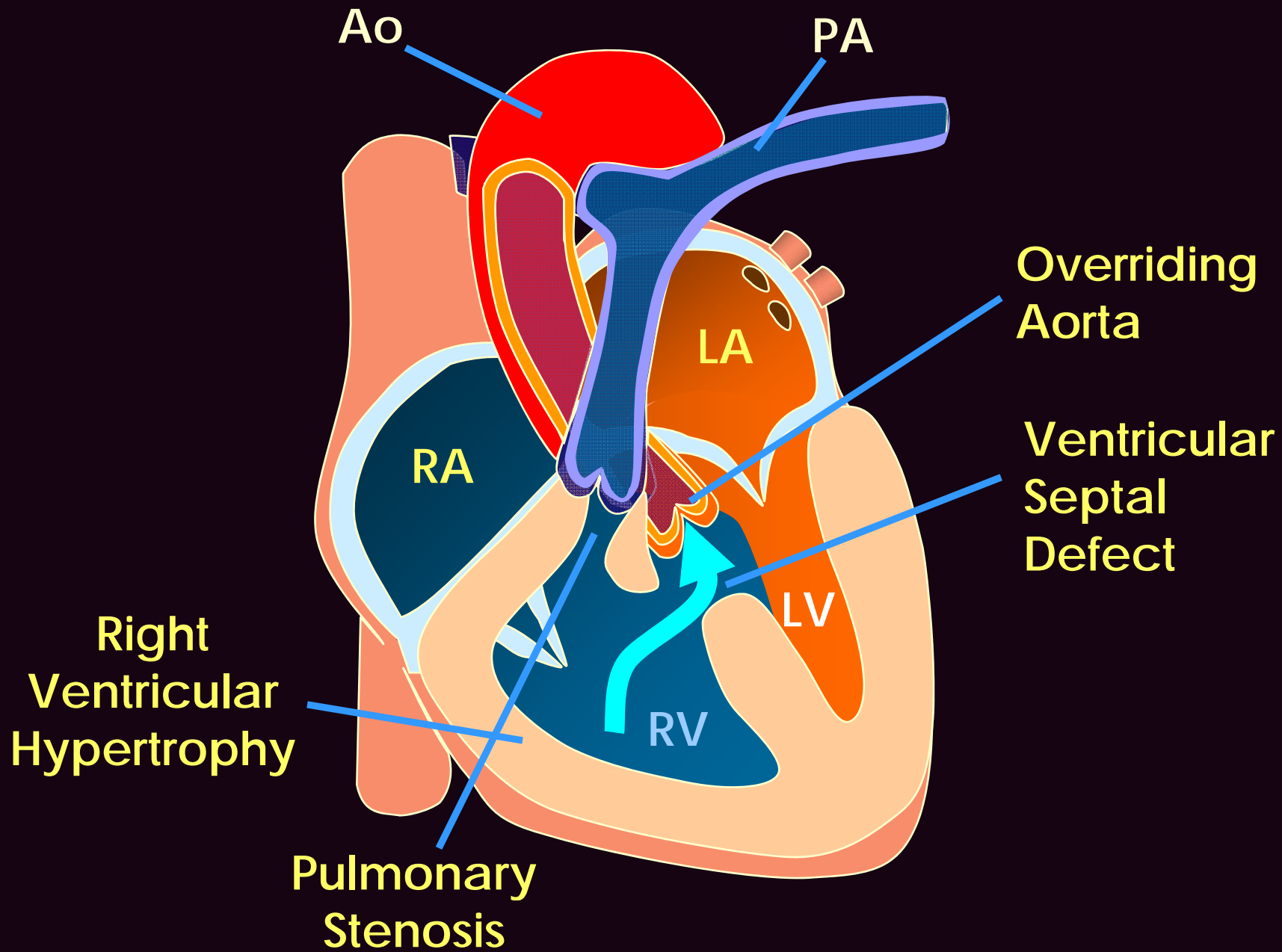
<i>Study</i>	<i>RCC</i>		<i>NCC</i>		<i>LCC</i>
	<i>+VSD</i>	<i>-VSD</i>	<i>+VSD</i>	<i>-VSD</i>	
This study	15	17	1	2	1
Sakakibara* ⁶	20	21	1	11	0
Kirklin ⁸	15	5	2	7	0
Dev† ¹¹		28		2	0
Chen ¹²	10	6	0	0	0
Burgkovsky ¹³	12	11	0	4	0
Lukacs ¹	3	6	0	6	0
Terdjman ¹⁴	0	3	0	1	0
Chiang ⁴	5	3	0	2	1
Vargas-Barron ¹⁵	0	2	0	1	0
Boutefeu* ²	49	73	0	21	5
Sakiyalak ³	9	15	0	3	0
Sahasakul ¹⁶	2	4	0	1	0
Total‡	140	166	4	61	6

LCC, Left coronary cusp; *NCC*, noncoronary cusp; *RCC*, right coronary cusp.

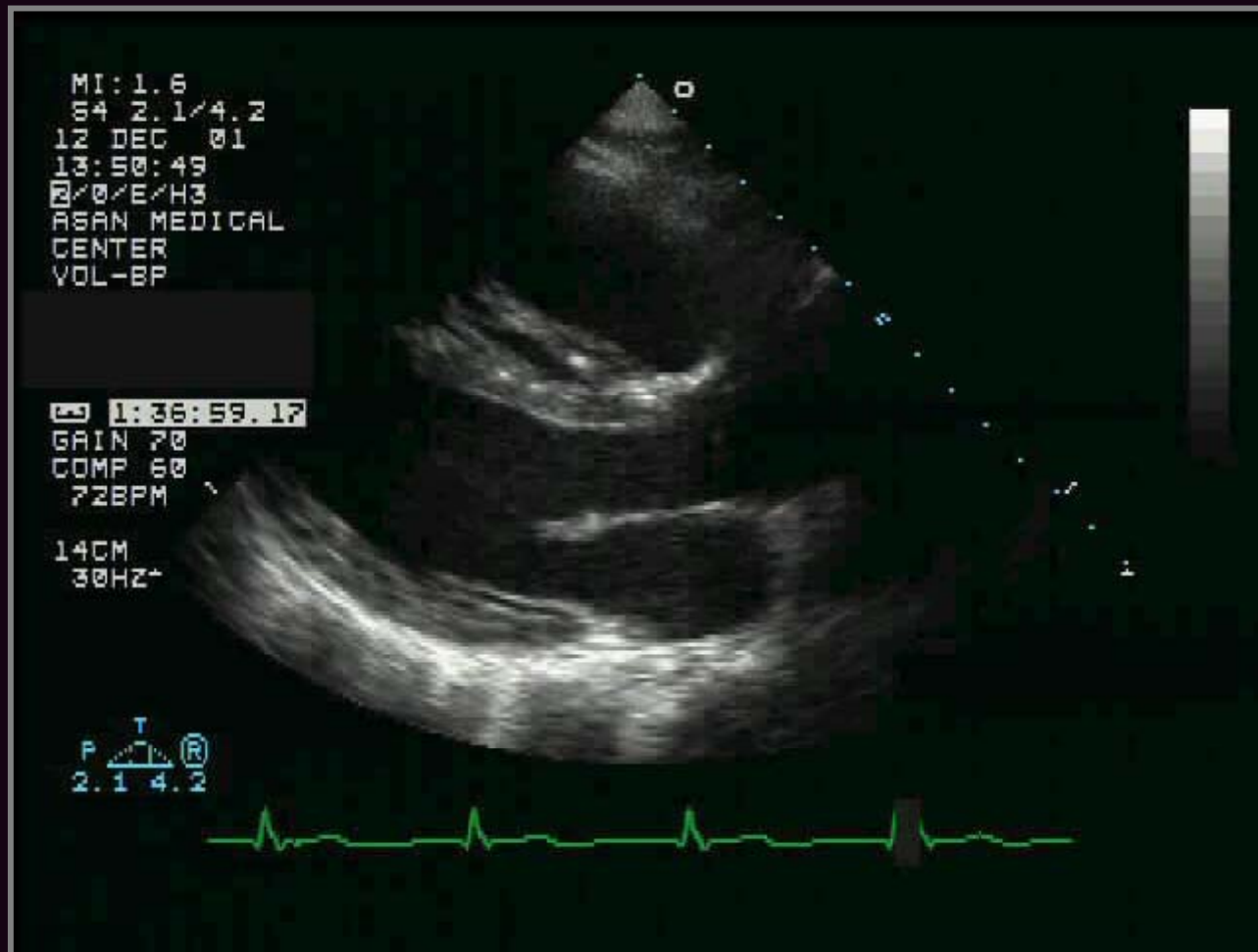
*Includes review of previous literature.

†Presence or absence of ventricular septal defect not reported.

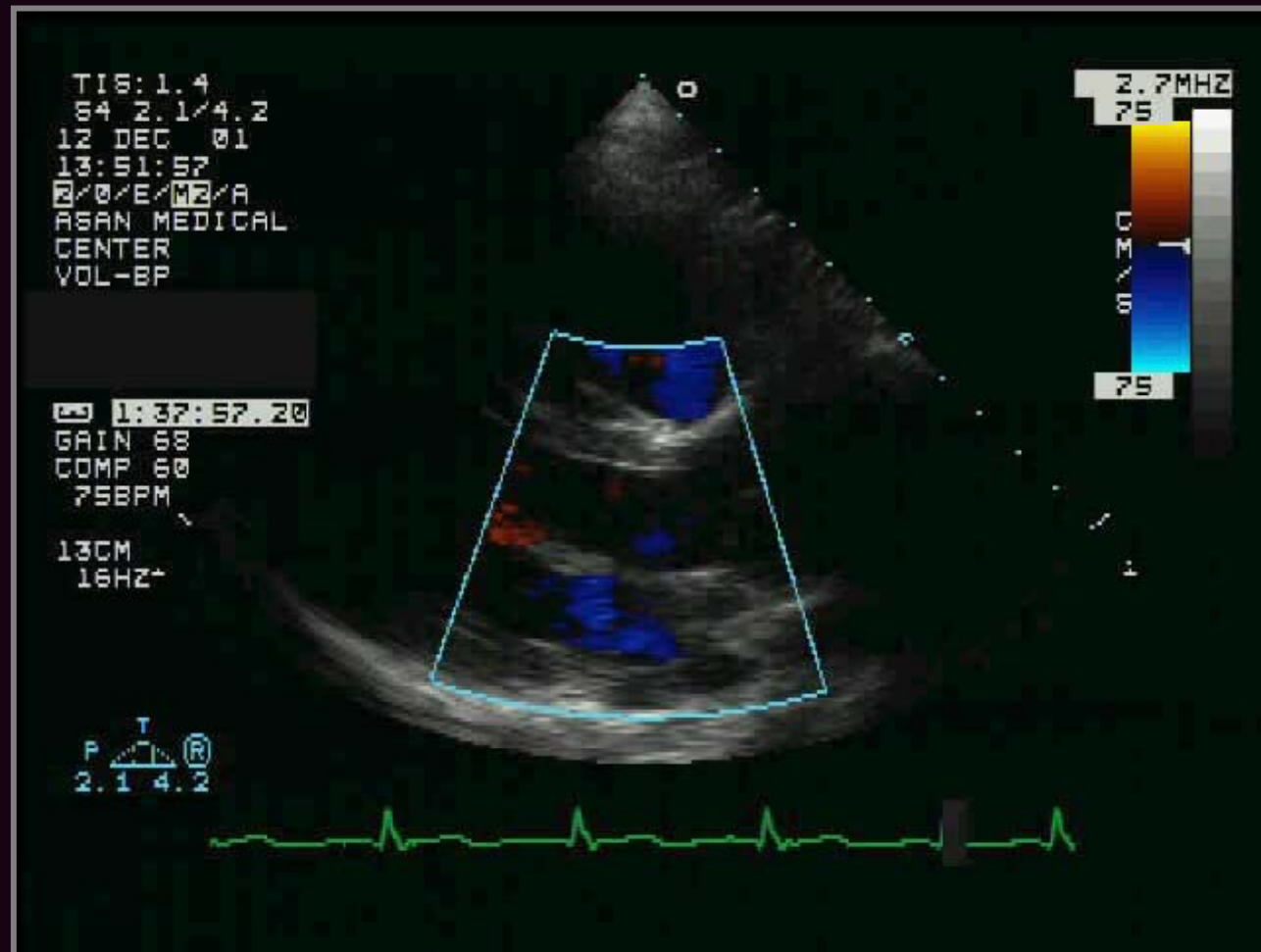
‡Excludes report of Dev.



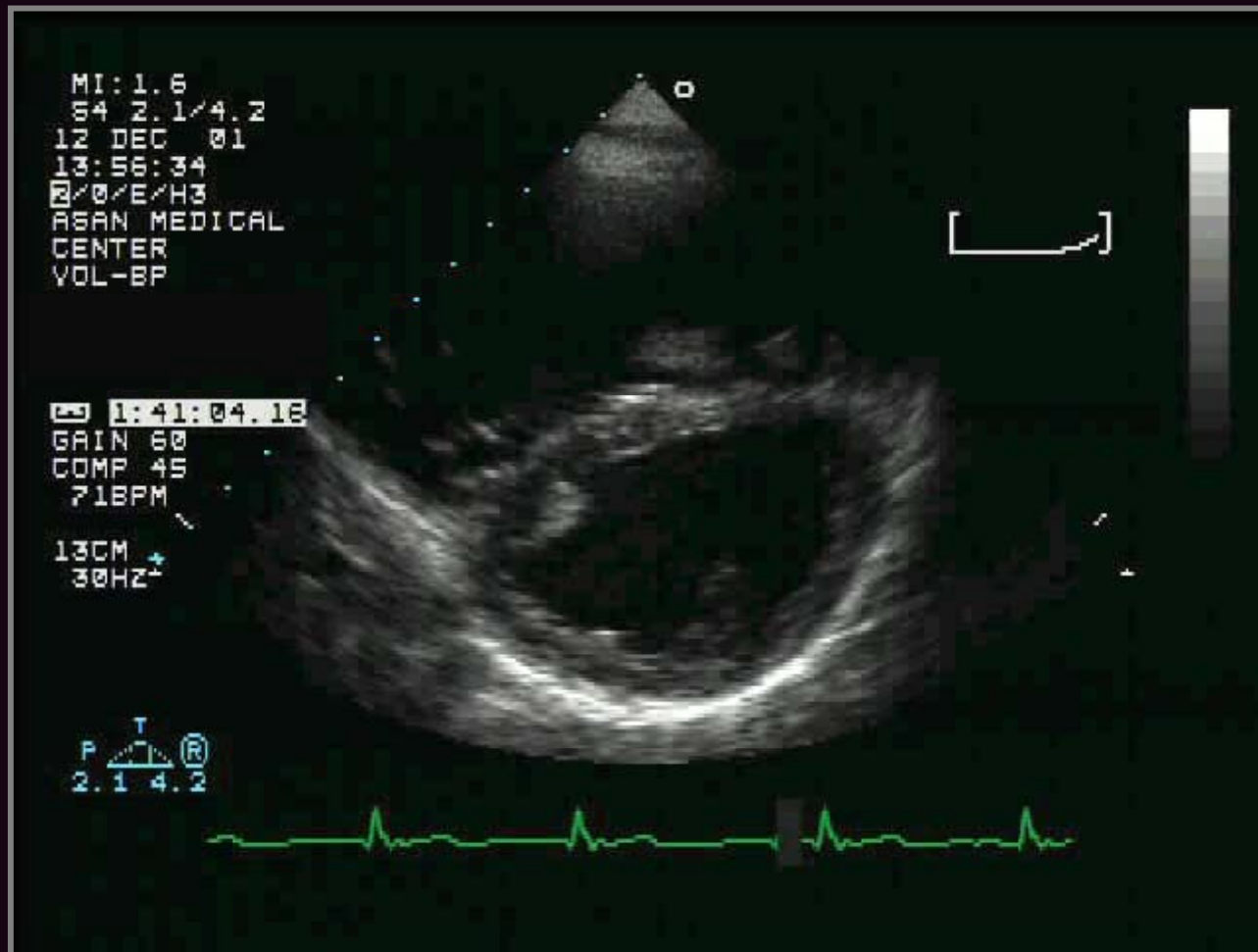
s/p TOF total correction (18/M)



s/p TOF total correction (18/M)



s/p TOF total correction (18/M)

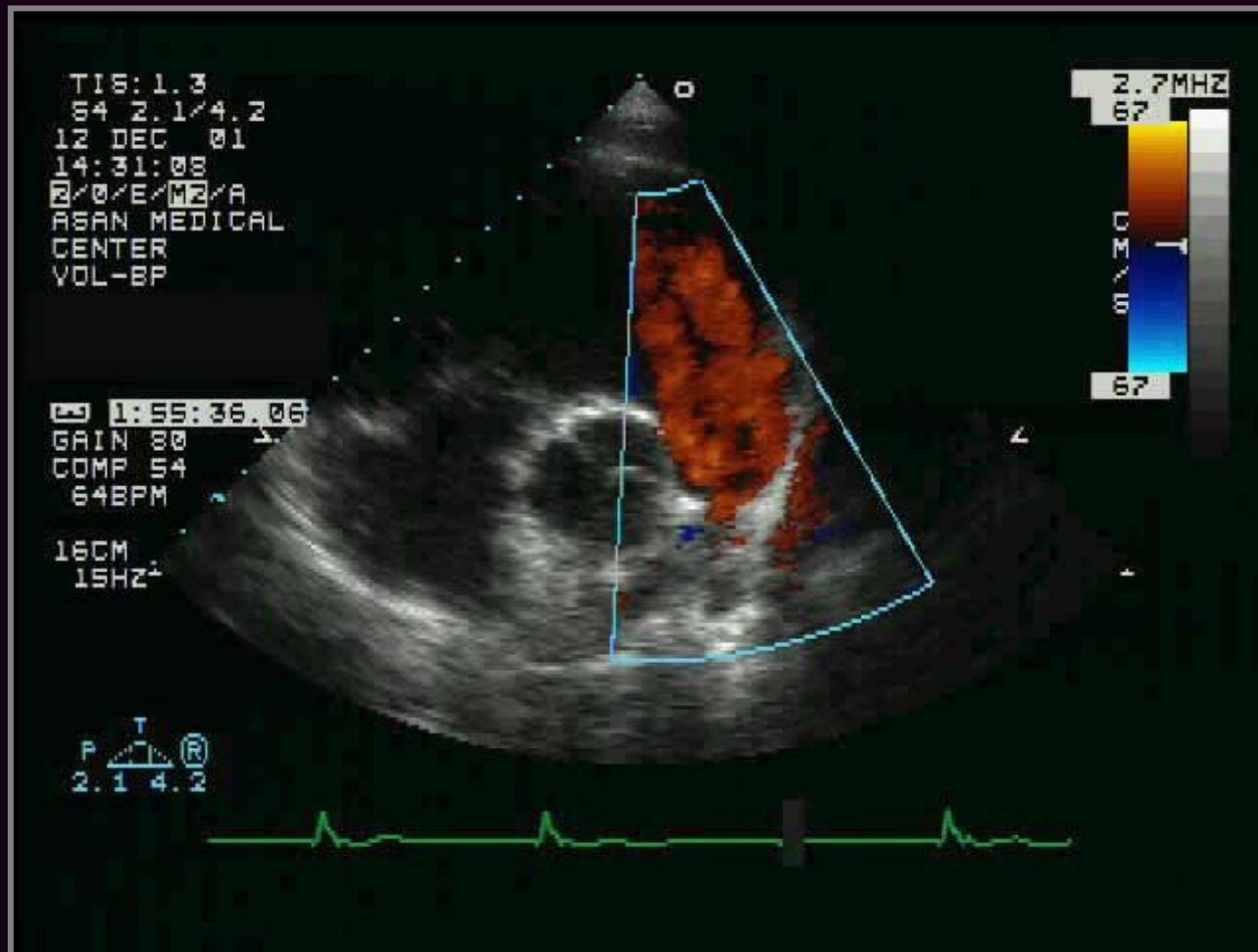


s/p TOF total correction (18/M)

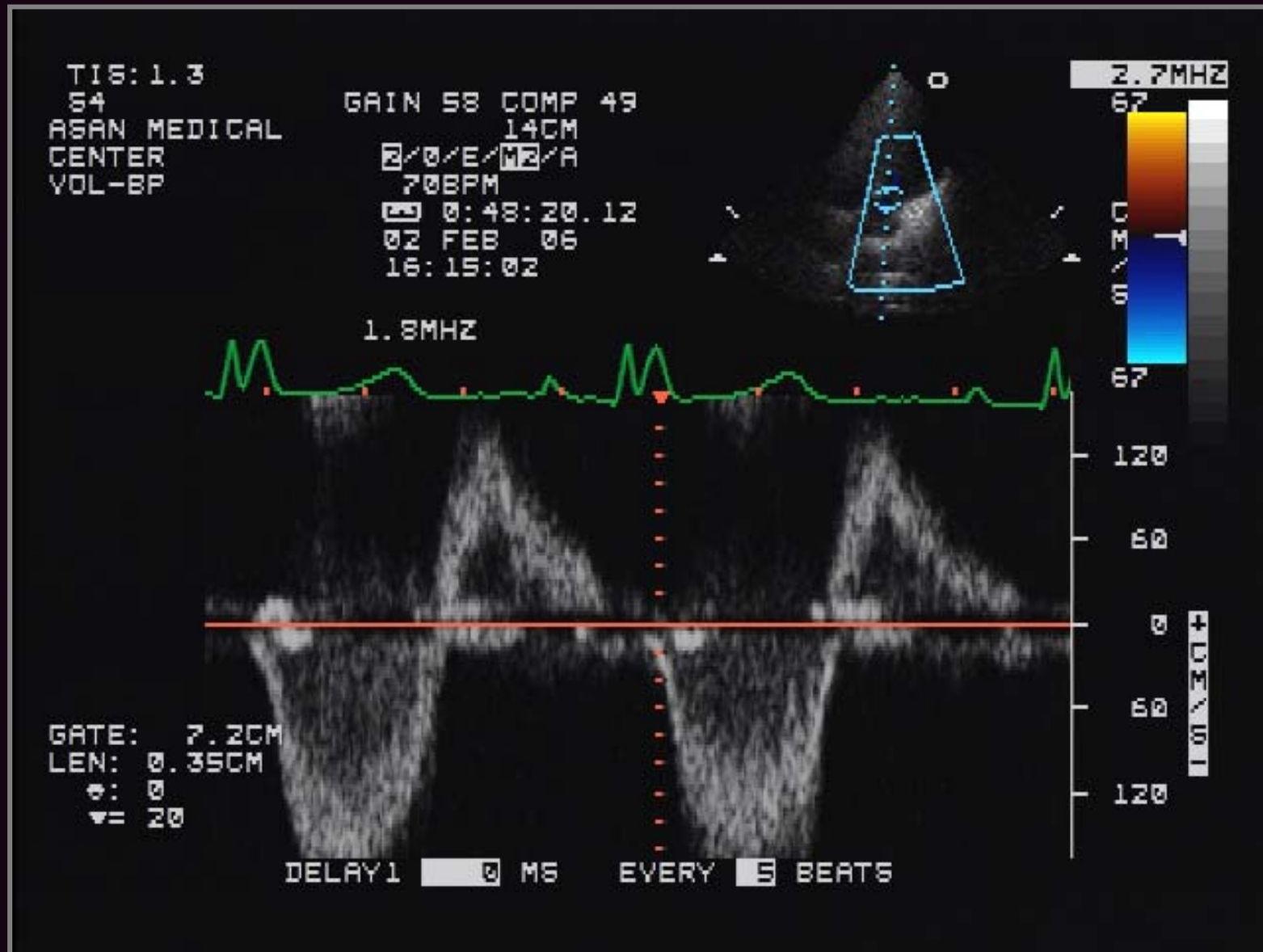
□ 이 환자에서 RV volume overload의 원인으로 가장 의심되는 것은 ?

1. Atrial septal defect
2. Severe tricuspid regurgitation
3. Severe pulmonary regurgitation
4. Remnant ventricular septal defect

s/p TOF total correction (18/M)



s/p TOF total correction (18/M)

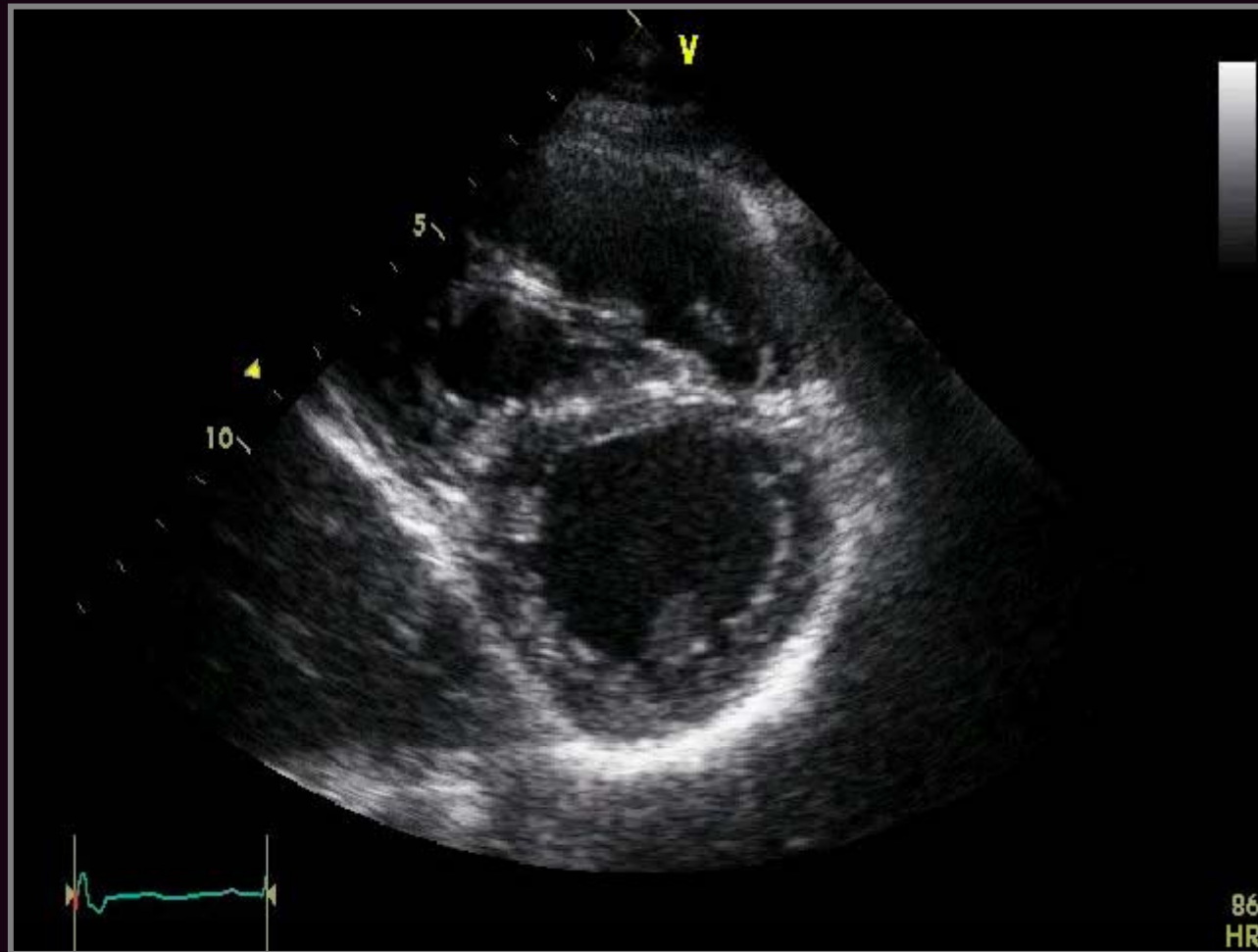


Tetralogy of Fallot

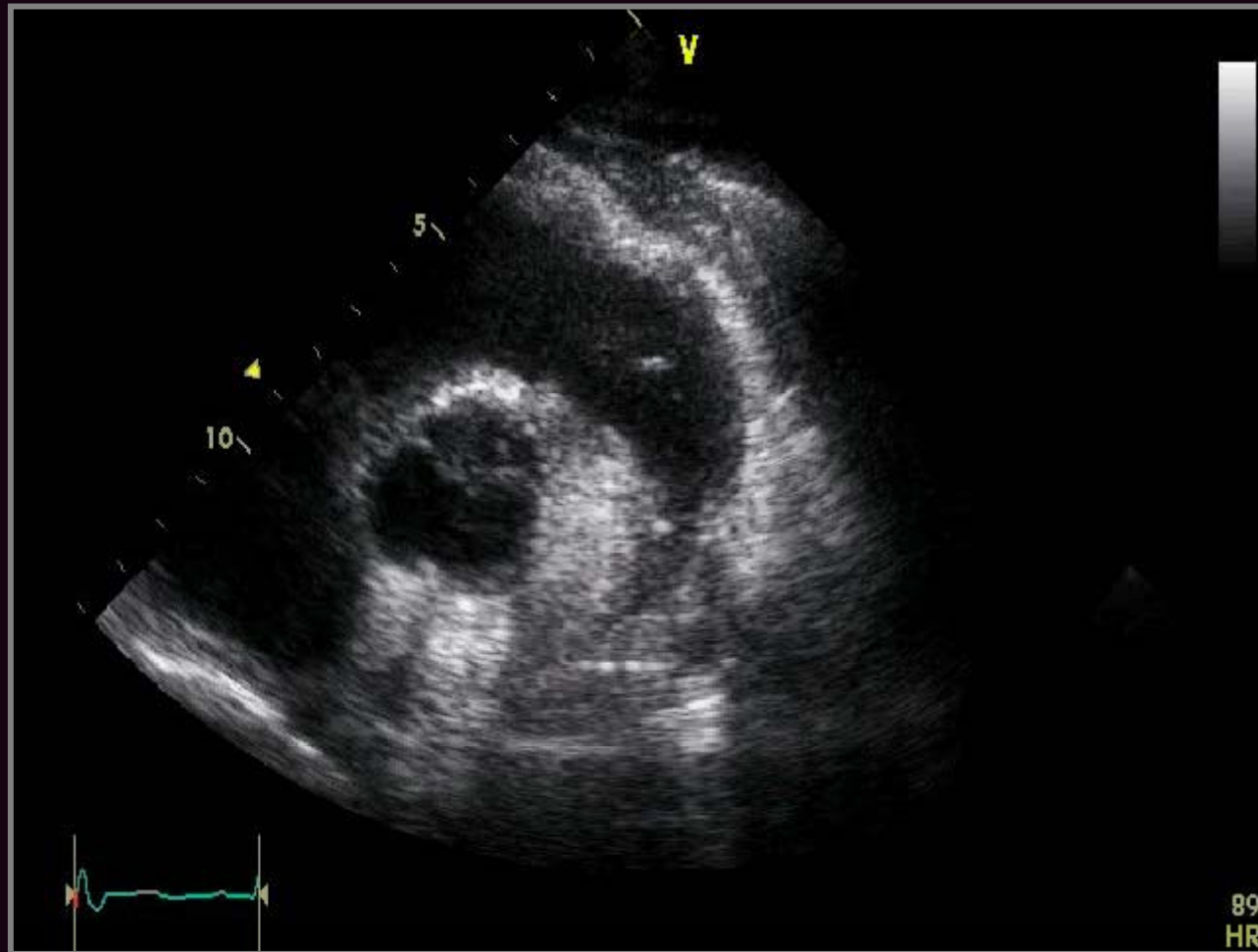□ Clinical issues after total correction

- Pulmonary regurgitation and RV dilatation
- Residual pulmonary stenosis
- Ventricular arrhythmia and sudden death

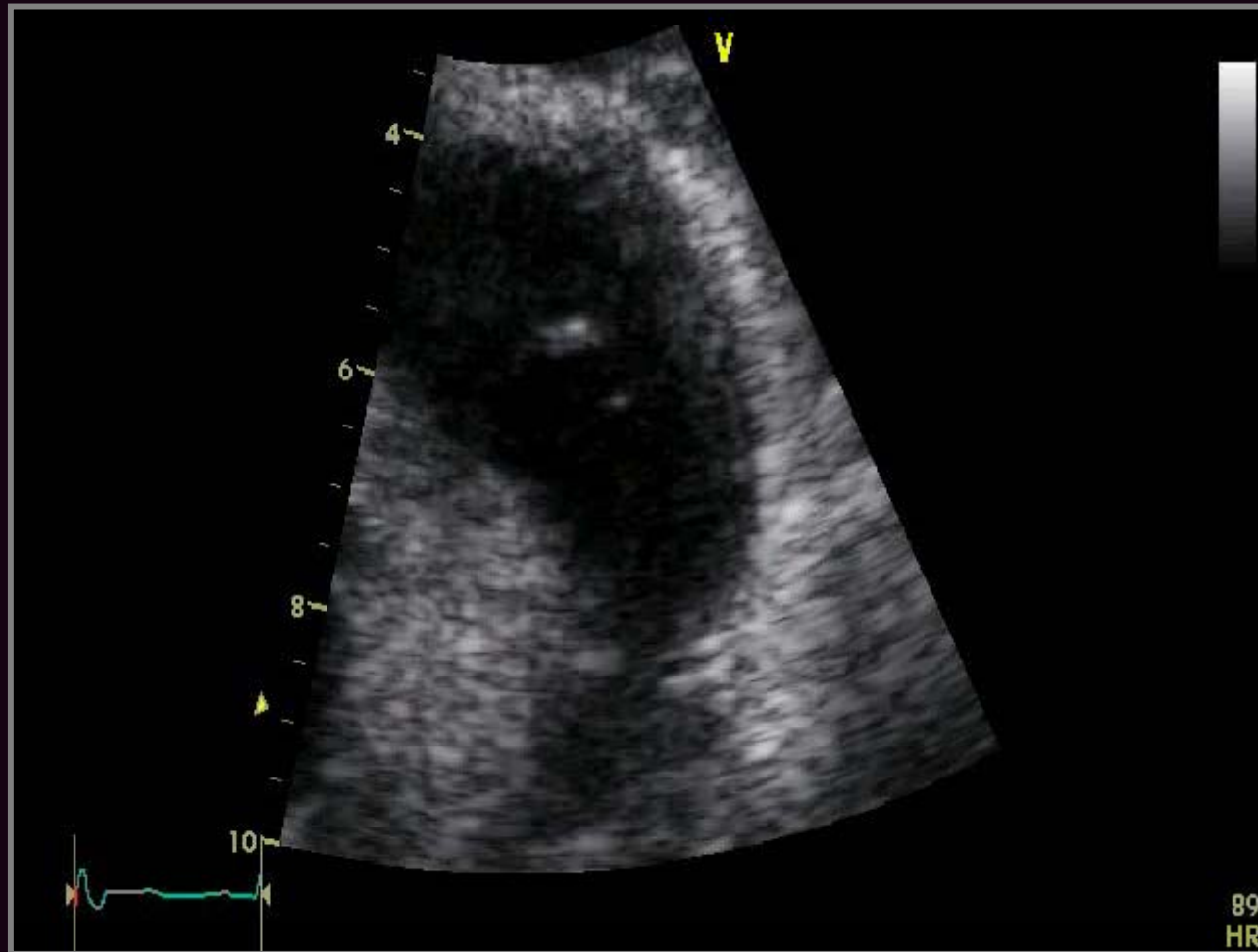
s/p TOF total correction (18/M)



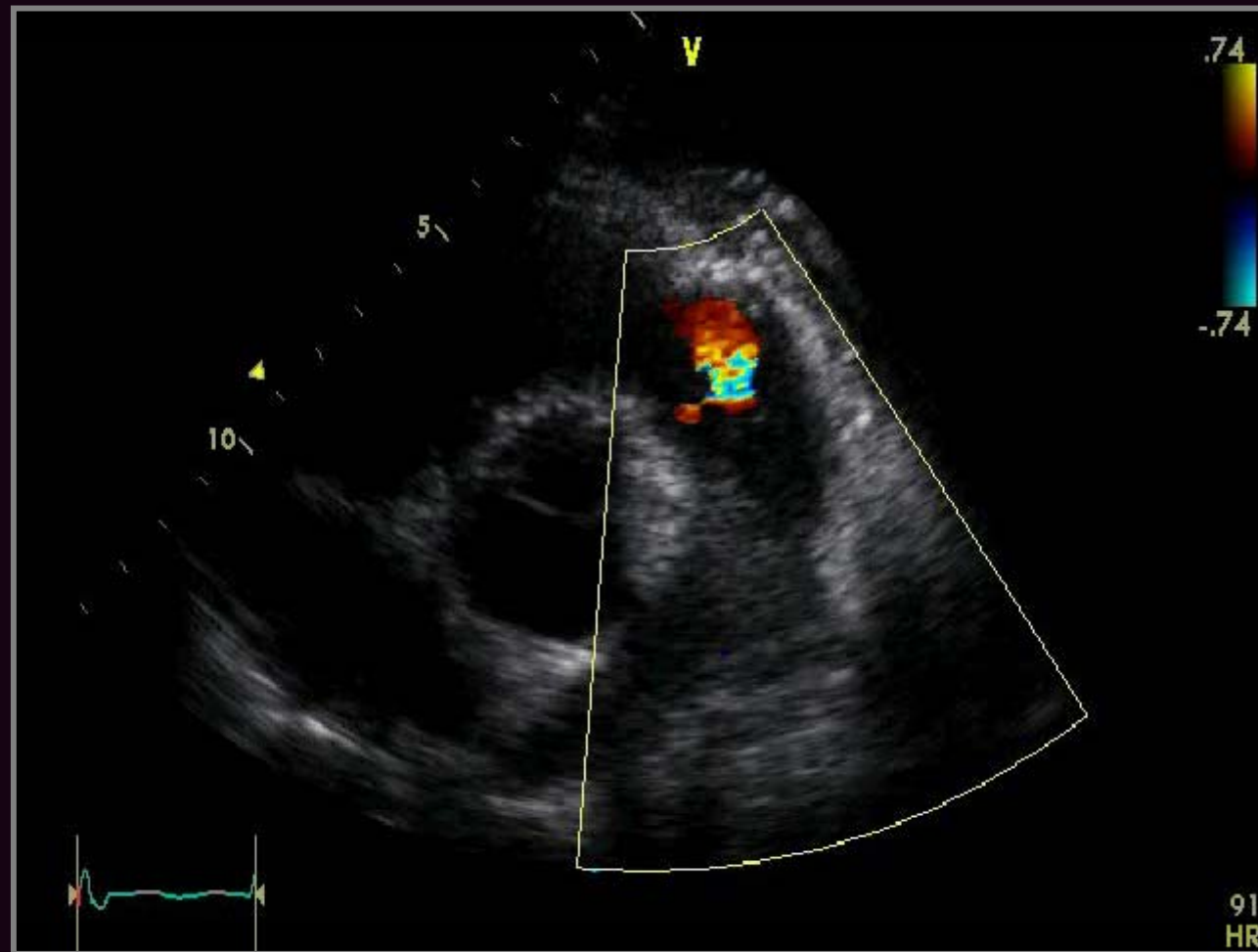
s/p TOF total correction (18/M)



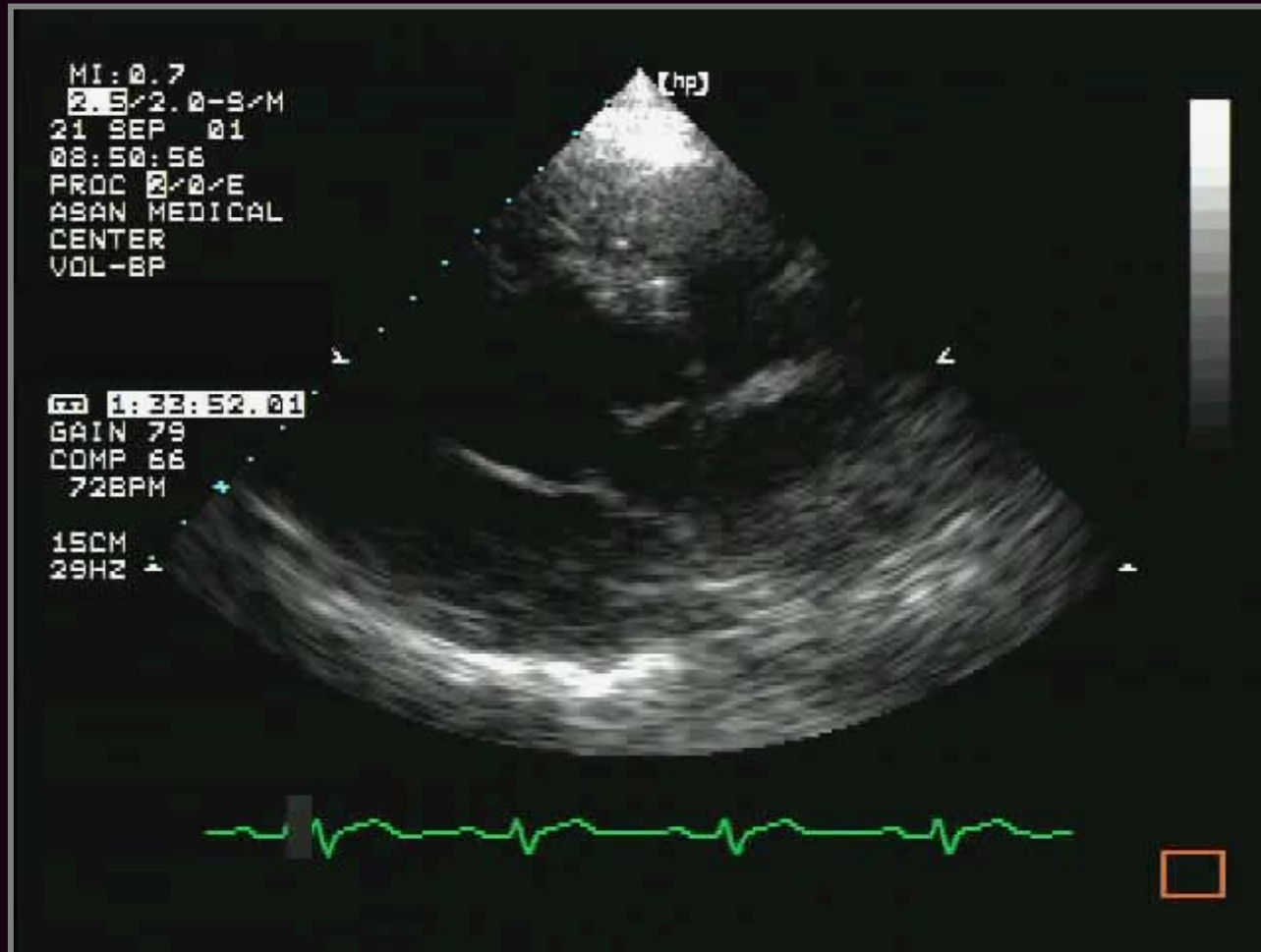
s/p TOF total correction (18/M)



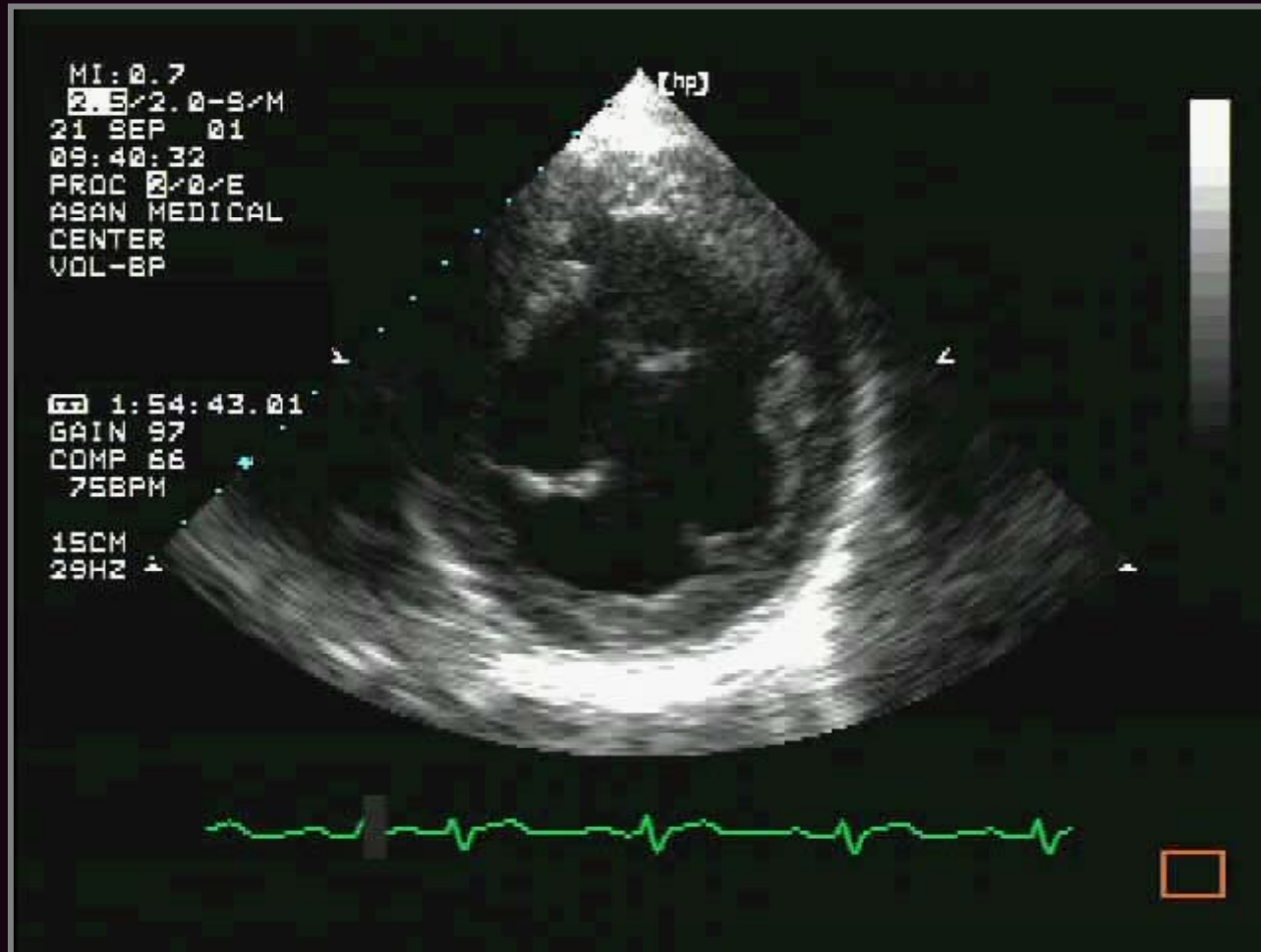
s/p TOF total correction (18/M)



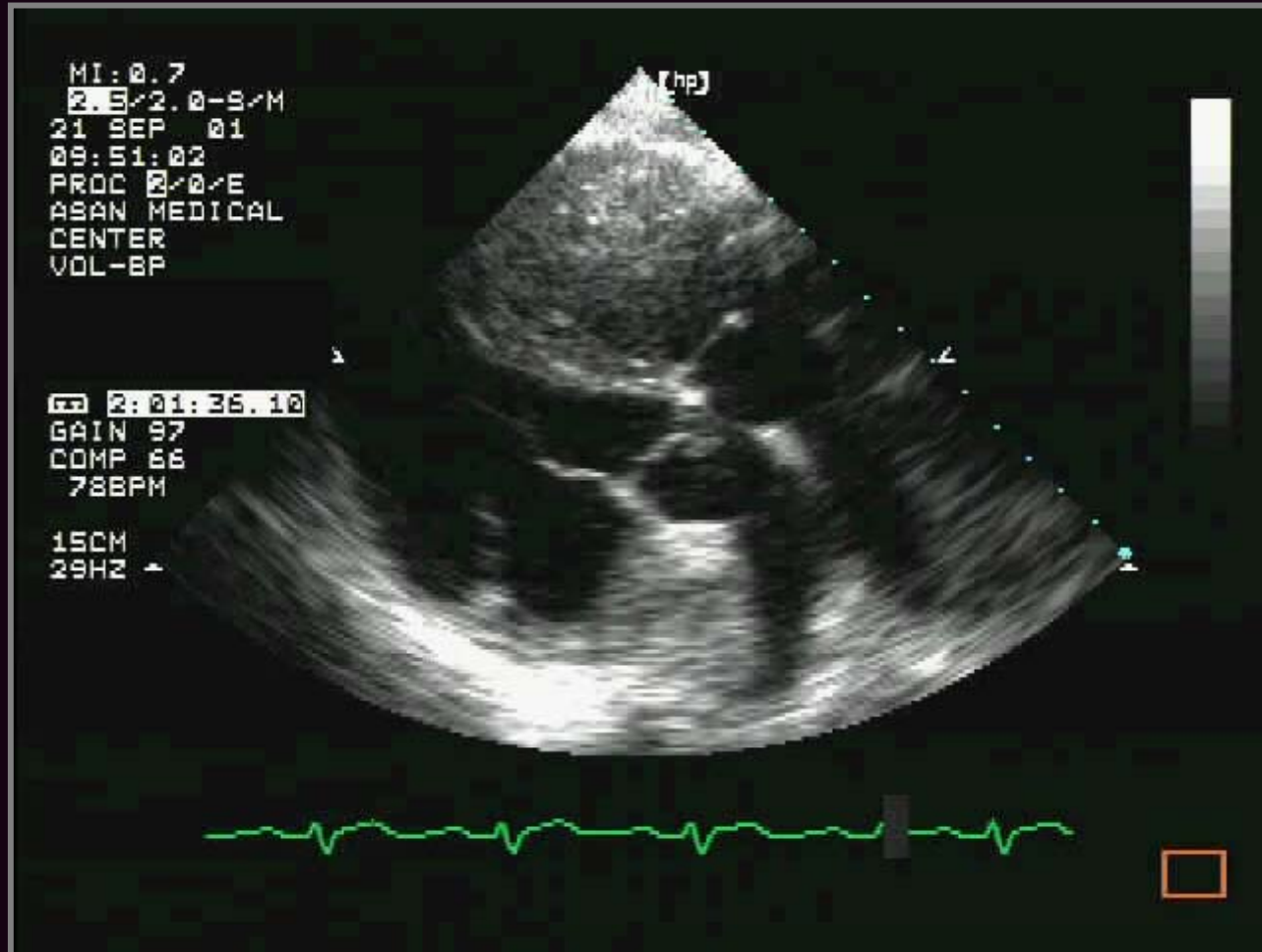
Case (42/M)



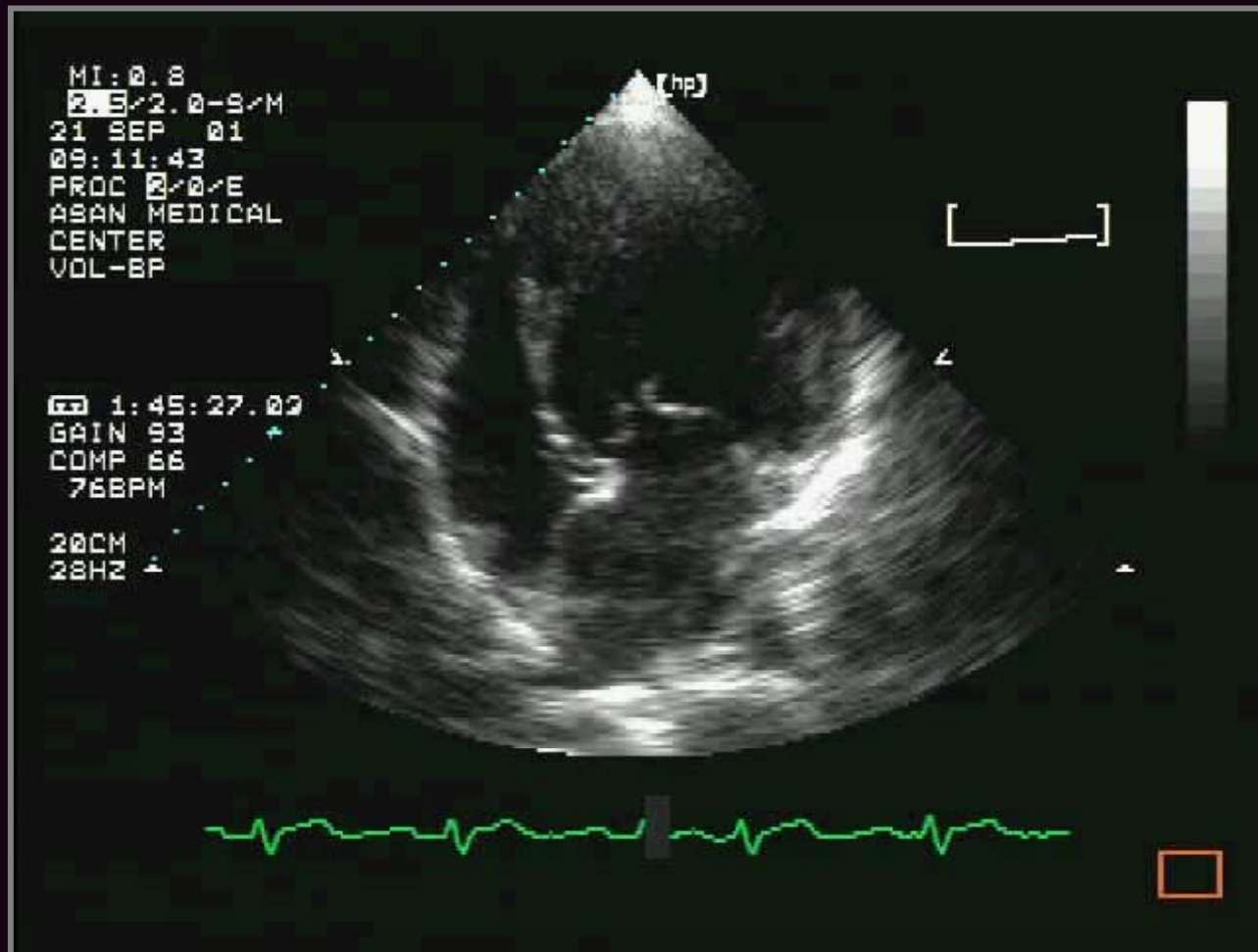
Case (42/M)



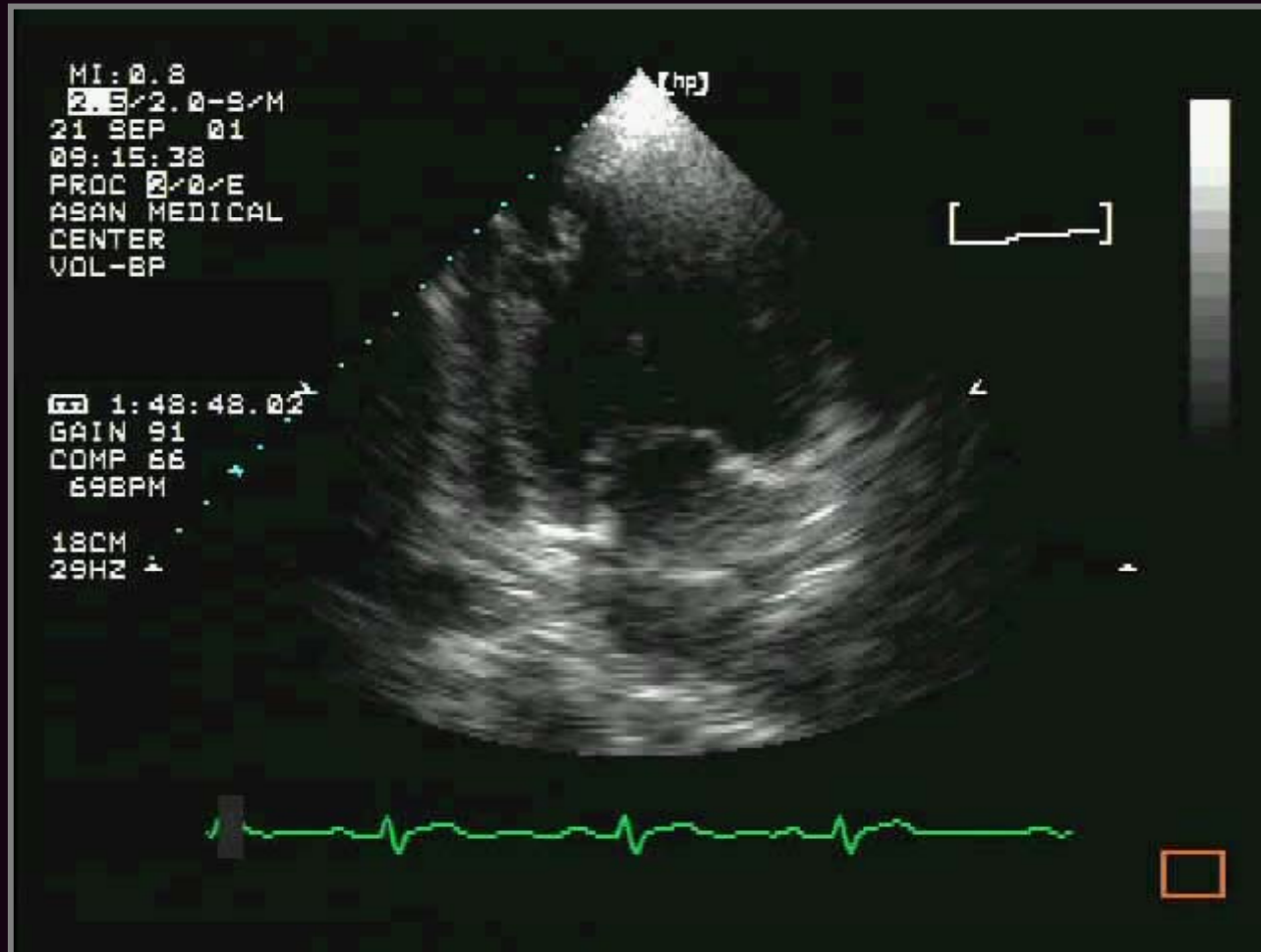
Case (42/M)



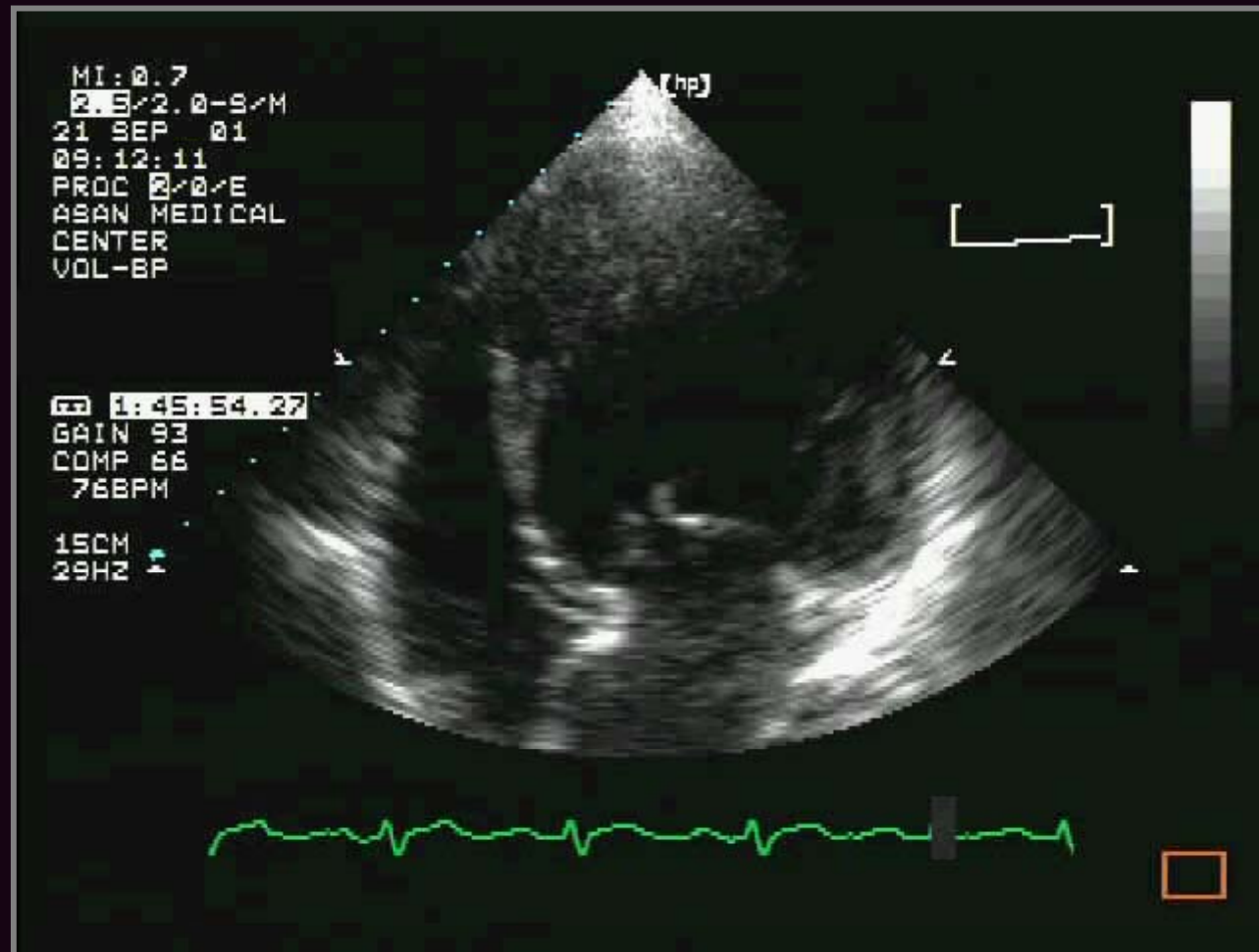
Case (42/M)



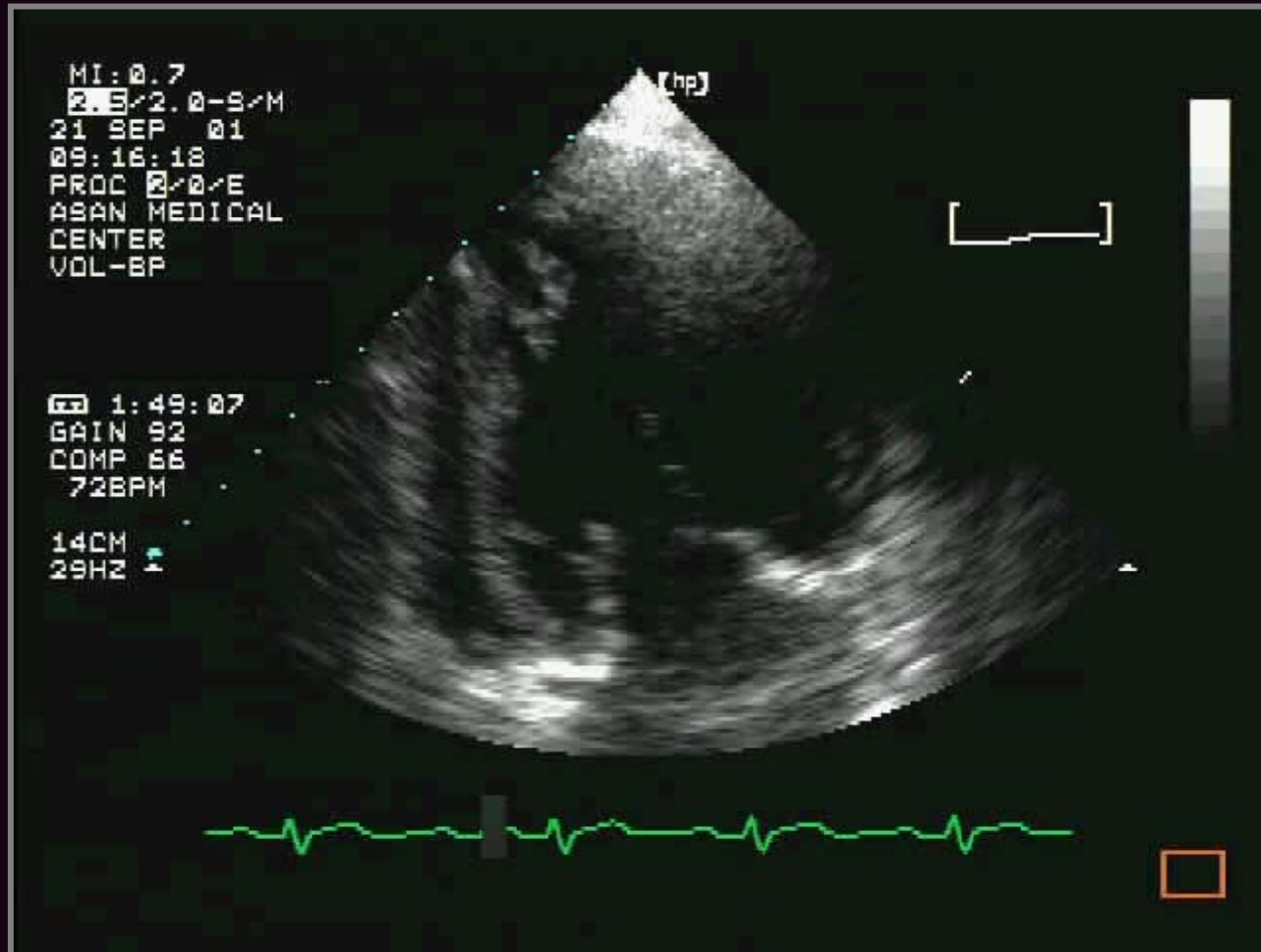
Case (42/M)



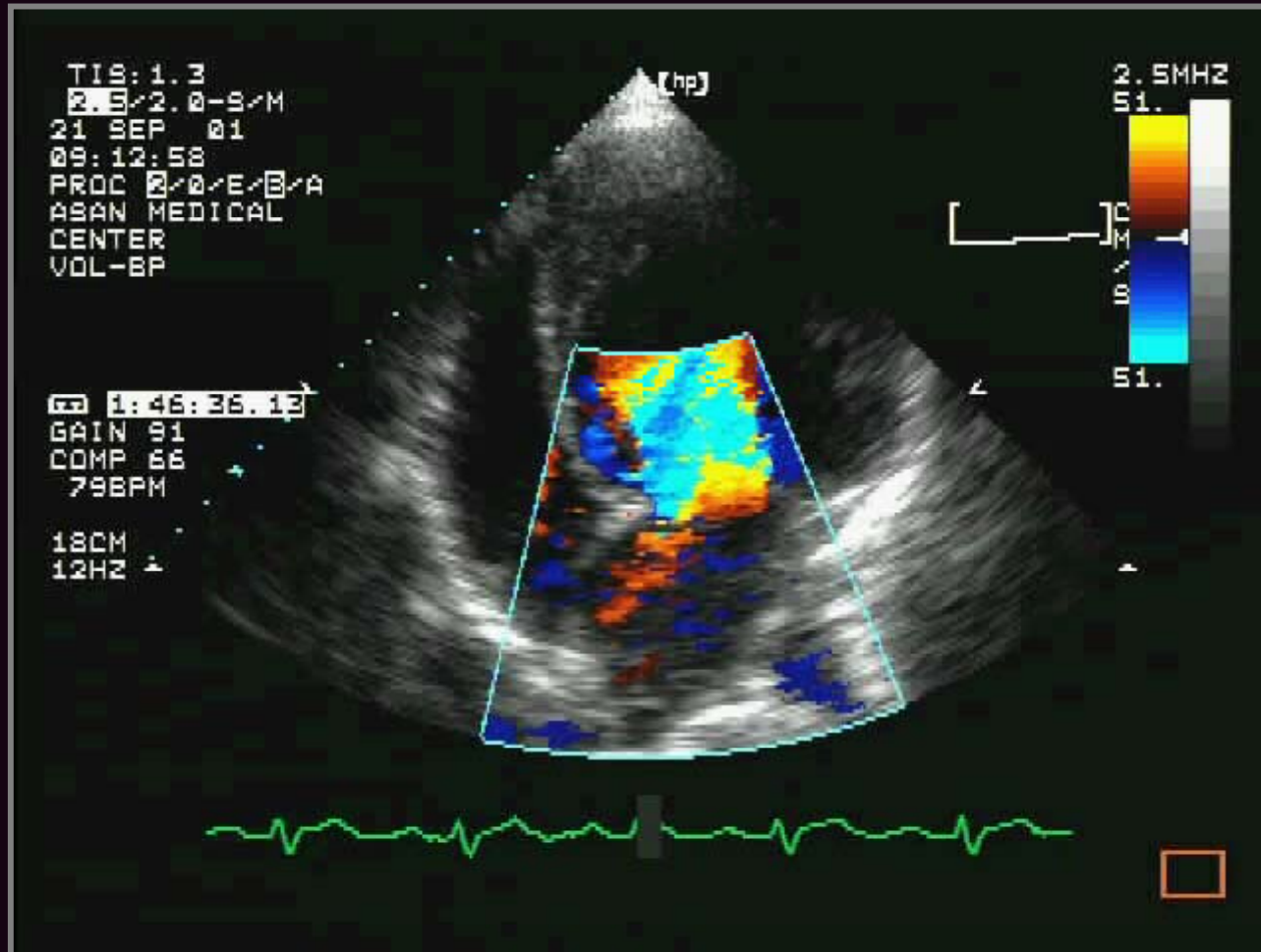
Case (42/M)



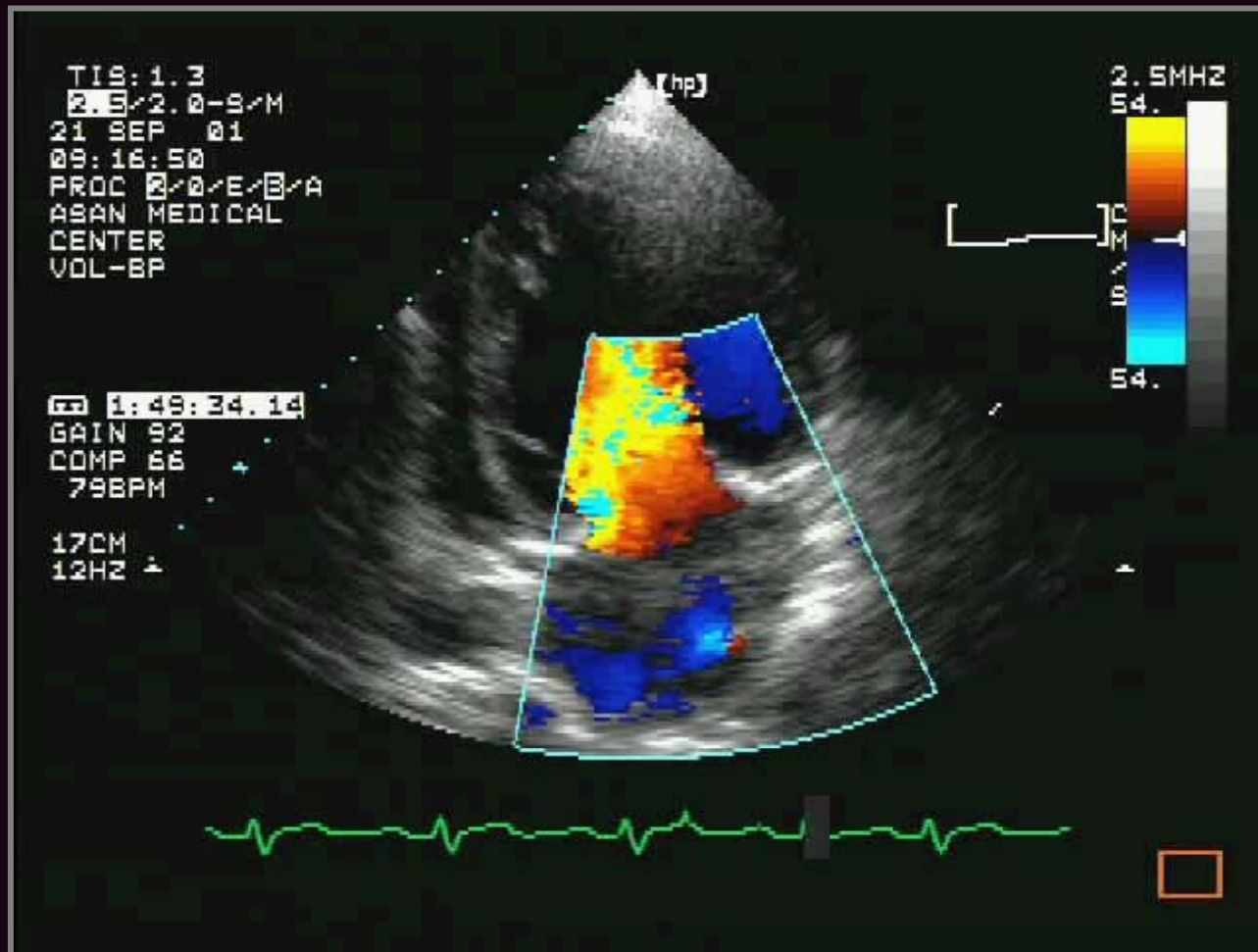
Case (42/M)



Case (42/M)



Case (42/M)

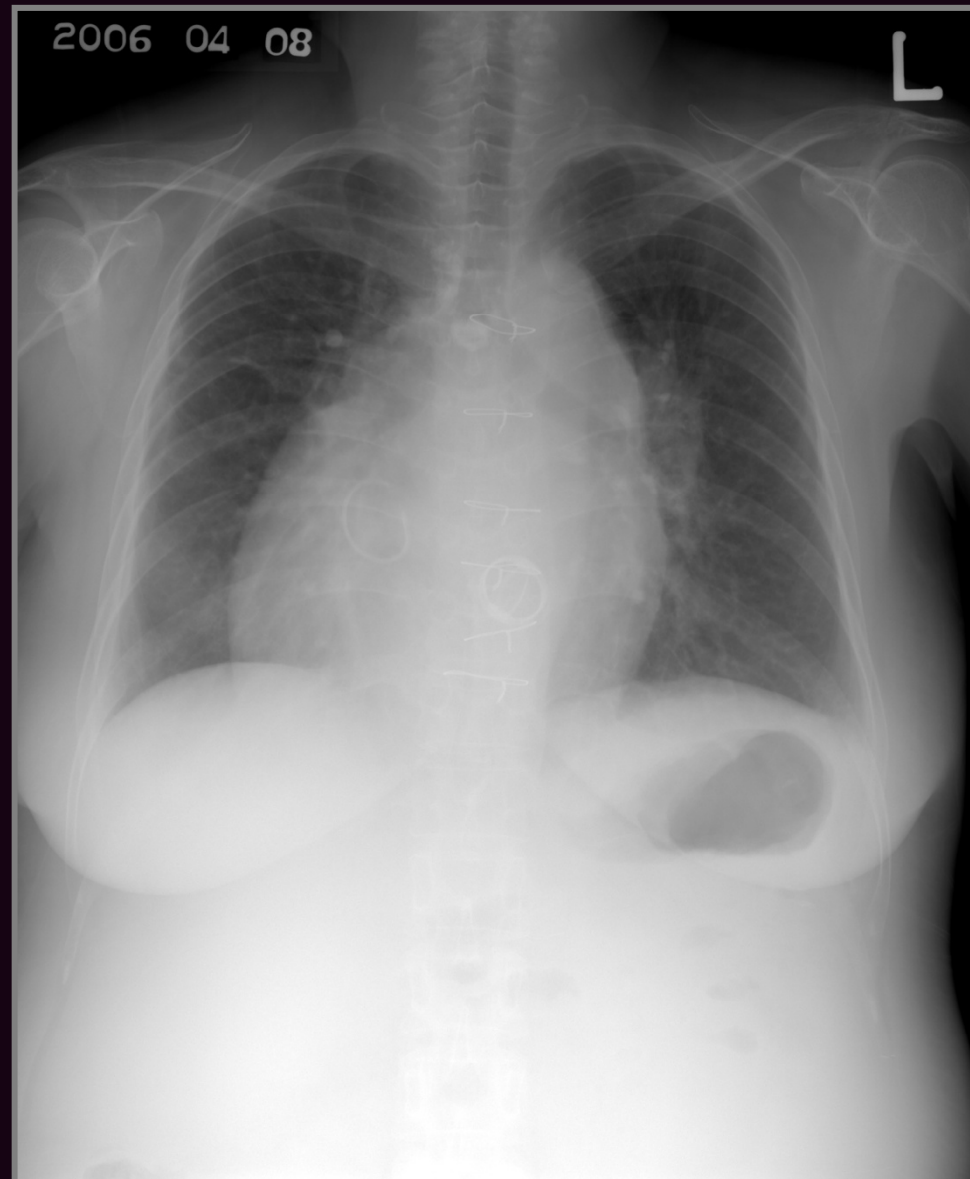

Corrected TGA

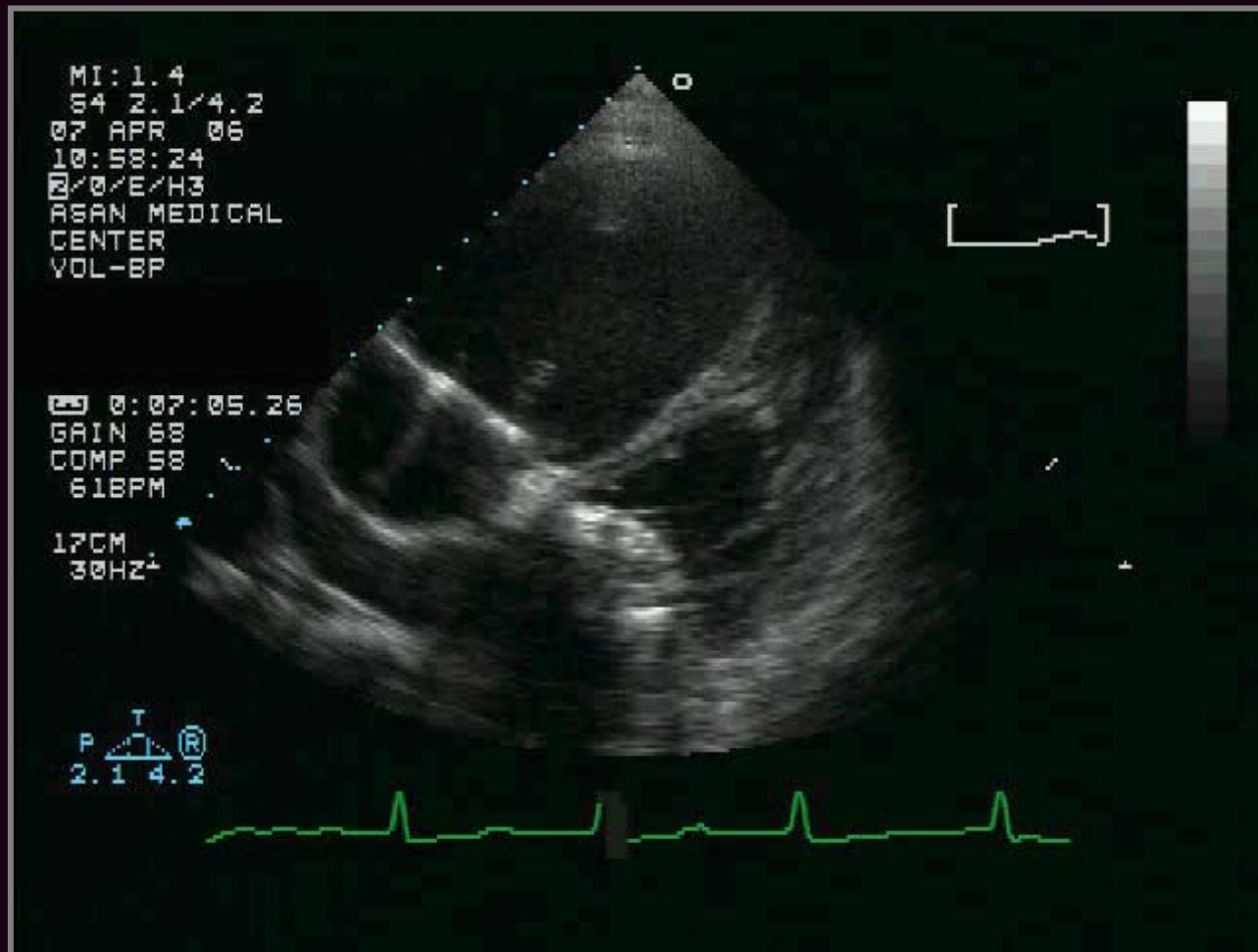
□ Clinical issues in corrected TGA

- Left AV valve regurgitation
- Left-sided ventricular dysfunction
- Atrial tachyarrhythmias
- Complete AV block

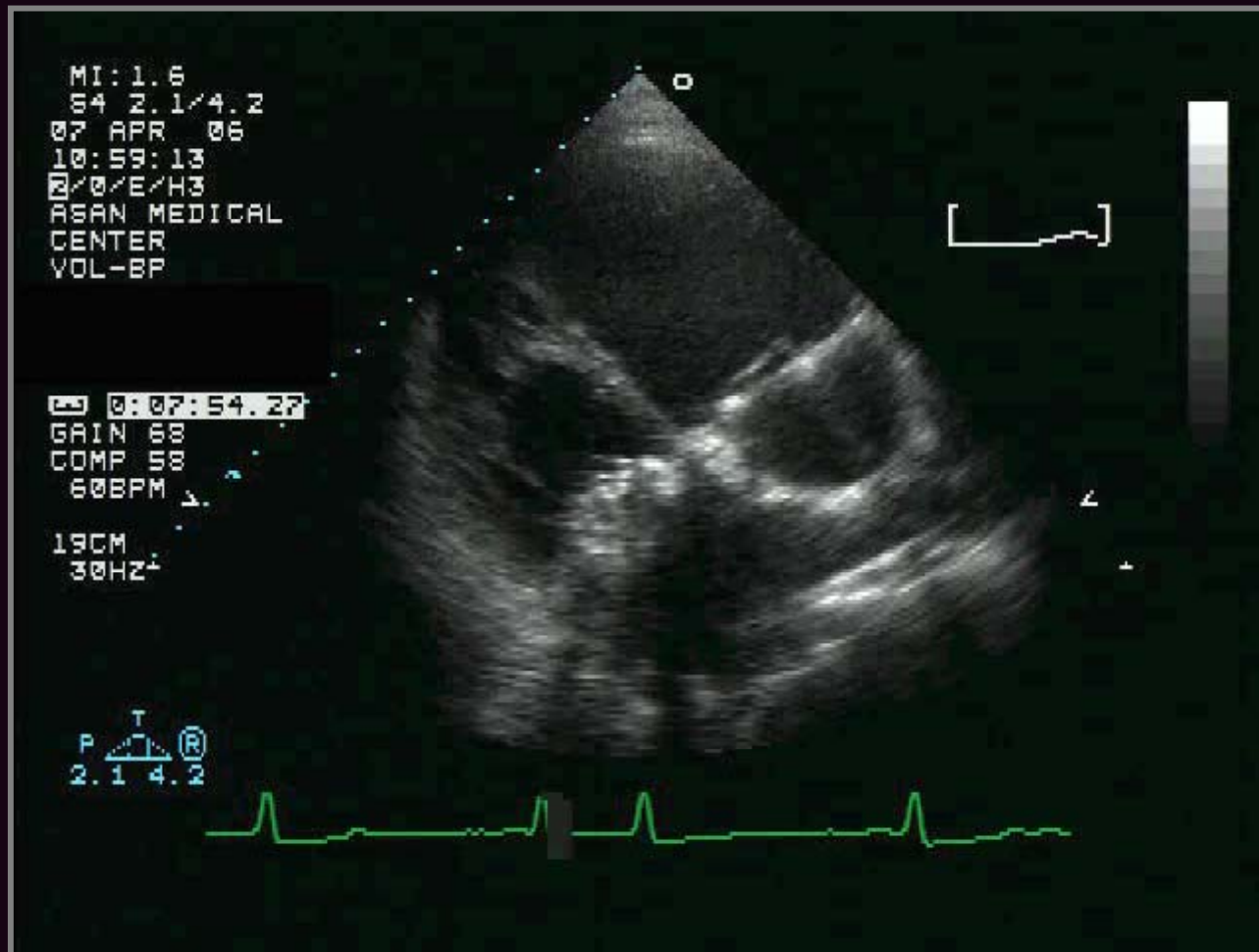
Case (54/F)



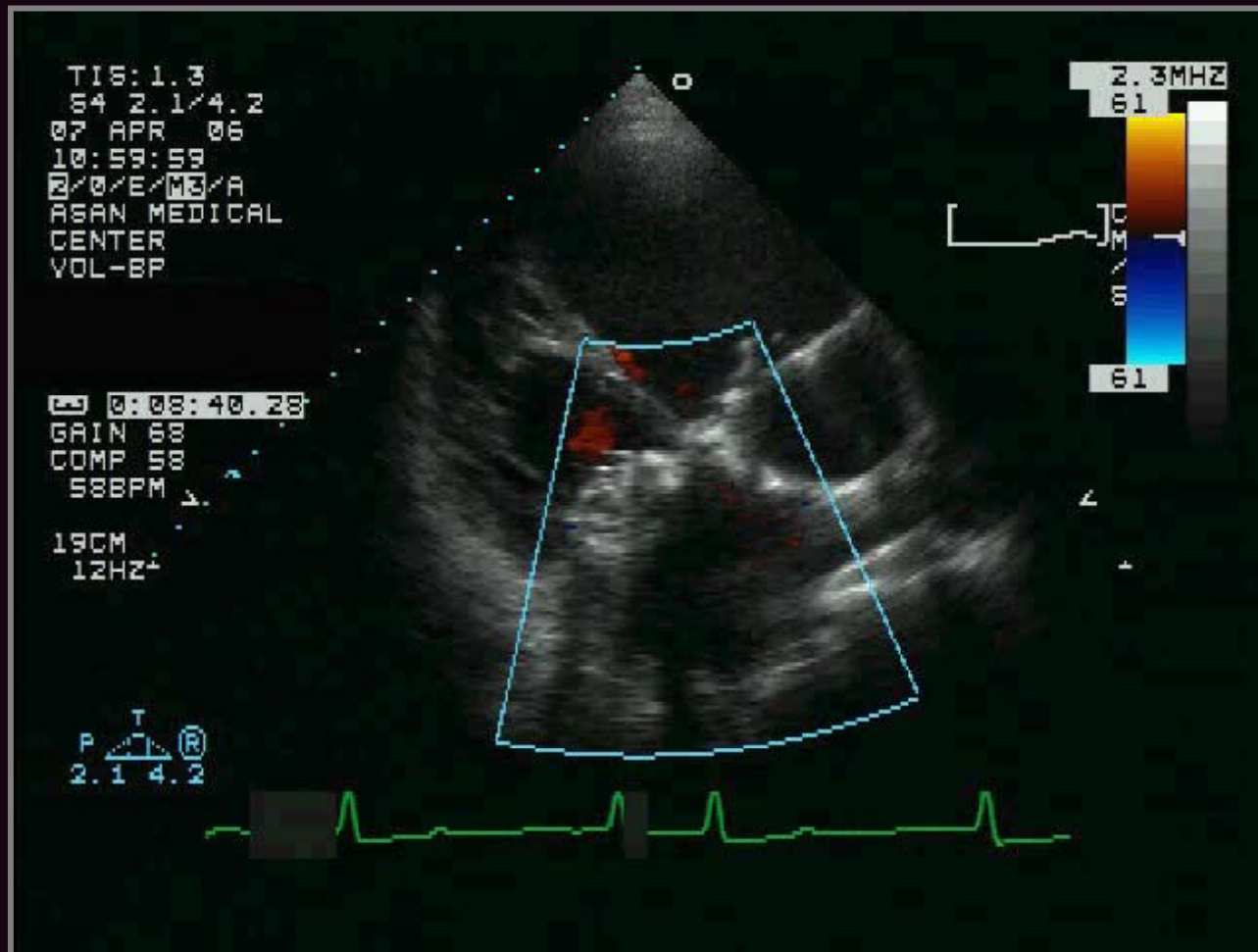
Case (54/F)



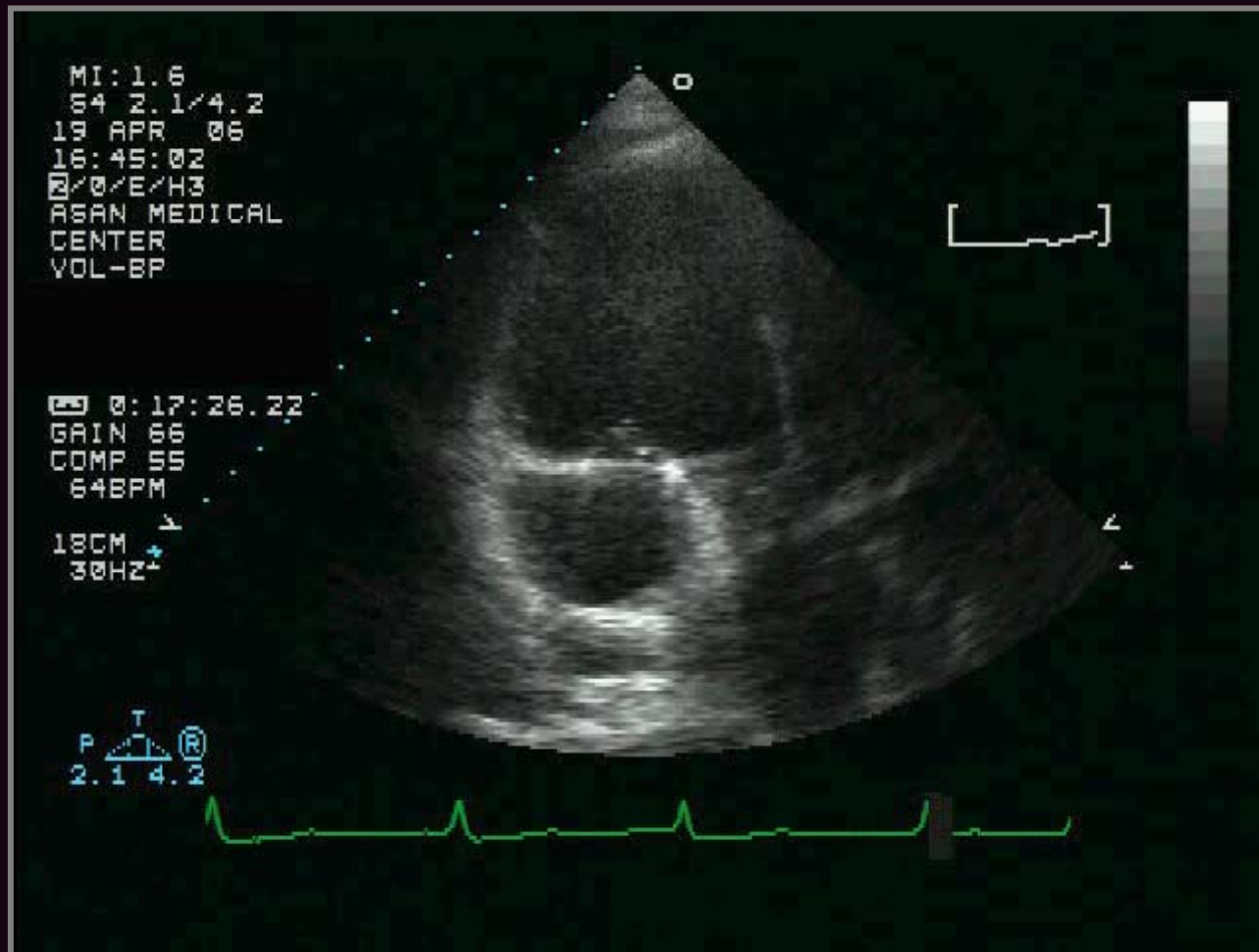
Case (54/F)



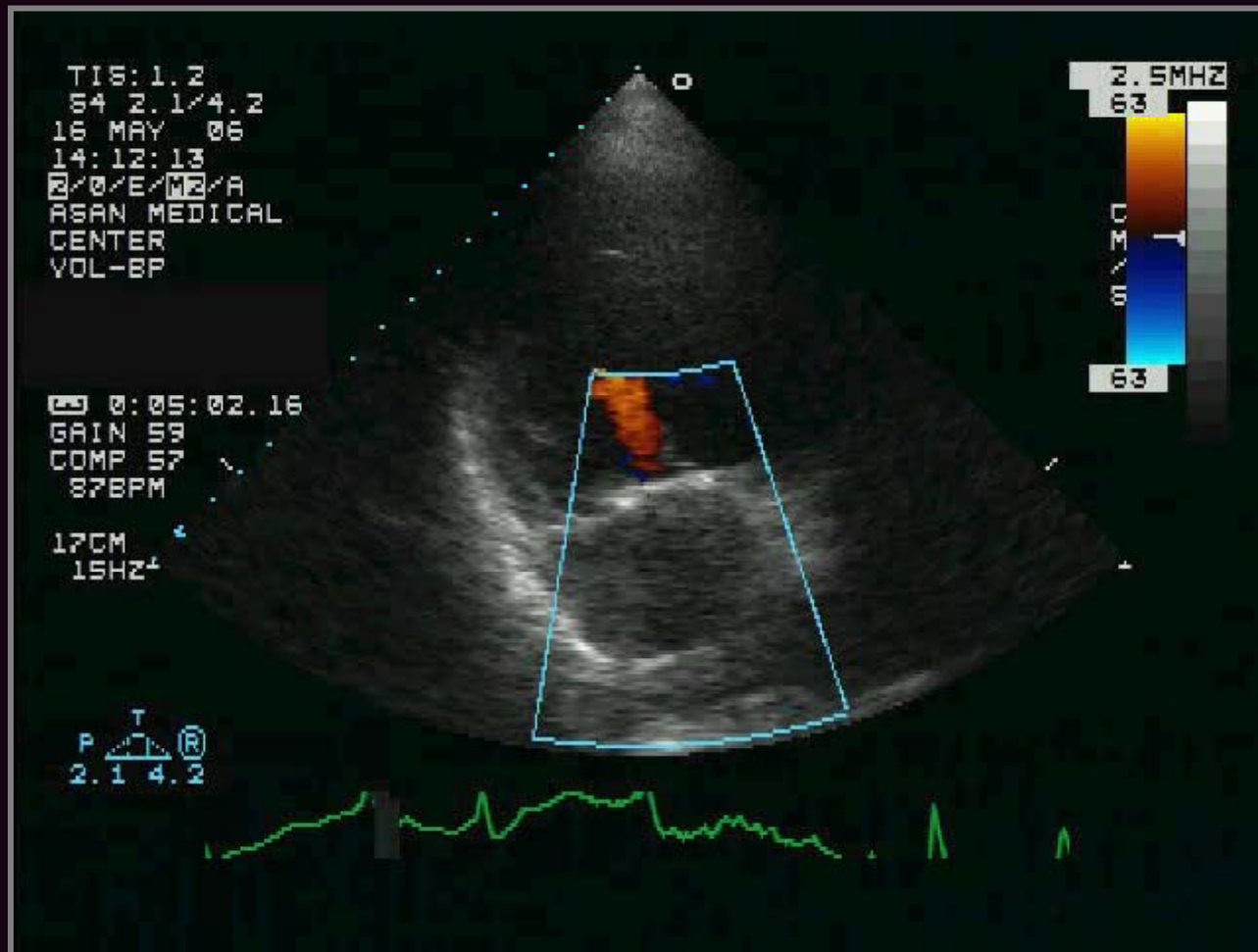
Case (54/F)



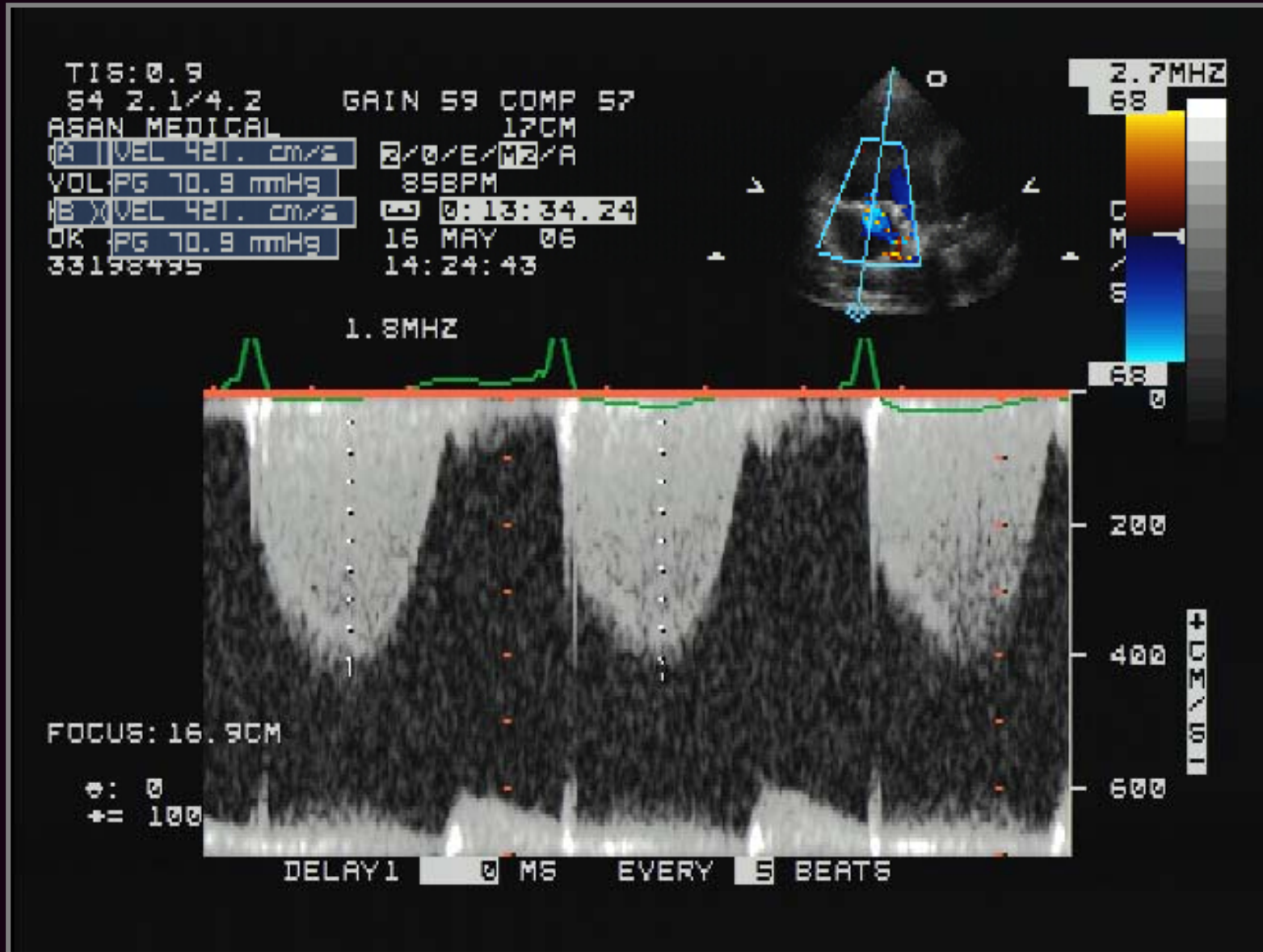
Case (54/F)



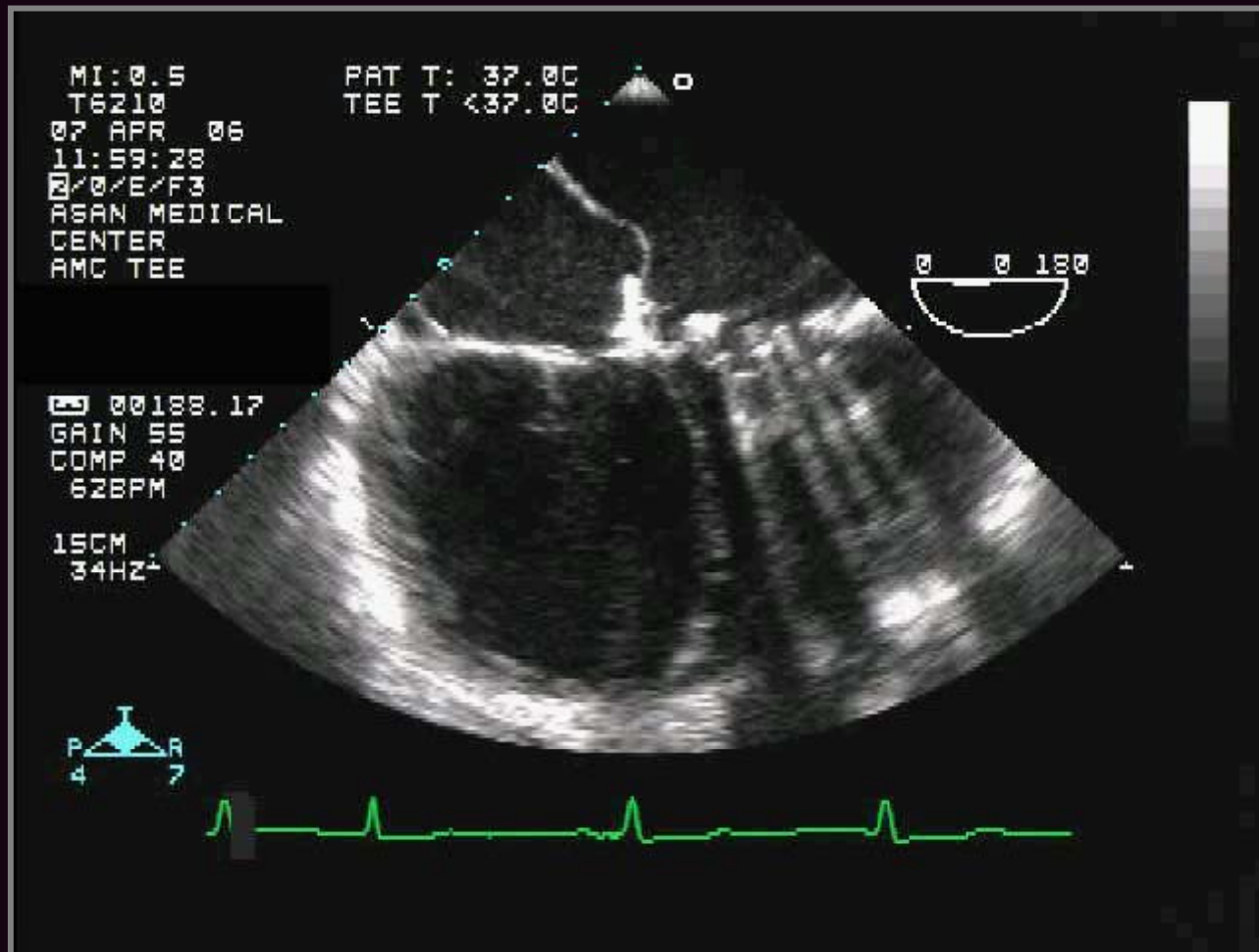
Case (54/F)



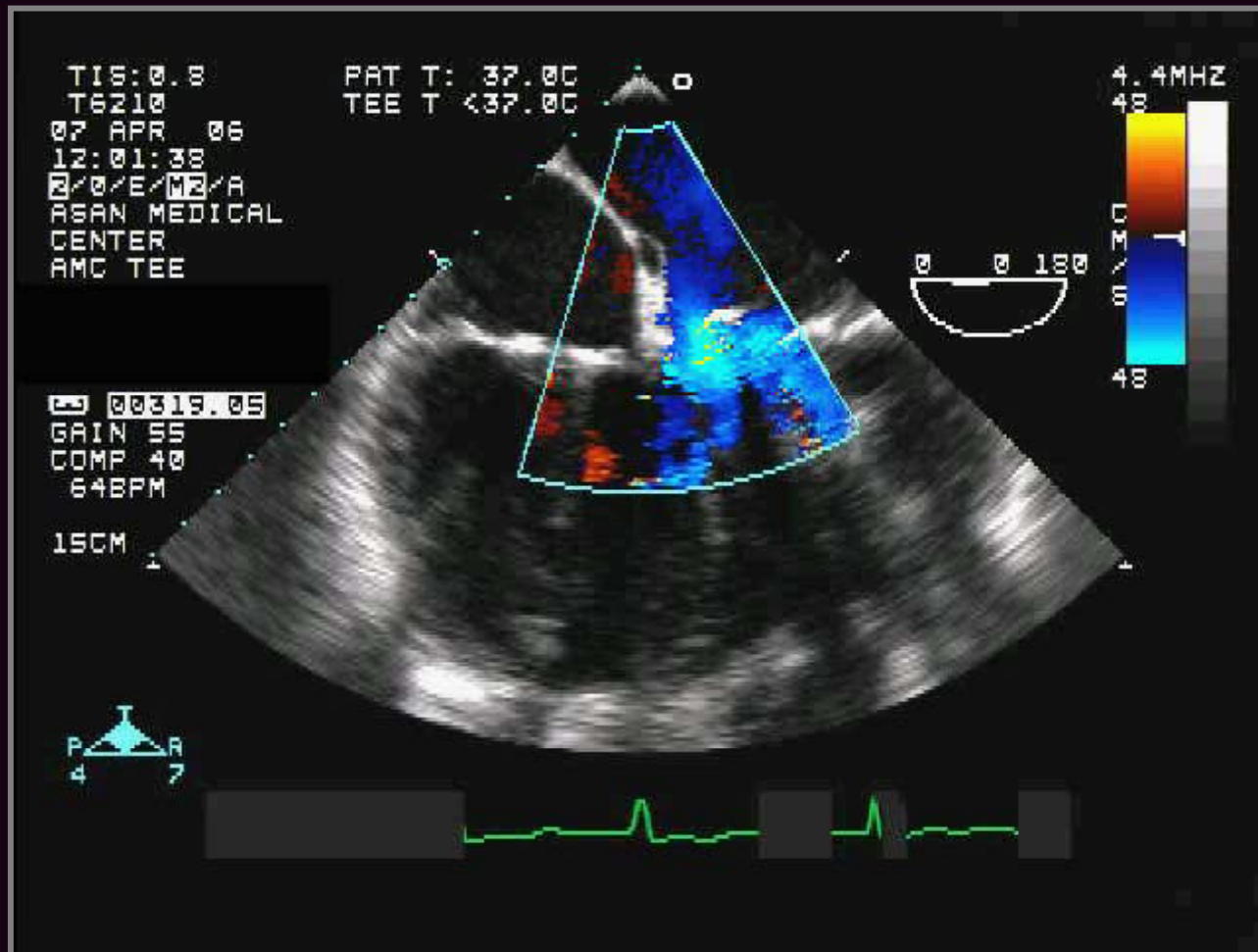
Case (54/F)



Case (54/F)



Case (54/F)

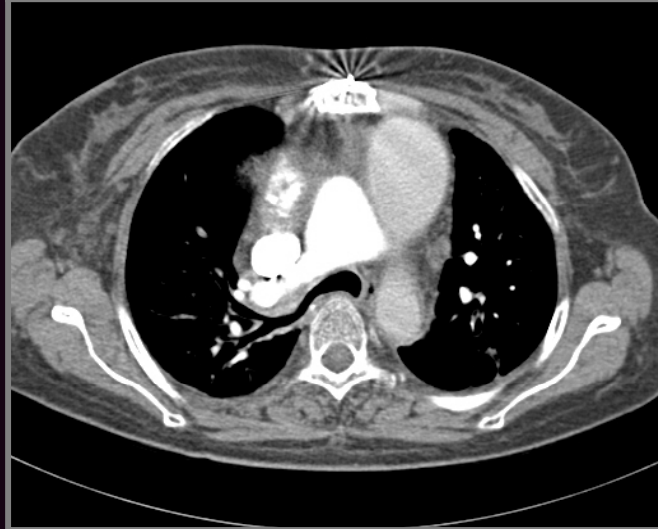
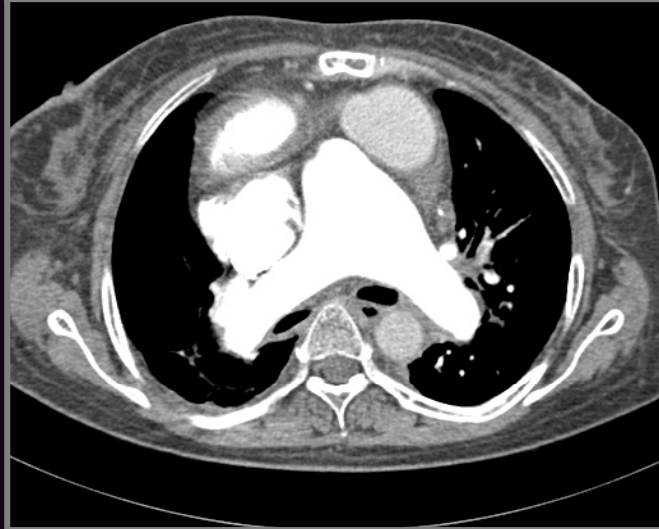
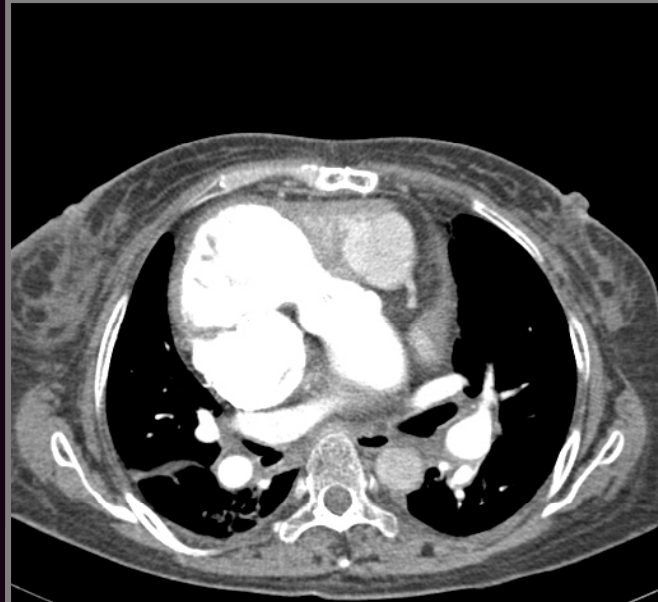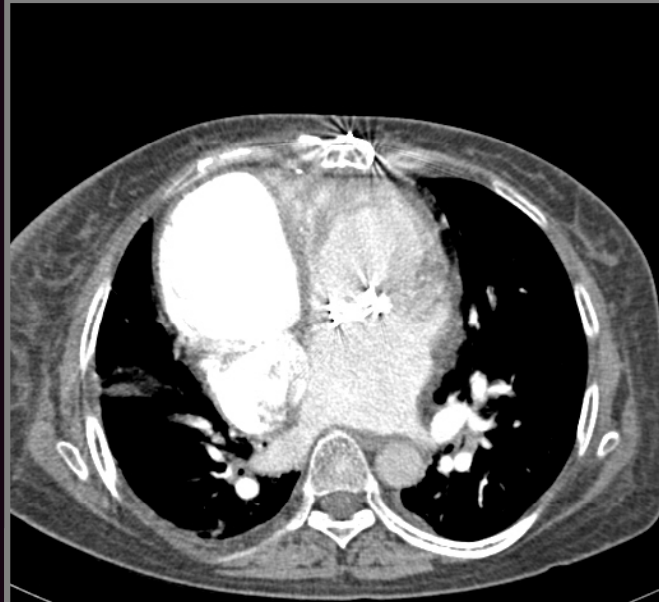Case (54/F)

□ 환자의 심질환과 시행받은 수술은 ?

1. Mirror image dextrocardia with LV dysfunction, MVR & TAP
2. Mirror image dextrocardia with LV dysfunction, TVR & MAP
3. Corrected TGA & dextroversion with LV dysfunction, MVR & TAP
4. Corrected TGA & dextroversion with LV dysfunction, TVR & MAP

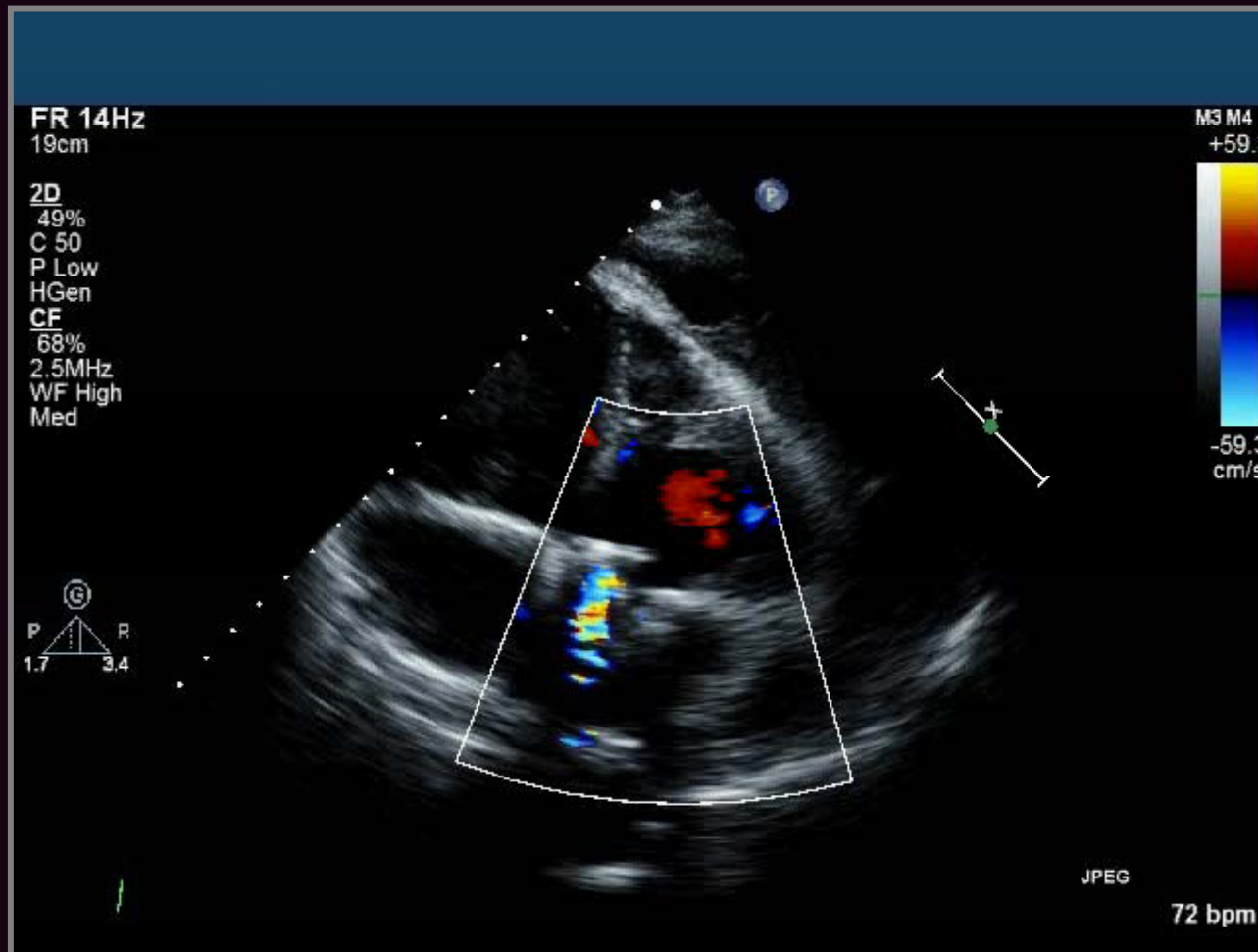
Case (54/F)



Case (54/F)

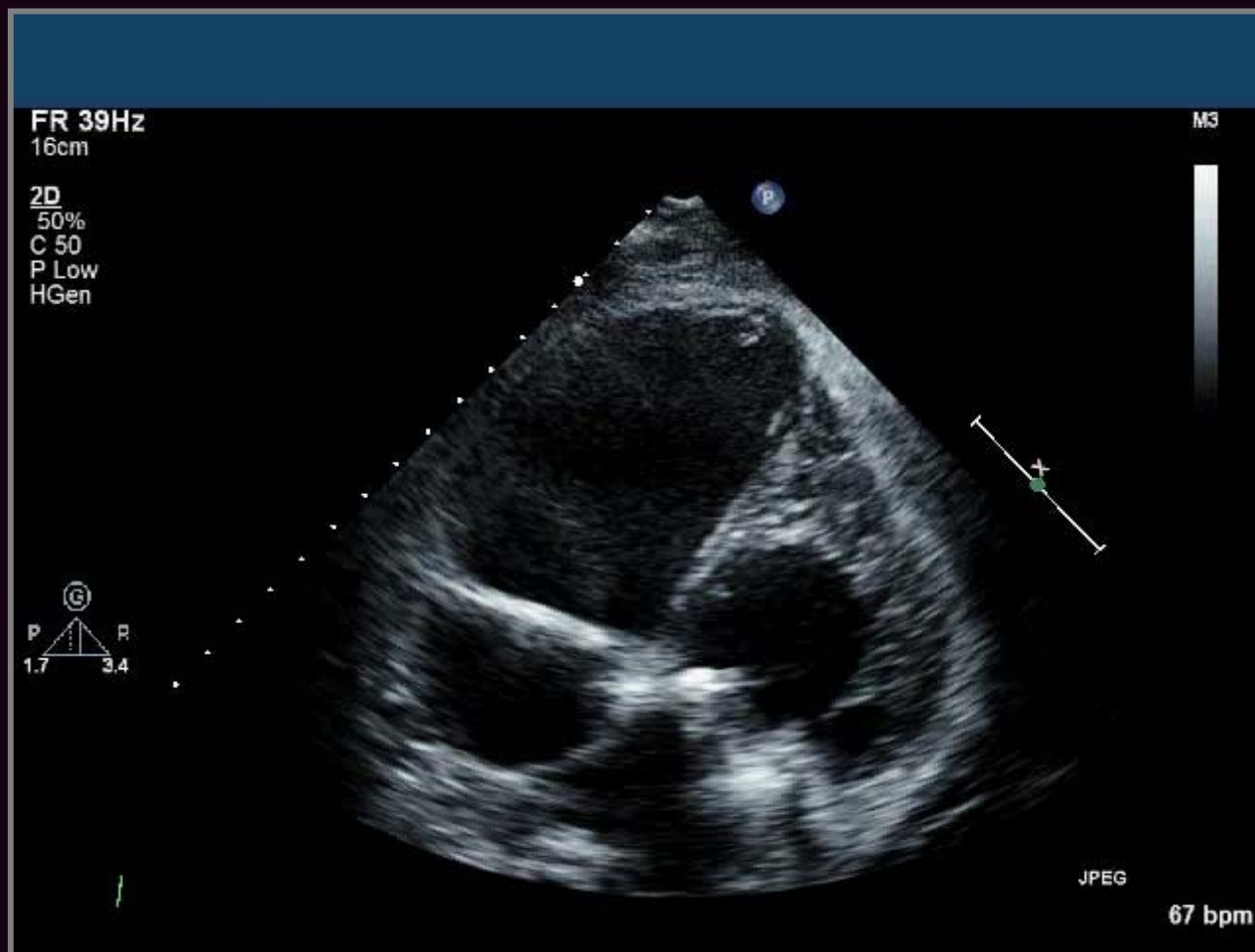
- 이 환자에게 대한 적절한 치료는 ?
 1. Medical follow-up
 2. TV Paravalvular leakage repair
 3. TV Paravalvular leakage repair + MVR
 4. Cardiac transplantation

Case (54/F)



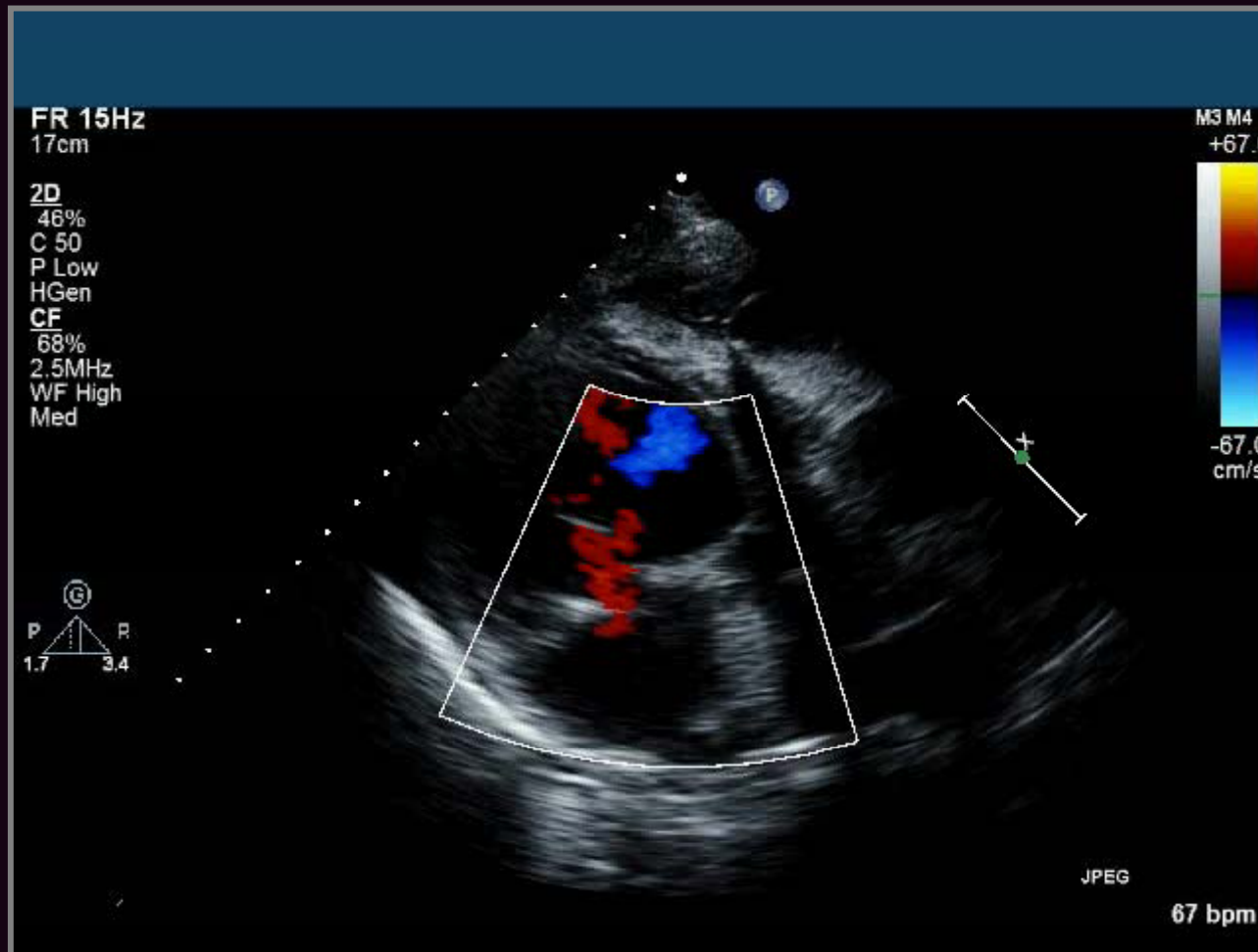2 months after TV Paravalvular leakage repair

Case (54/F)



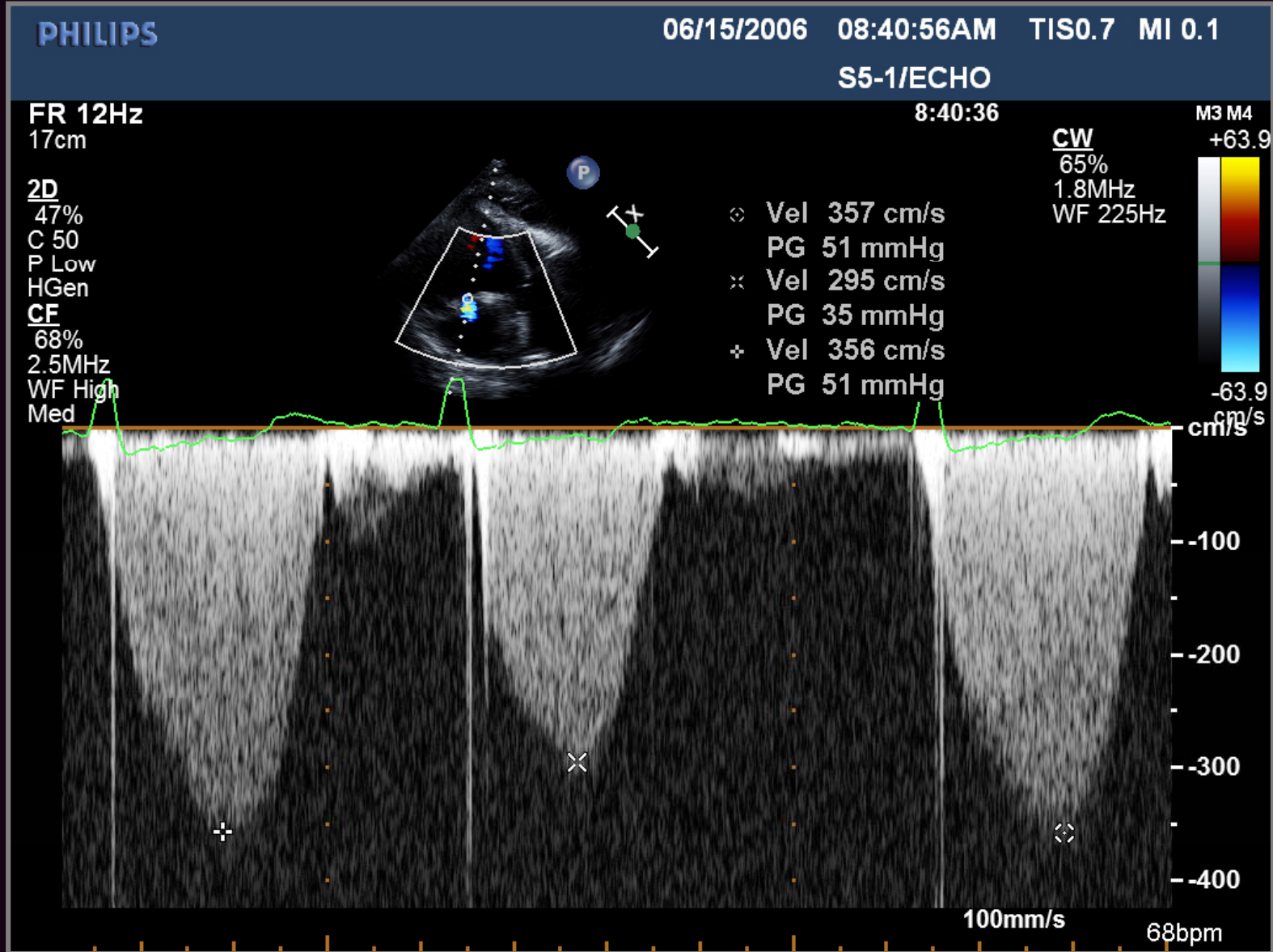
2 months after TV Paravalvular leakage repair

Case (54/F)

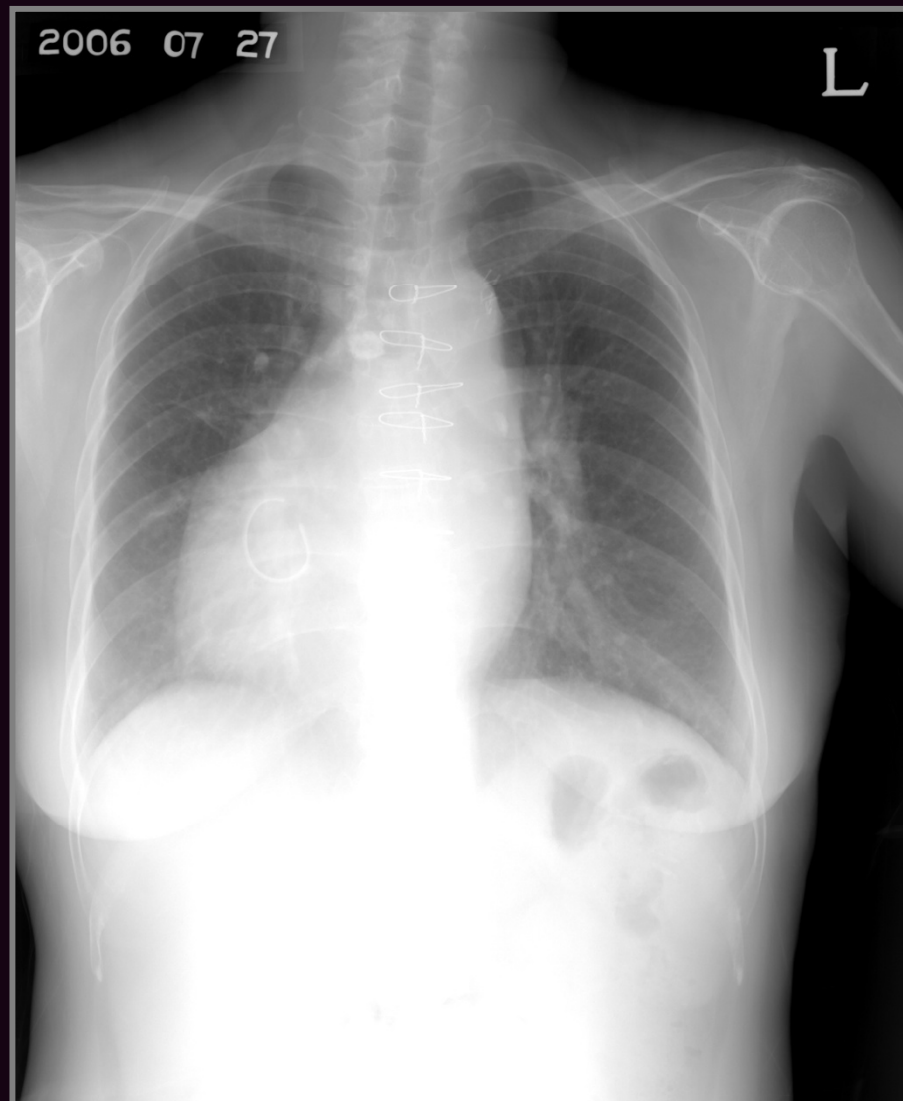
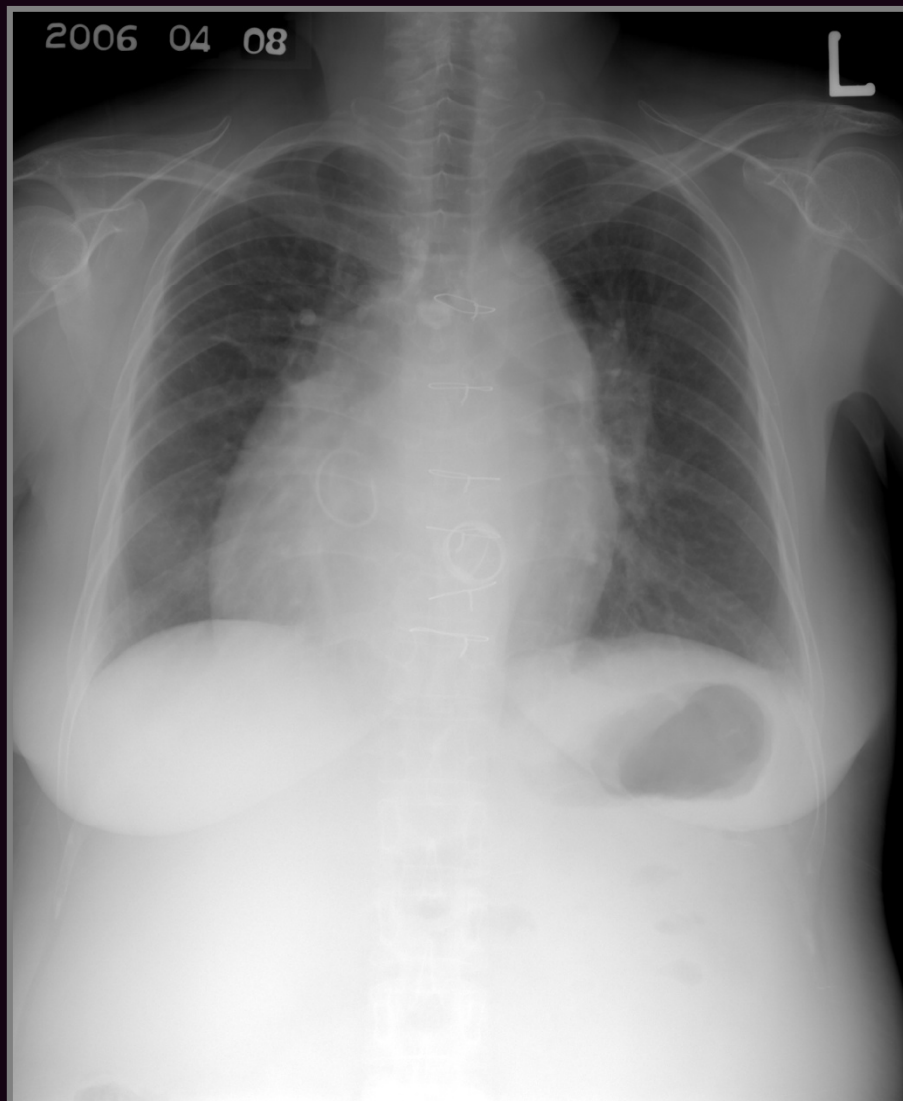
2 months after TV Paravalvular leakage repair

Case (54/F)



Case (54/F)



Thank you for your attention.

