




**Why do we need 3D?**  
**-Case-based learning-**

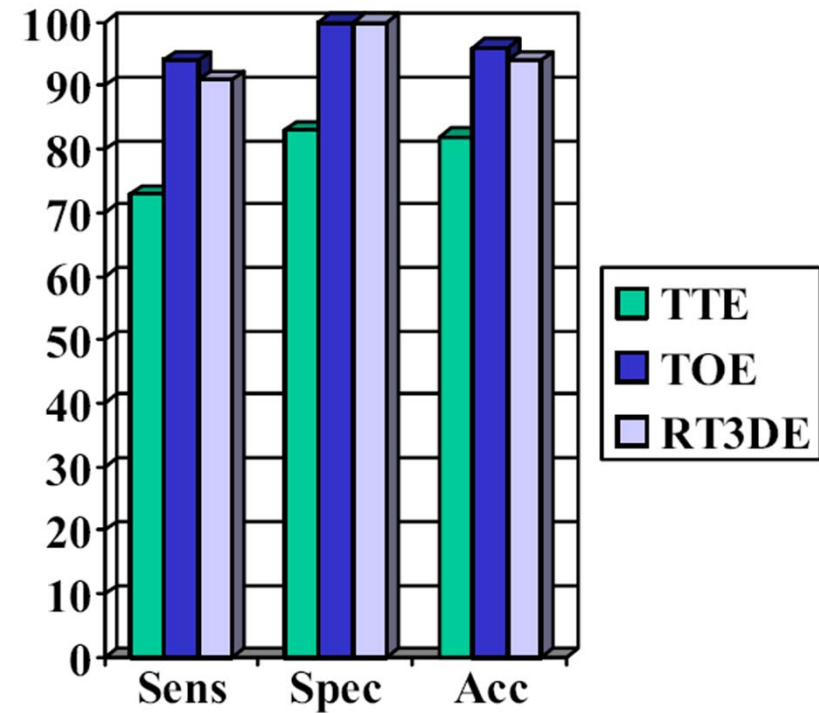
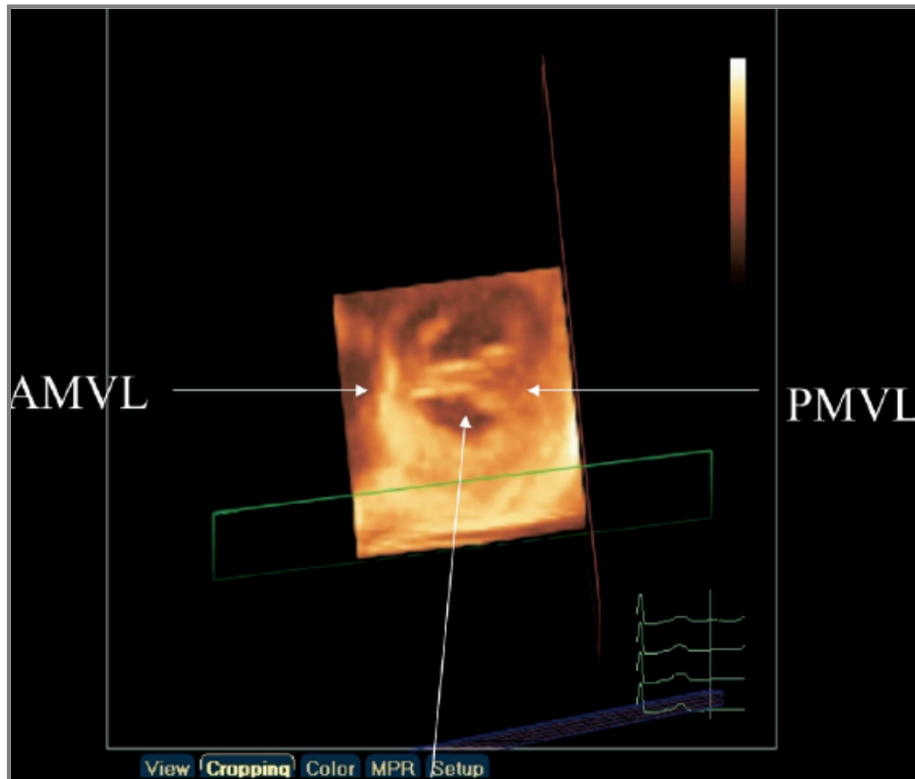
*Jong-Min Song*

*Asan Medical Center  
University of Ulsan College of Medicine*

# 3D, More Informative ?



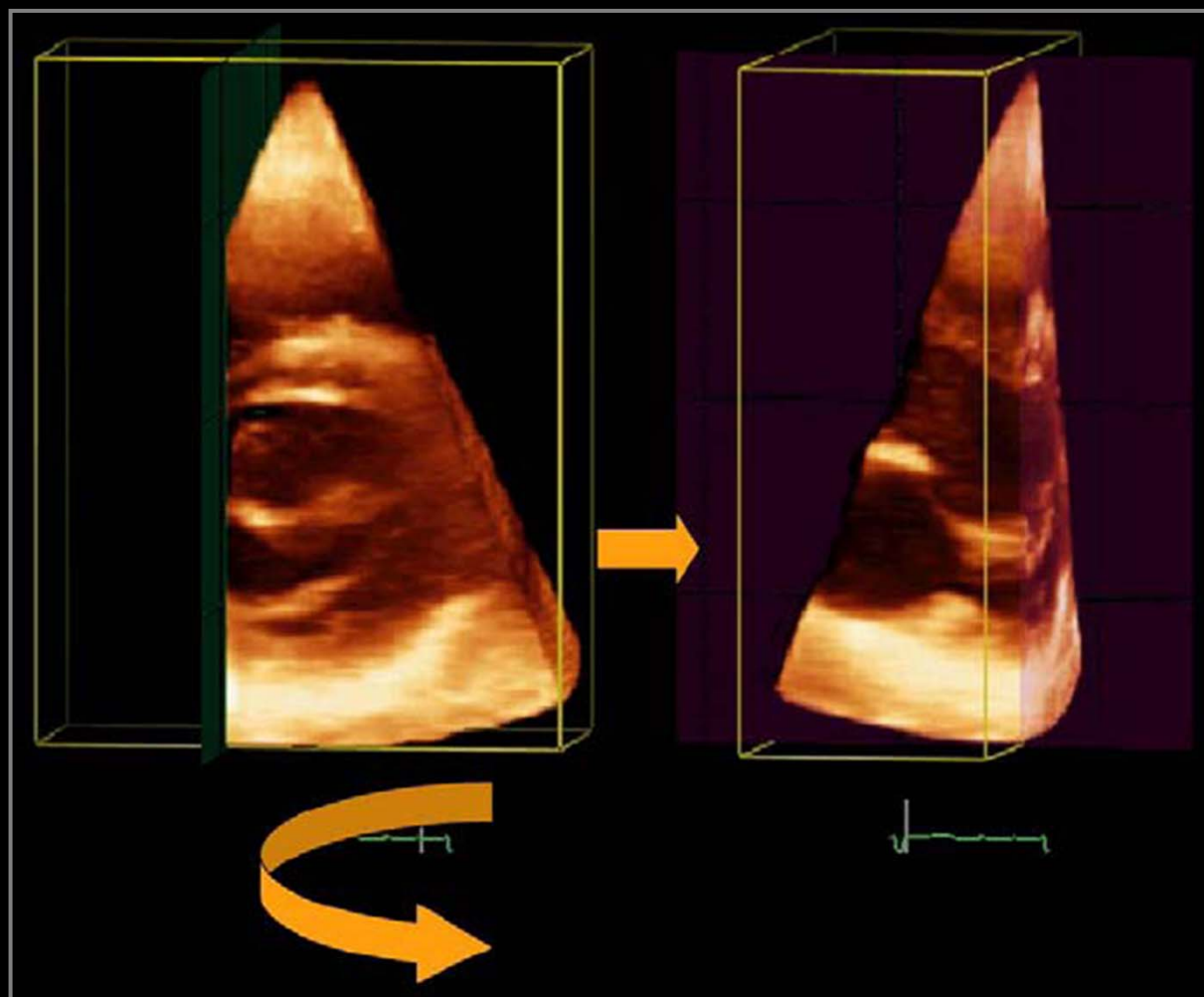
# Mitral Valve Prolapse



RT3DE technique was limited by poor image quality in 11% of patients.

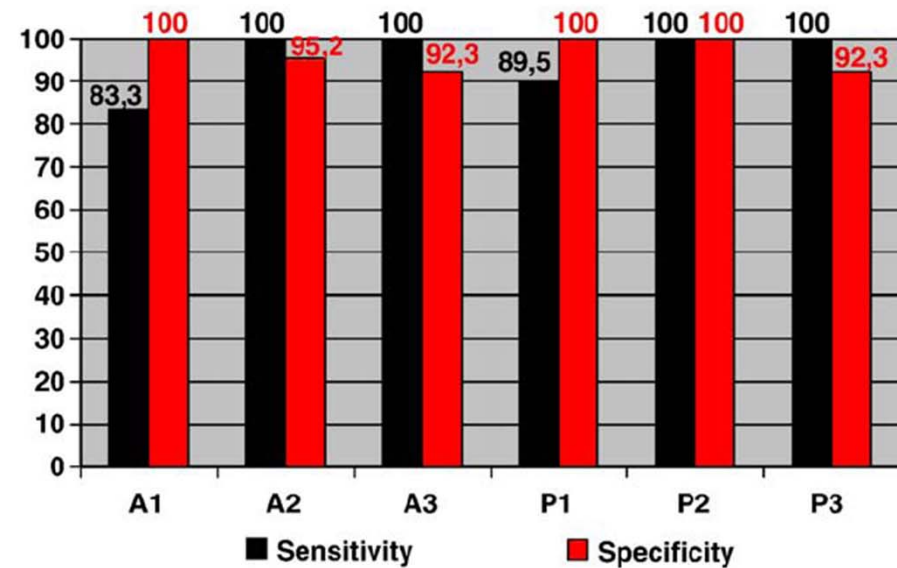
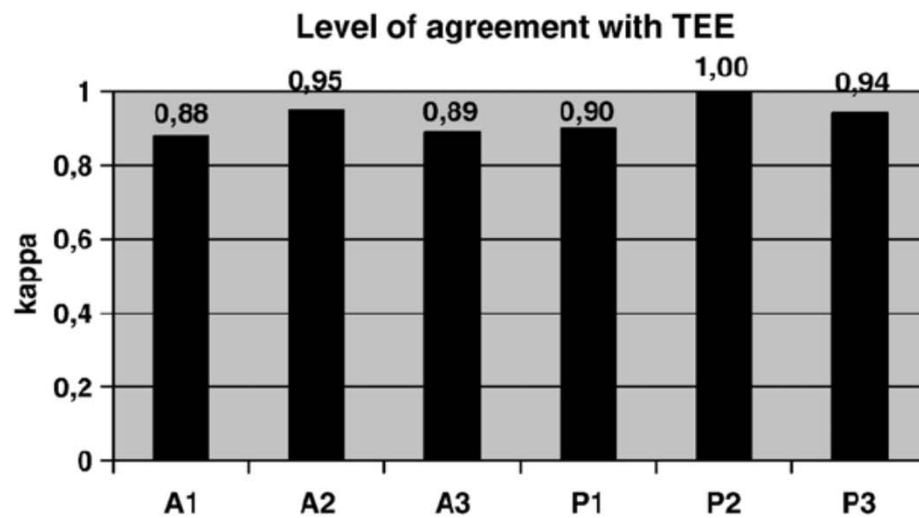
*Sharma R et al. JASE 2007;20:934-40*

# Mitral Valve Prolapse



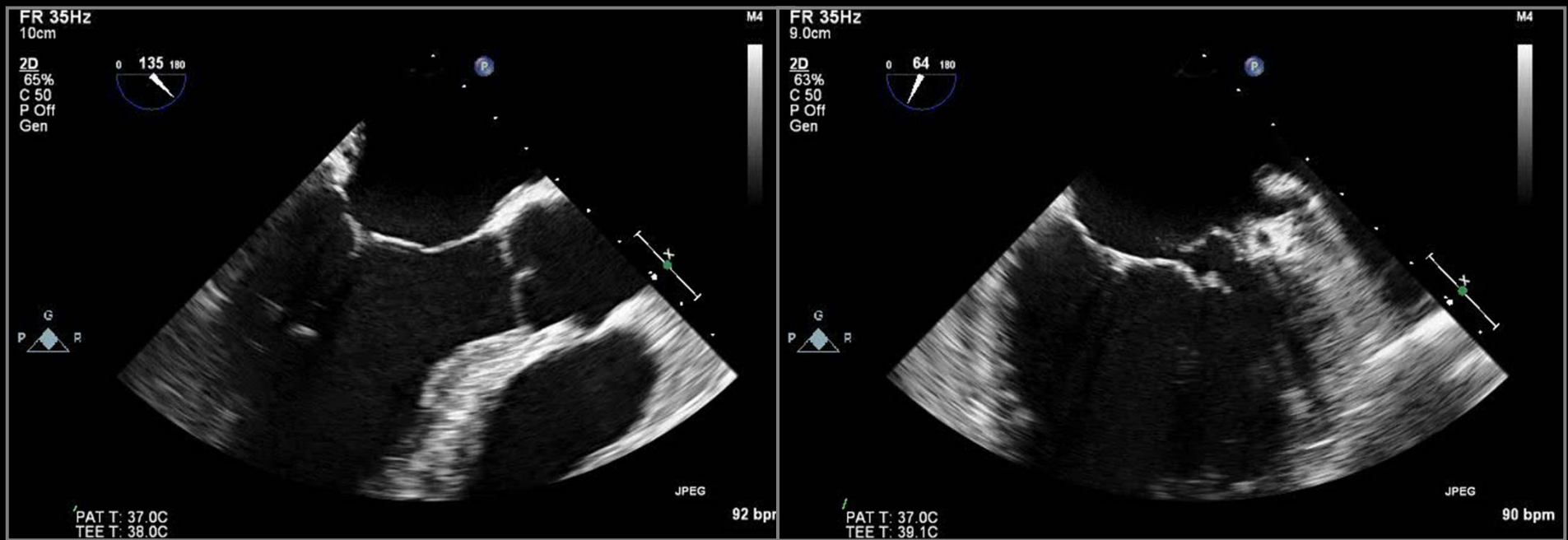
*Gutiérrez-Chico JL et al. Am Heart J 2008;155:694-8*

# Mitral Valve Prolapse

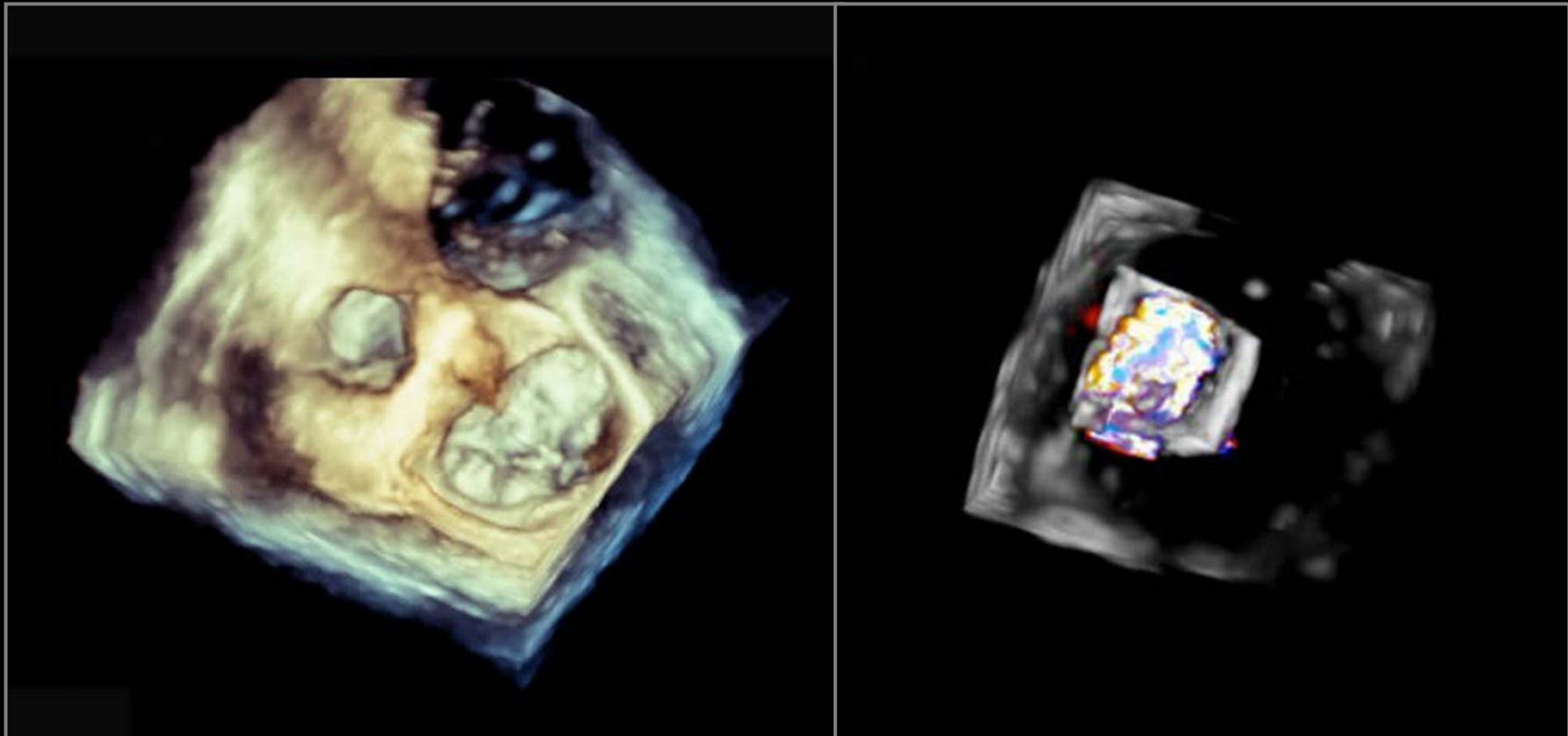


*Gutiérrez-Chico JL et al. Am Heart J 2008;155:694-8*

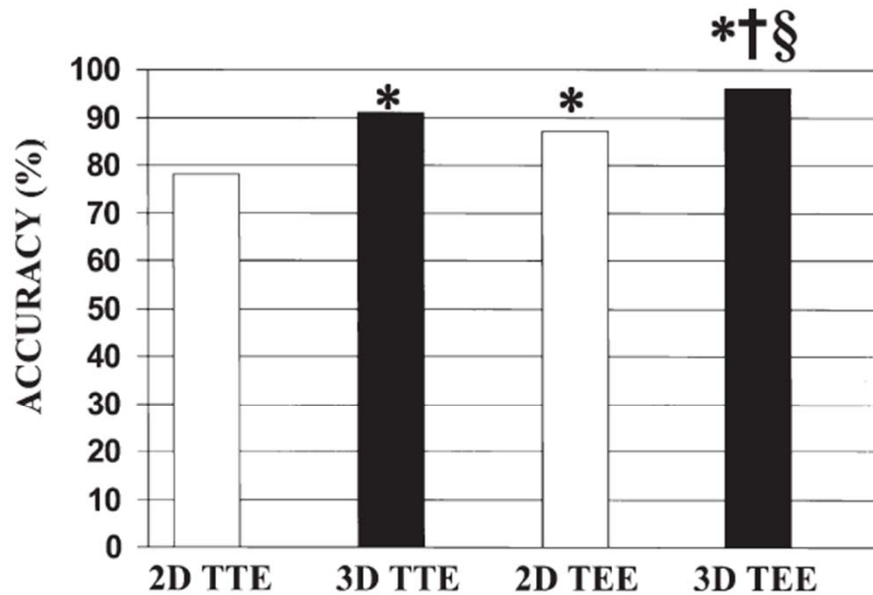
# MV Prolapse Case 1



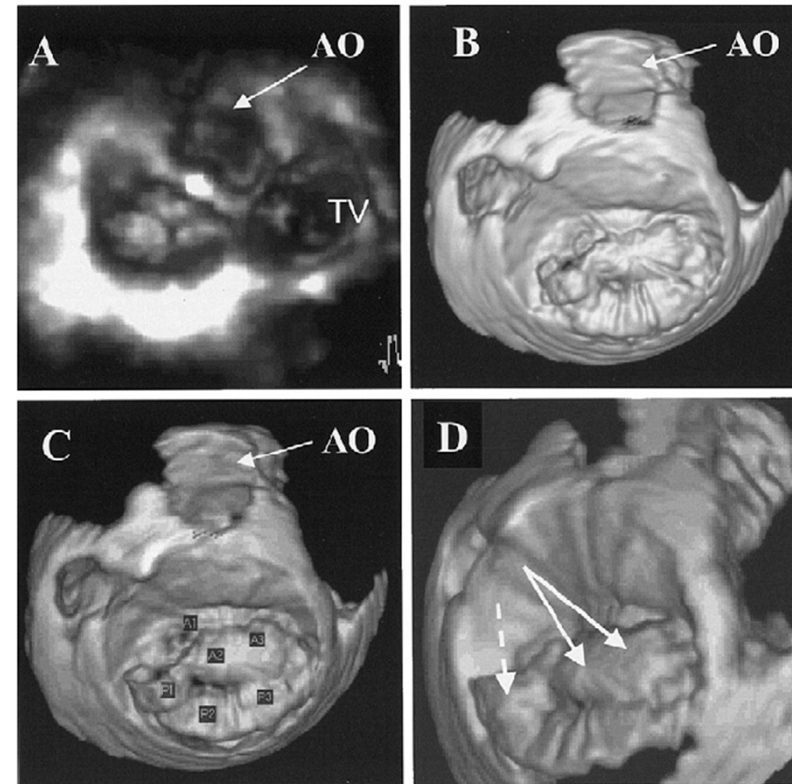
# MV Prolapse Case 1



# MV Prolapse on 3D TEE



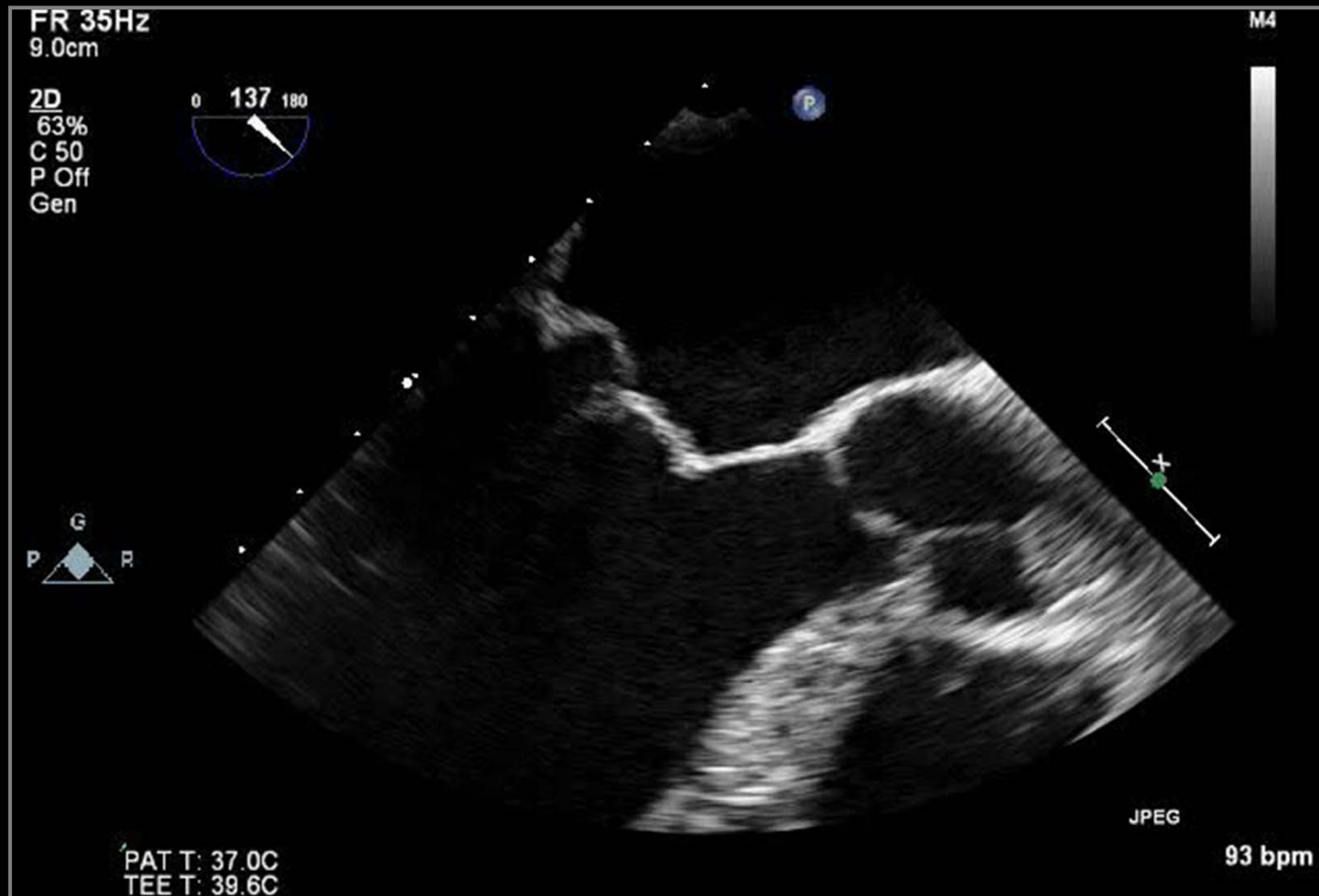**Figure 1.** Overall accuracy of the 4 techniques in the identification of mitral valve pathology. \* $p < 0.001$  versus 2D TTE; † $p < 0.001$  versus 3D TTE; § $p < 0.001$  versus 2D TEE. 2D = two-dimensional; 3D = three-dimensional; TEE = transesophageal echocardiography; TTE = transthoracic echocardiography.



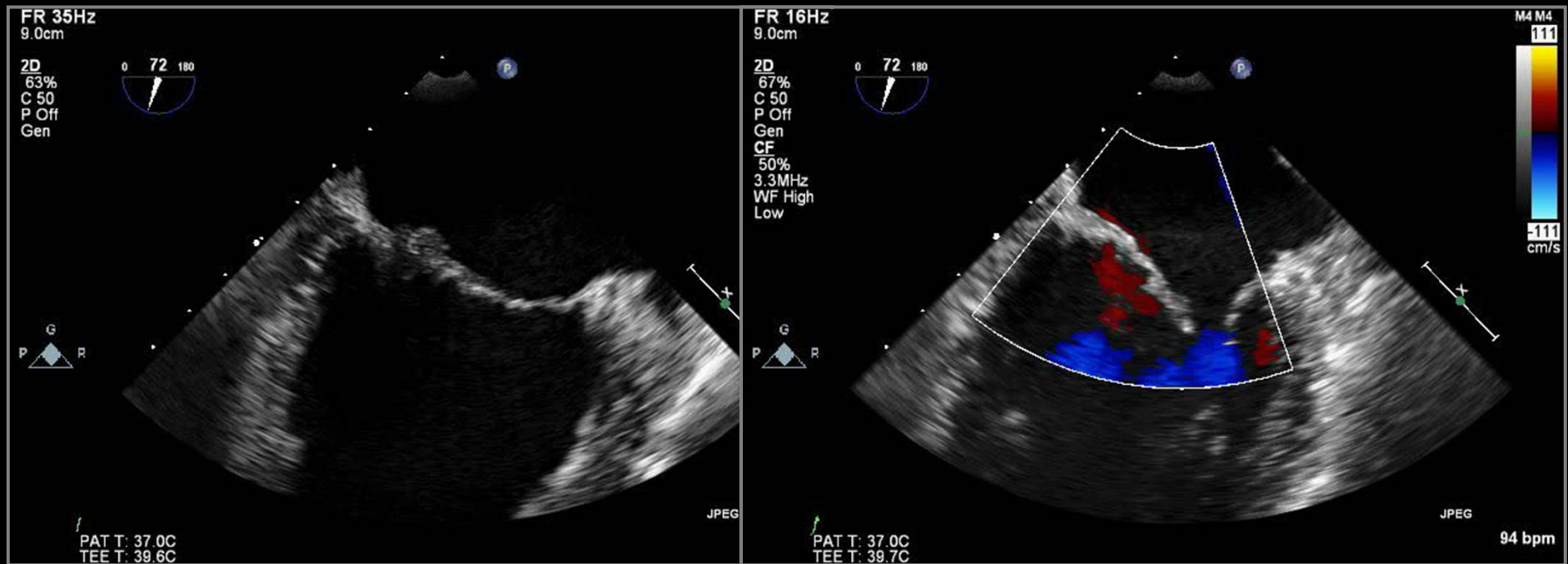
*Pepi M, JACC 2006;48:2524-30*



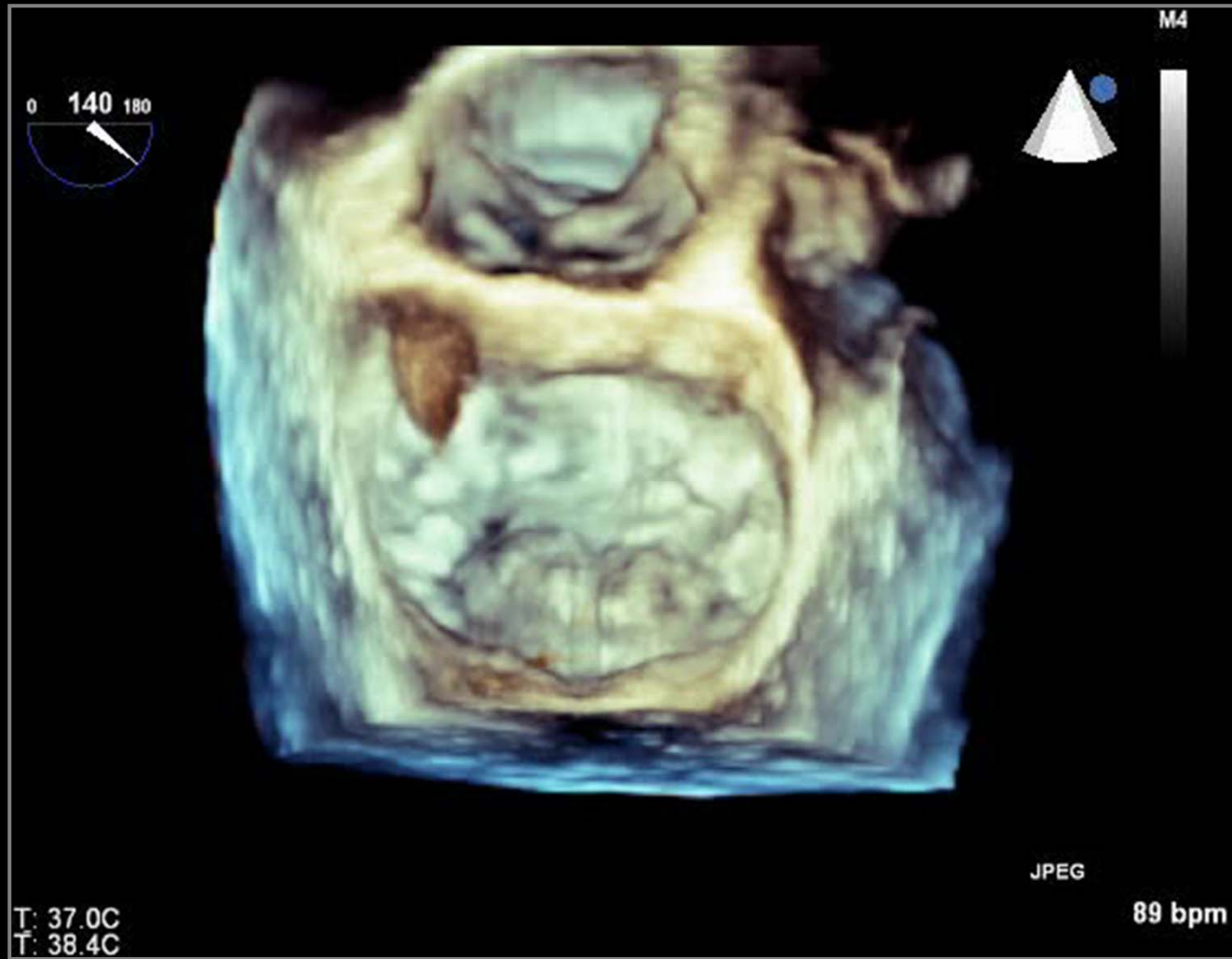# MV Prolapse Case 2



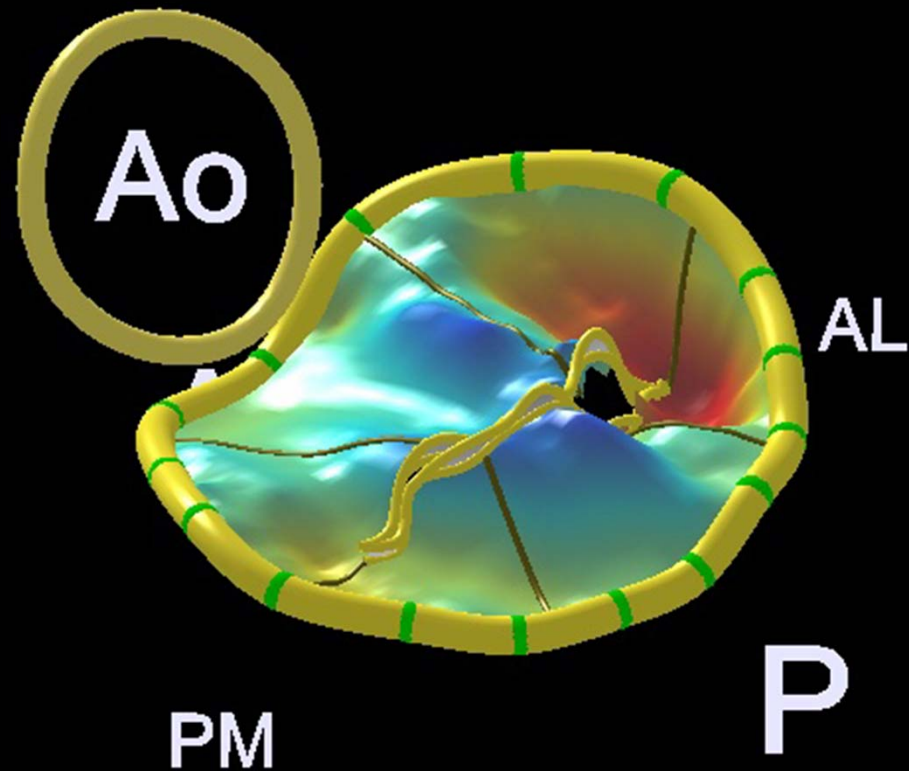
# MV Prolapse Case 2



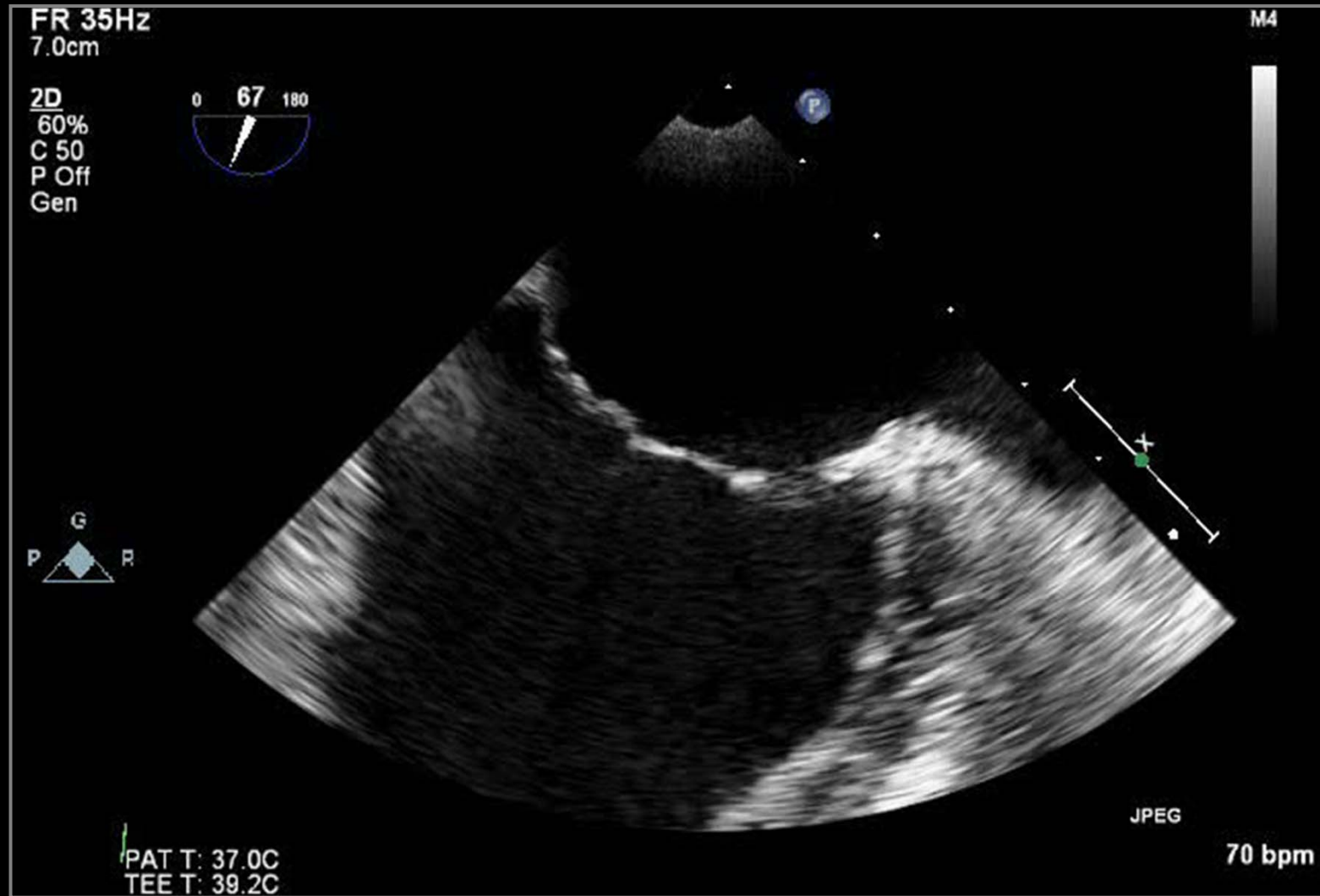
# MV Prolapse Case 2



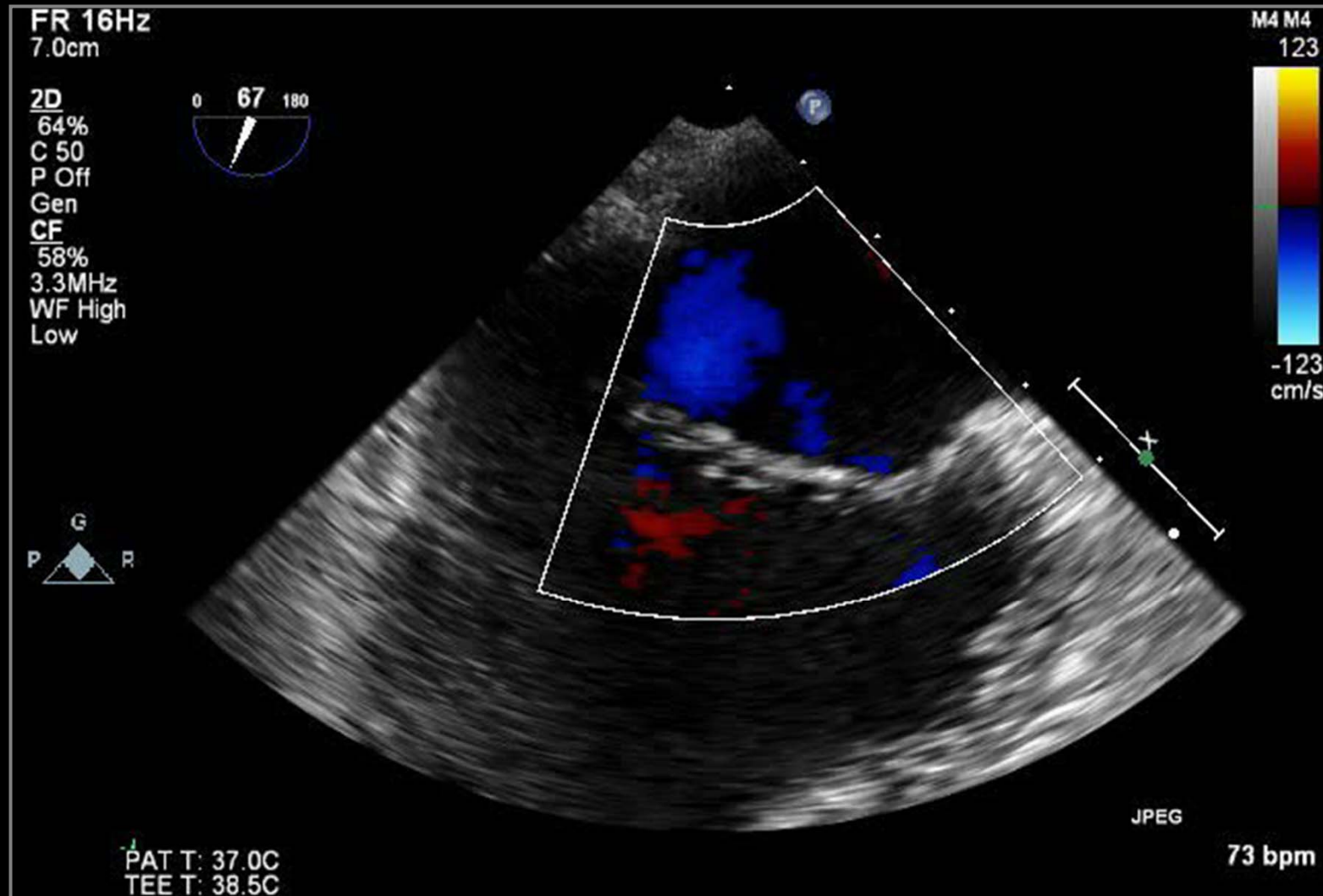
# Mitral Valve Prolapse



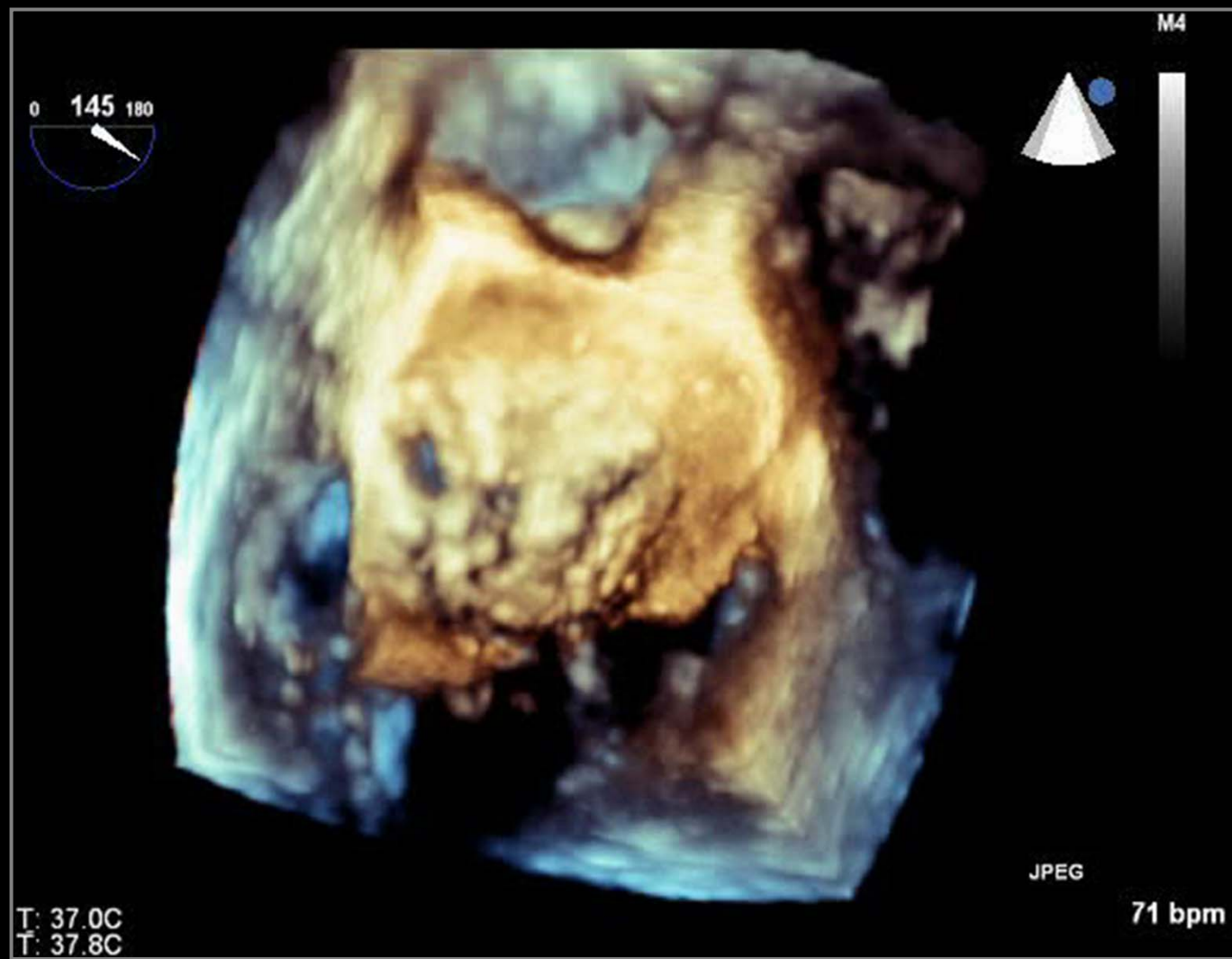
# s/p LA Myxoma Removal



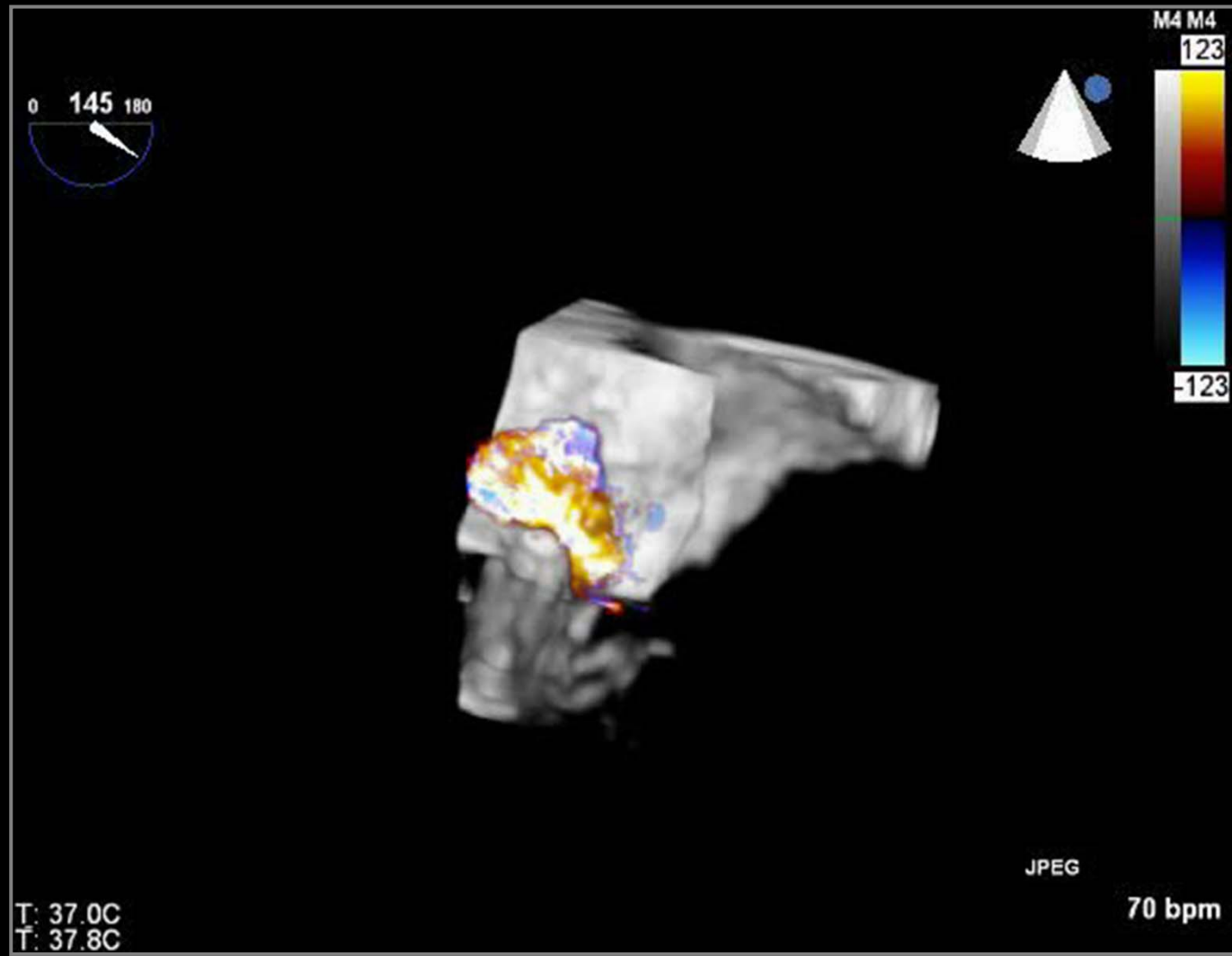
# s/p LA Myxoma Removal



# s/p LA Myxoma Removal

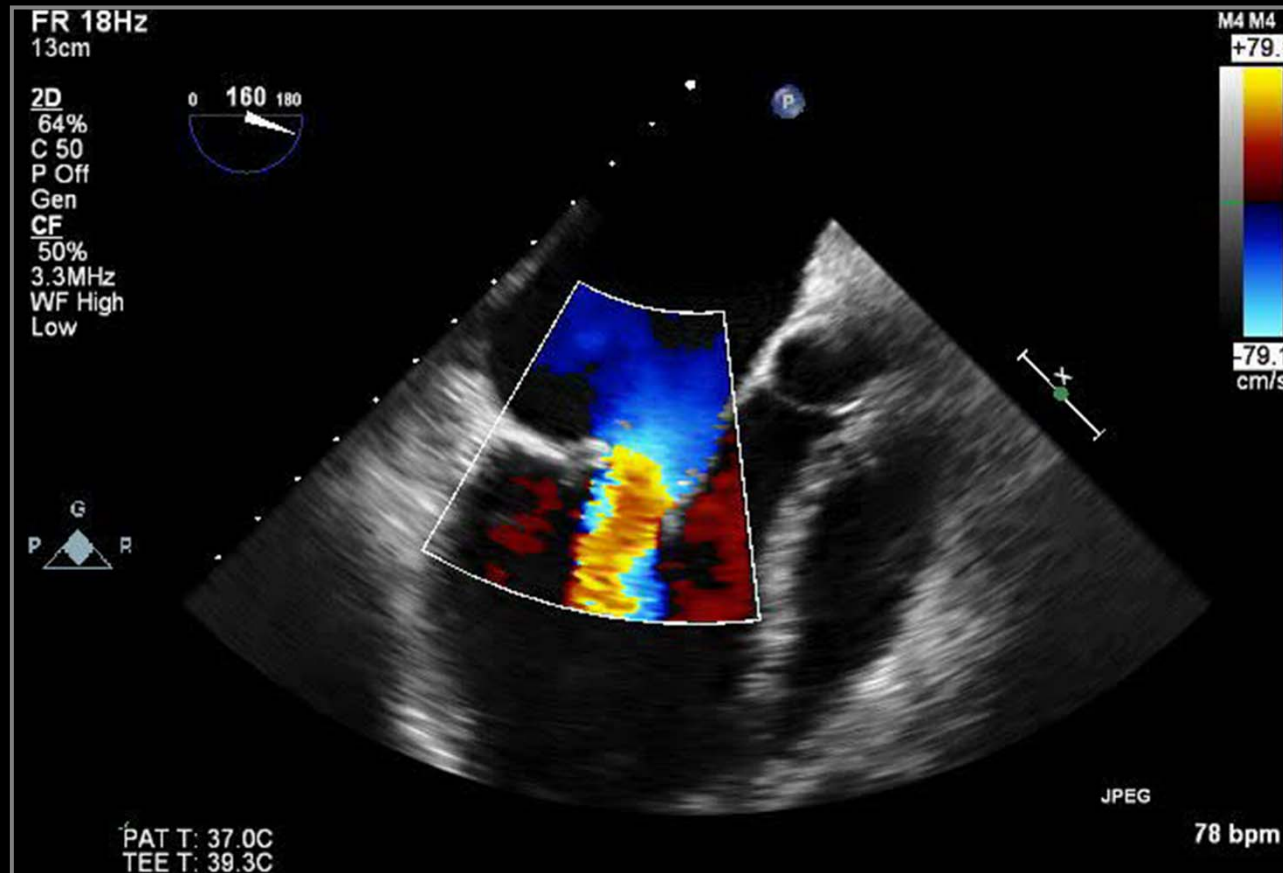


# s/p LA Myxoma Removal

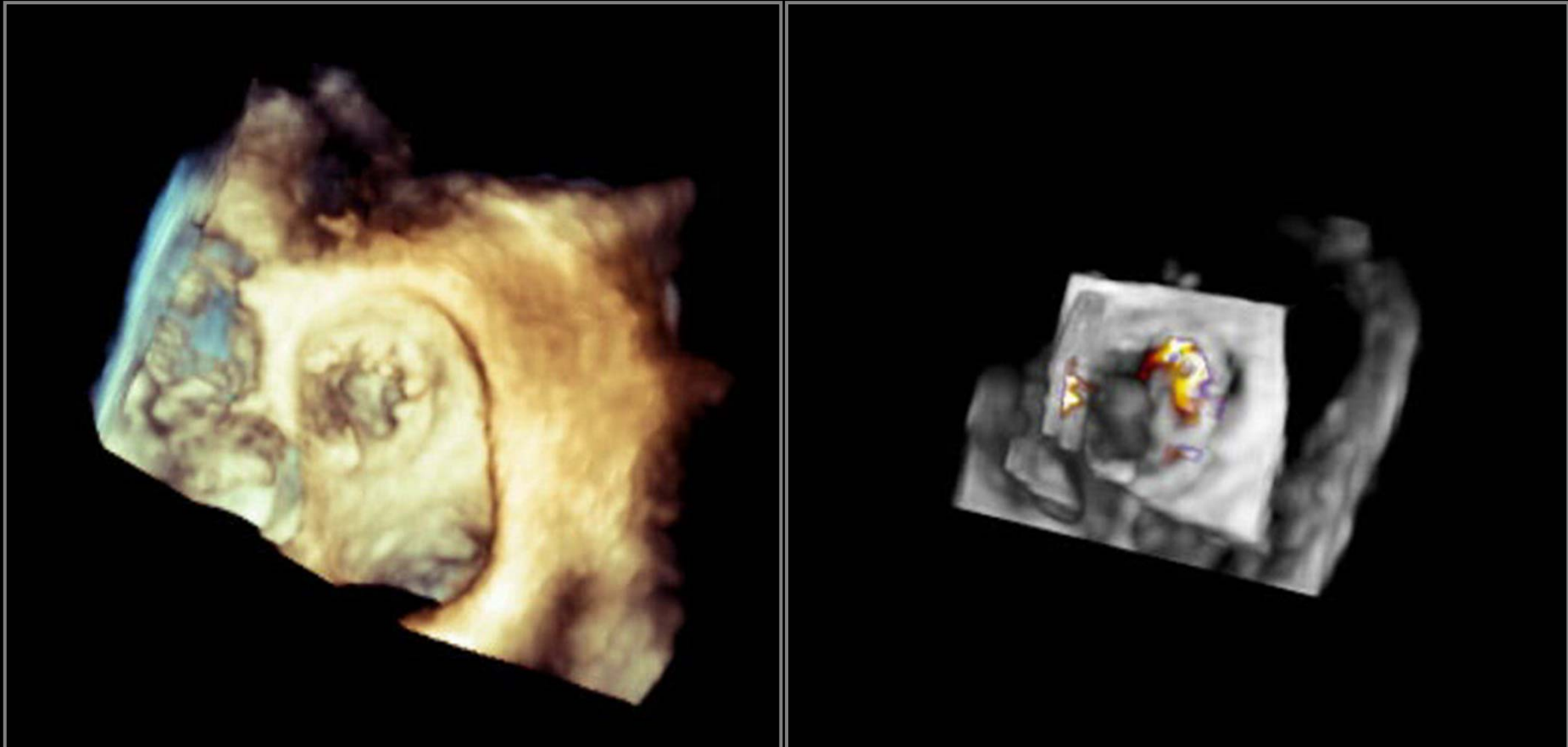




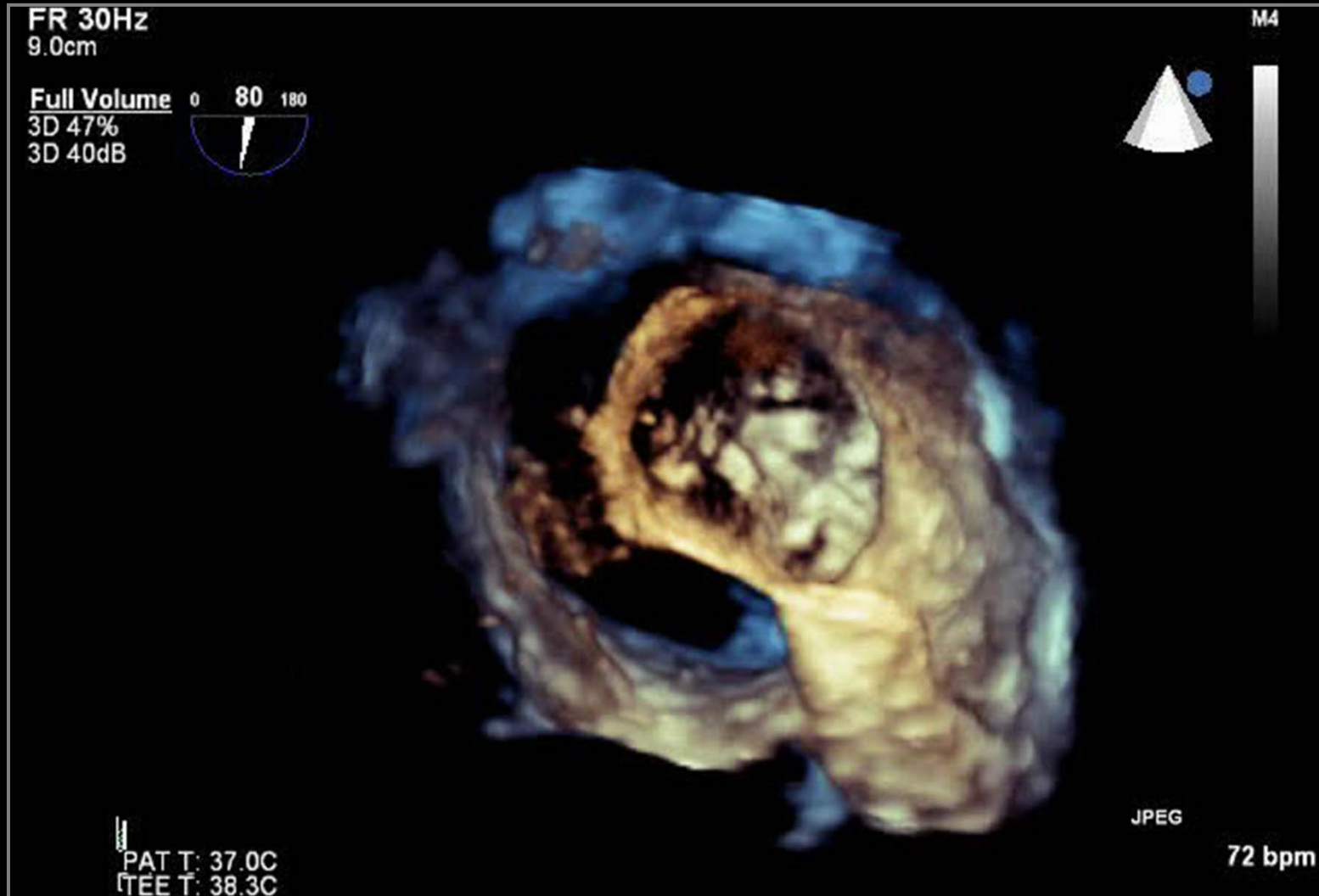
# Pararating Leakage



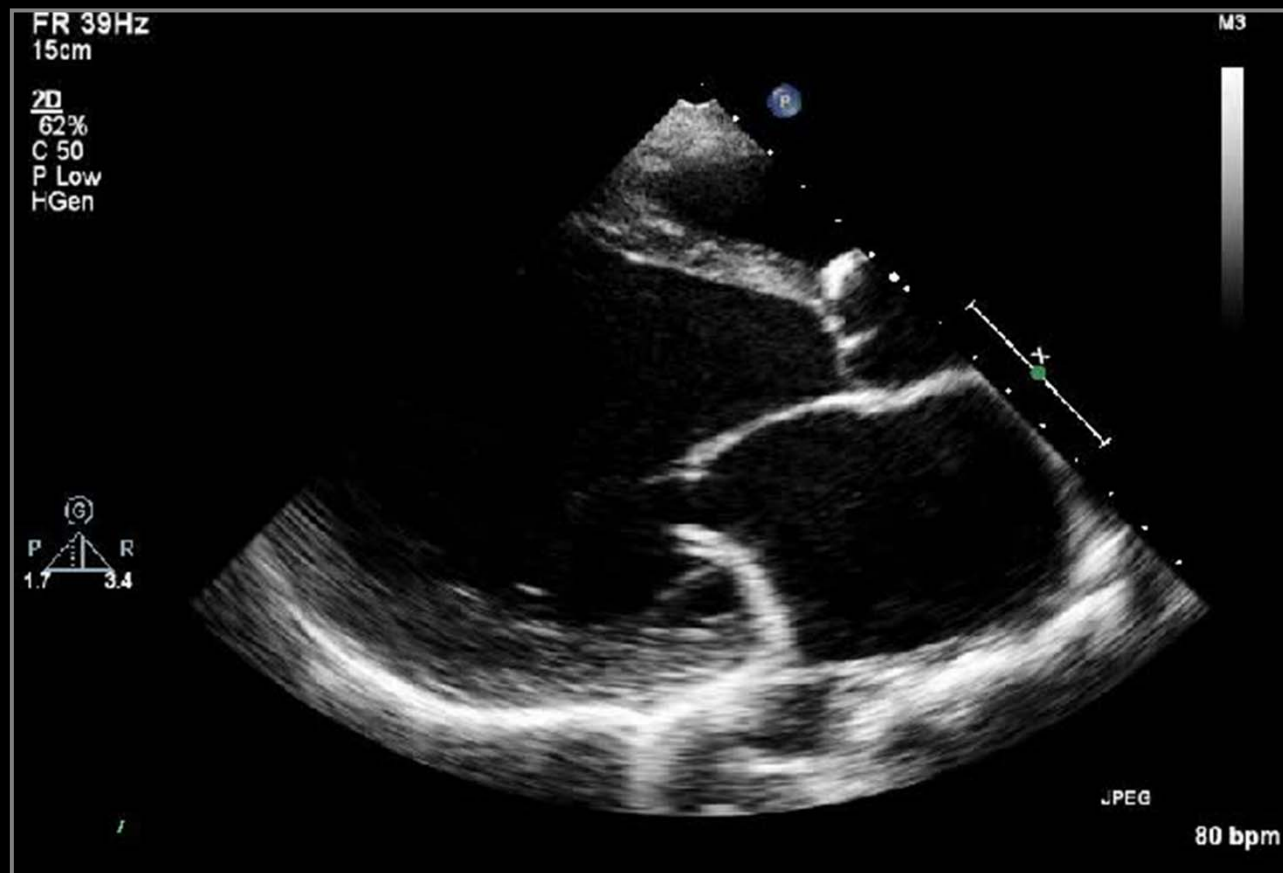# Pararing Leakage



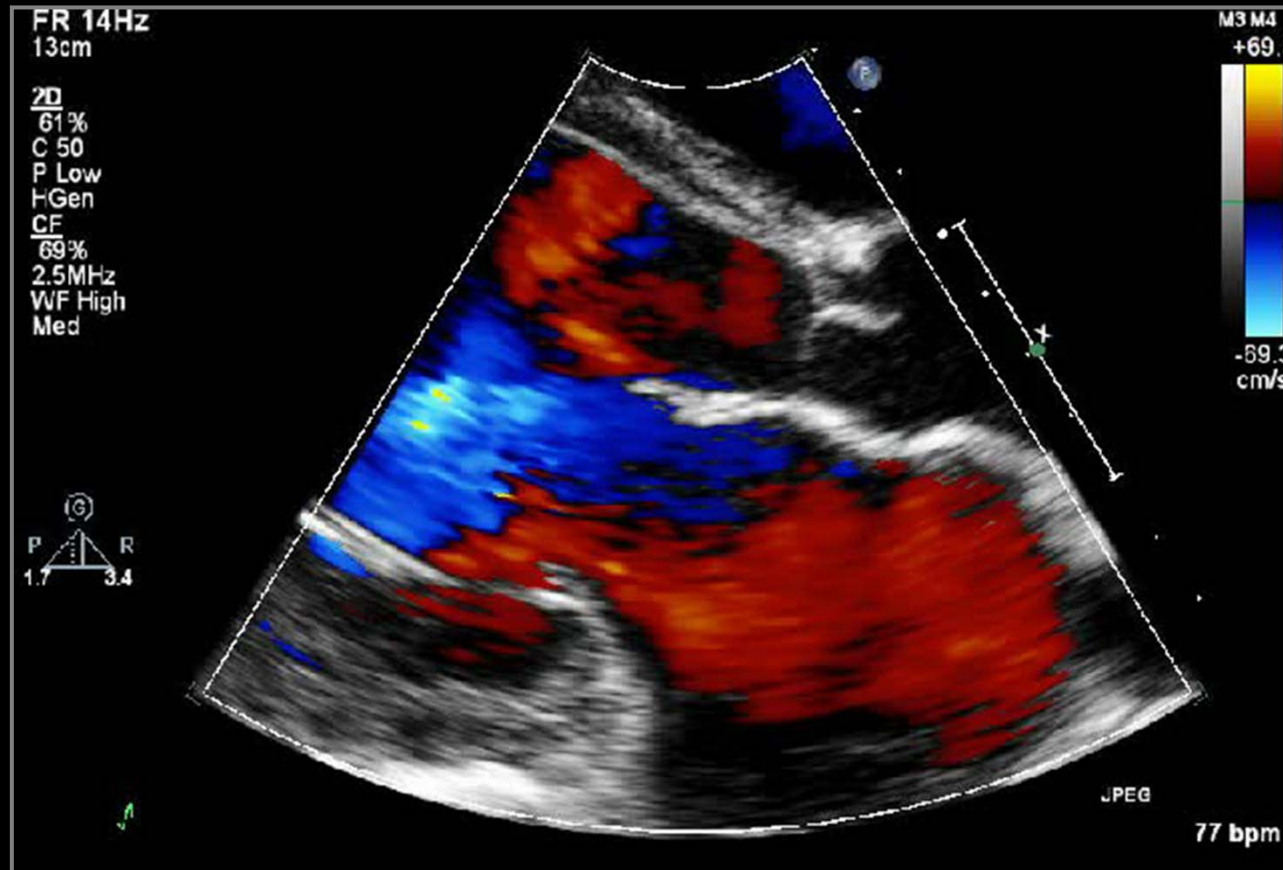
# Double-Orifice MV



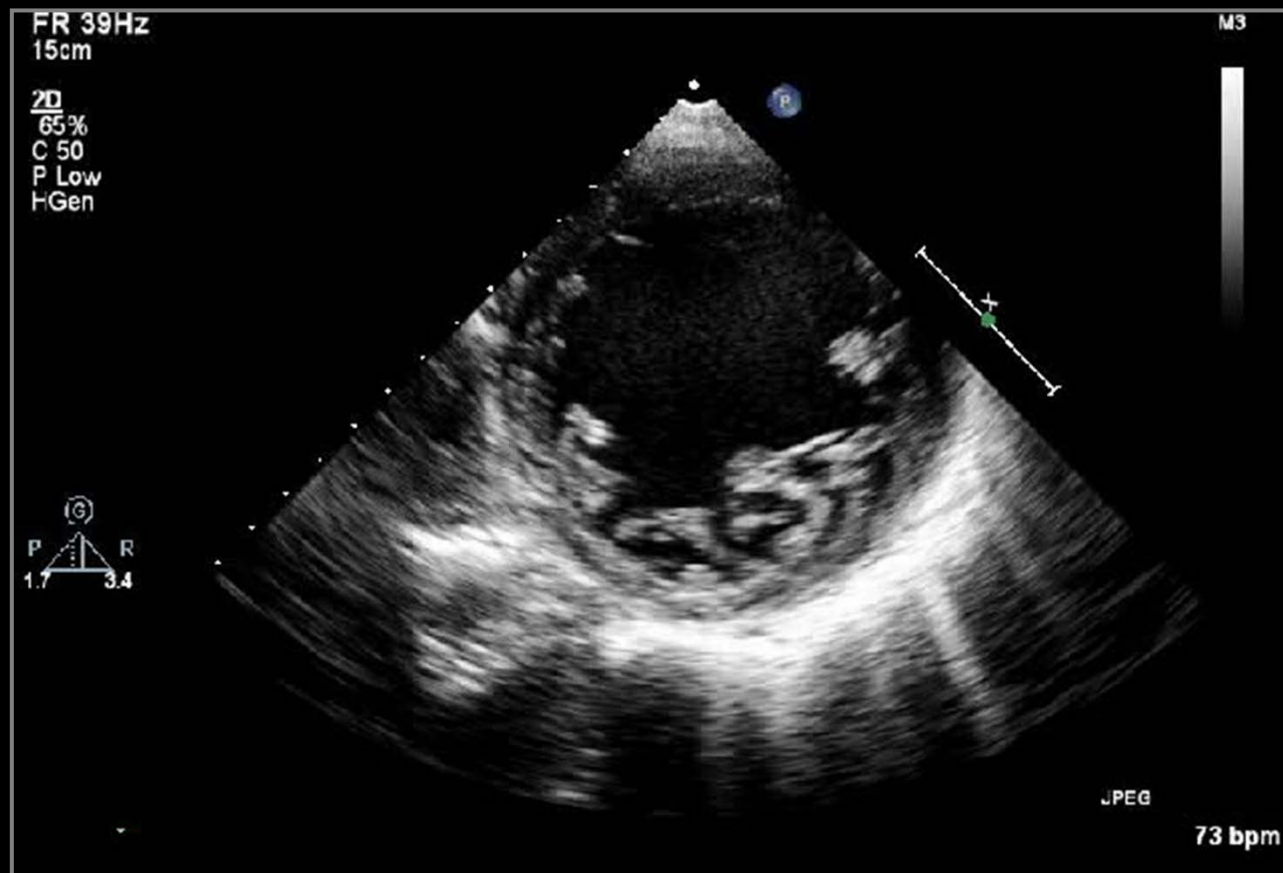
# Cause of Severe MR



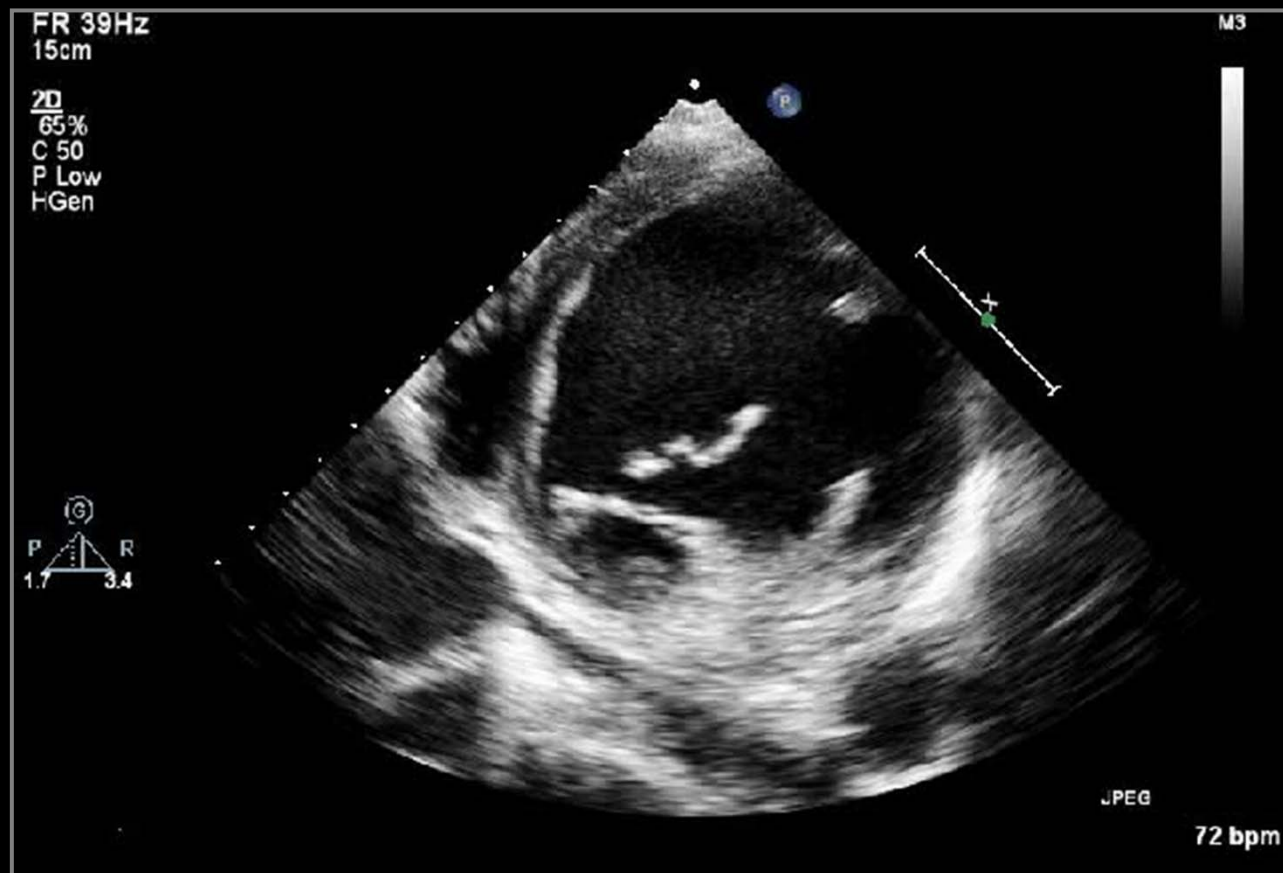
# Cause of Severe MR



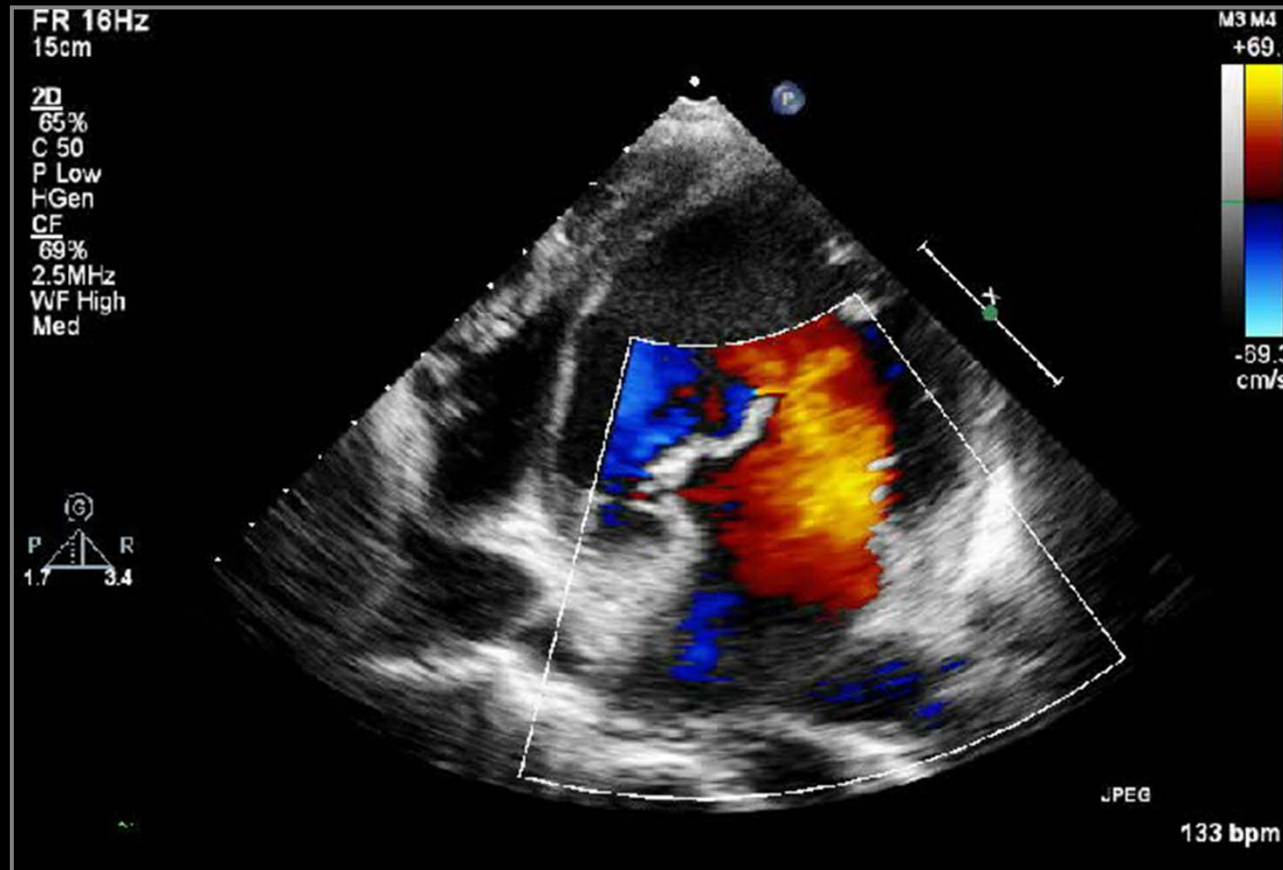
# Cause of Severe MR



# Cause of Severe MR

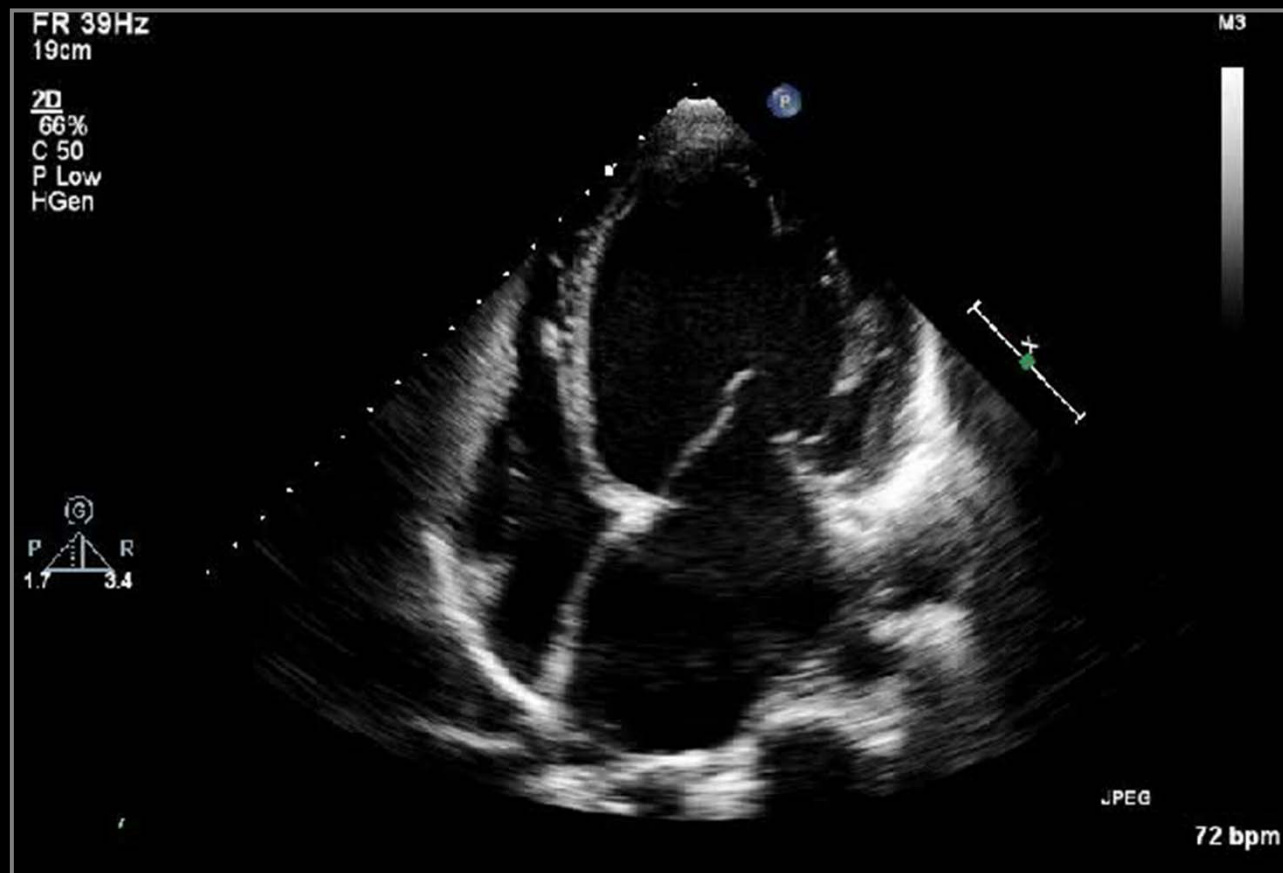


# Cause of Severe MR

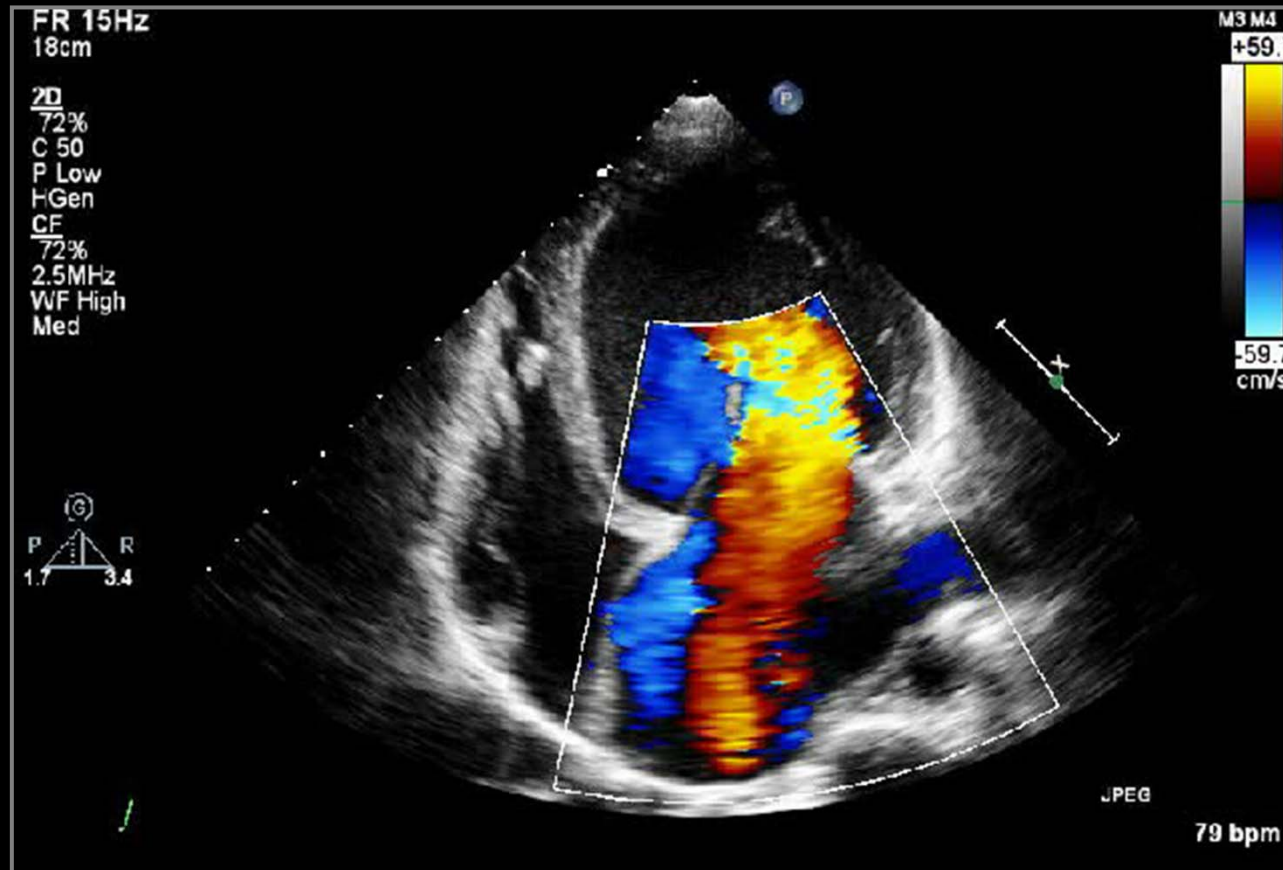




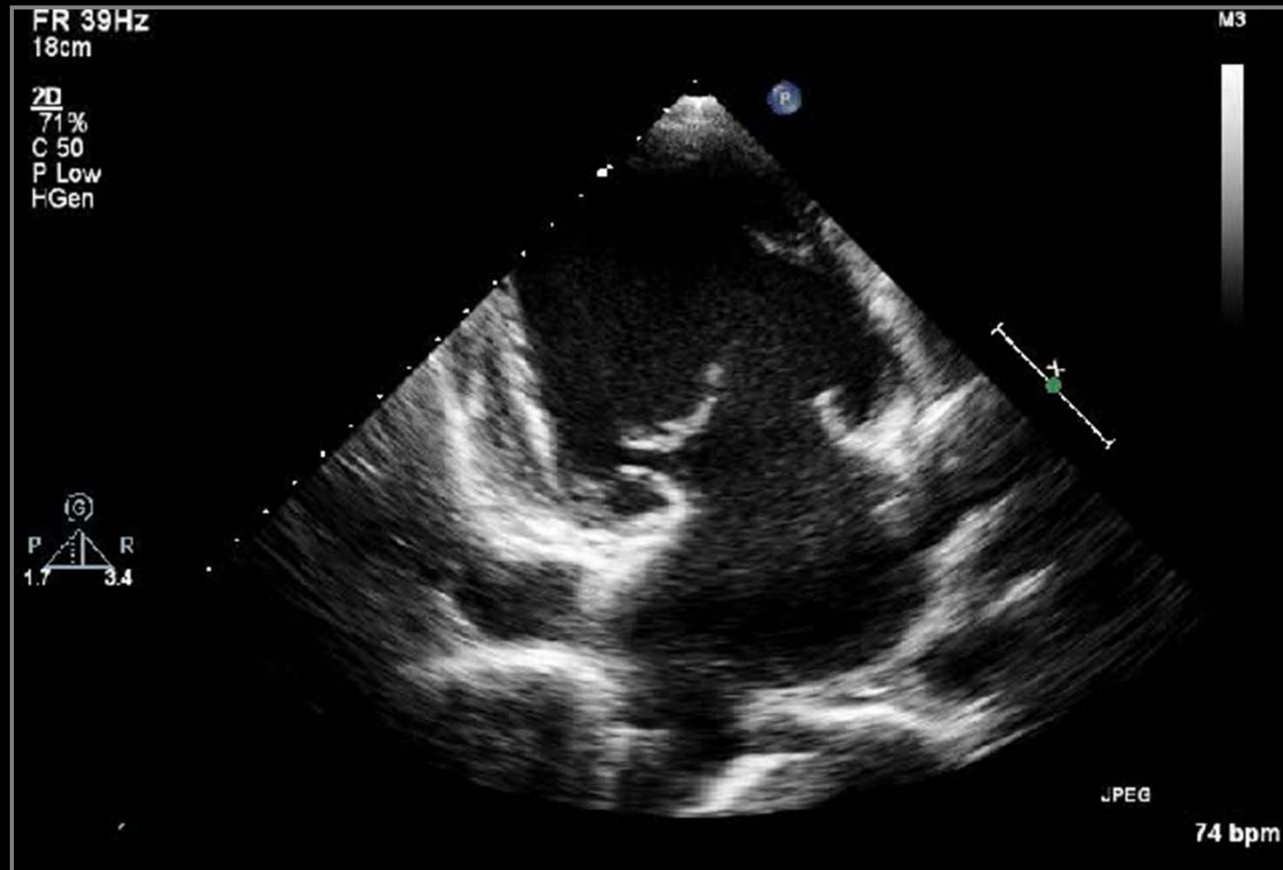
# Cause of Severe MR



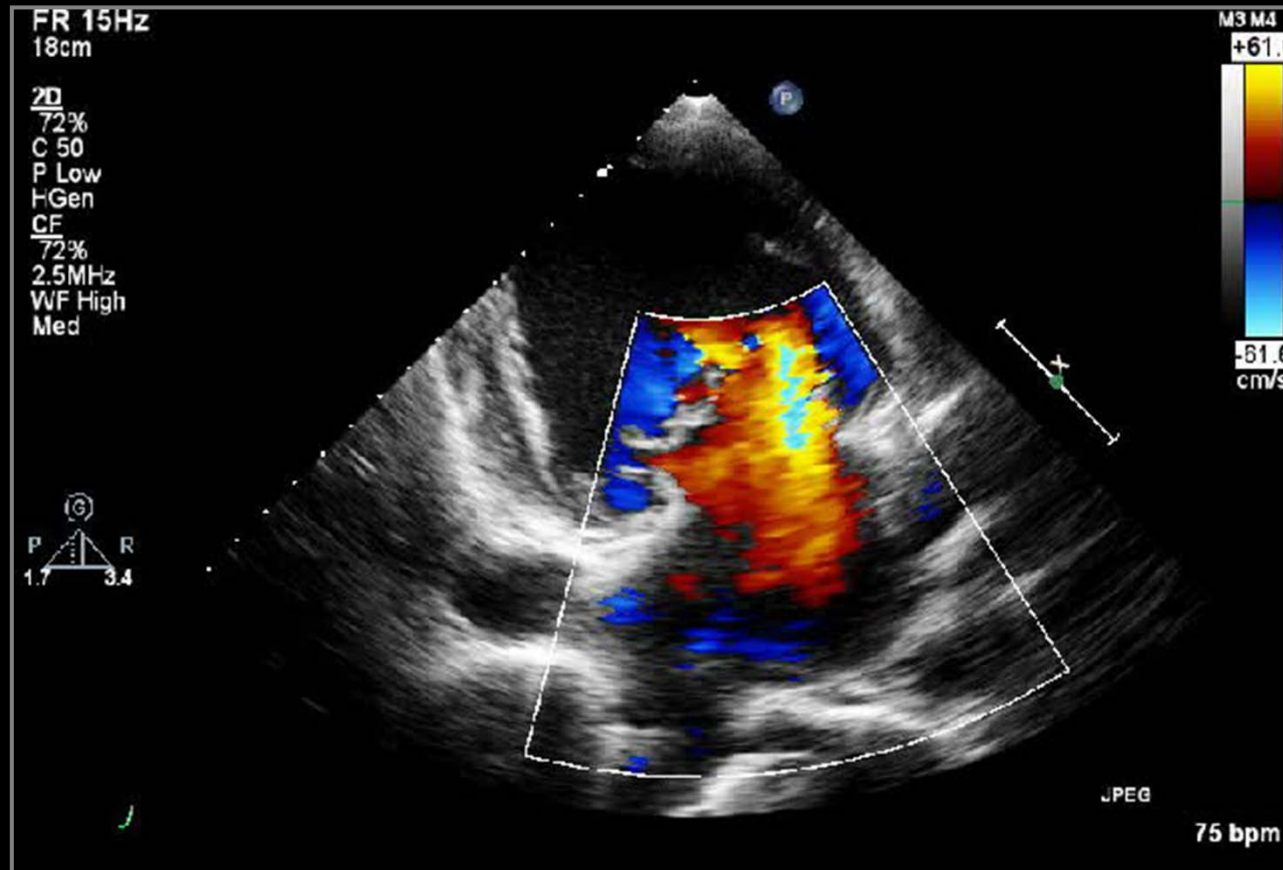
# Cause of Severe MR



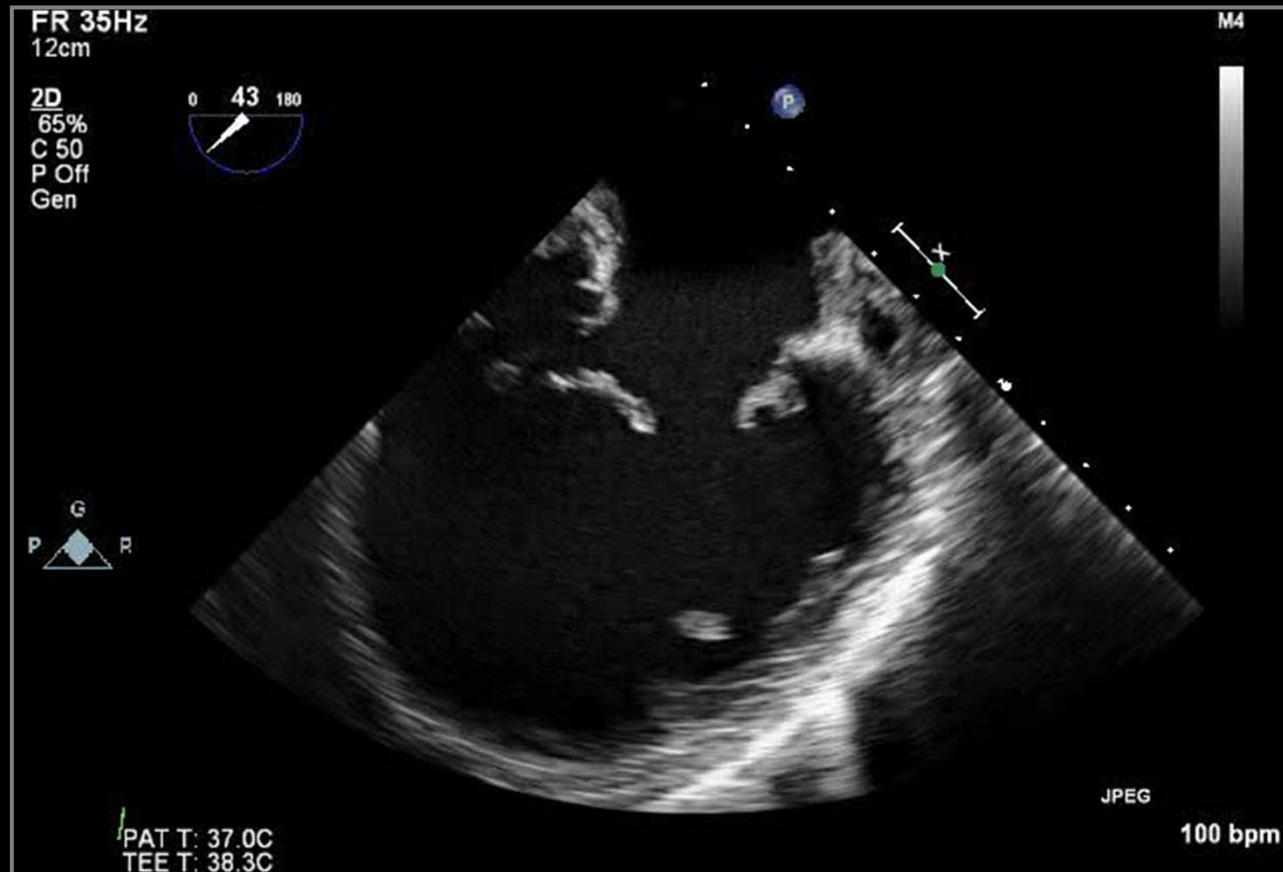
# Cause of Severe MR



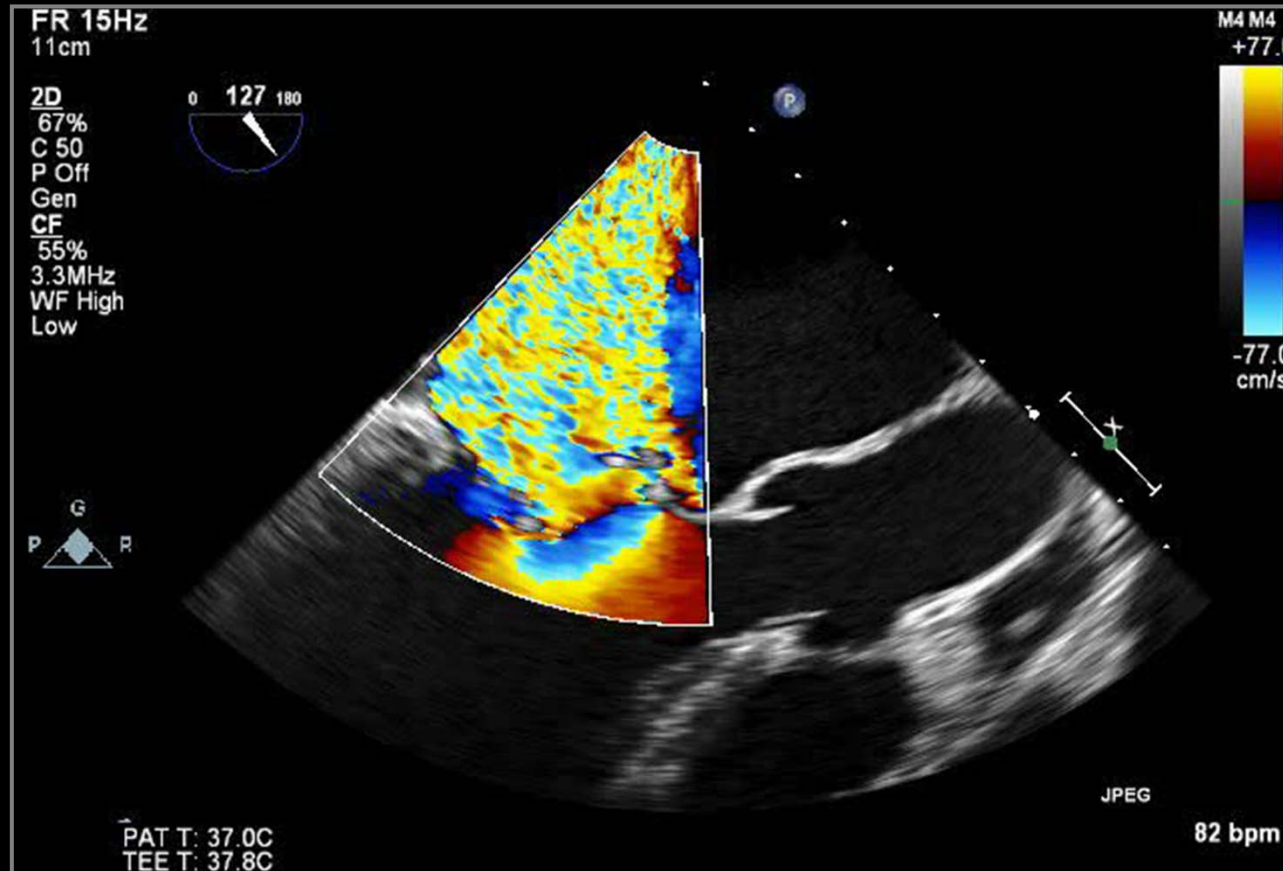
# Cause of Severe MR



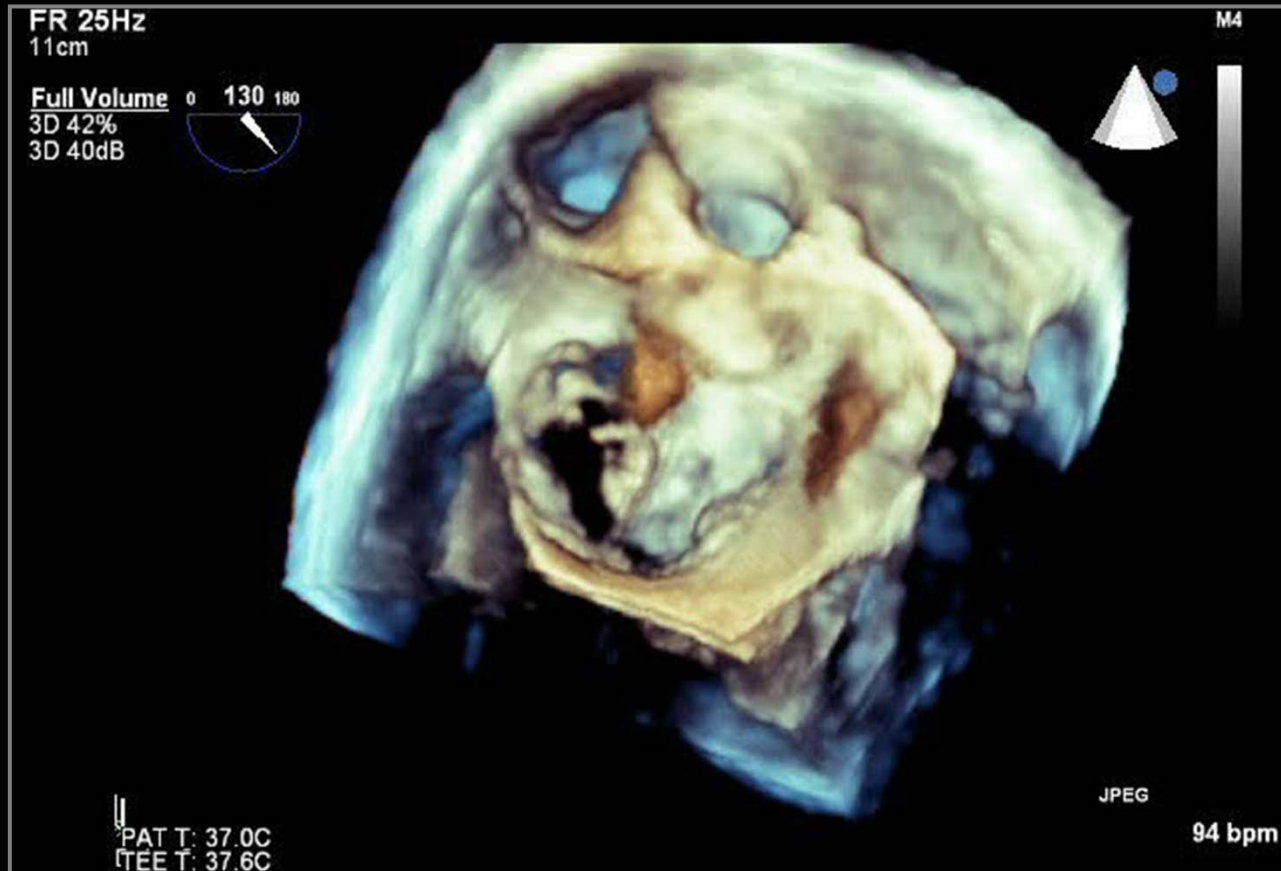# Cause of Severe MR



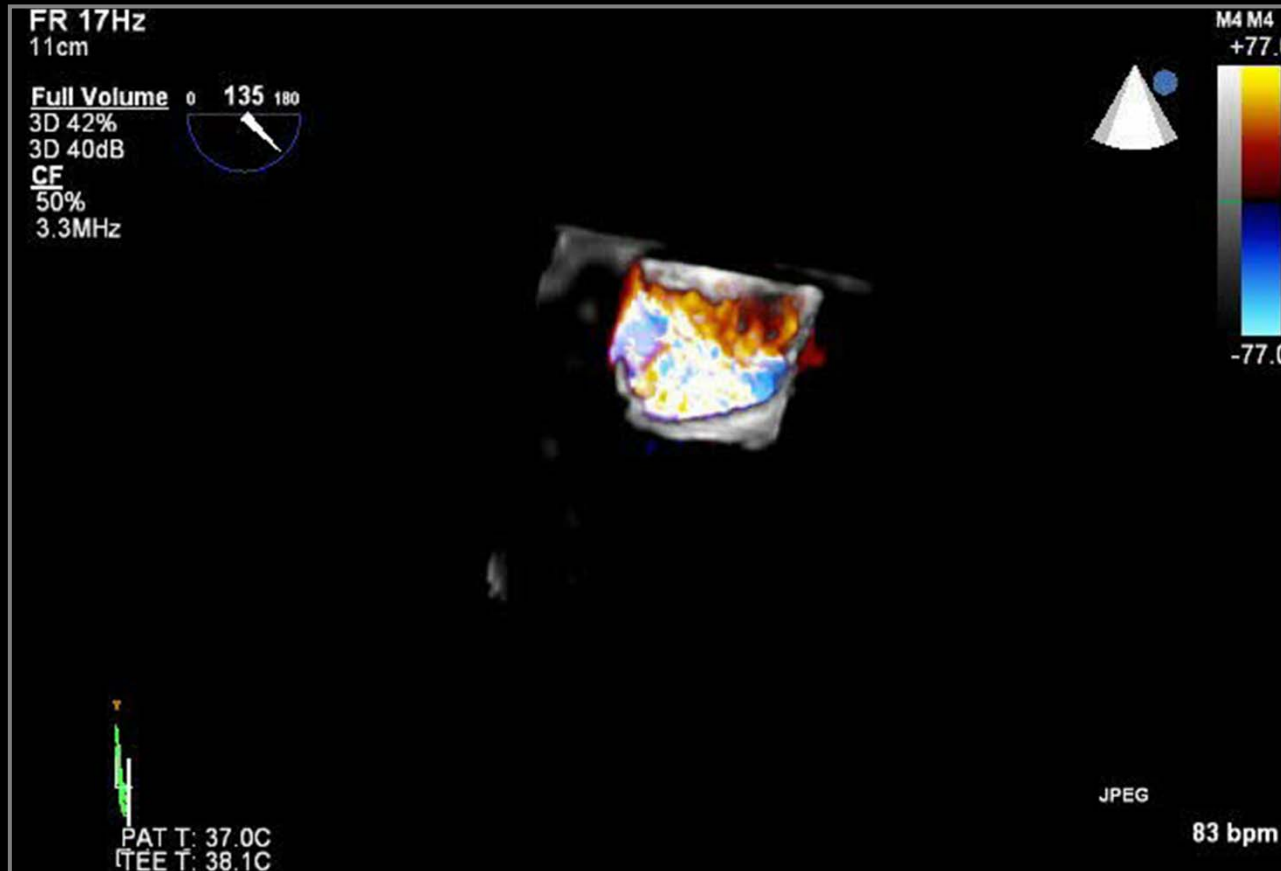# Cause of Severe MR



# Cause of Severe MR

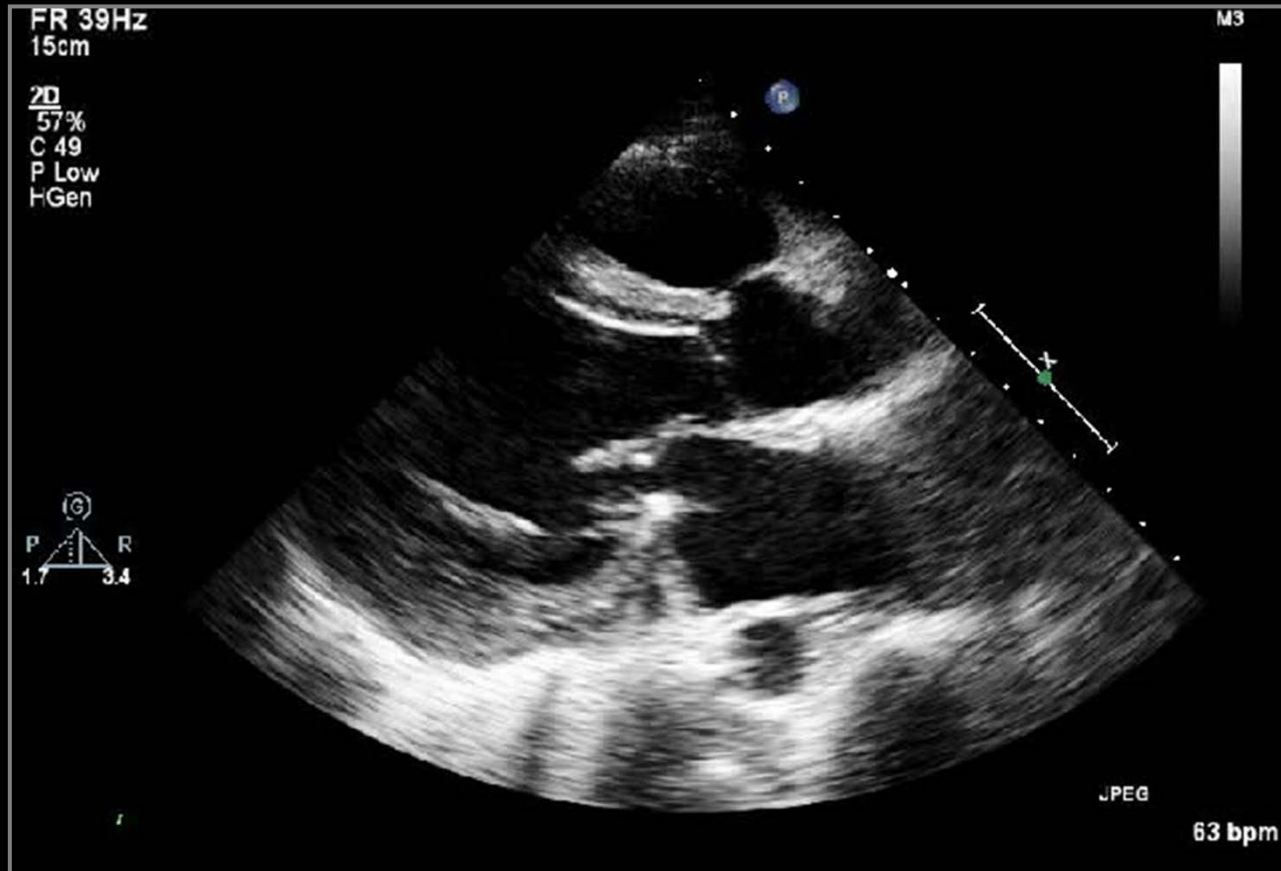


# Cause of Severe MR

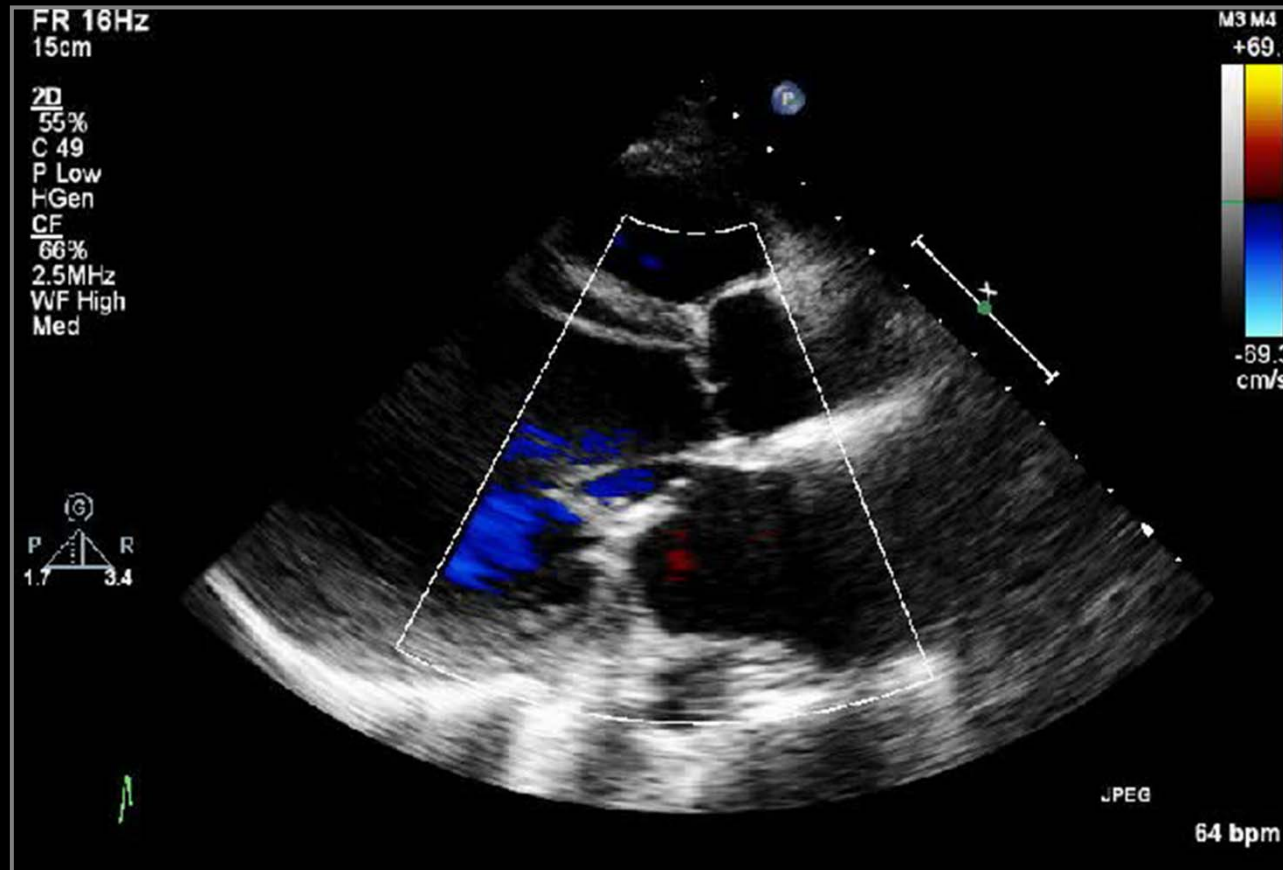




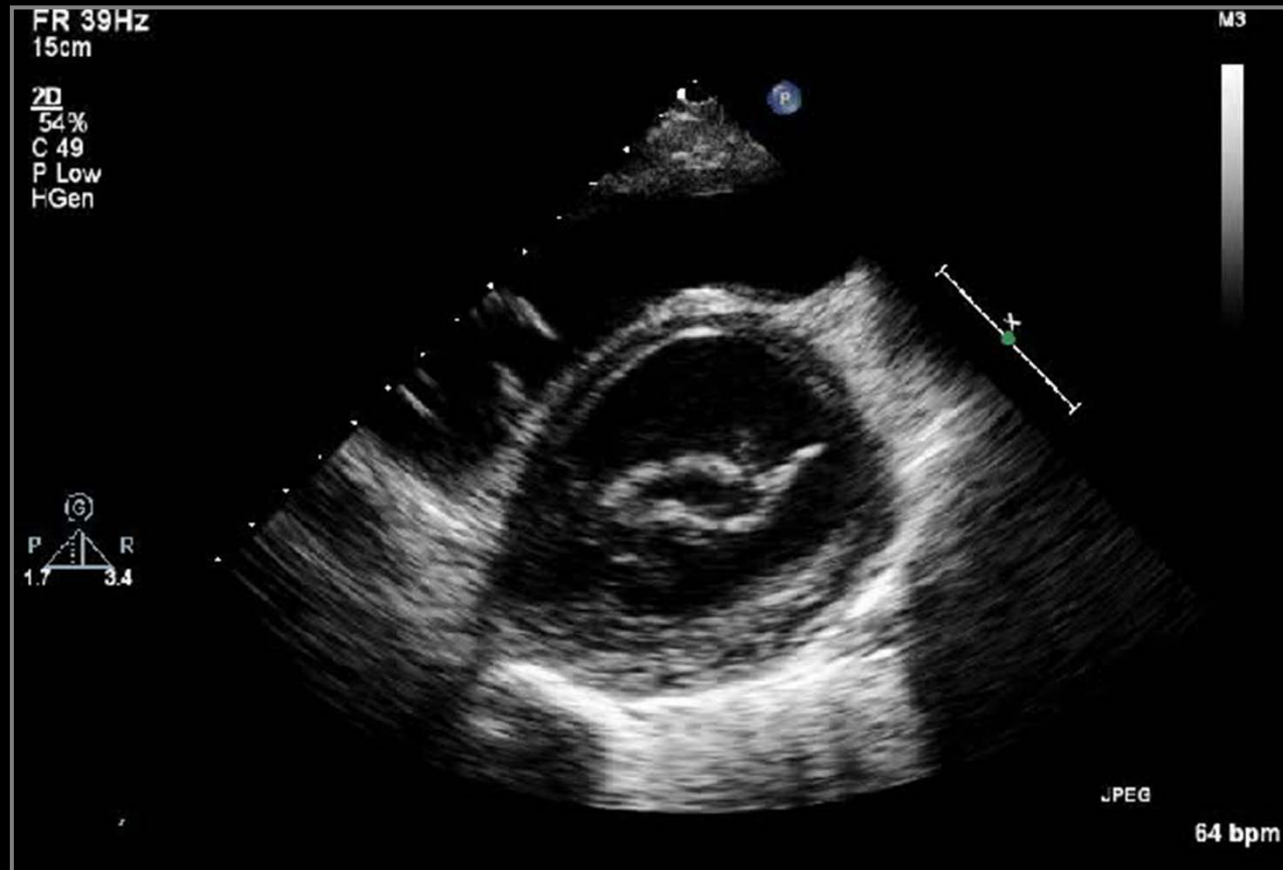
# s/p MV Repair



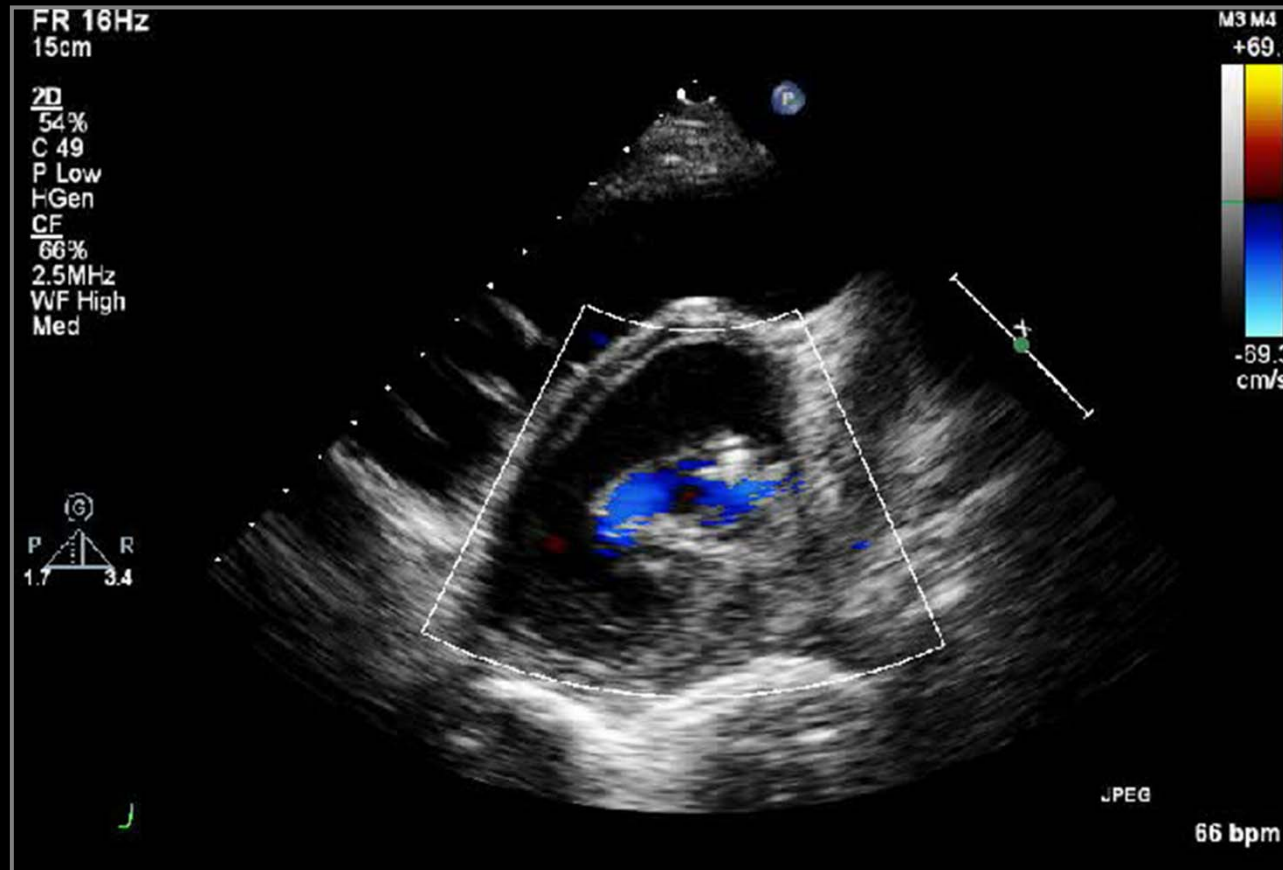
# s/p MV Repair



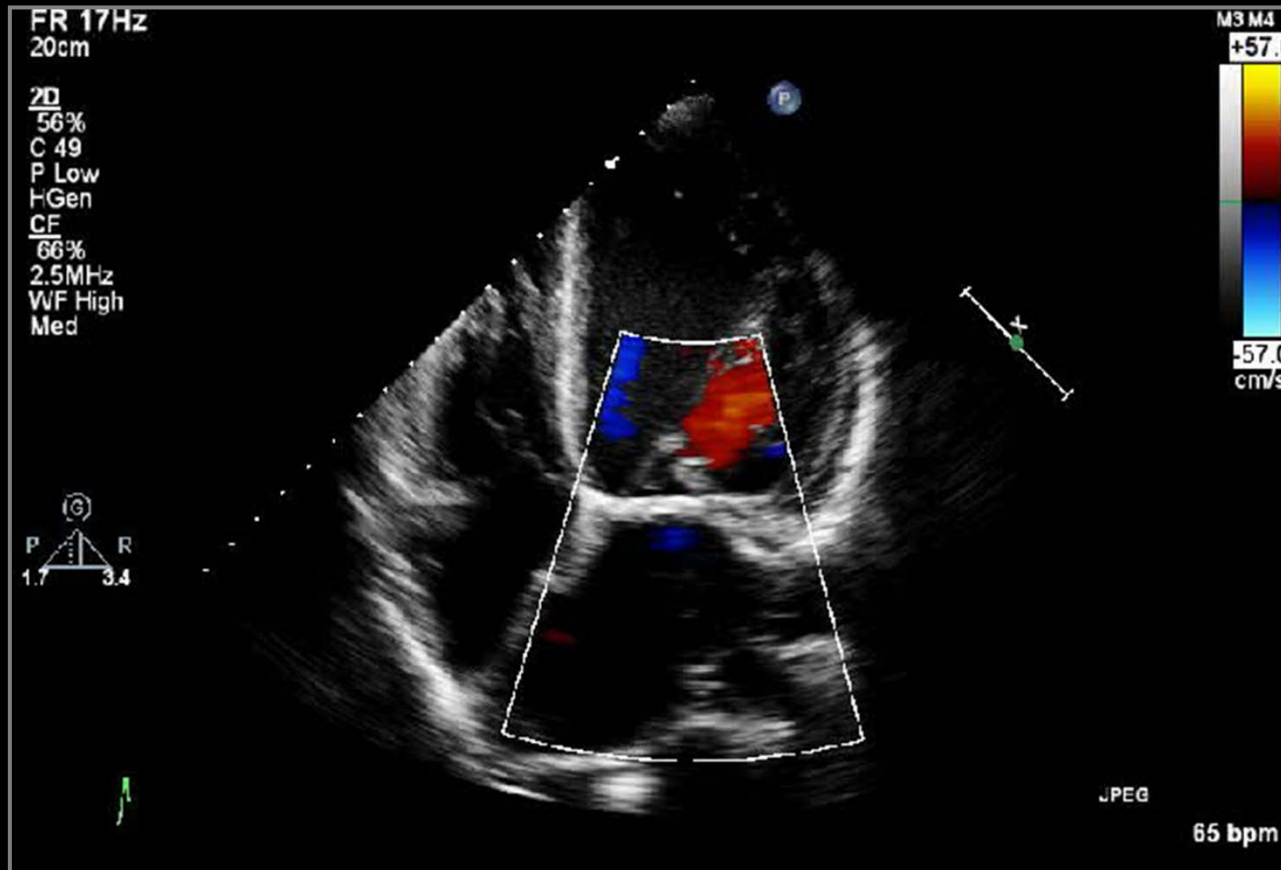
# s/p MV Repair



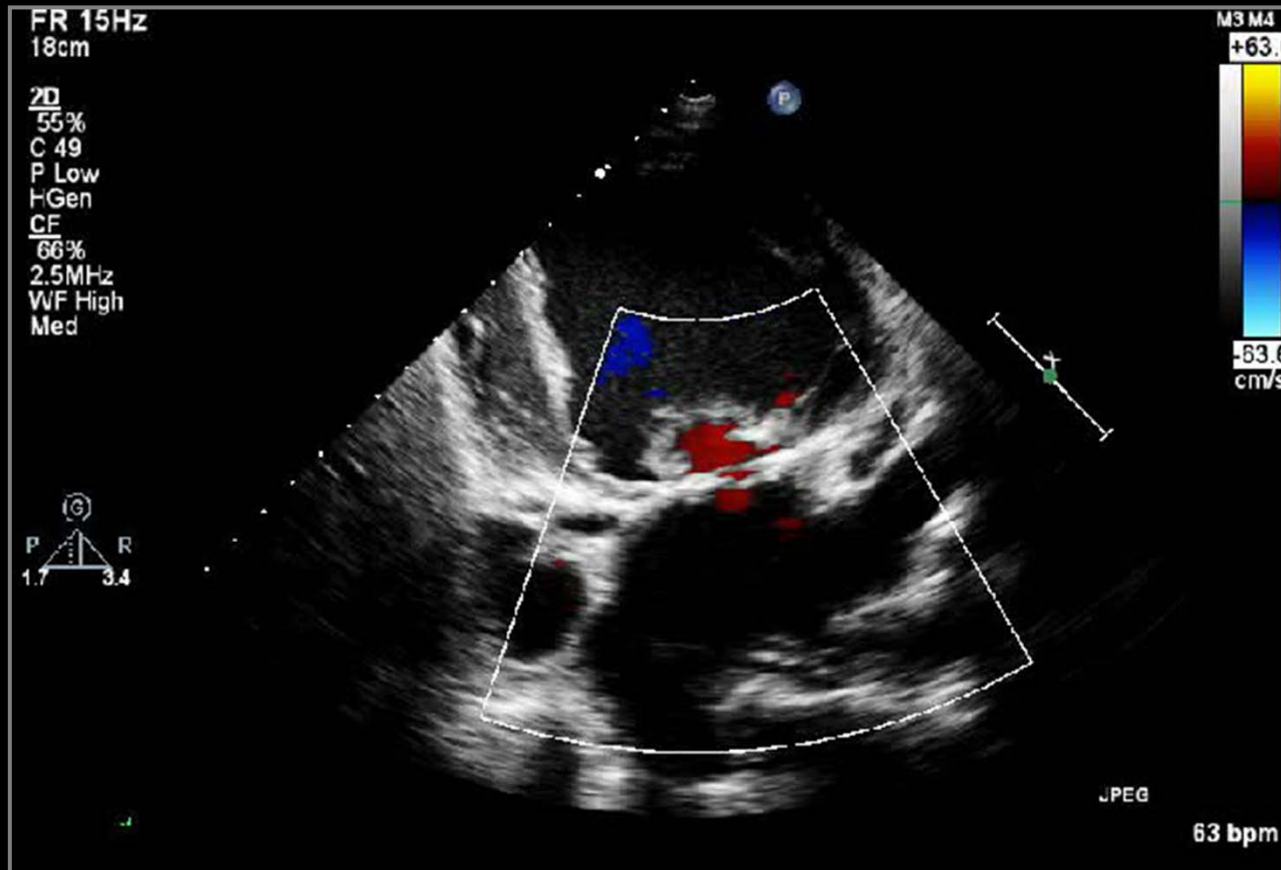
# s/p MV Repair



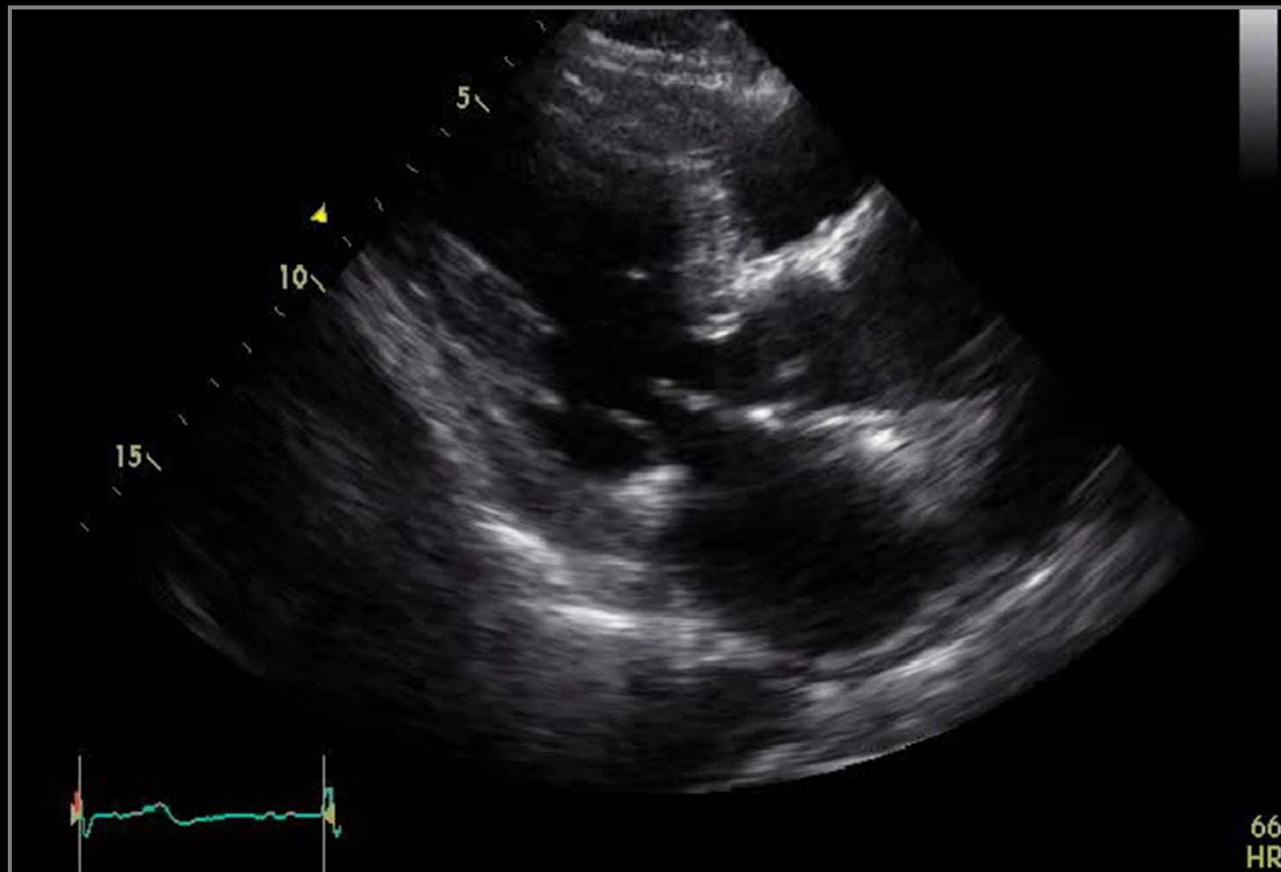
# s/p MV Repair



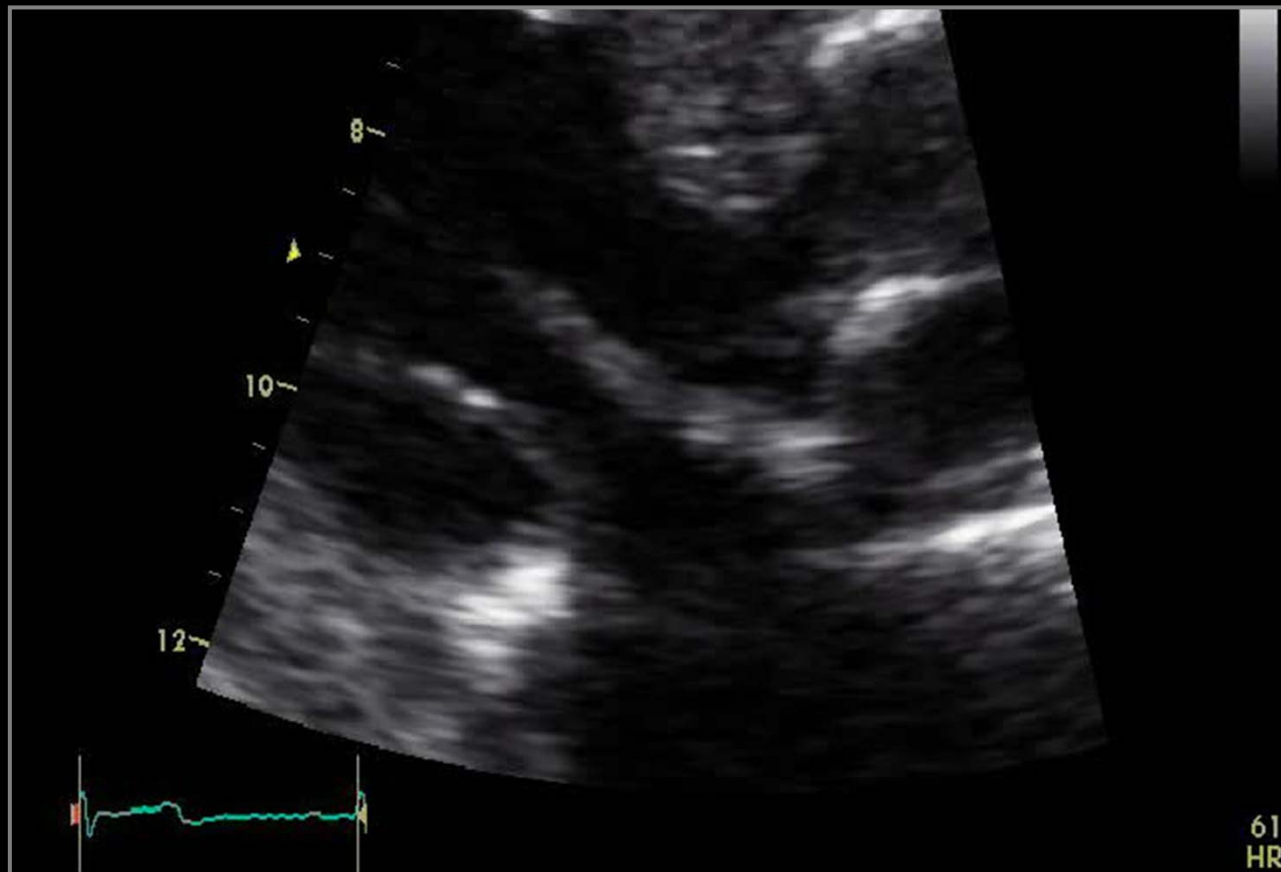
# s/p MV Repair



# Cause of Severe MR

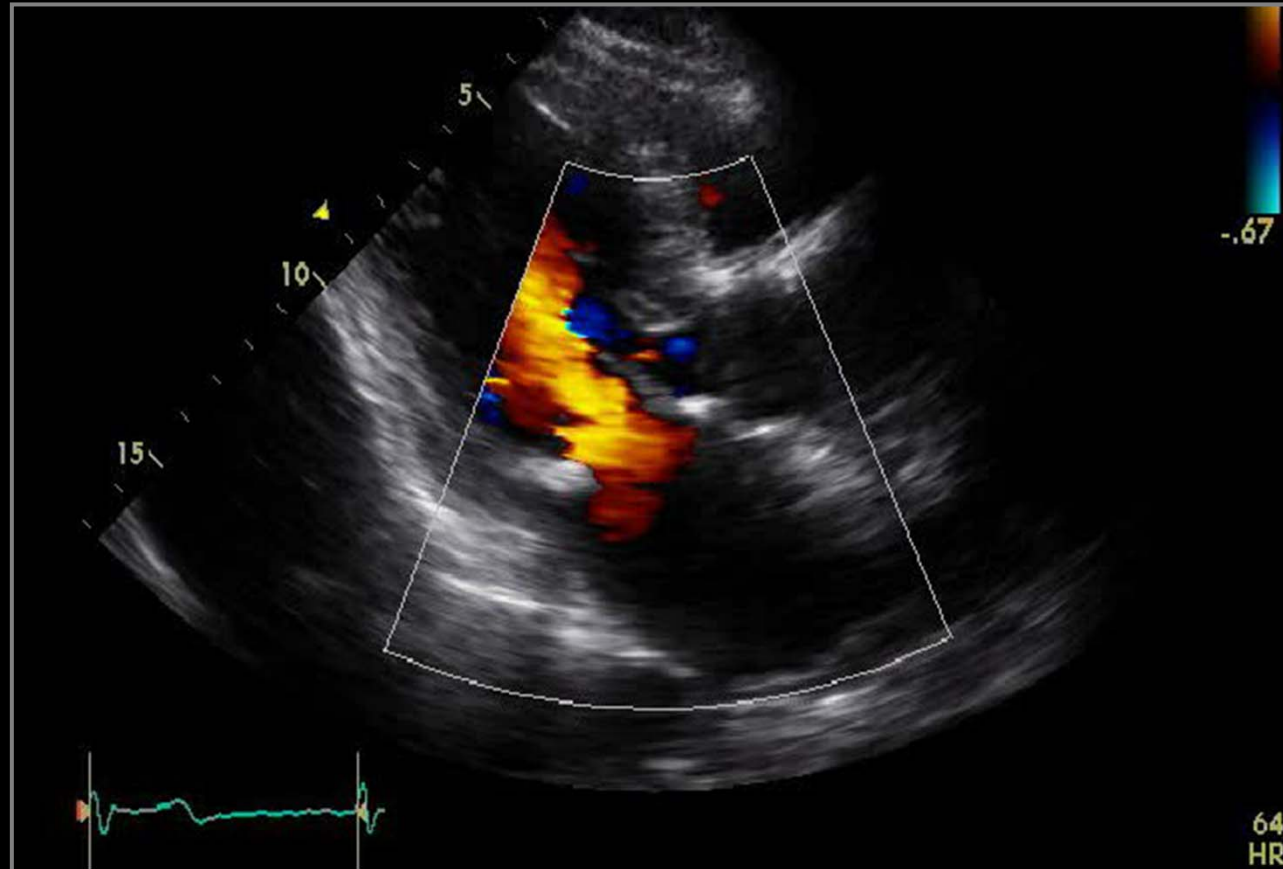


# Cause of Severe MR

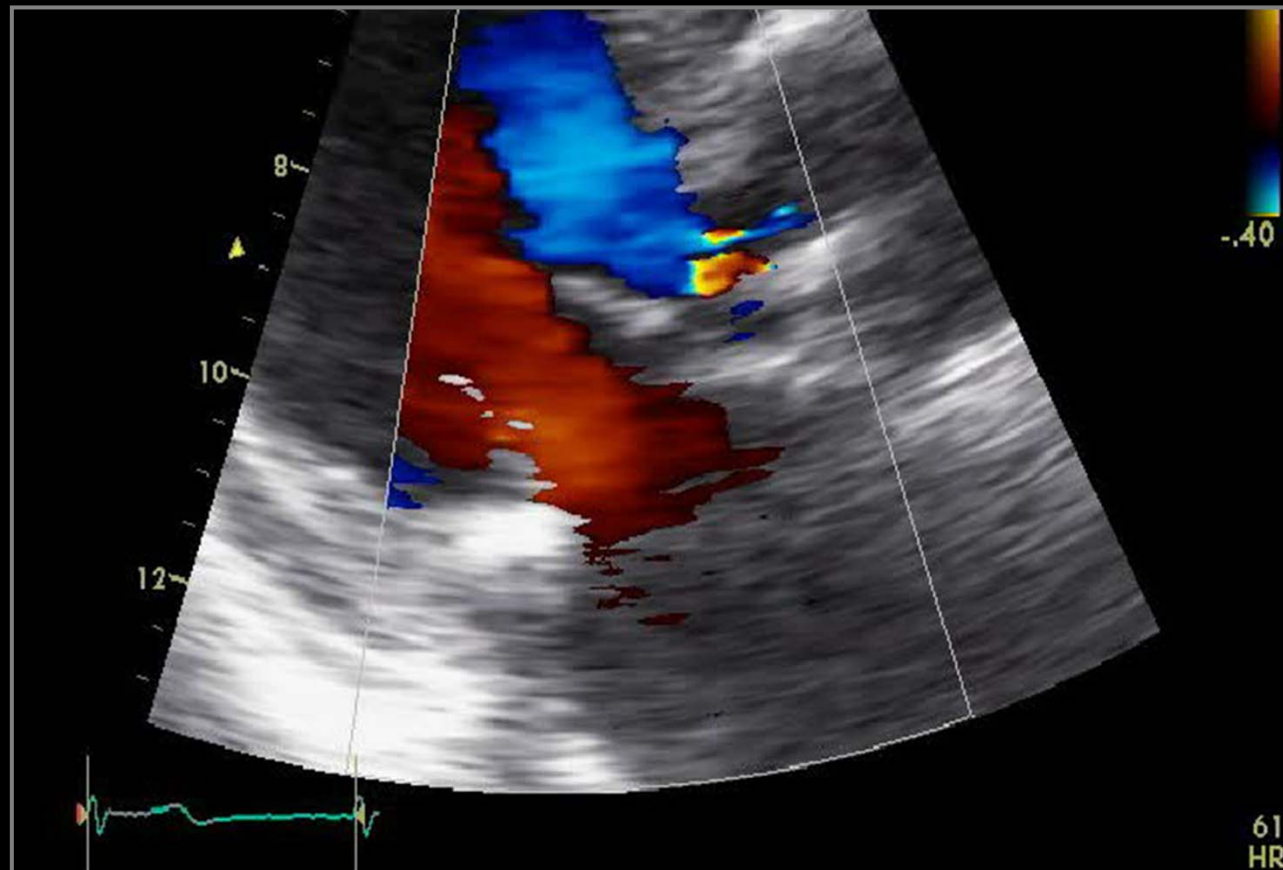




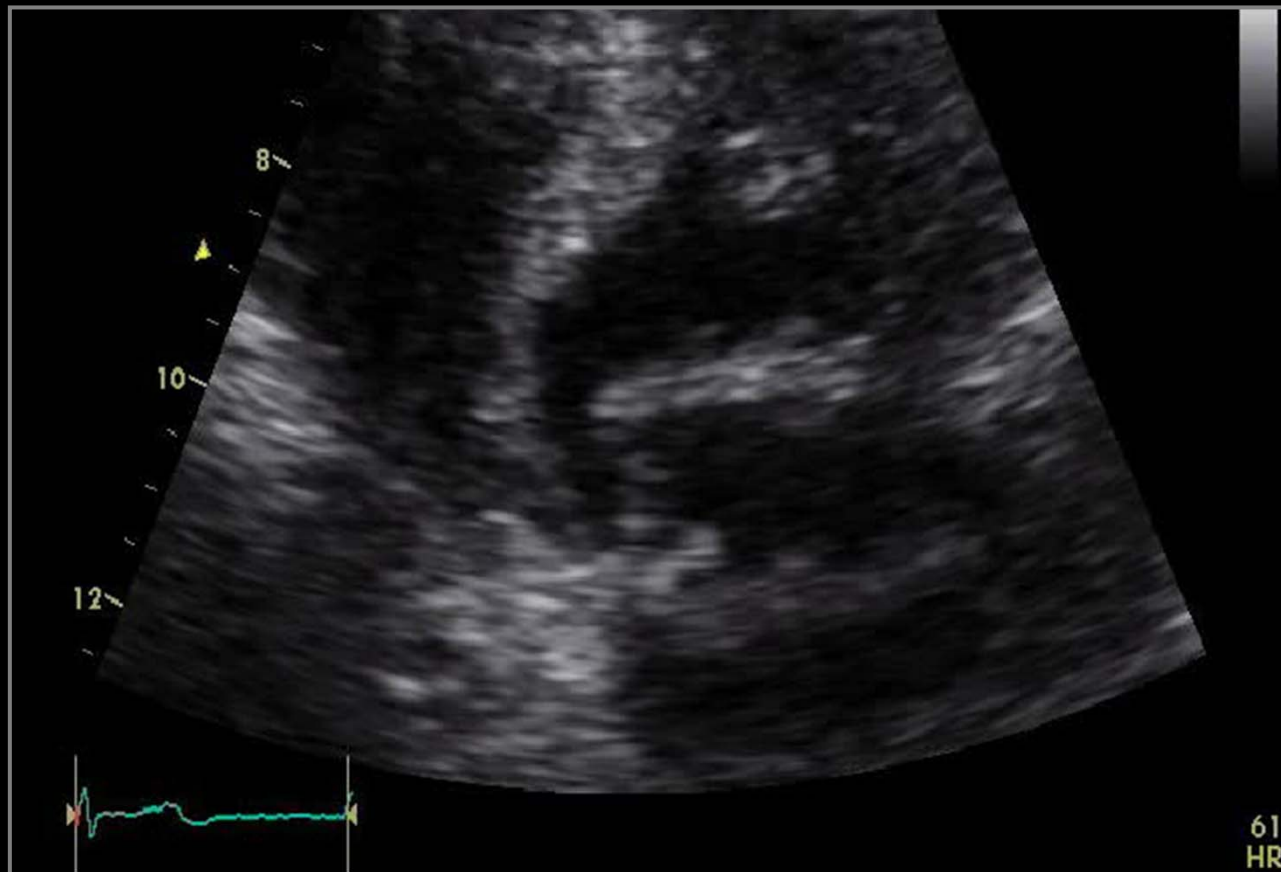
# Cause of Severe MR



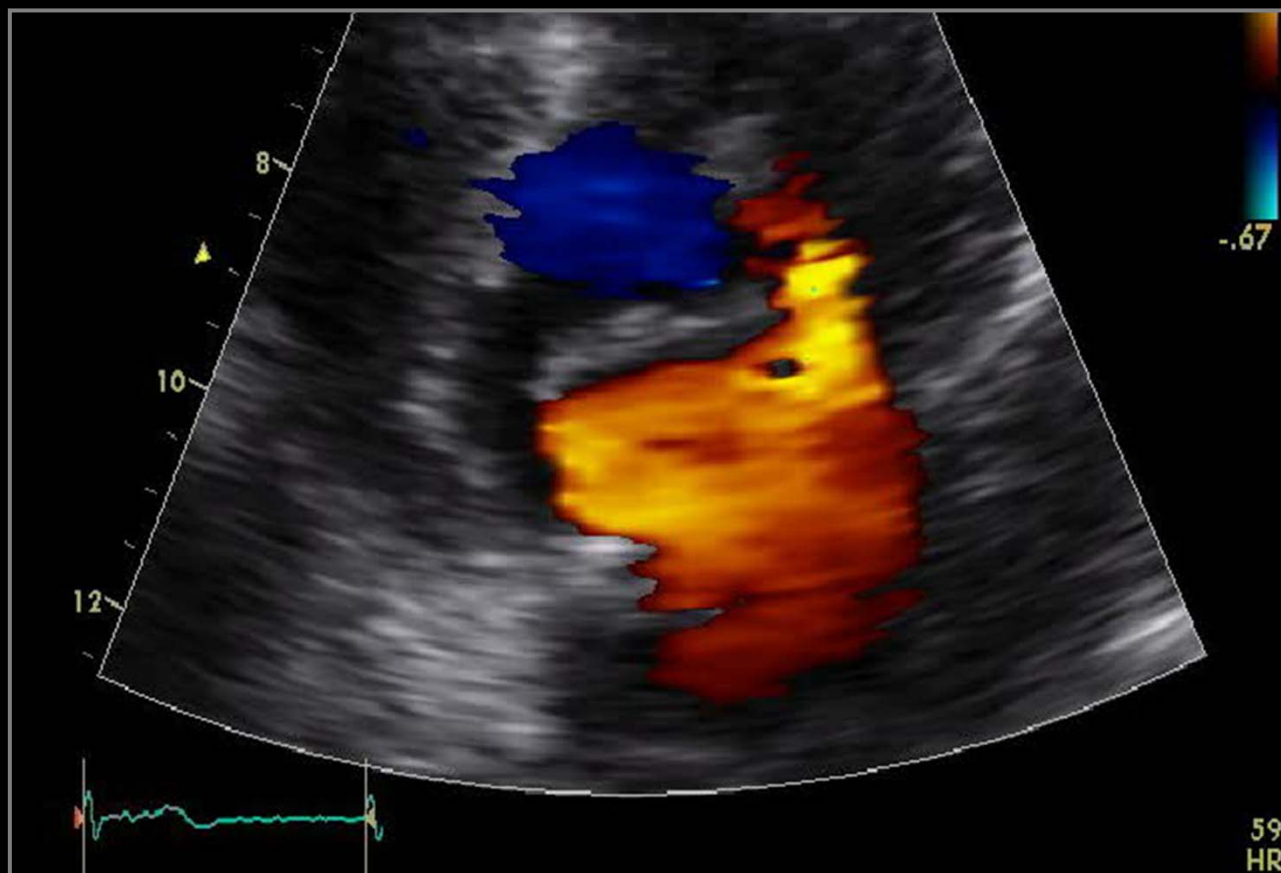
# Cause of Severe MR



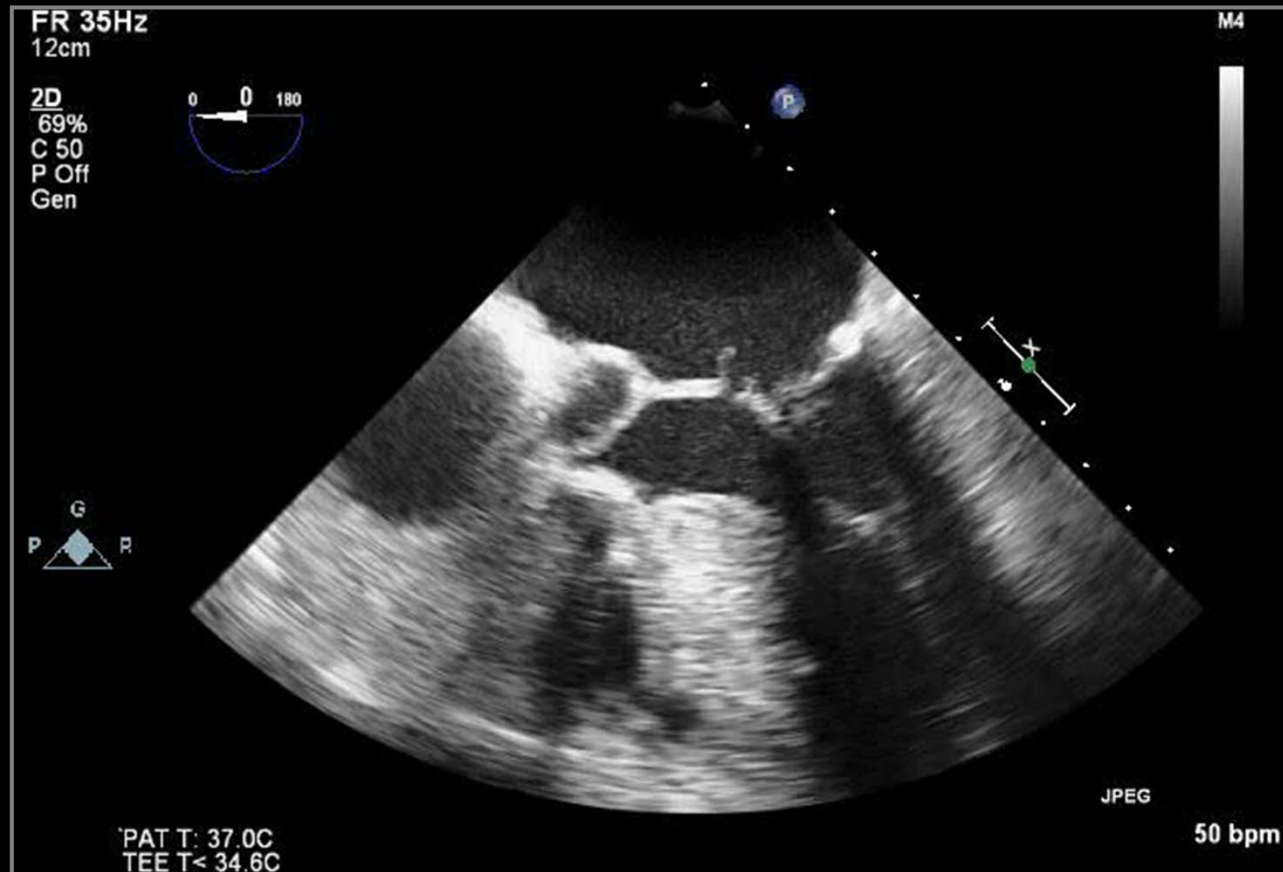
# Cause of Severe MR



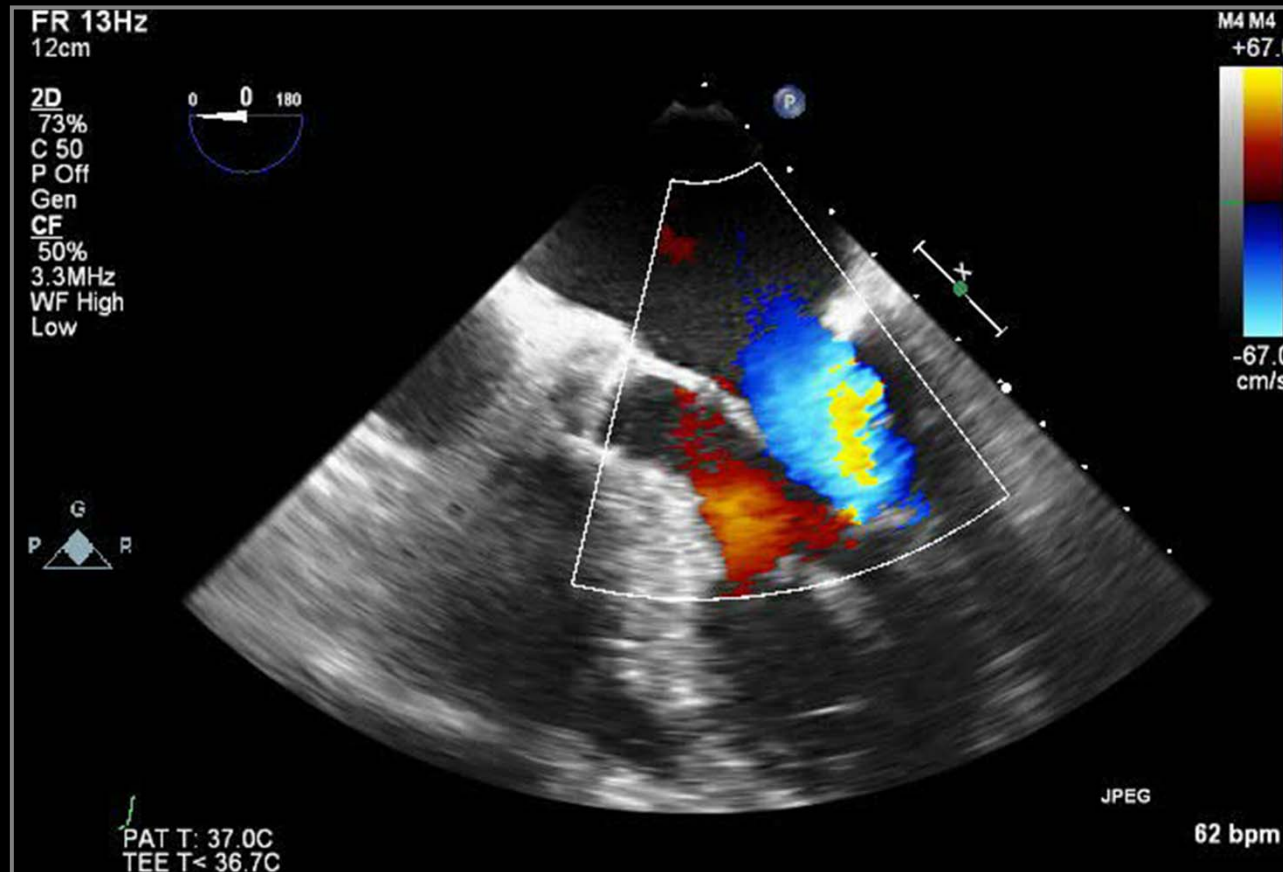
# Cause of Severe MR



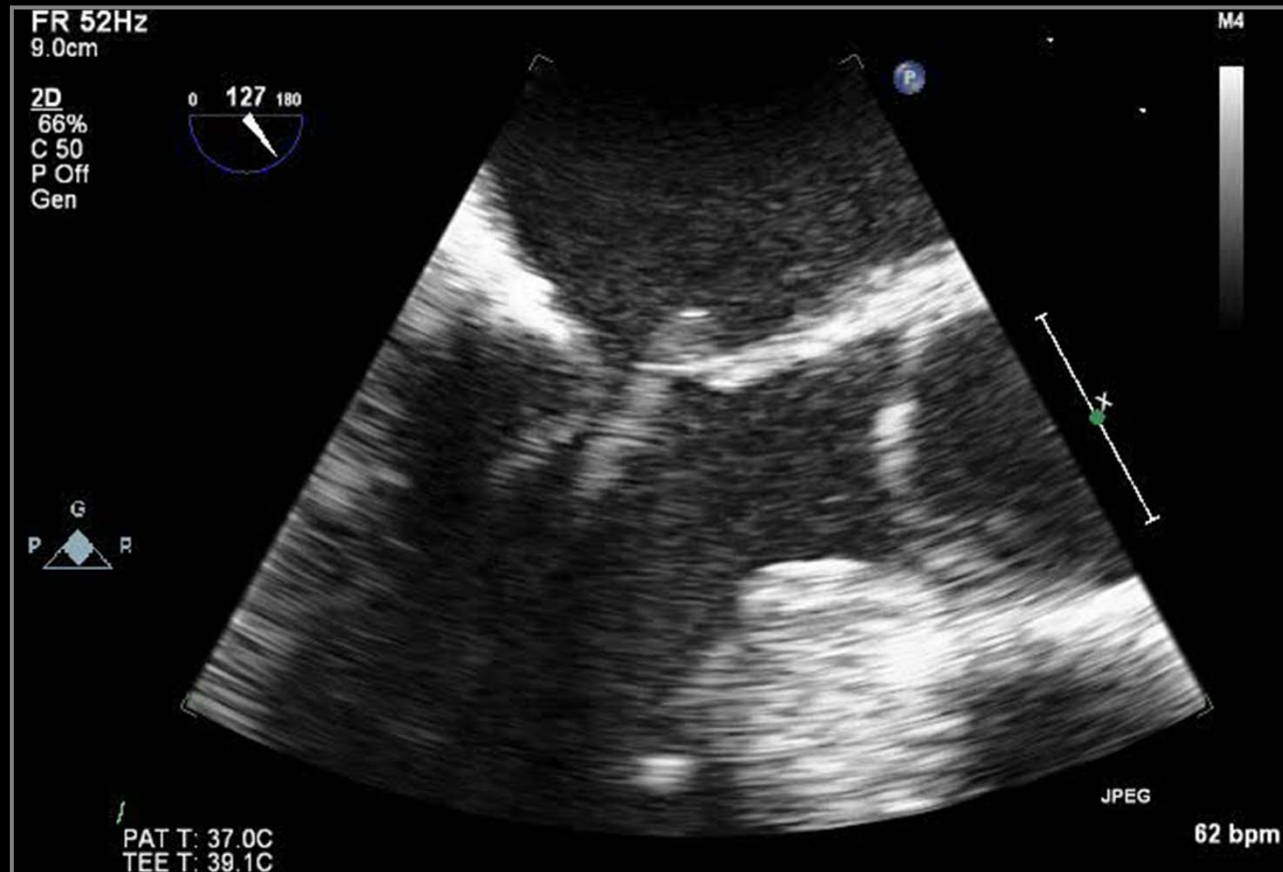
# Cause of Severe MR



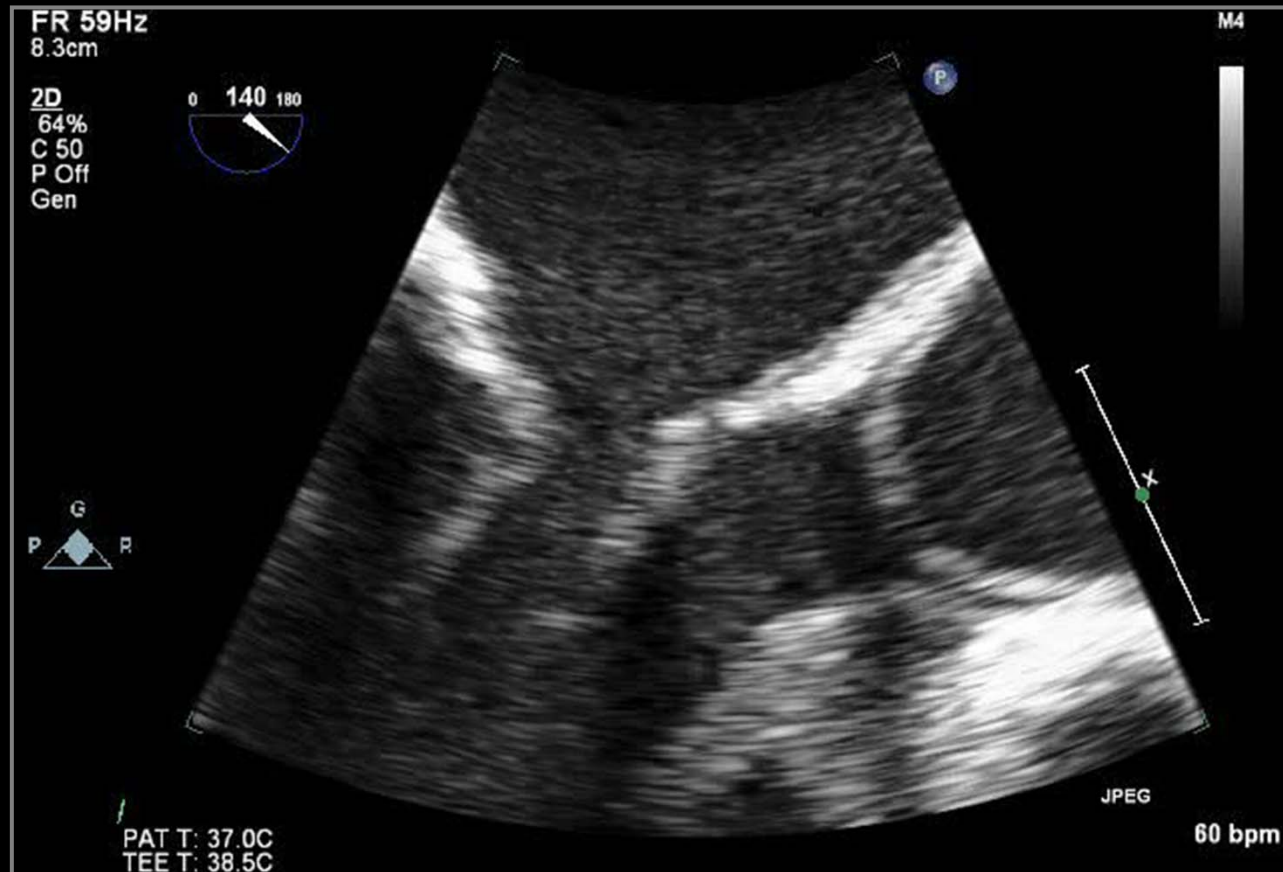
# Cause of Severe MR



# Cause of Severe MR

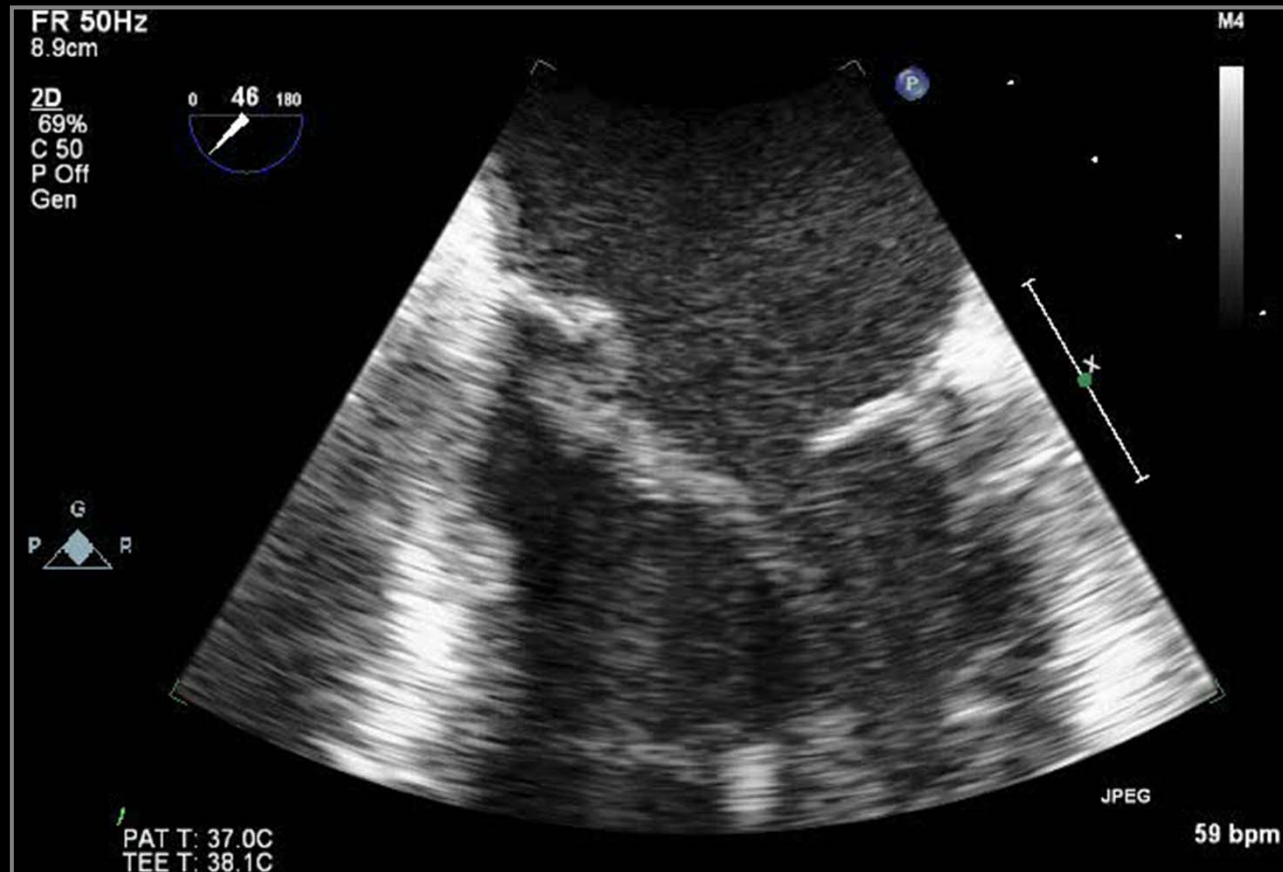


# Cause of Severe MR

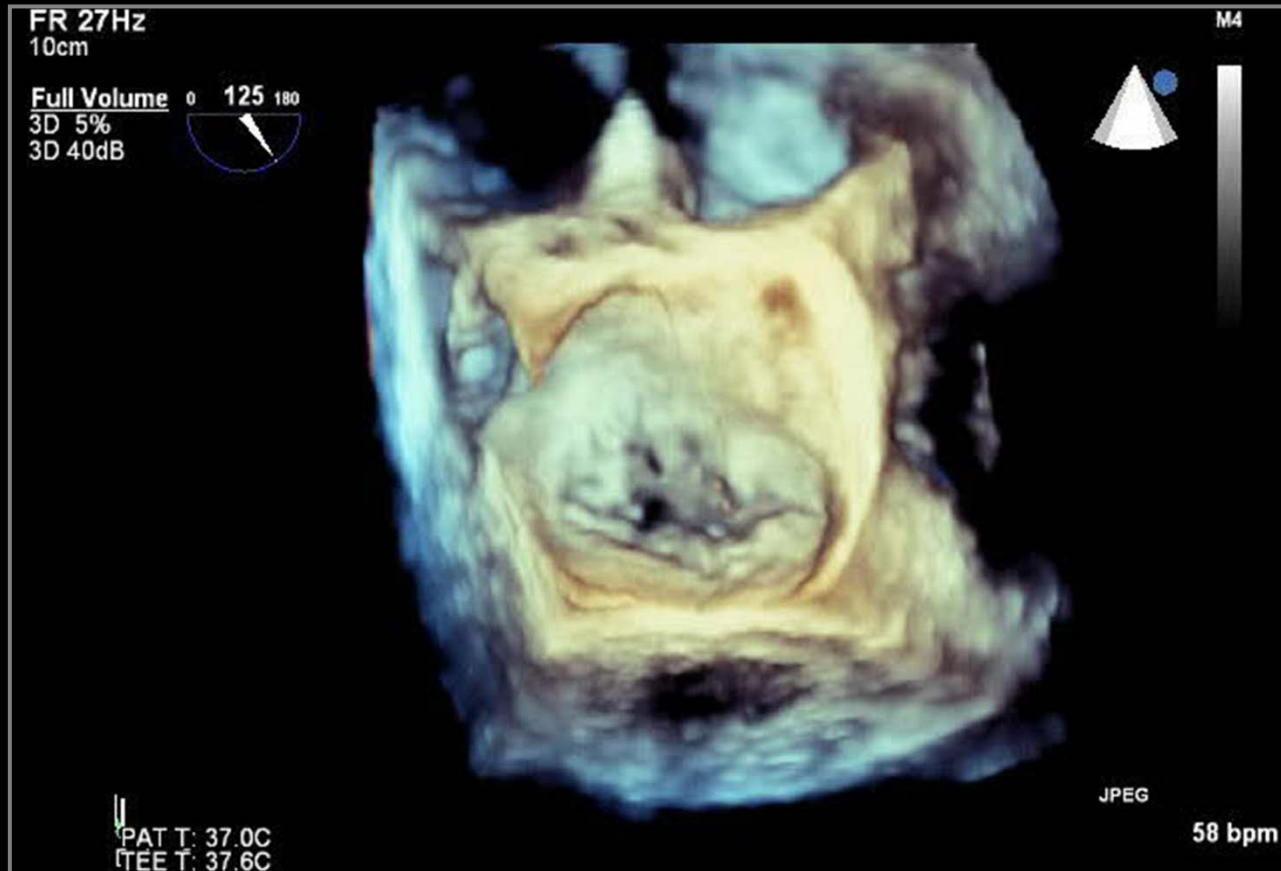



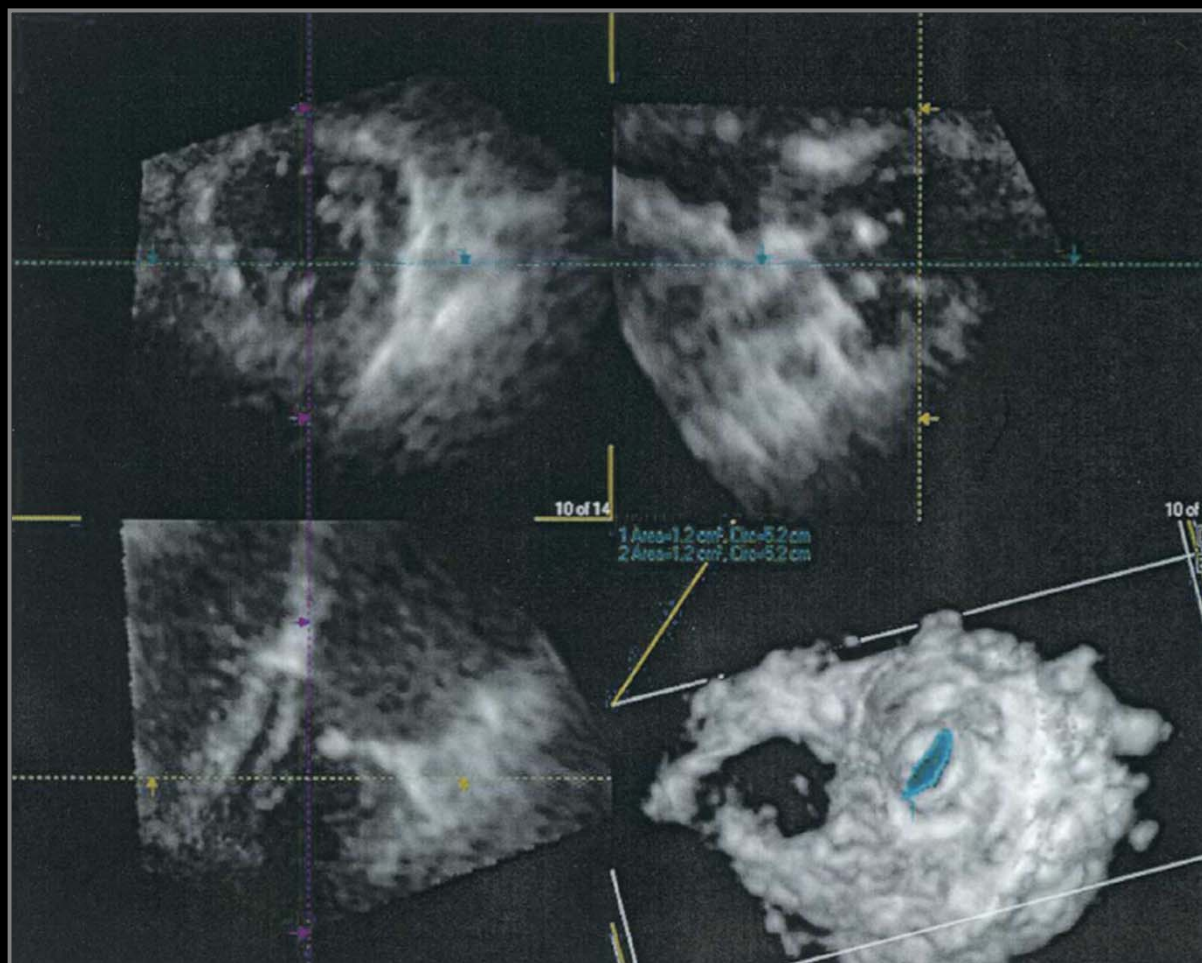
# Cause of Severe MR



# Cause of Severe MR

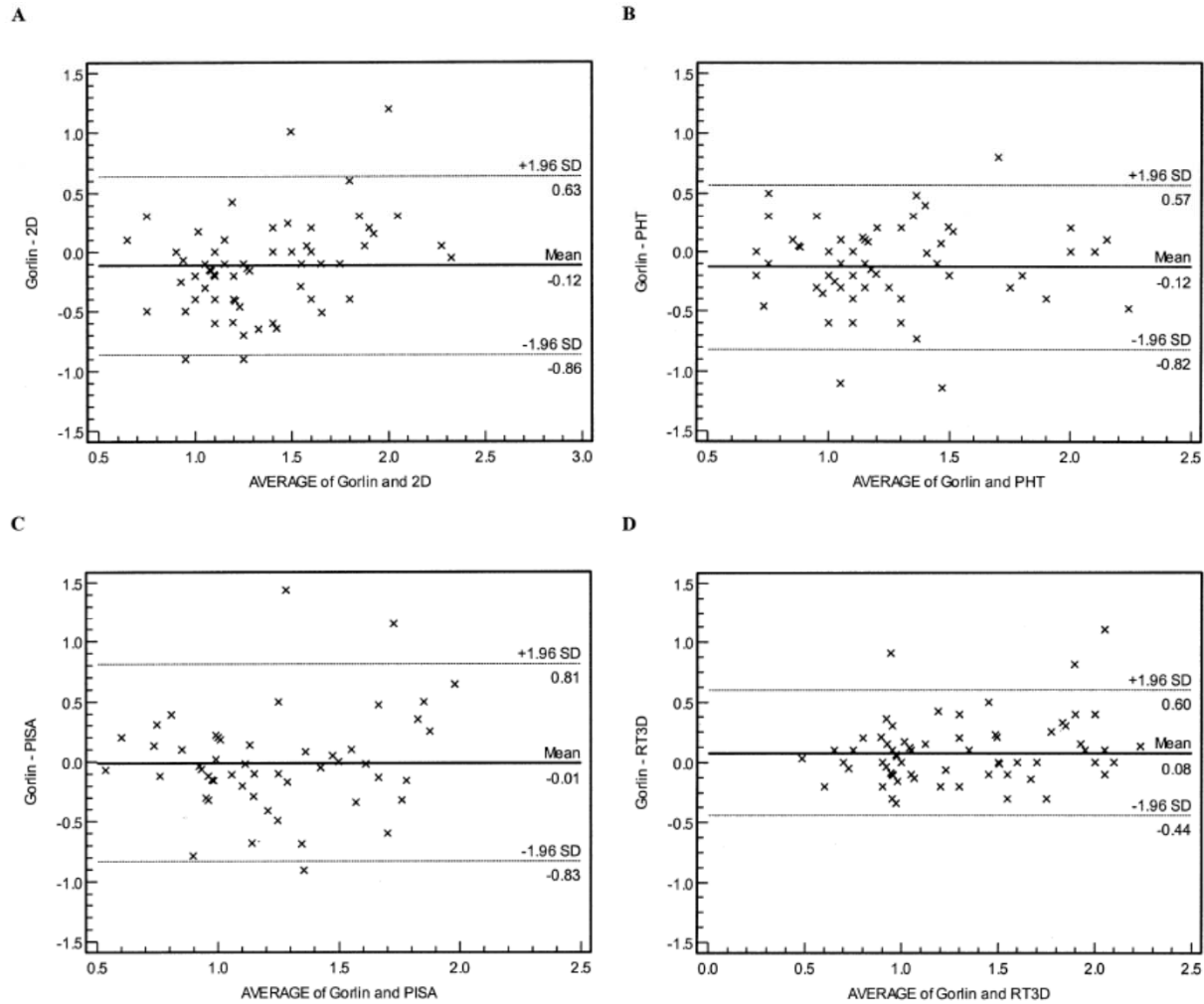


# Mitral Stenosis



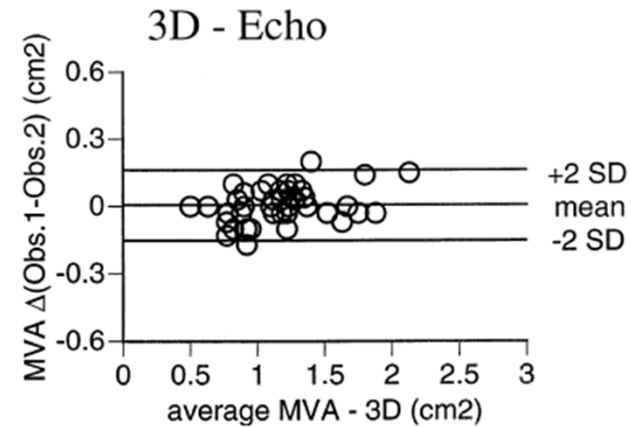
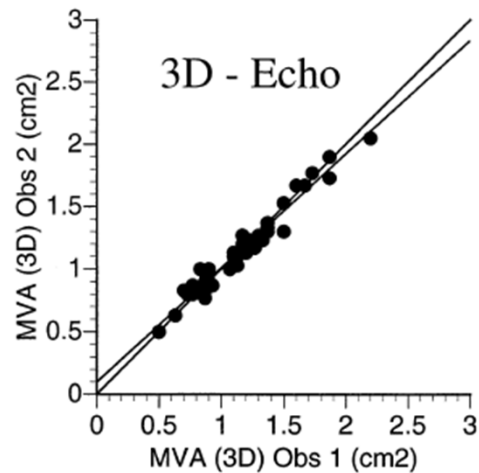
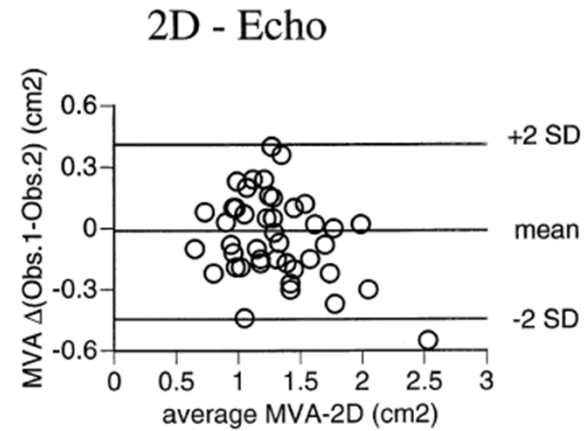
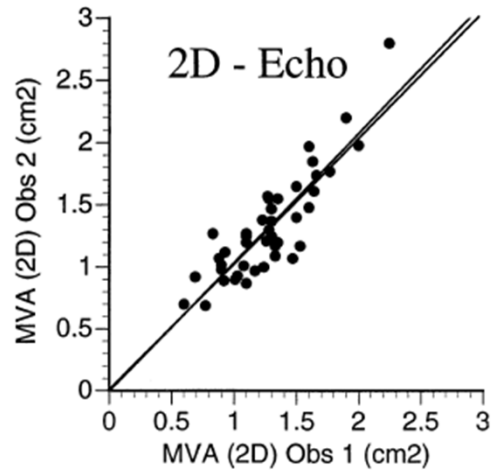
*Jamorano J et al. JACC 2004;43:2091-6*

# Mitral Stenosis



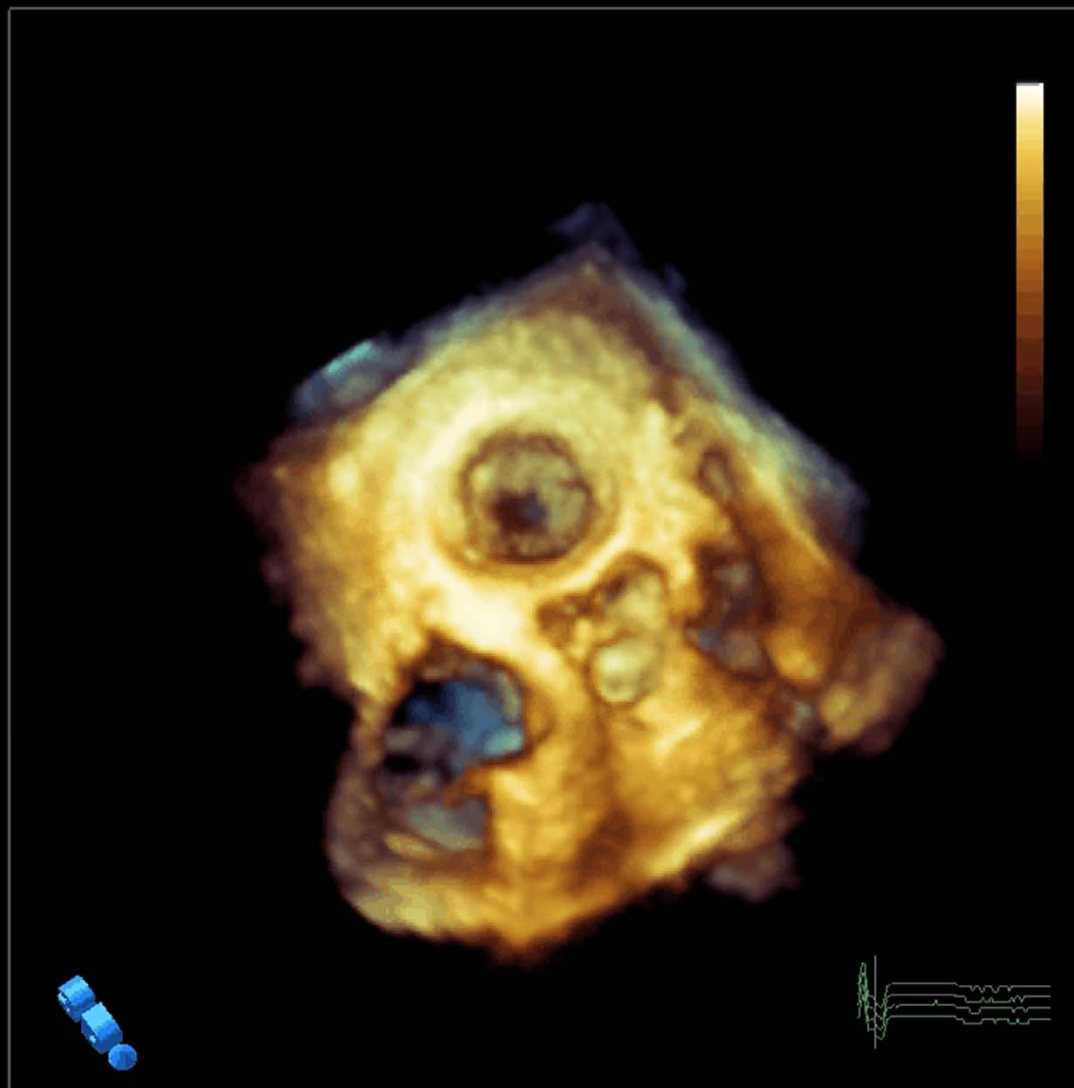
*Jamorano J et al. JACC 2004;43:2091-6*

# Mitral Stenosis



*Binder TM et al. JACC 2000;36:1355- 61*

# Mitral Stenosis on 3D TEE



PHILIPS

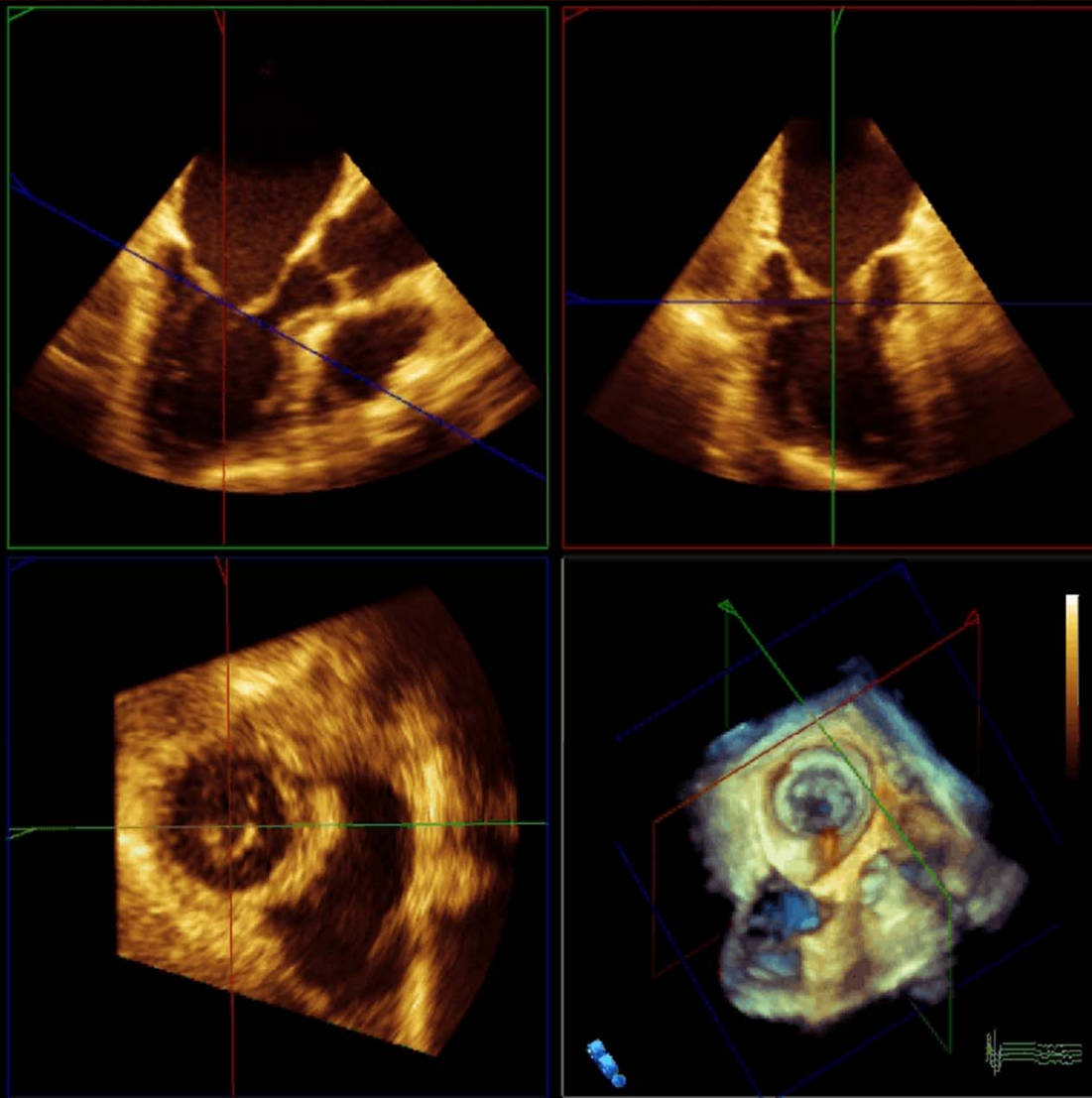


ASAN  
Medical Center



UNIVERSITY OF ULSAN  
COLLEGE OF MEDICINE

# Mitral Stenosis on 3D TEE



PHILIPS

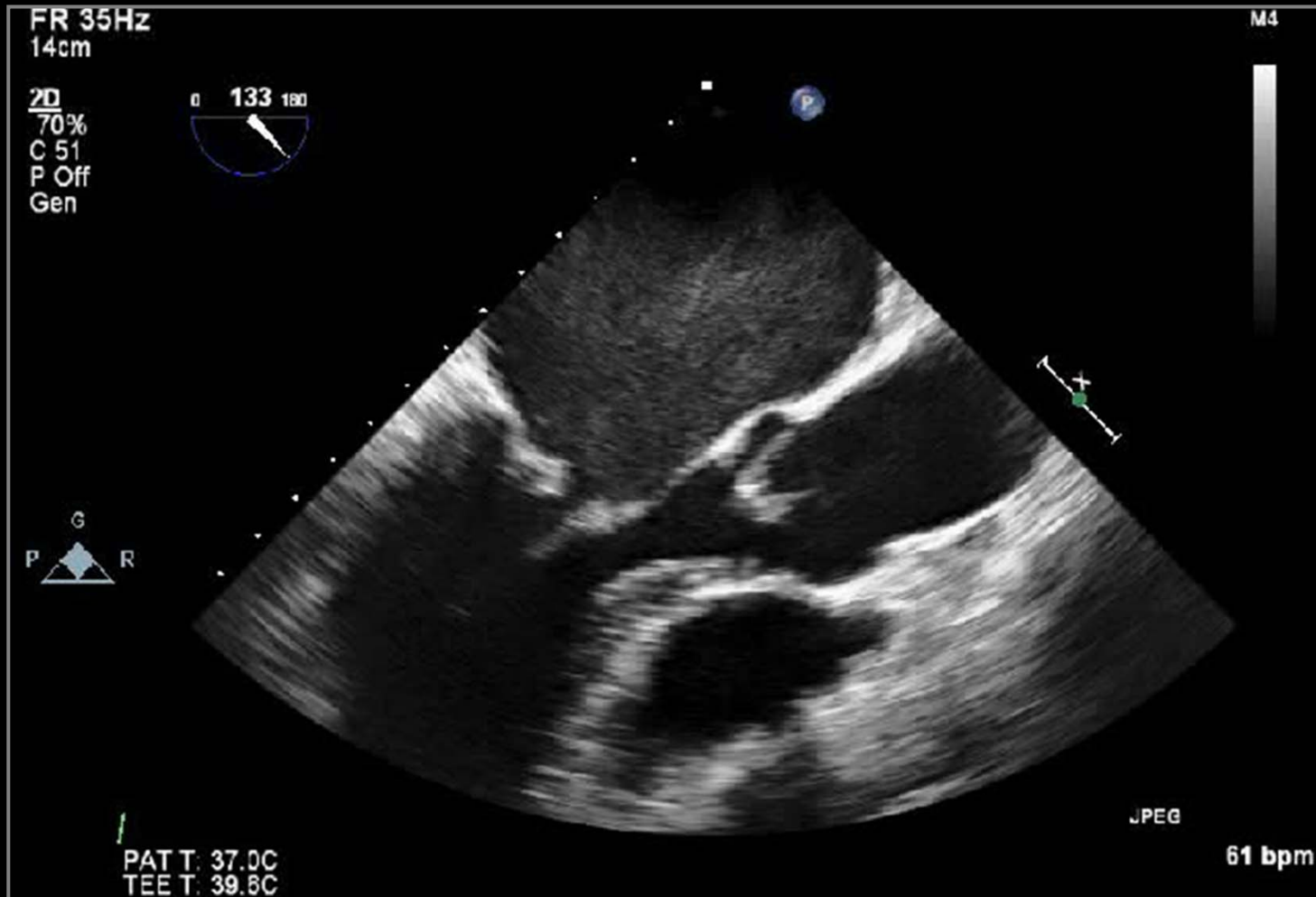


ASAN  
Medical Center



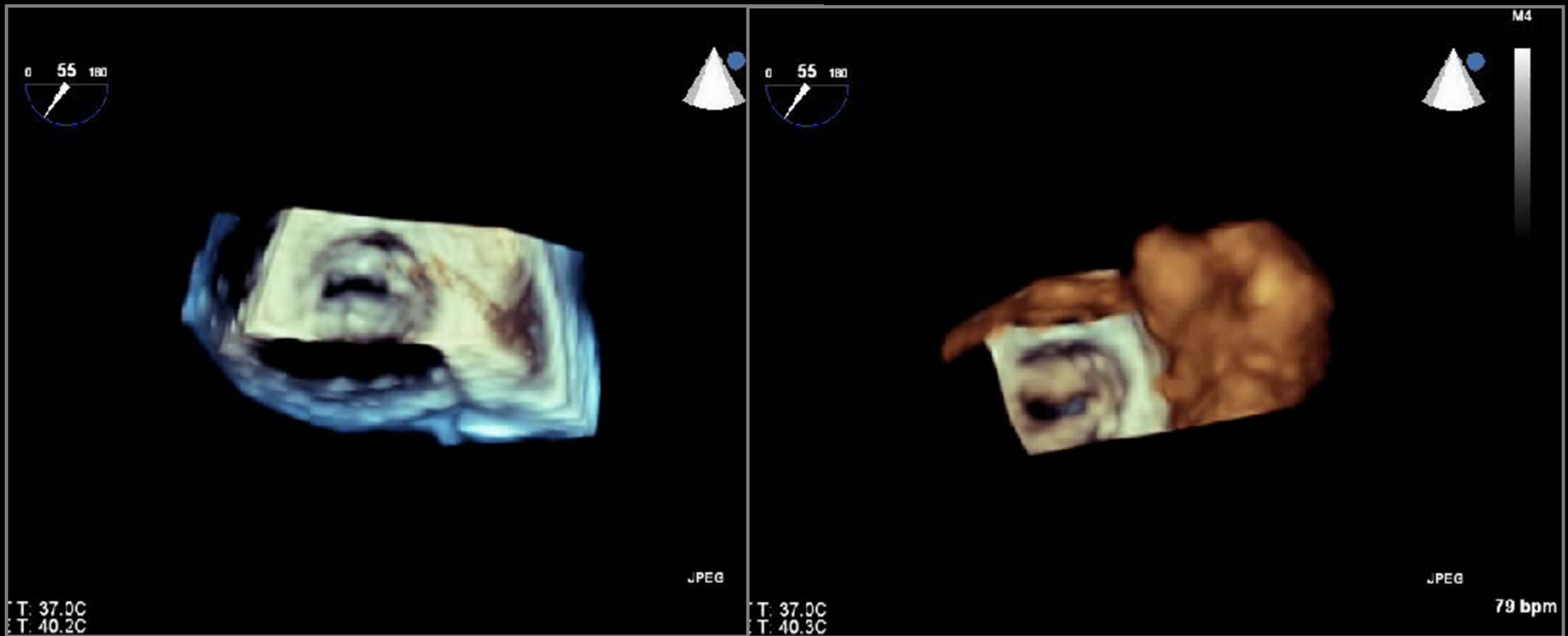
UNIVERSITY OF ULSAN  
COLLEGE OF MEDICINE

# Mitral Stenosis

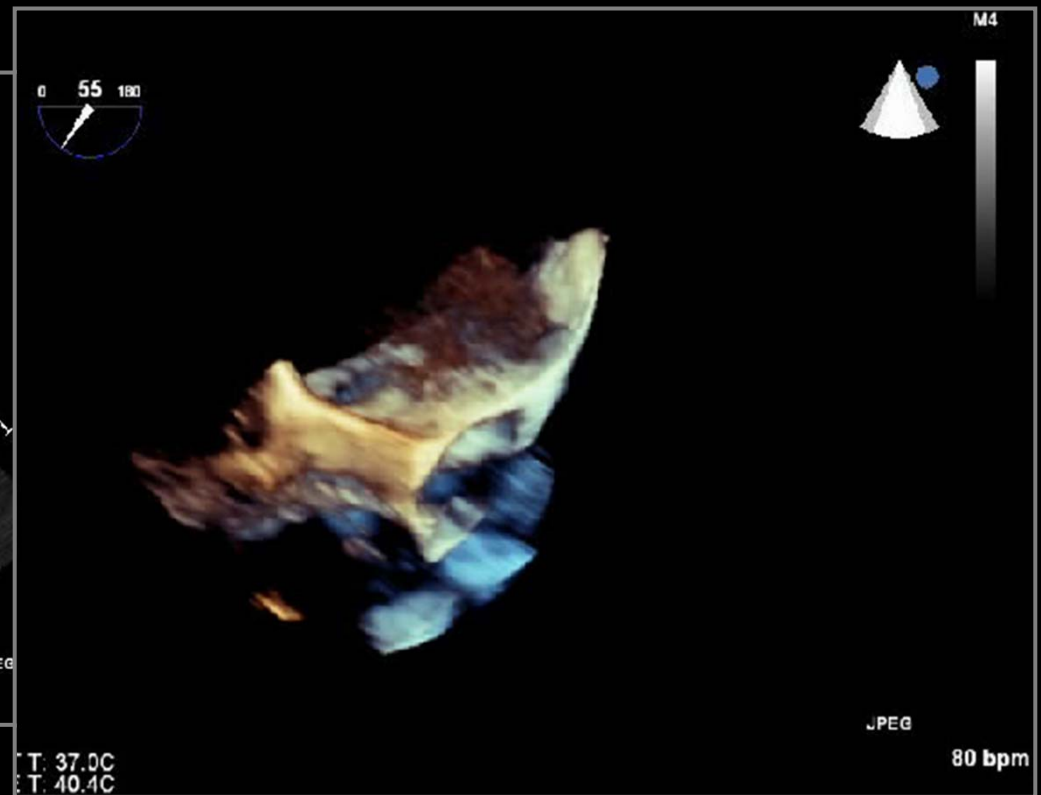
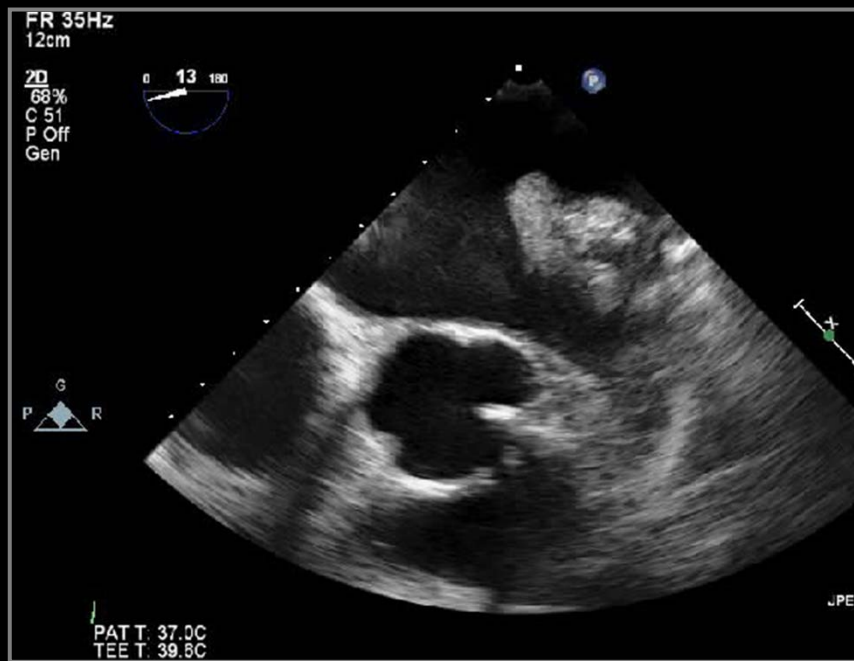



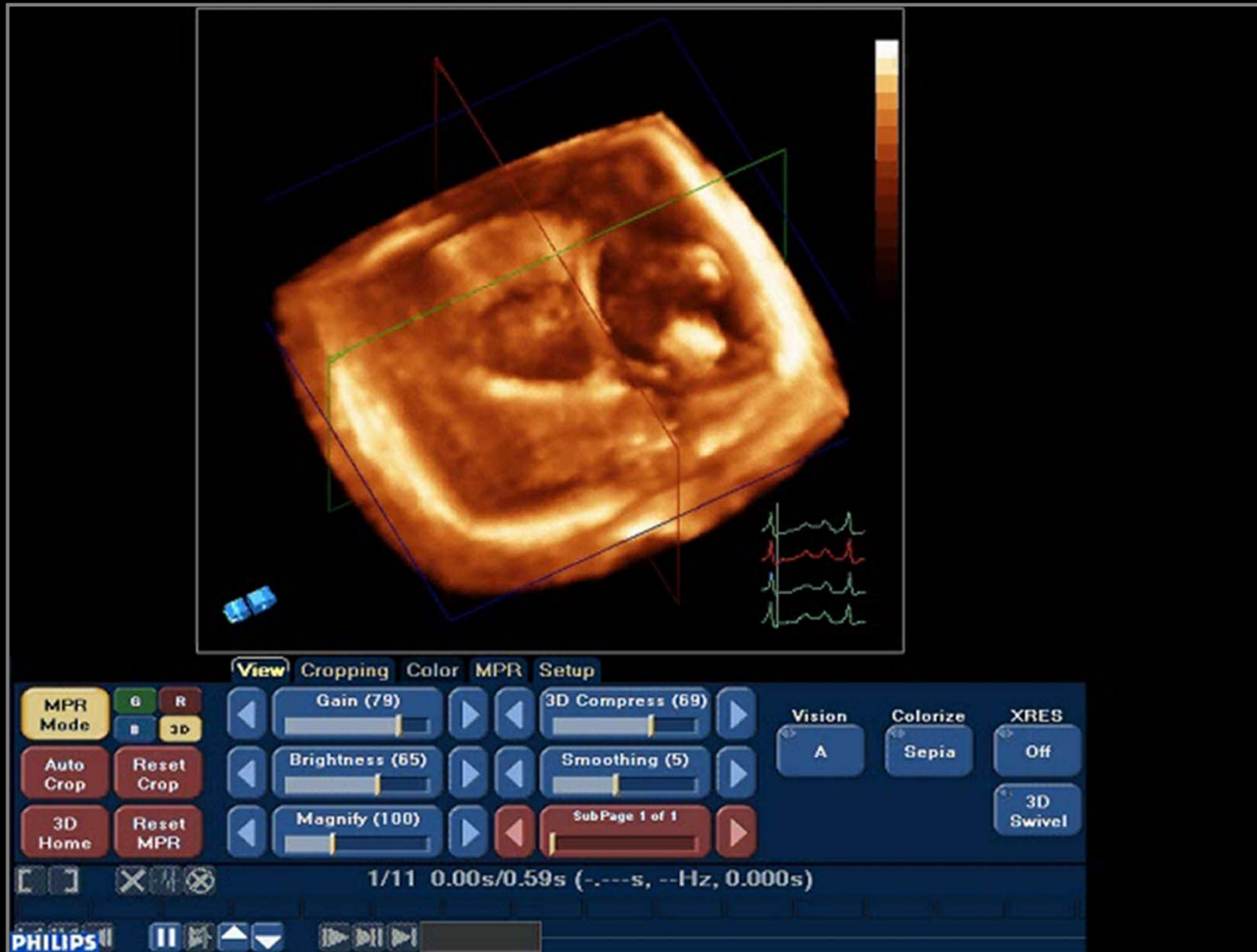
# Mitral Stenosis



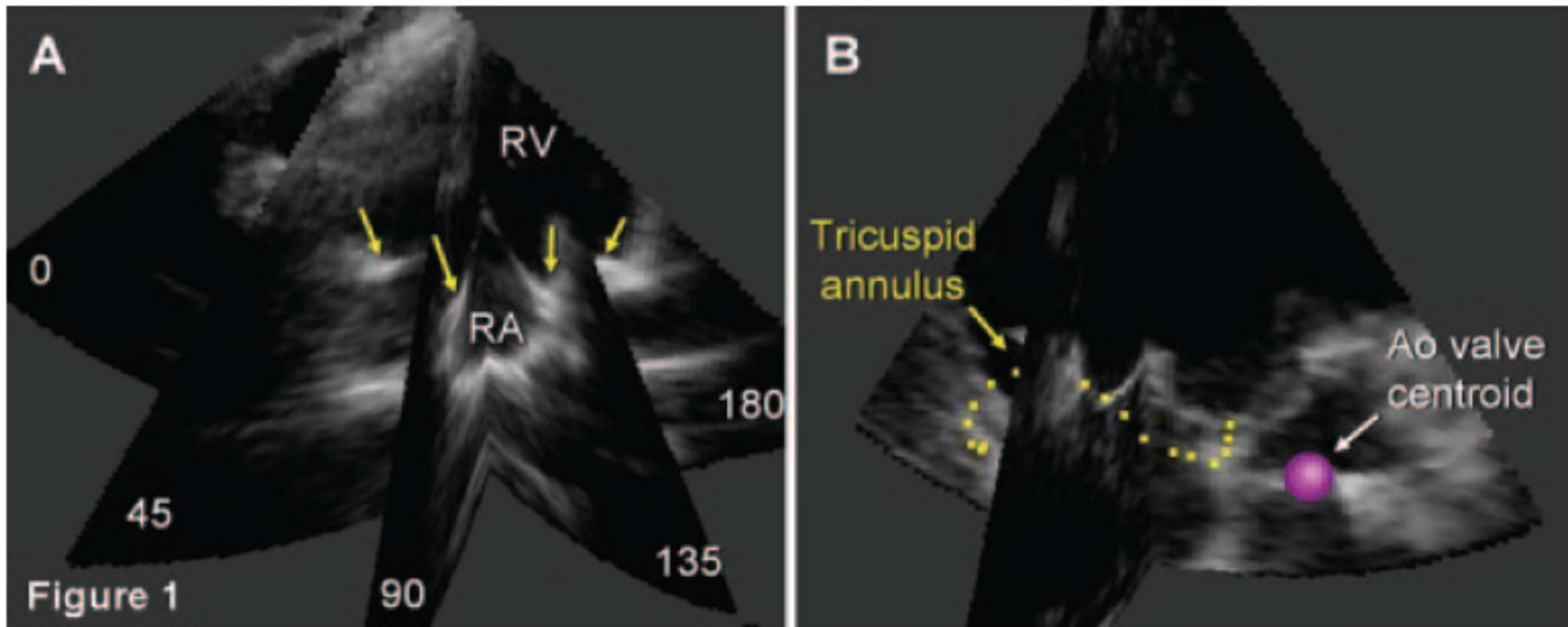
# LA Appendageal Thrombus



# Functional Tricuspid Regurgitation

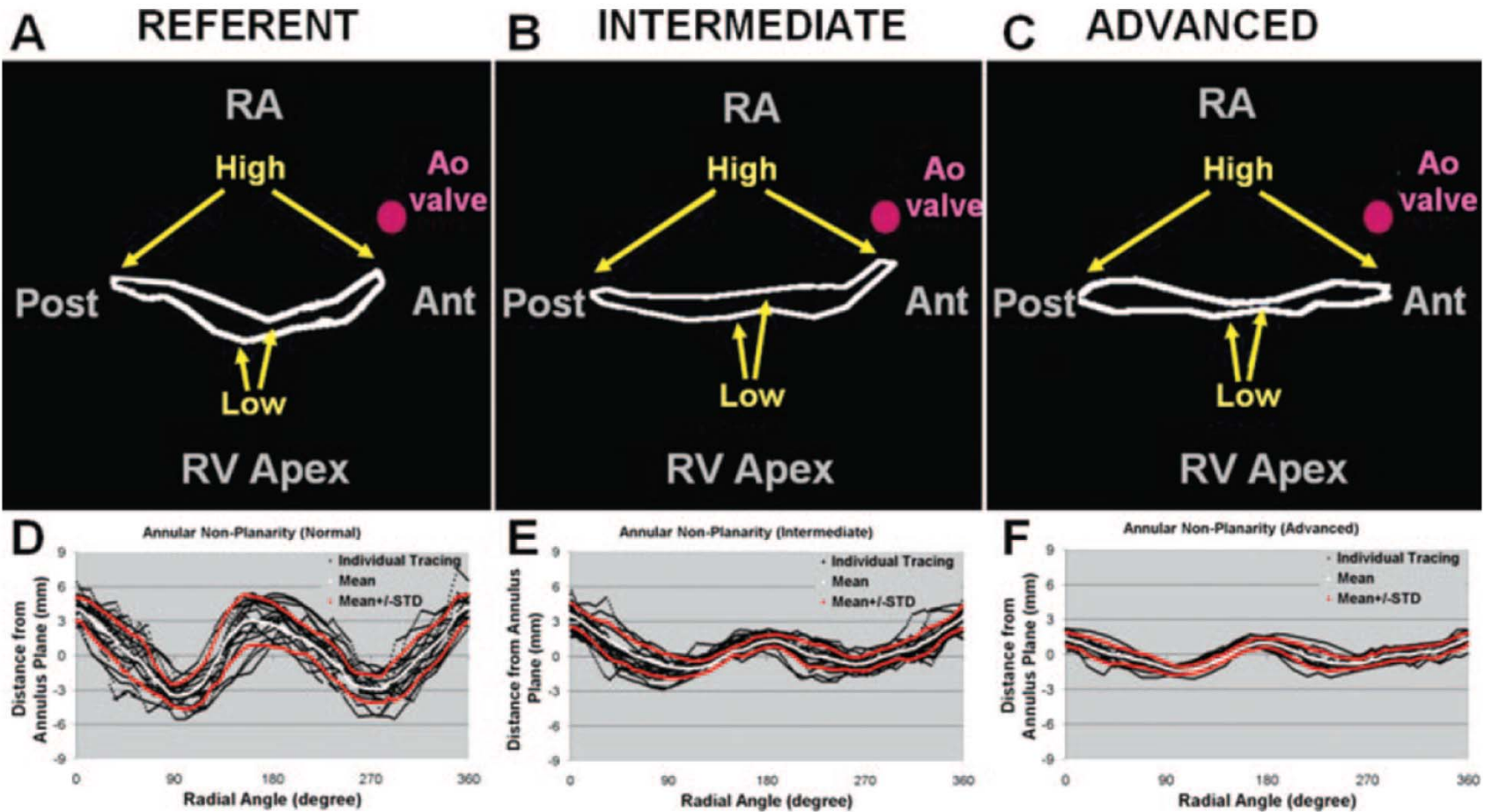


# Functional Tricuspid Regurgitation



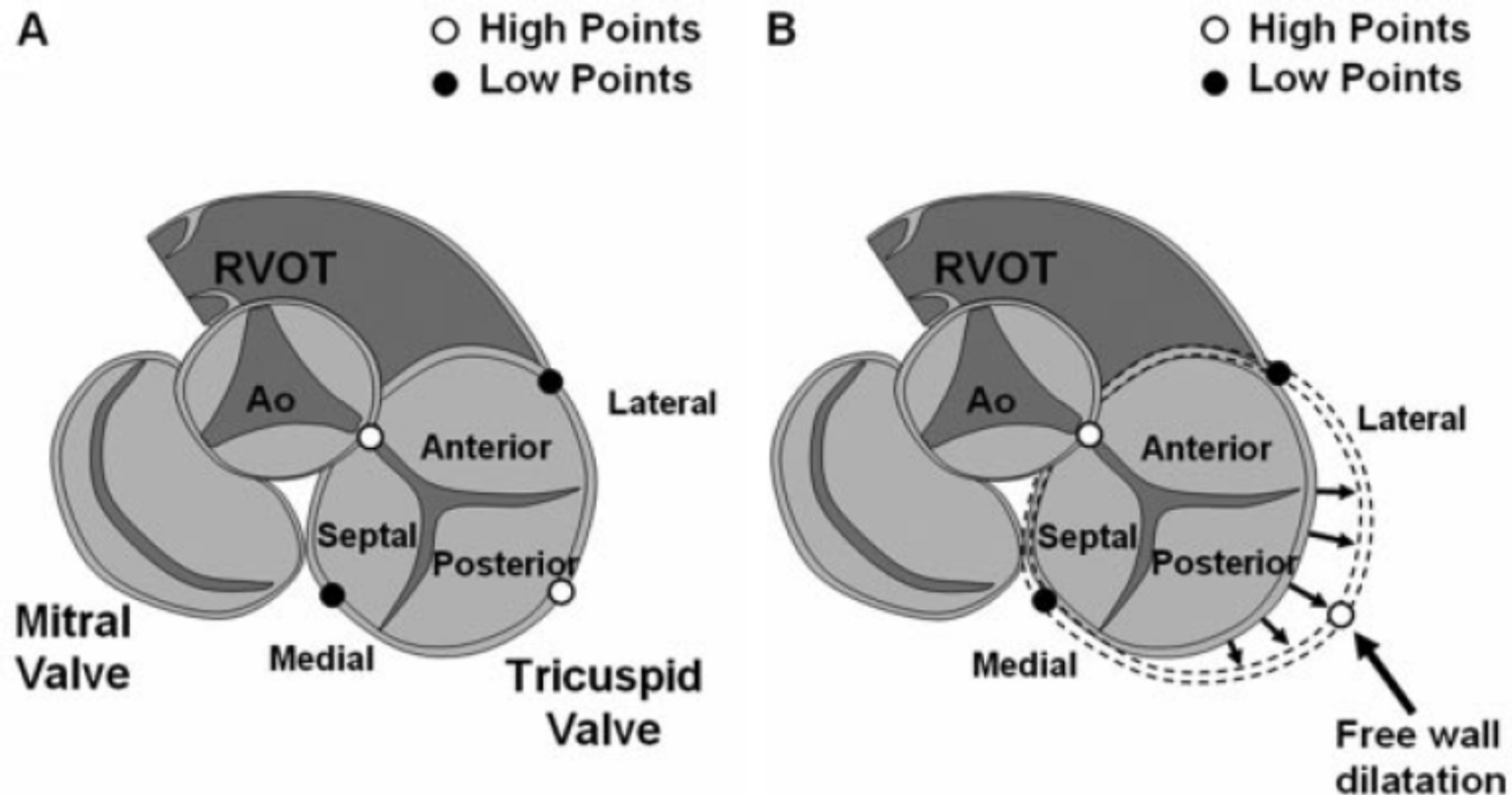
*Ton-Nu T et al. Circulation. 2006;114:143-9*

# Functional Tricuspid Regurgitation



Ton-Nu T et al. *Circulation*. 2006;114:143-9

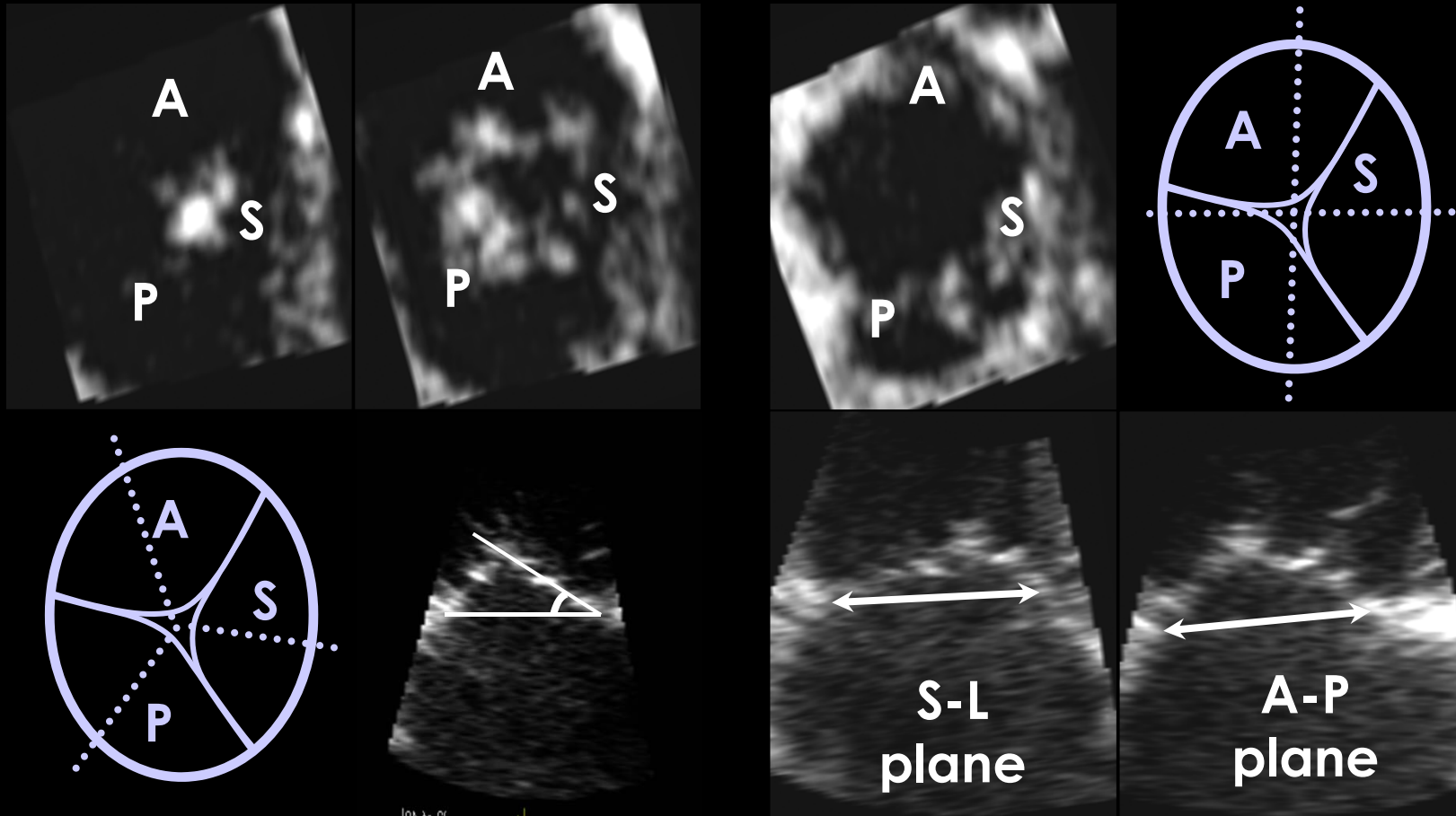
# Functional Tricuspid Regurgitation



*Ton-Nu T et al. Circulation. 2006;114:143-9*

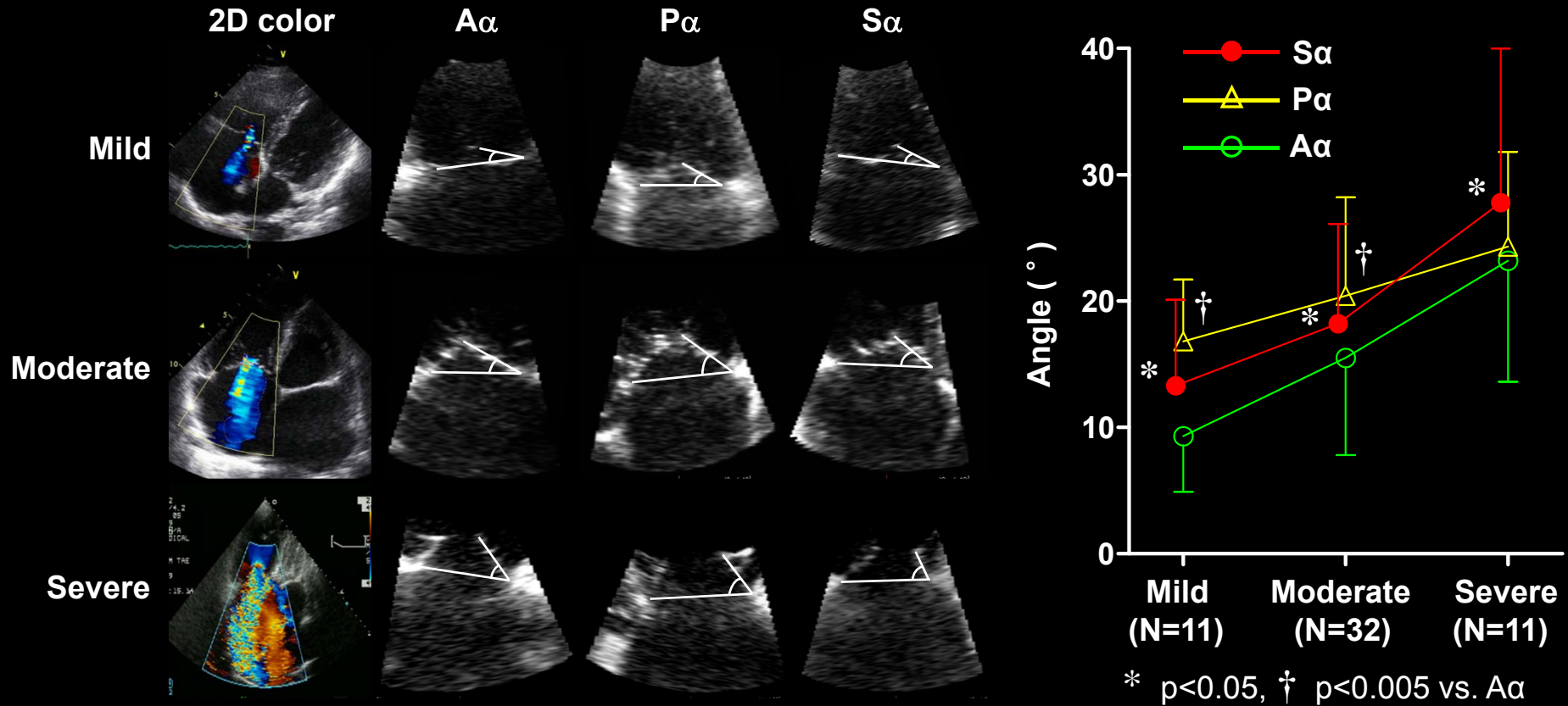
# Functional Tricuspid Regurgitation

- 54 patients with various degrees of functional tricuspid regurgitation



*Park YH et al. IJC 2008;124:160-5*

# Functional Tricuspid Regurgitation

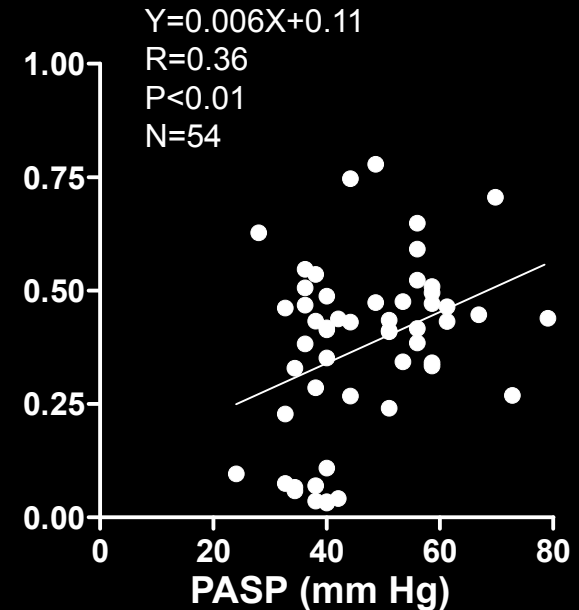
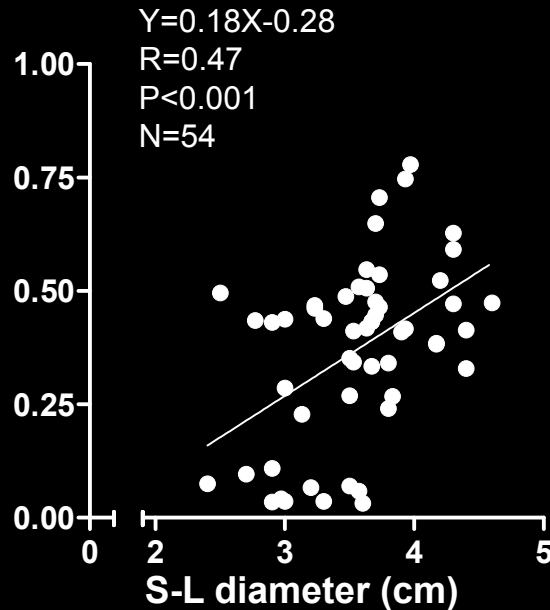
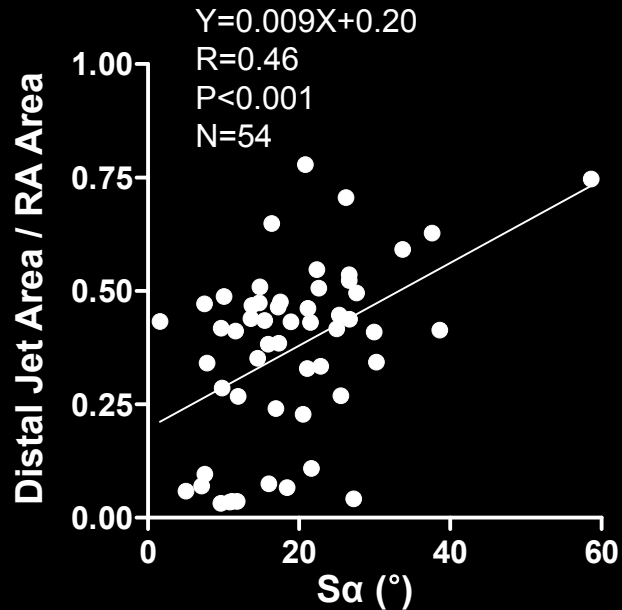


Park YH et al. IJC 2008;124:160-5

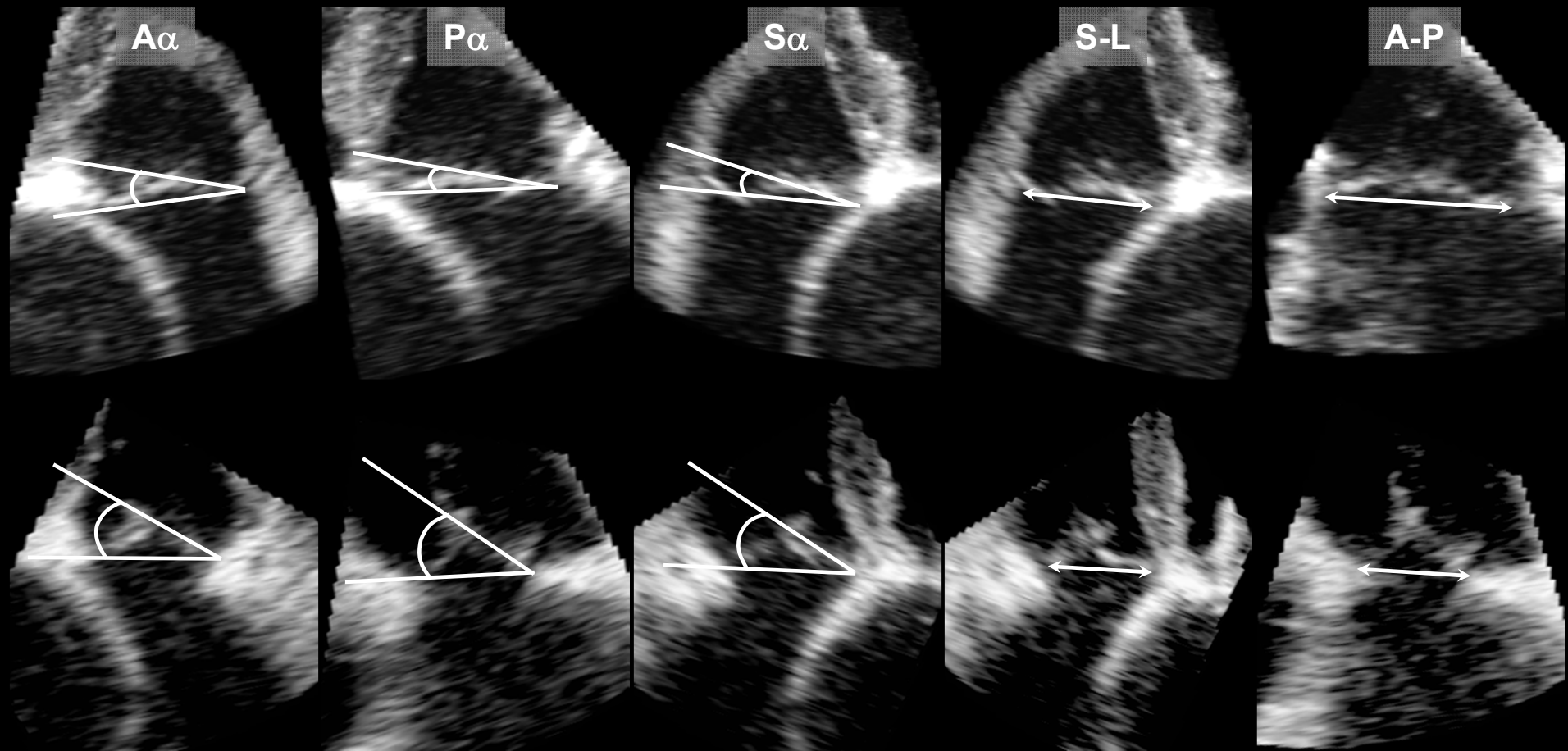


# Functional Tricuspid Regurgitation

Variables	r	Univariate P	Multivariate P
Aa	0.48	< 0.001	0.31
Pa	0.31	< 0.05	0.58
<b>Sa</b>	0.46	< 0.001	<b>&lt; 0.005</b>
<b>Septal-lateral (S-L) annulus diameter</b>	0.47	< 0.001	<b>&lt; 0.01</b>
Antero-posterior annulus diameter	0.46	< 0.001	0.58
Tricuspid tenting volume	0.49	< 0.001	0.30
<b>Pulmonary artery systolic pressure (PASP)</b>	0.36	< 0.01	<b>&lt; 0.05</b>



# Geometric Change After TAP



*Min SY, Eur Heart J. 2010;31; 2871-2880*

# Predictors of Severe TR After TAP

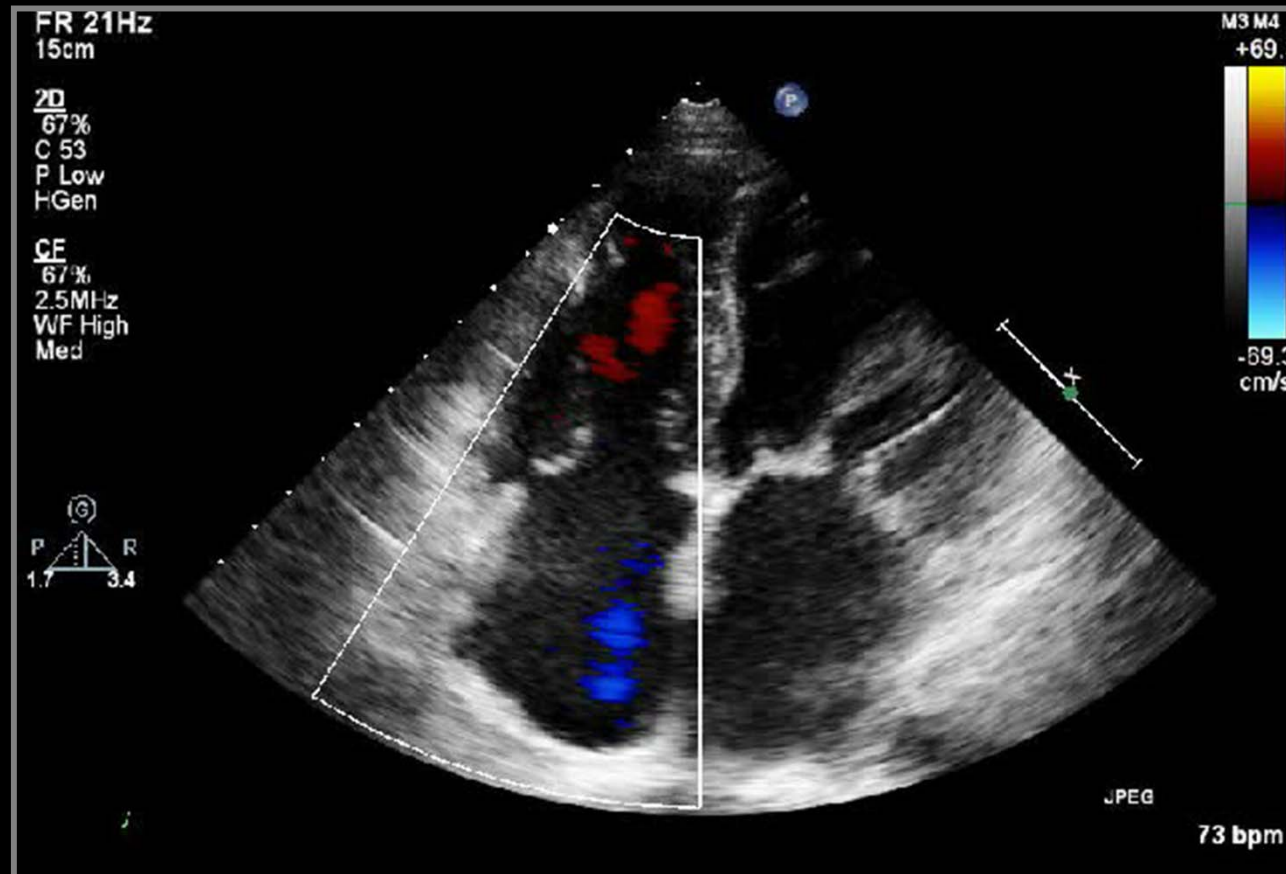
**Table 4** Univariate and multivariate linear regression analyses for residual tricuspid regurgitation severity assessed by distal jet area after tricuspid annuloplasty

	Pre-operative variables			Post-operative variables		
	r	Univariate P	Multivariate P	r	Univariate P	Multivariate P
TR distal jet area	0.471	<0.001				
A $\alpha$	0.328	0.012		-0.032	0.811	
P $\alpha$	0.274	0.037		0.051	0.702	
S $\alpha$	0.423	0.001		0.031	0.816	
Anterior leaflet length	0.004	0.976		0.029	0.830	
Posterior leaflet length	0.156	0.243		0.155	0.246	
Septal leaflet length	-0.031	0.818		0.014	0.918	
A-P annulus diameter	0.431	0.001	0.043	0.325	0.013	
S-L annulus diameter	0.218	0.100		0.166	0.212	
A-P RV inlet dimension	0.280	0.033		0.290	0.027	
S-L RV inlet dimension	0.134	0.316		0.162	0.225	
Tenting volume	0.563	<0.001	<0.001	0.481	<0.001	0.002
PASP	0.137	0.302		0.721	<0.001	<0.001
RV EDA	0.105	0.429		0.155	0.242	
RV ESA	0.100	0.451		0.232	0.077	0.027
RV FAC	-0.133	0.316		-0.303	0.019	

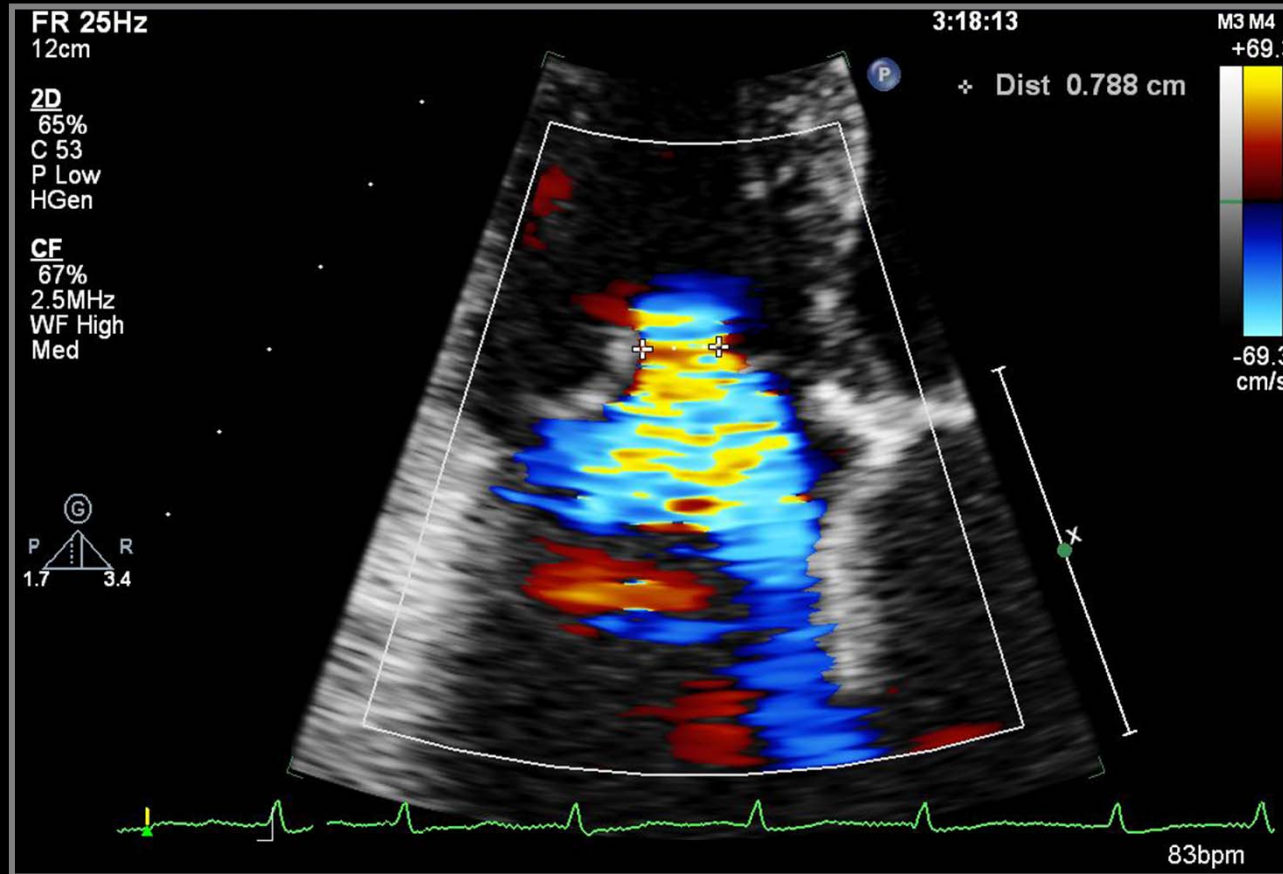
A $\alpha$ , anterior leaflet tenting angle; A-P, antero-posterior; EDA, end-diastolic area; ESA, end-systolic area; FAC, fractional area change; PASP, pulmonary artery systolic pressure; P $\alpha$ , posterior leaflet tenting angle; RV, right ventricle; S $\alpha$ , septal leaflet tenting angle; S-L, septal-lateral; TR, tricuspid regurgitation.

*Min SY, Eur Heart J. 2010;31: 2871–2880*

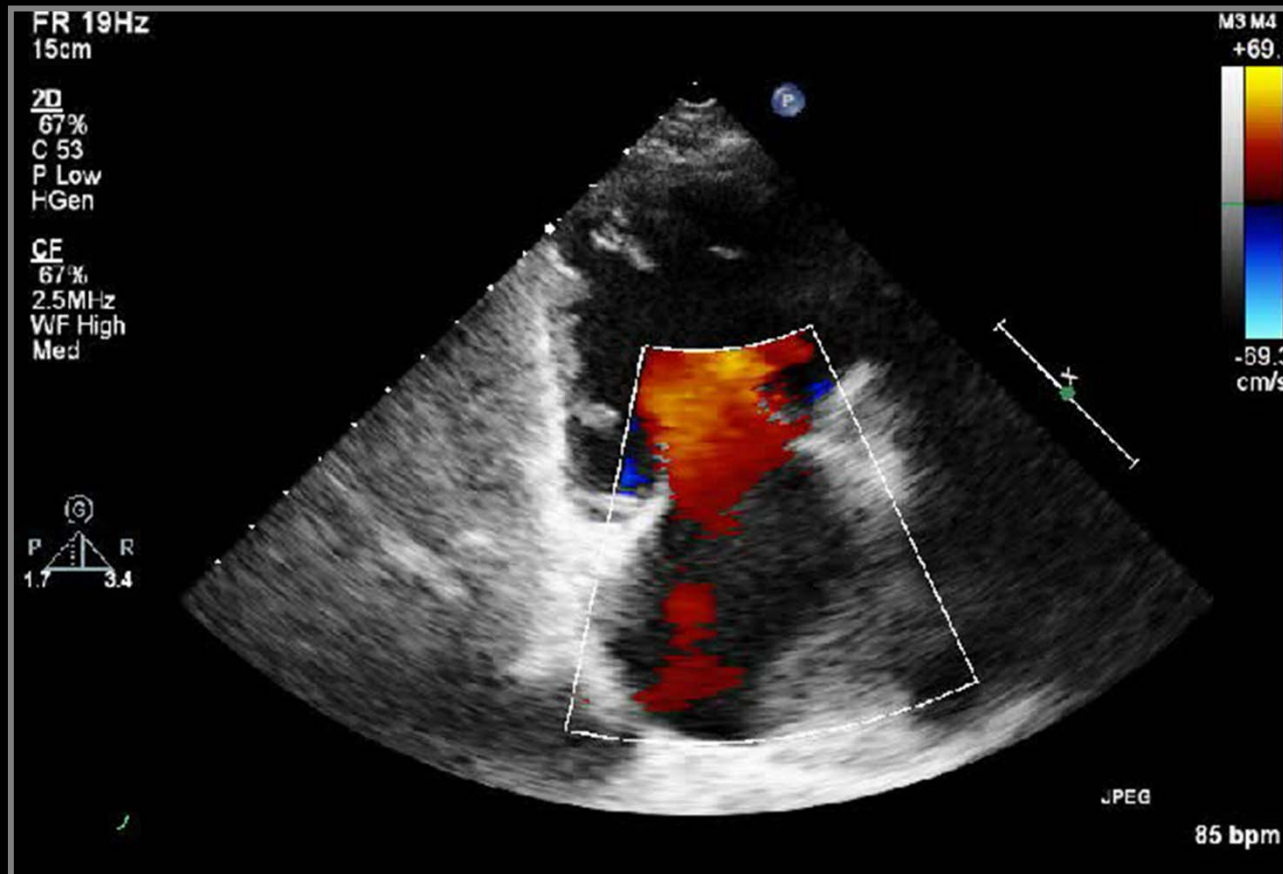
# Vena Contracta of Functional TR



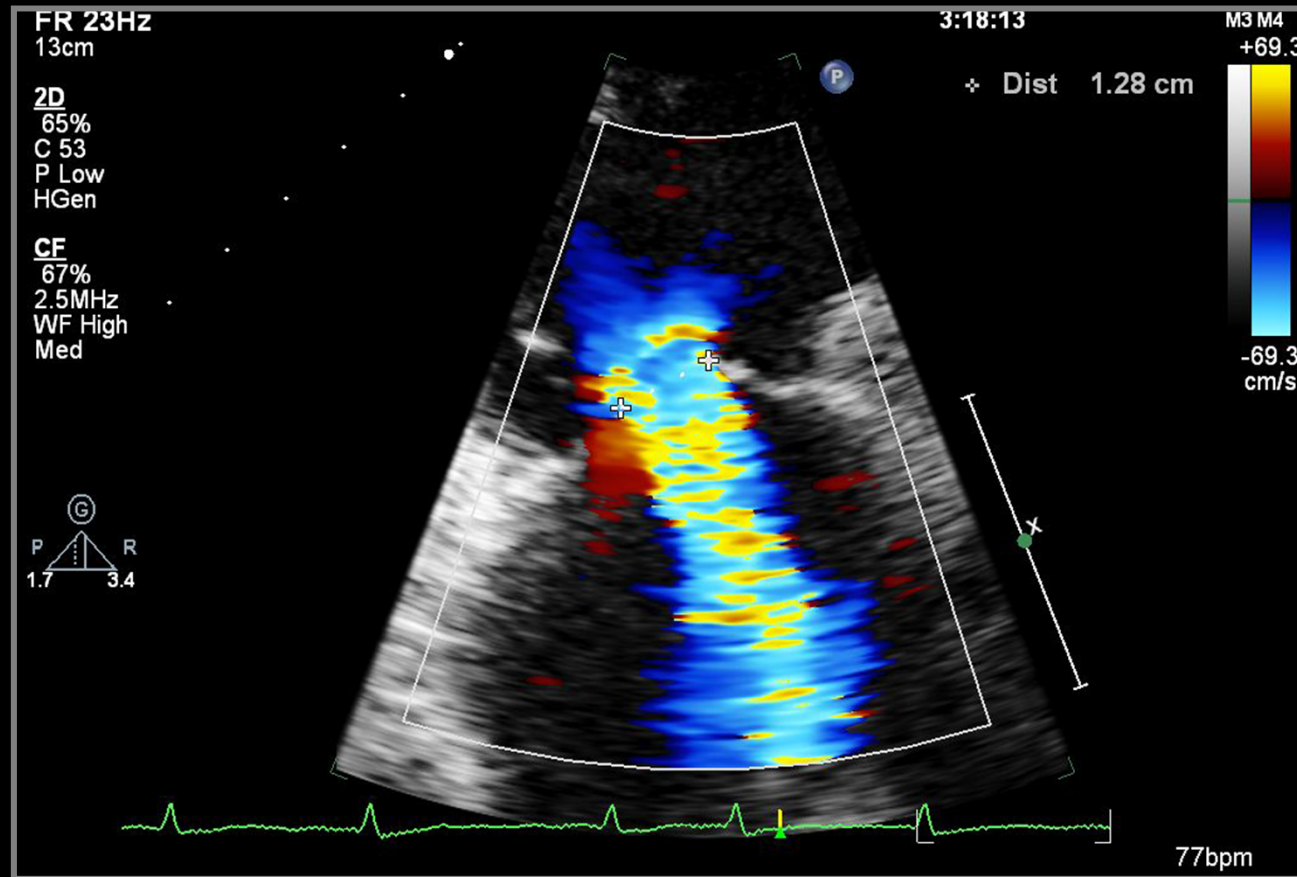
# Vena Contracta of Functional TR



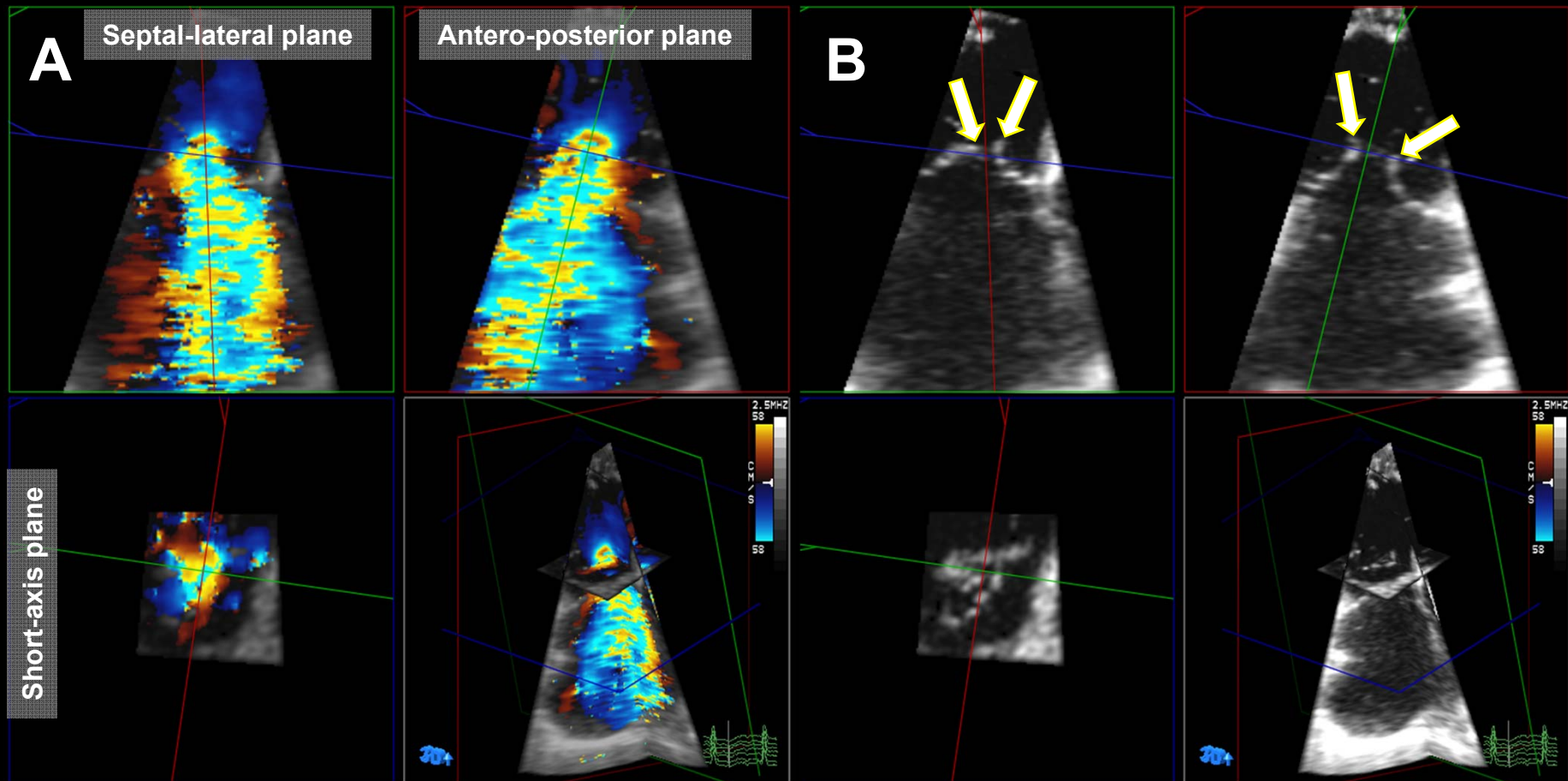
# Vena Contracta of Functional TR



# Vena Contracta of Functional TR



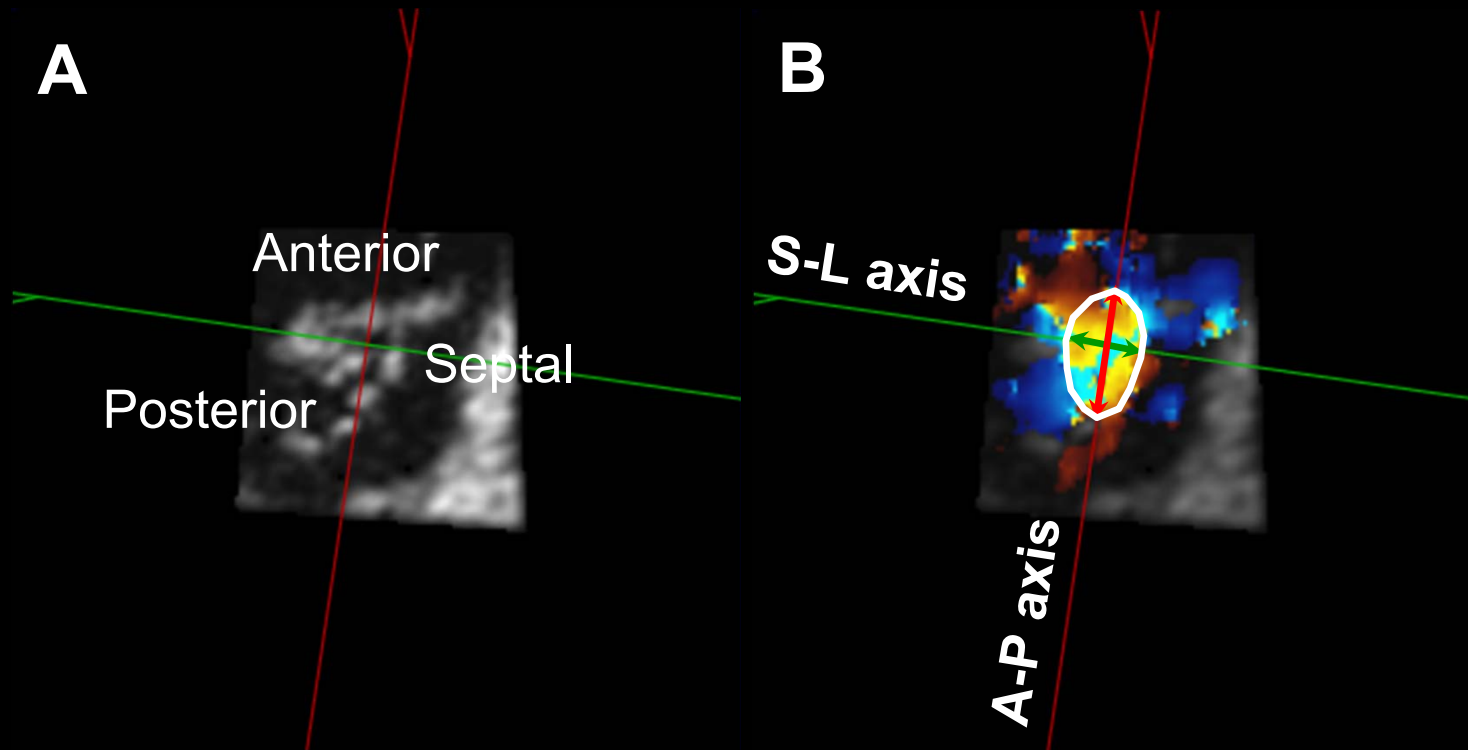
# Vena Contracta Widths



*Song JM, JASE 2011 (Epub)*

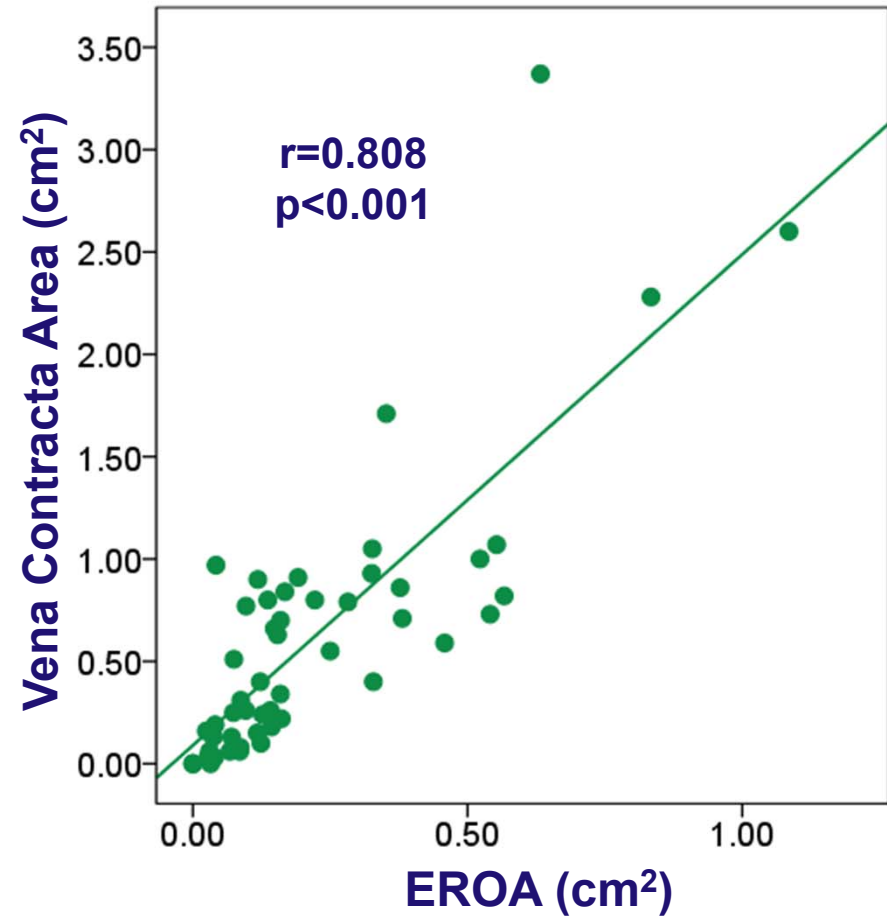
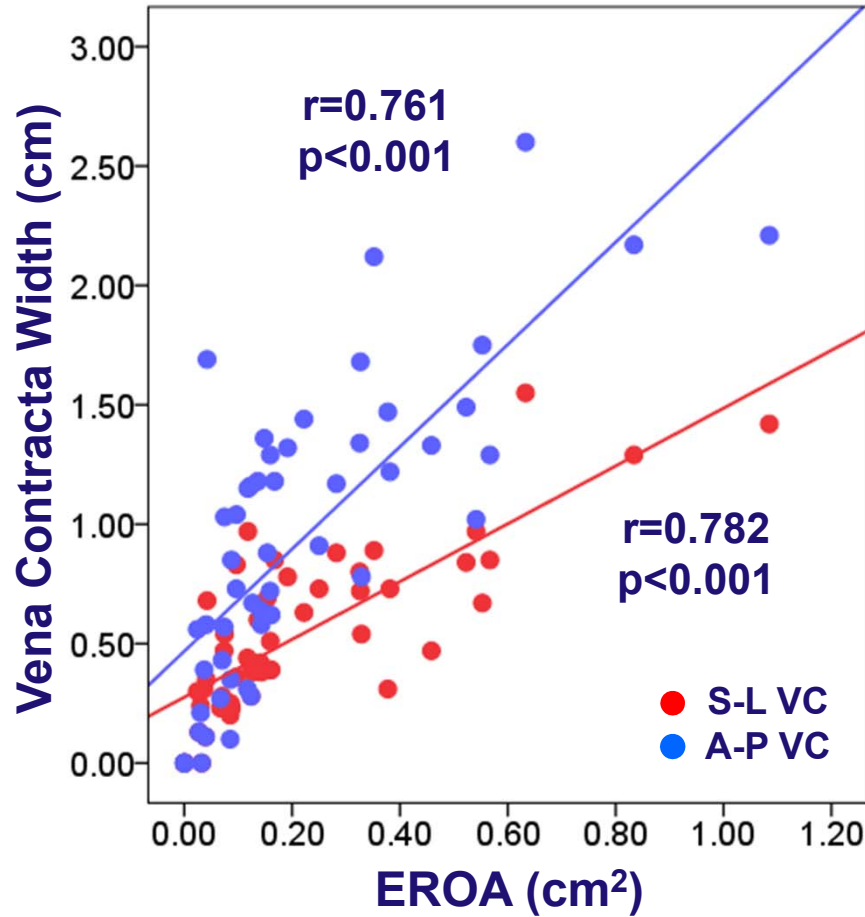


# Measurements by RT3DE



*Song JM, JASE 2011 (Epub)*

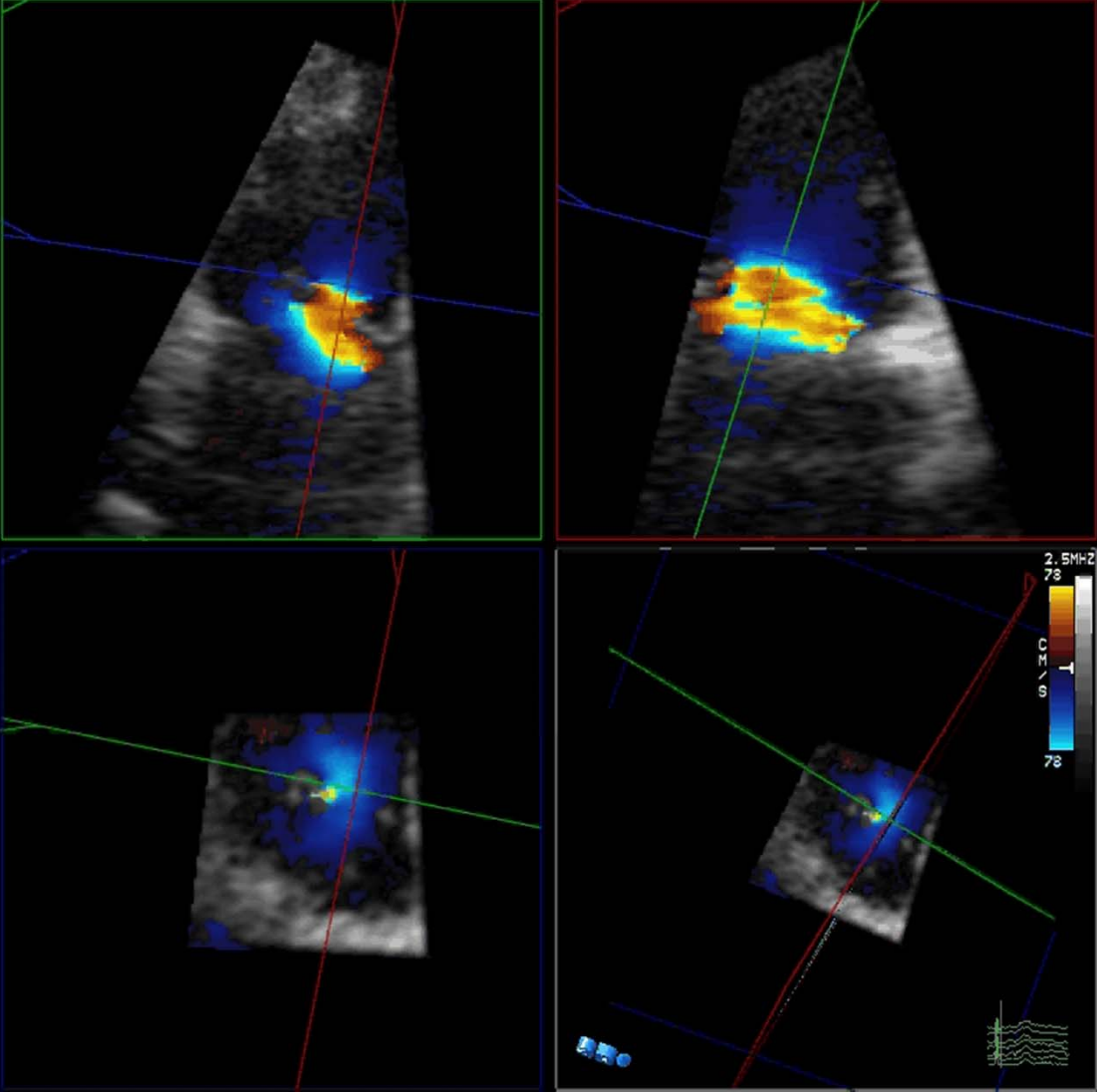
# EROA & Vena Contracta



A-P VC – S-L VC:  $0.39 \pm 0.37$  cm,  $p<0.001$

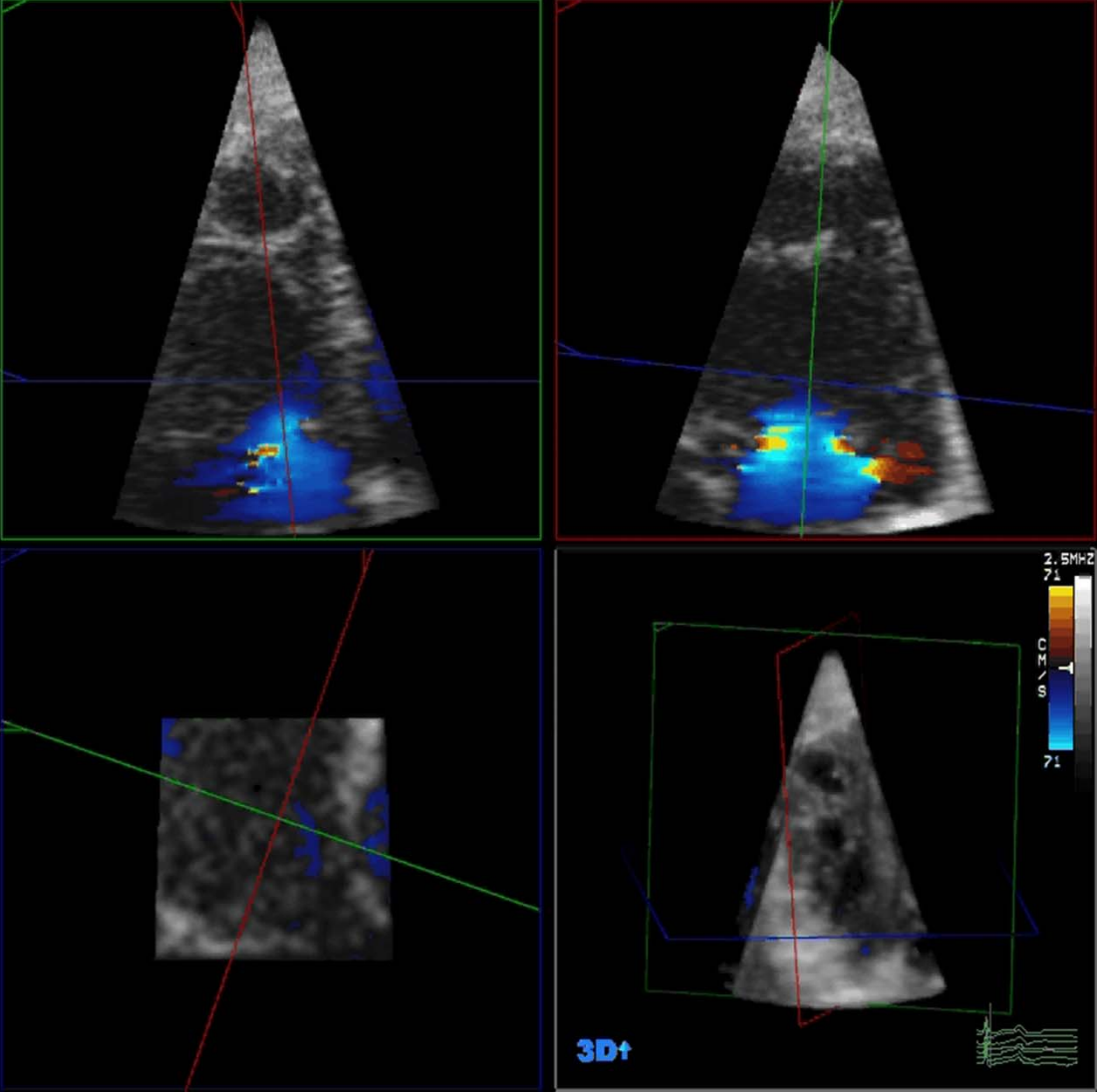
*Song JM, JASE 2011 (Epub)*

# VC Widths



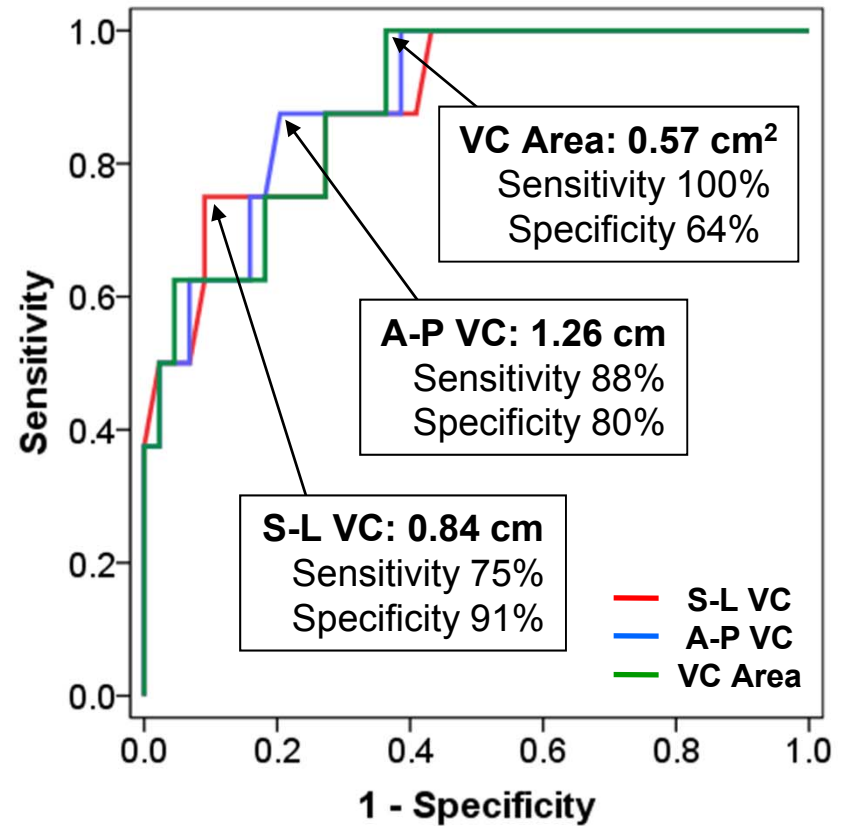
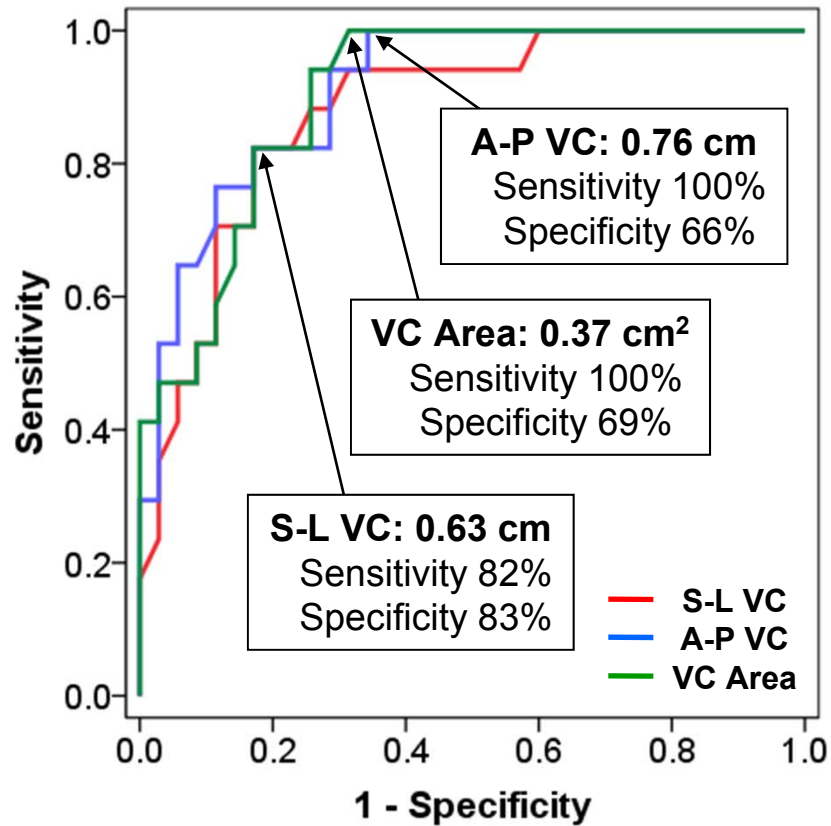
PHILIPS

# VC Widths



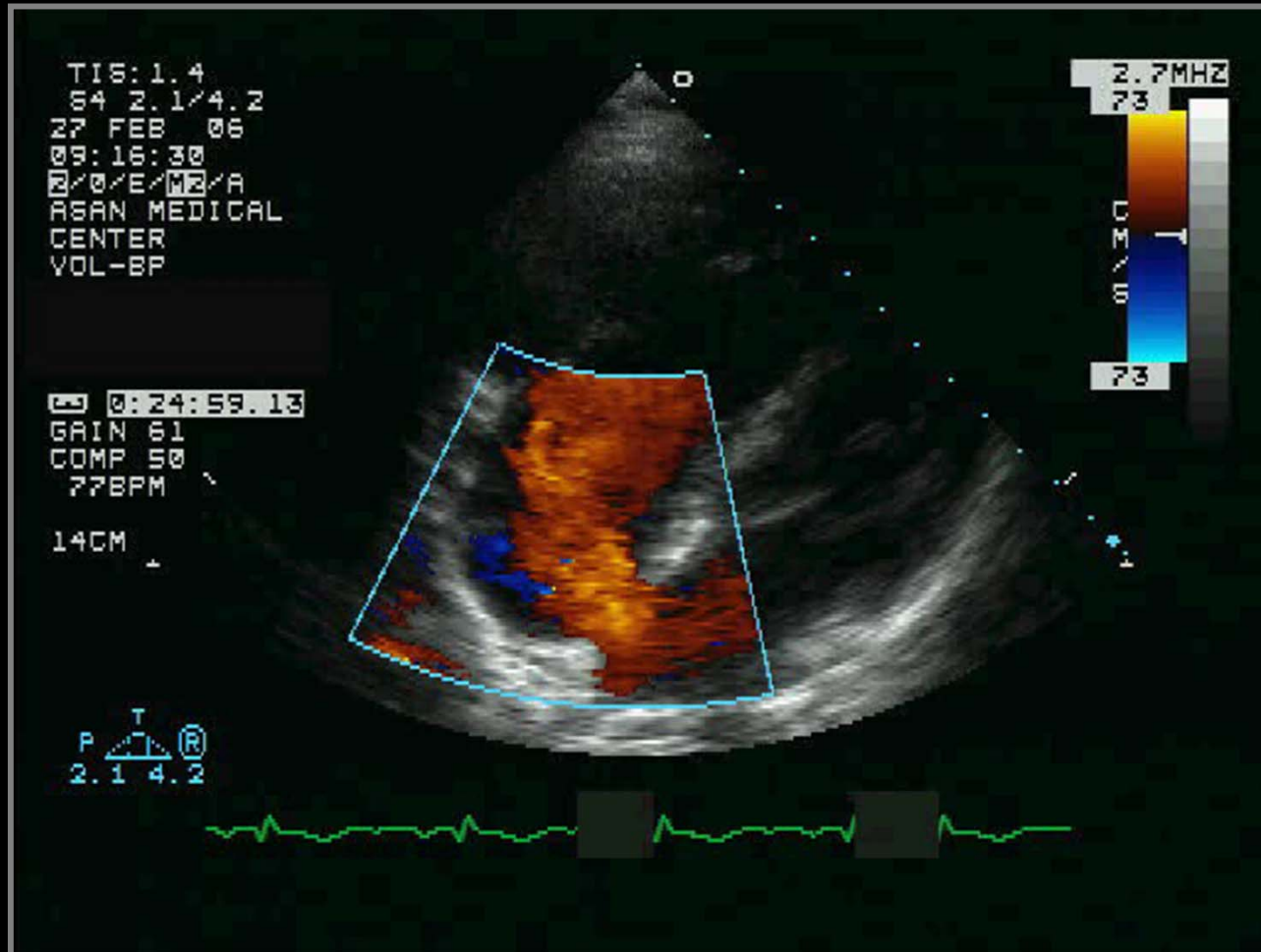
PHILIPS

# 3D Vena Contracta

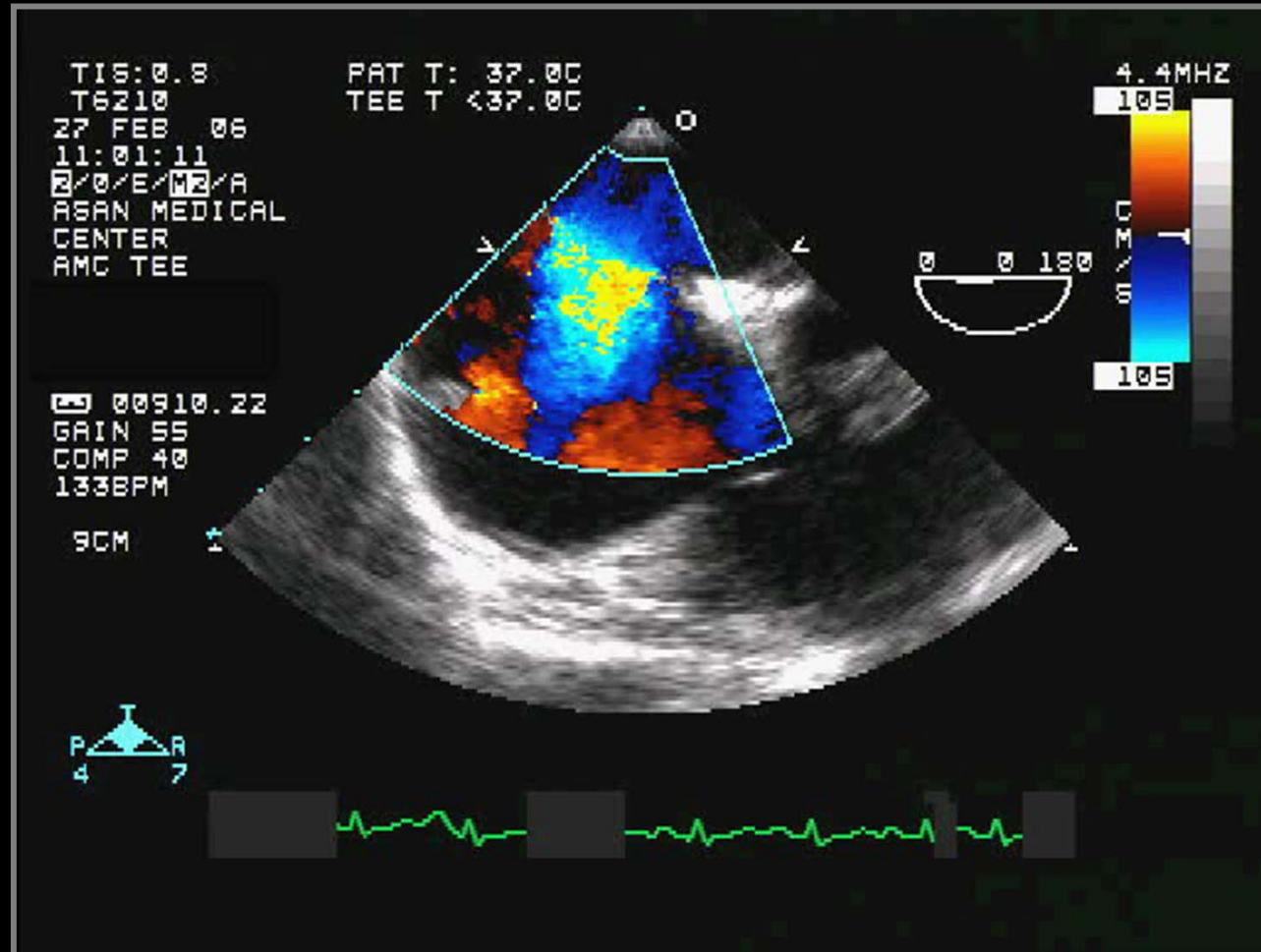


*Song JM, JASE 2011 (Epub)*

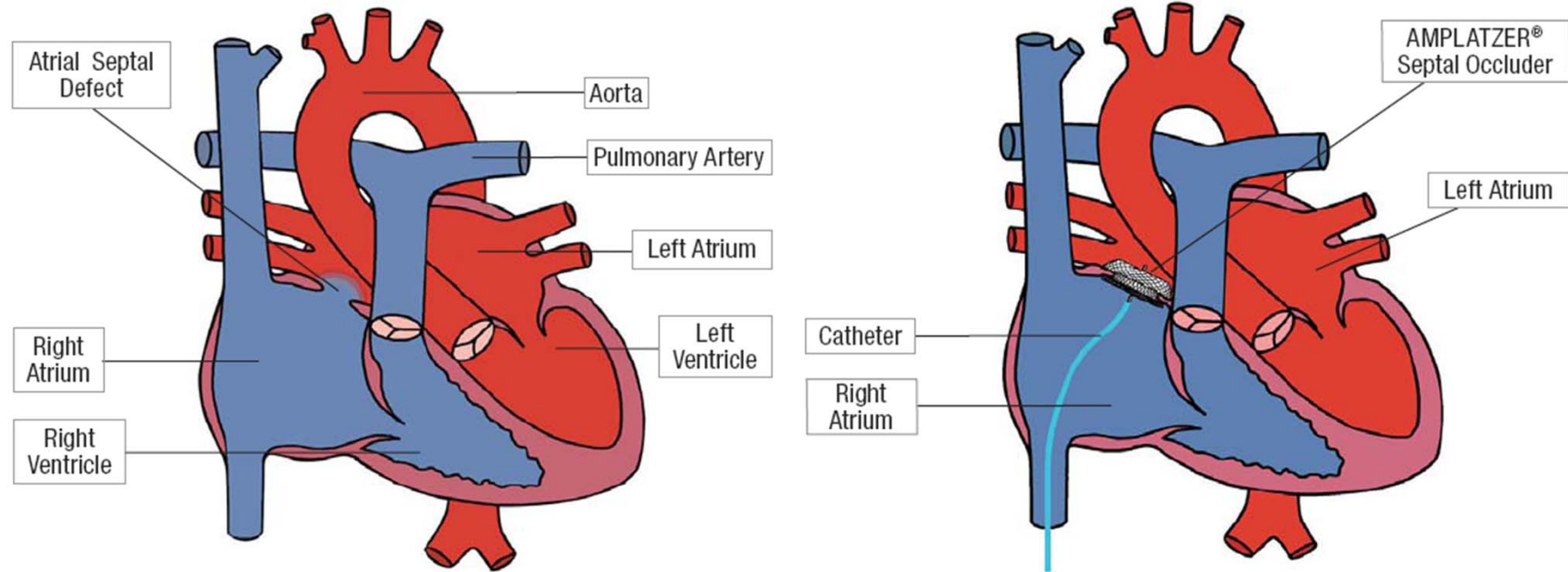
# Secundum ASD (29/F)



# Secundum ASD (29/F)

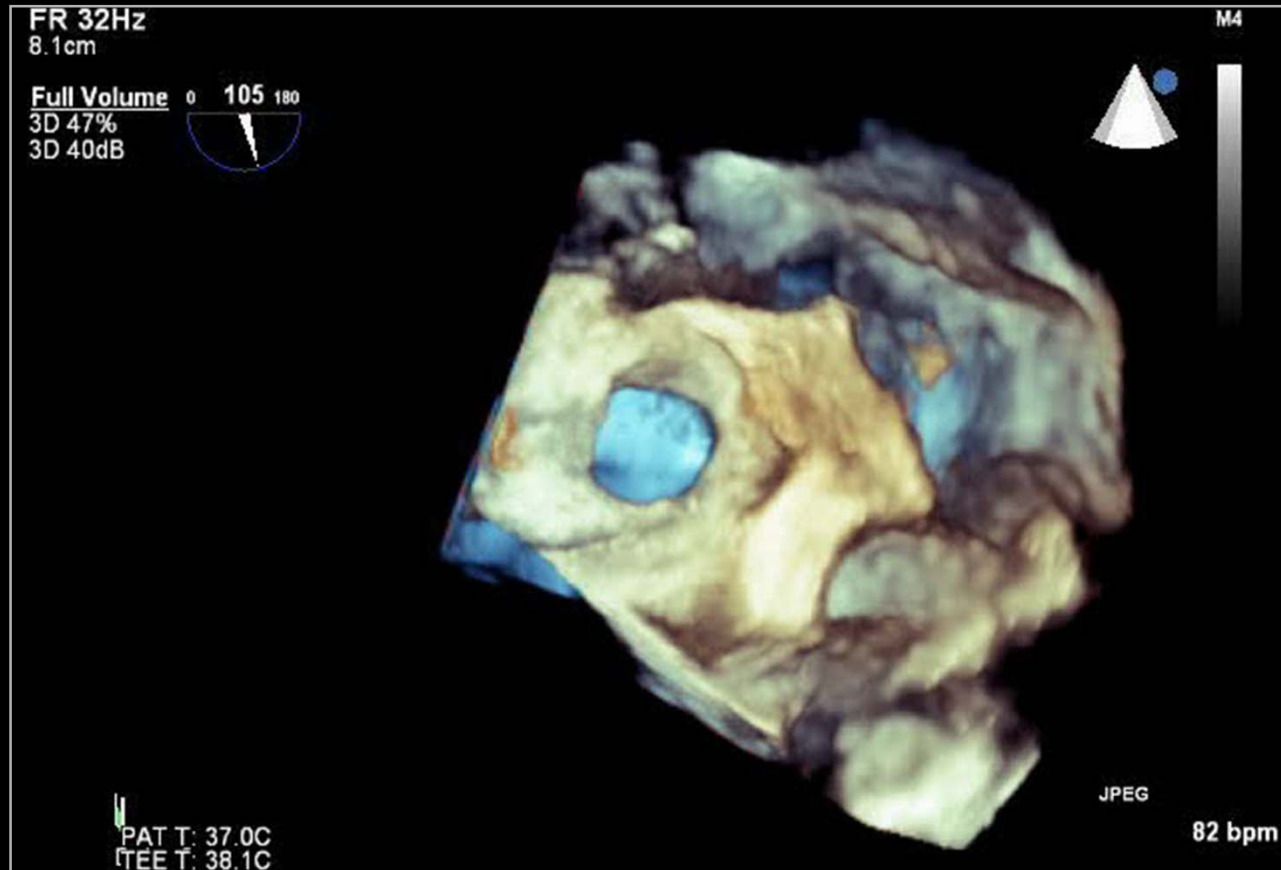


# Atrial Septal Occluder

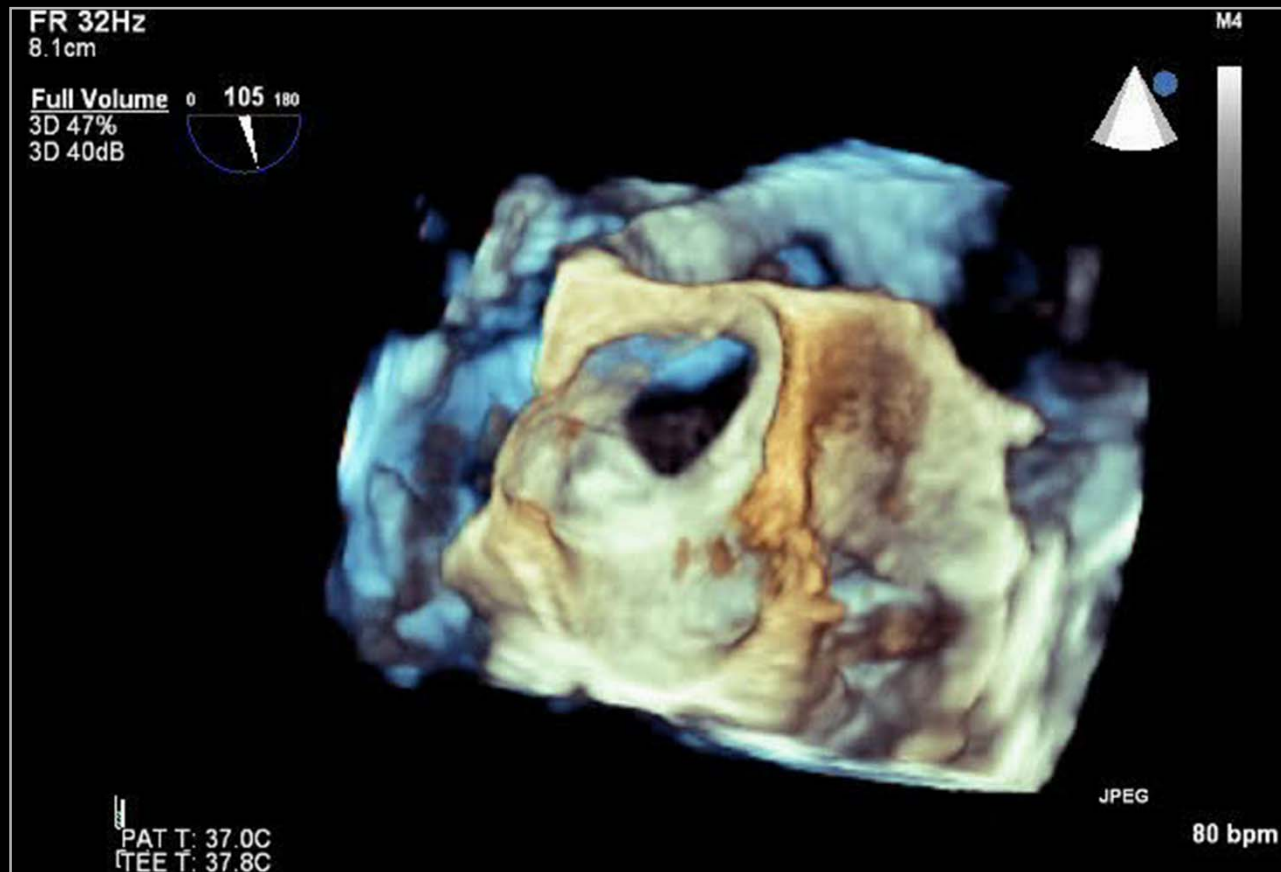




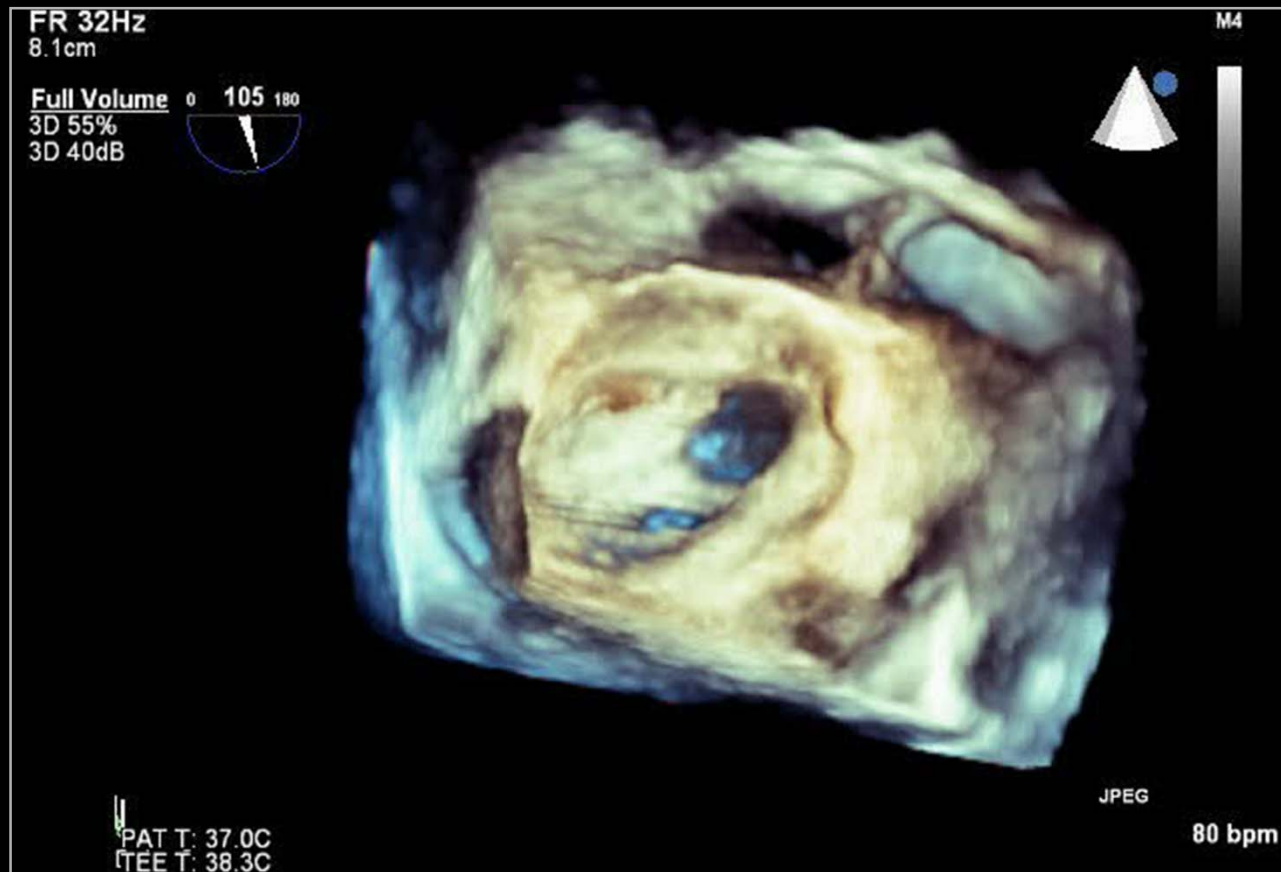
# Round ASD



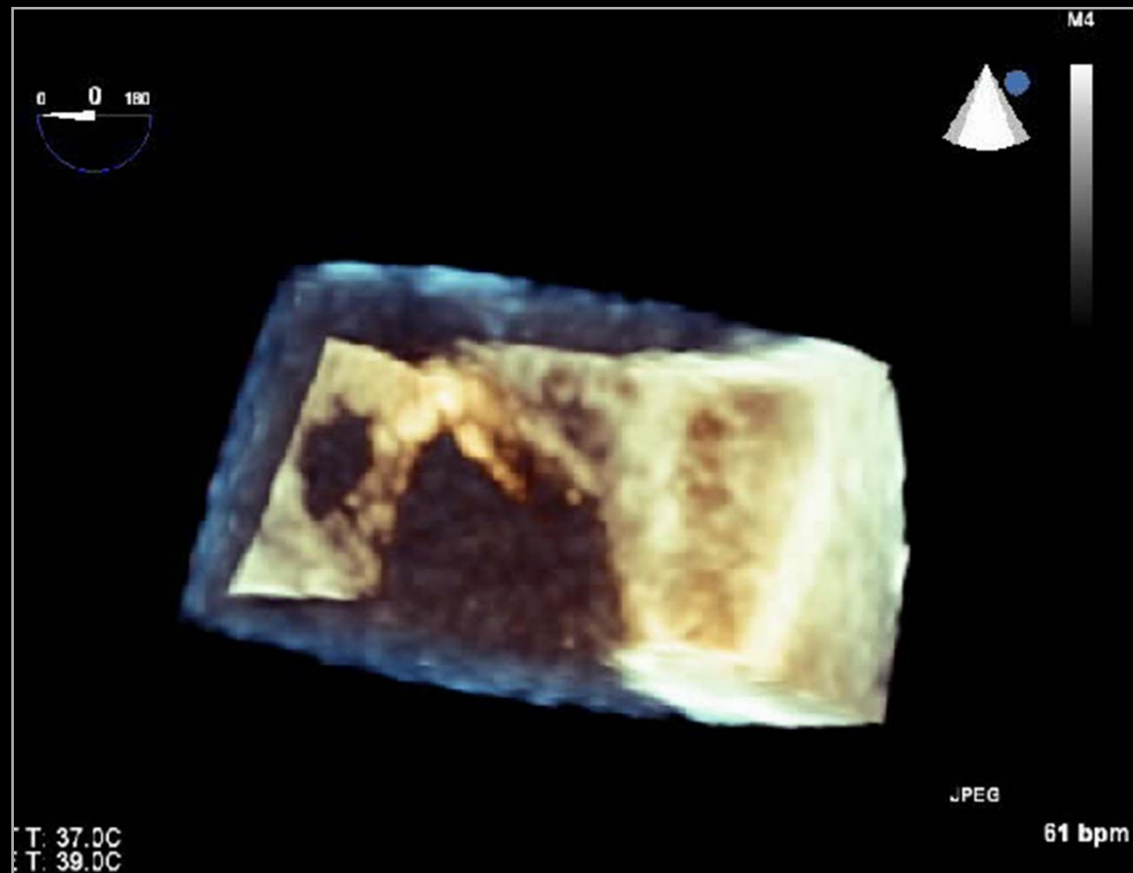
# Ellipsoidal ASD



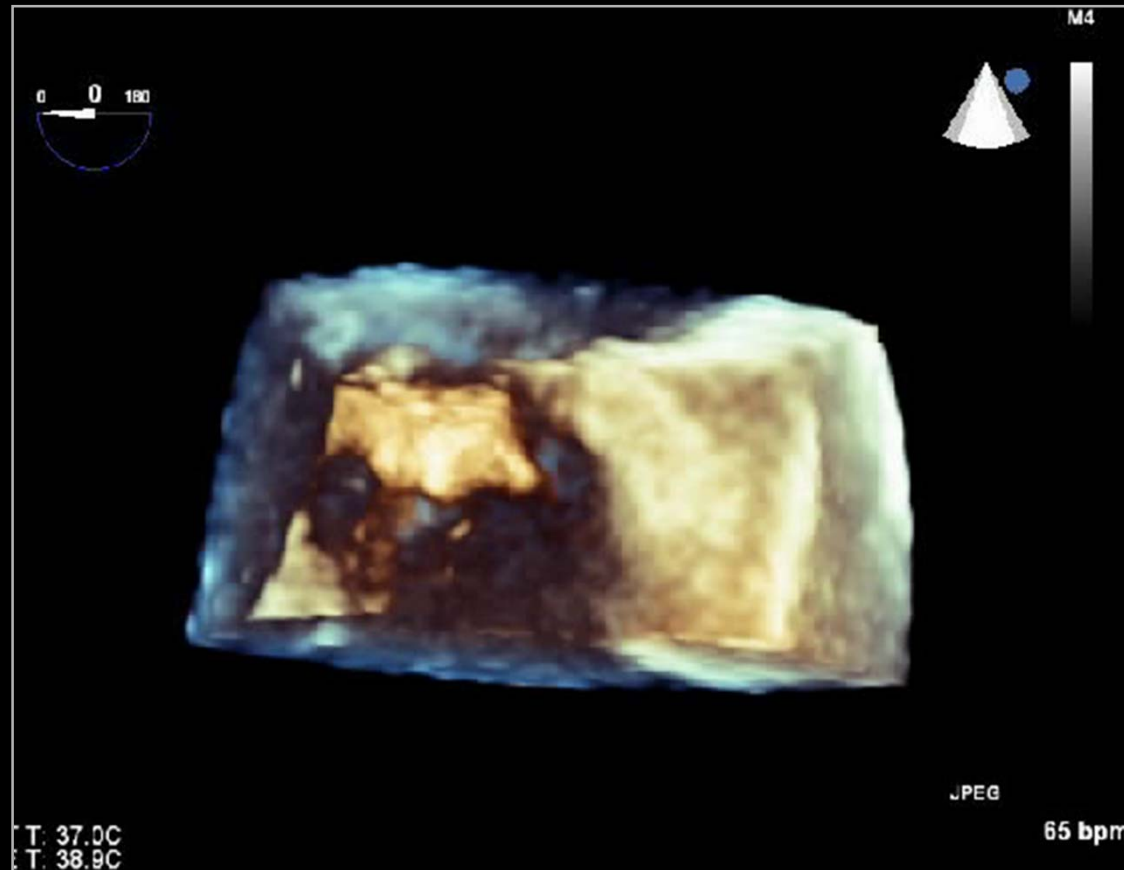
# Multiple ASD



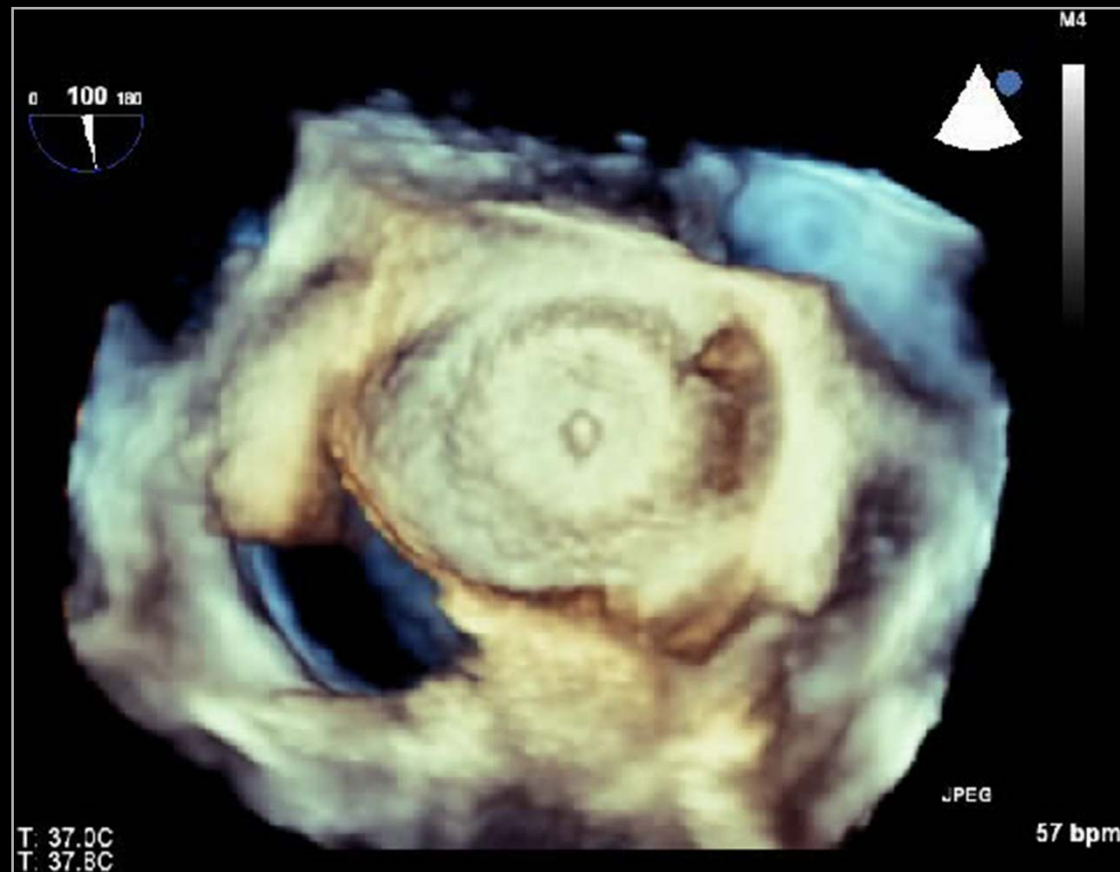
# Multiple ASD



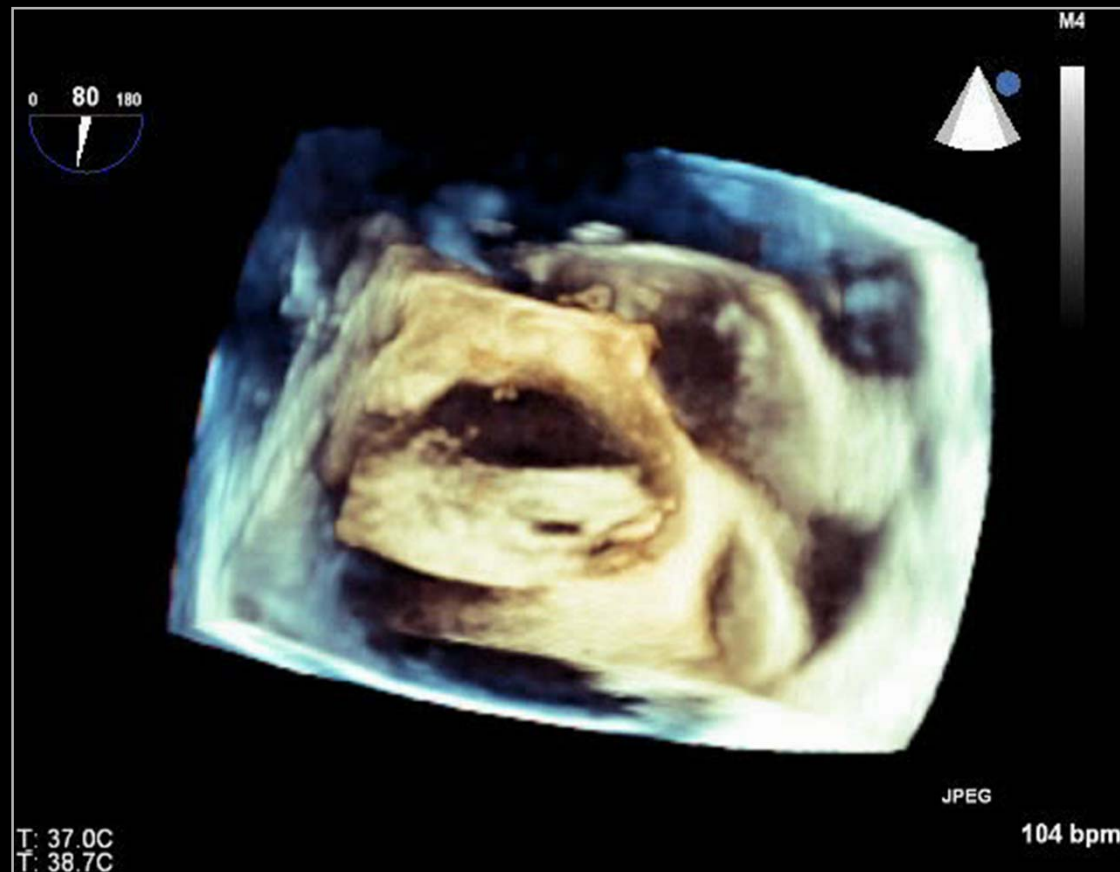# Multiple ASD



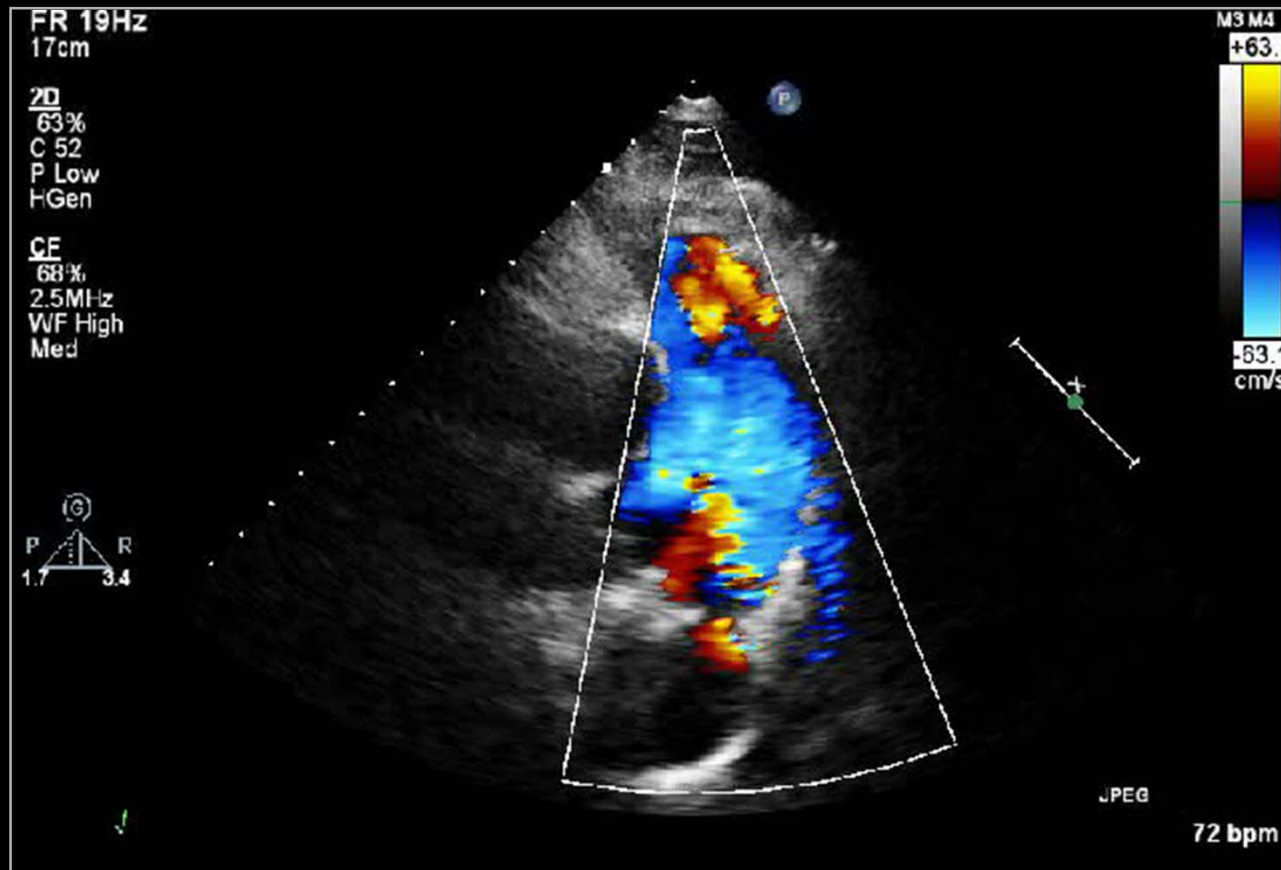
# Multiple ASD



# Multiple ASD

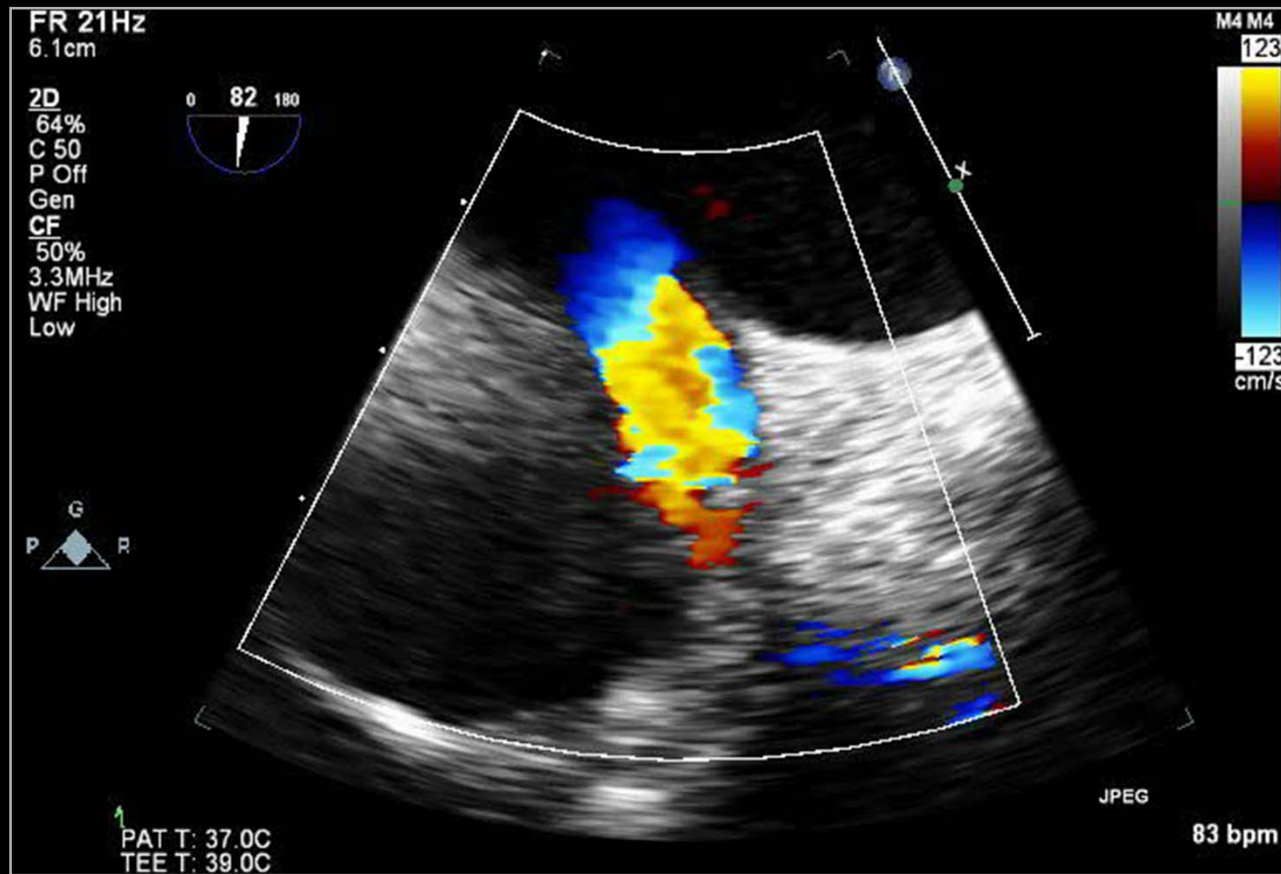


# Patent Ductus Arteriosus

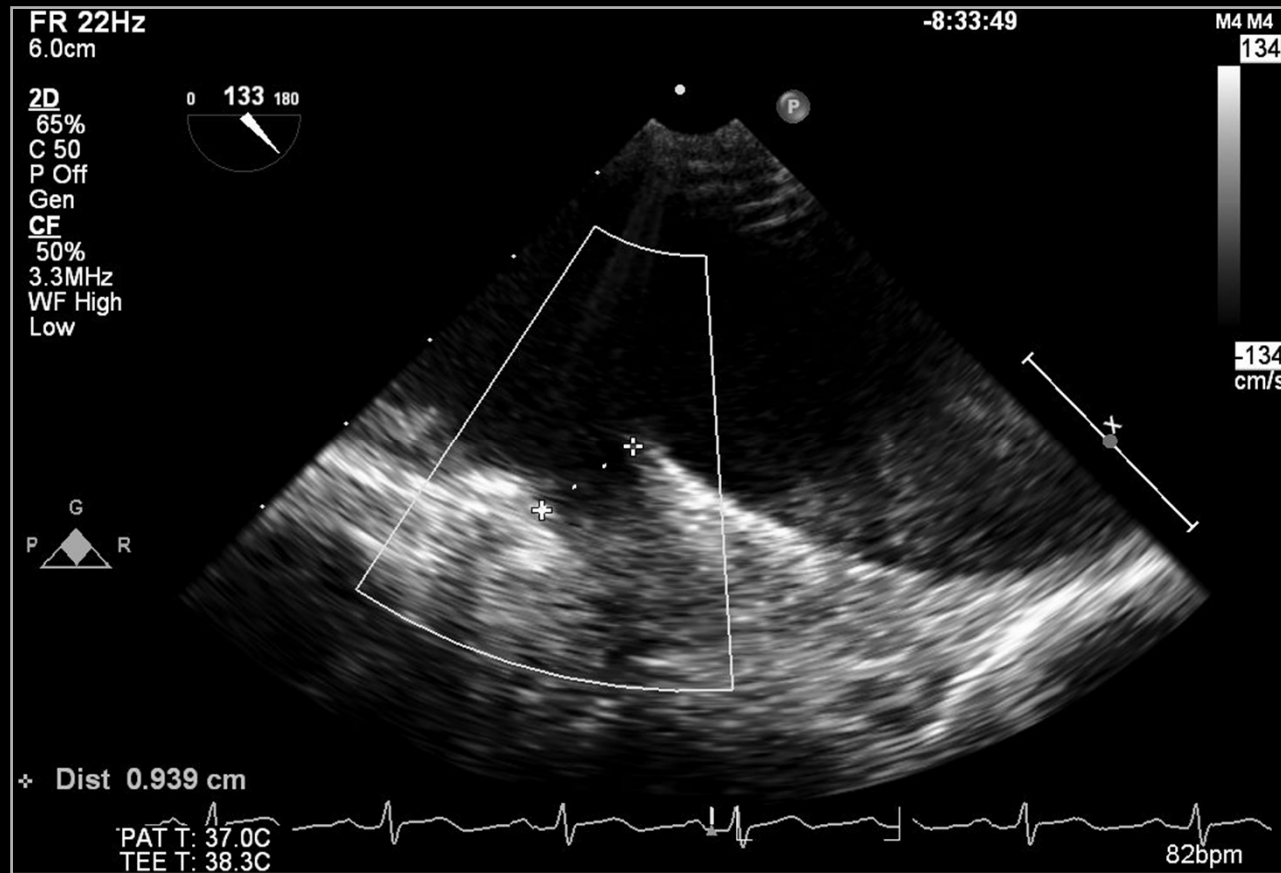




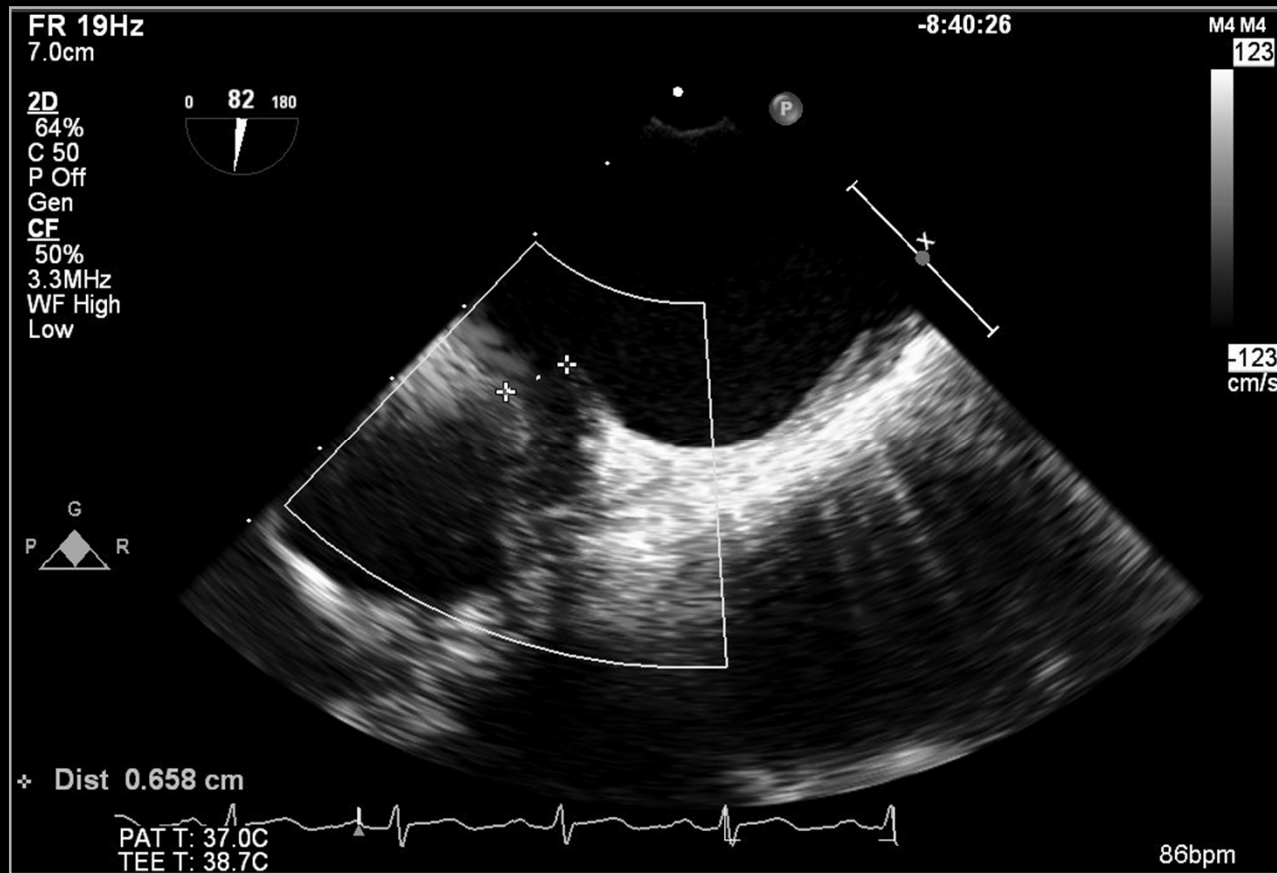
# Patent Ductus Arteriosus



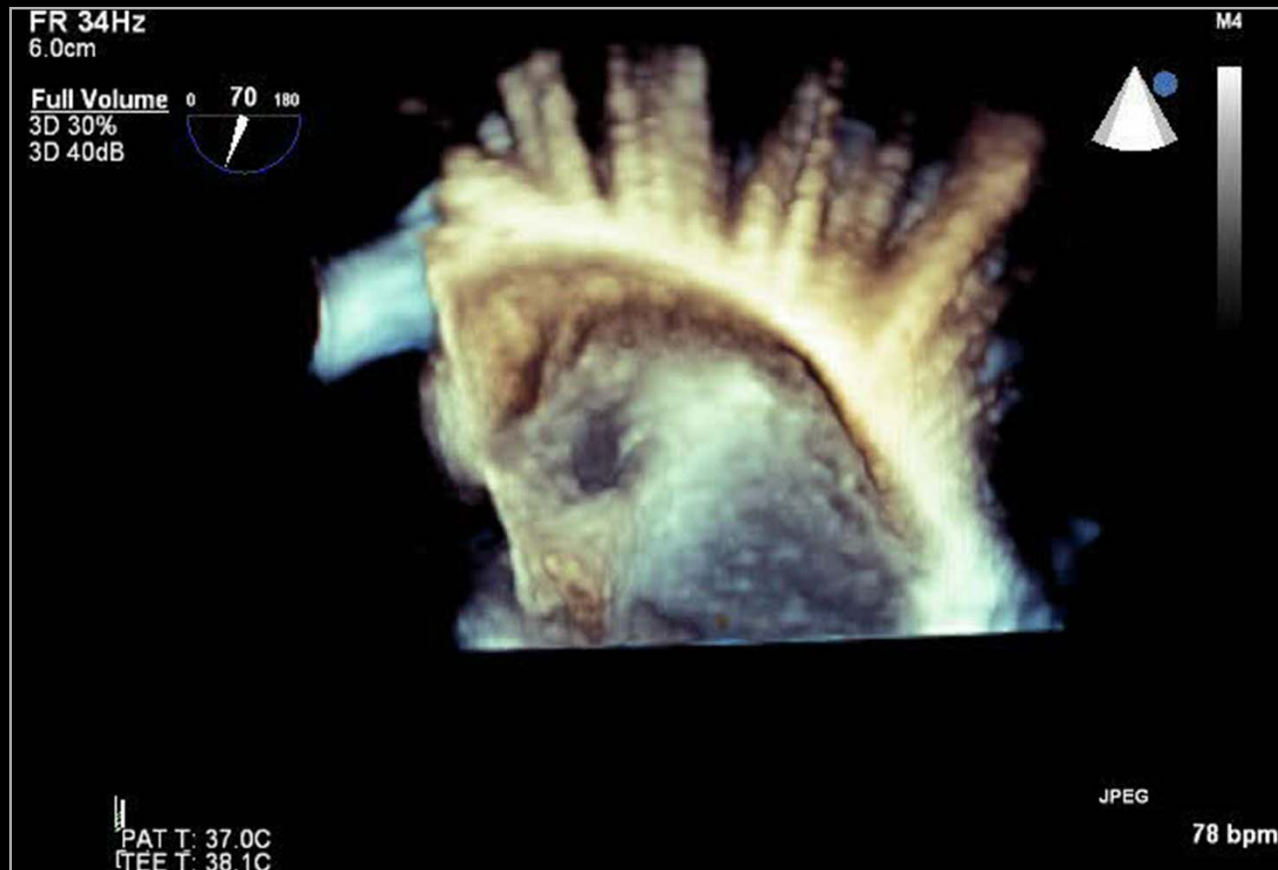
# Patent Ductus Arteriosus



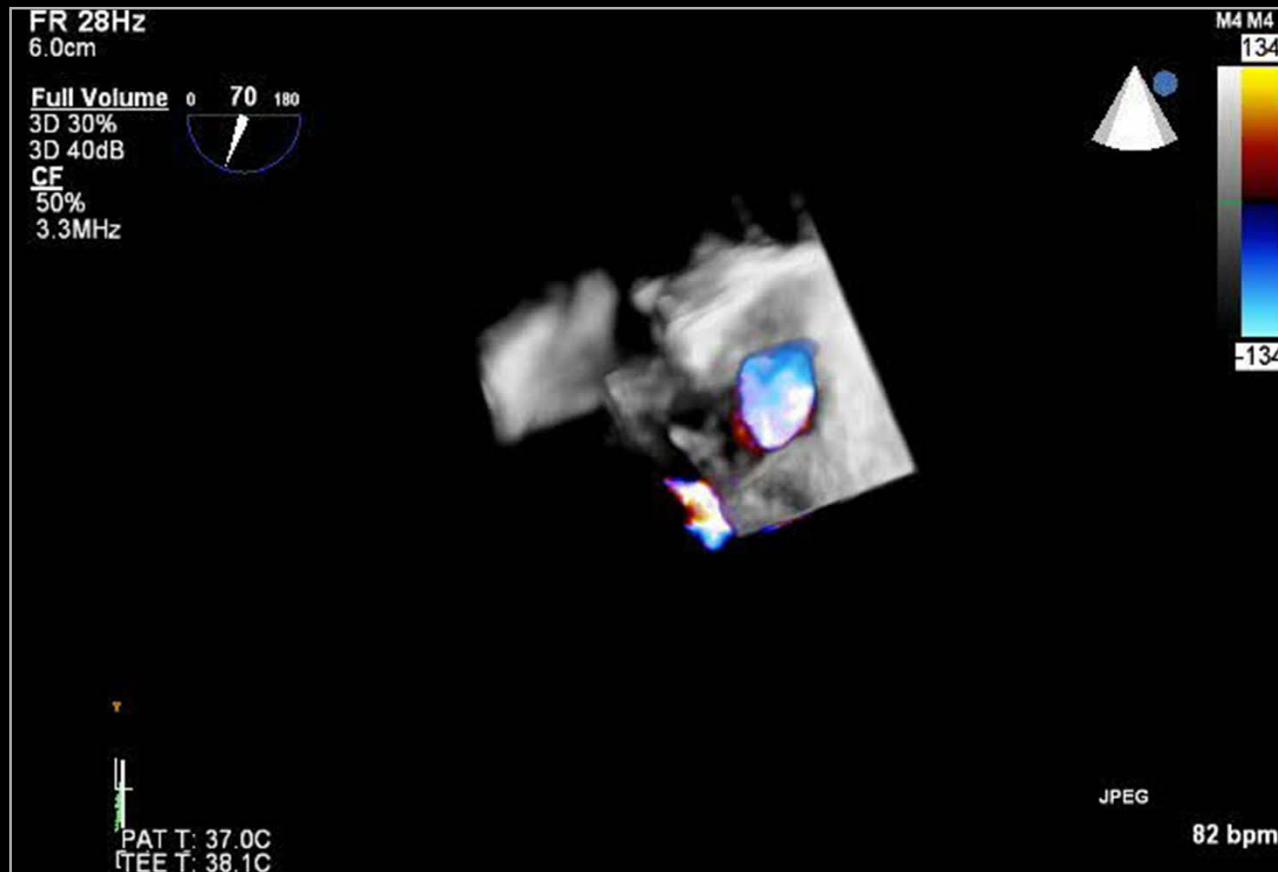
# Patent Ductus Arteriosus



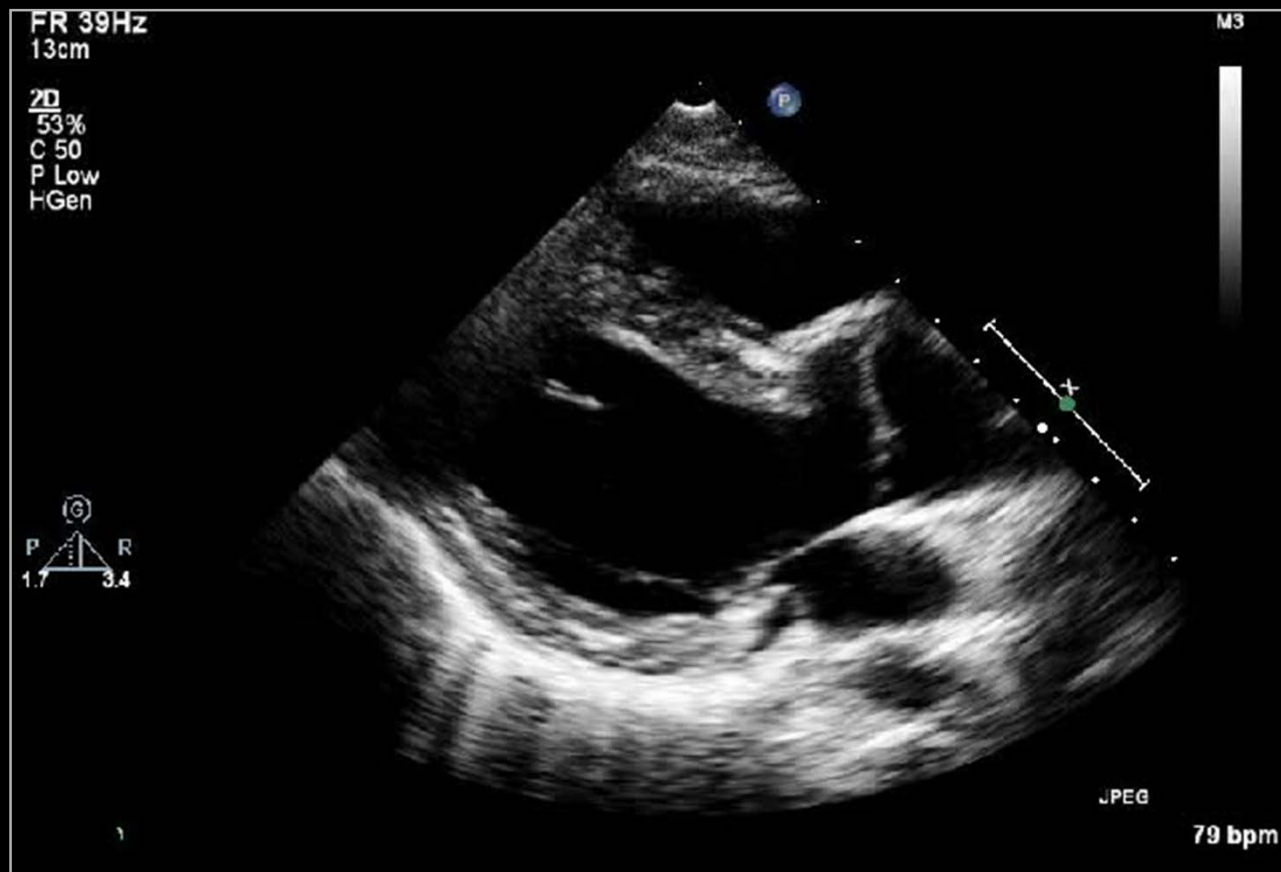# Patent Ductus Arteriosus



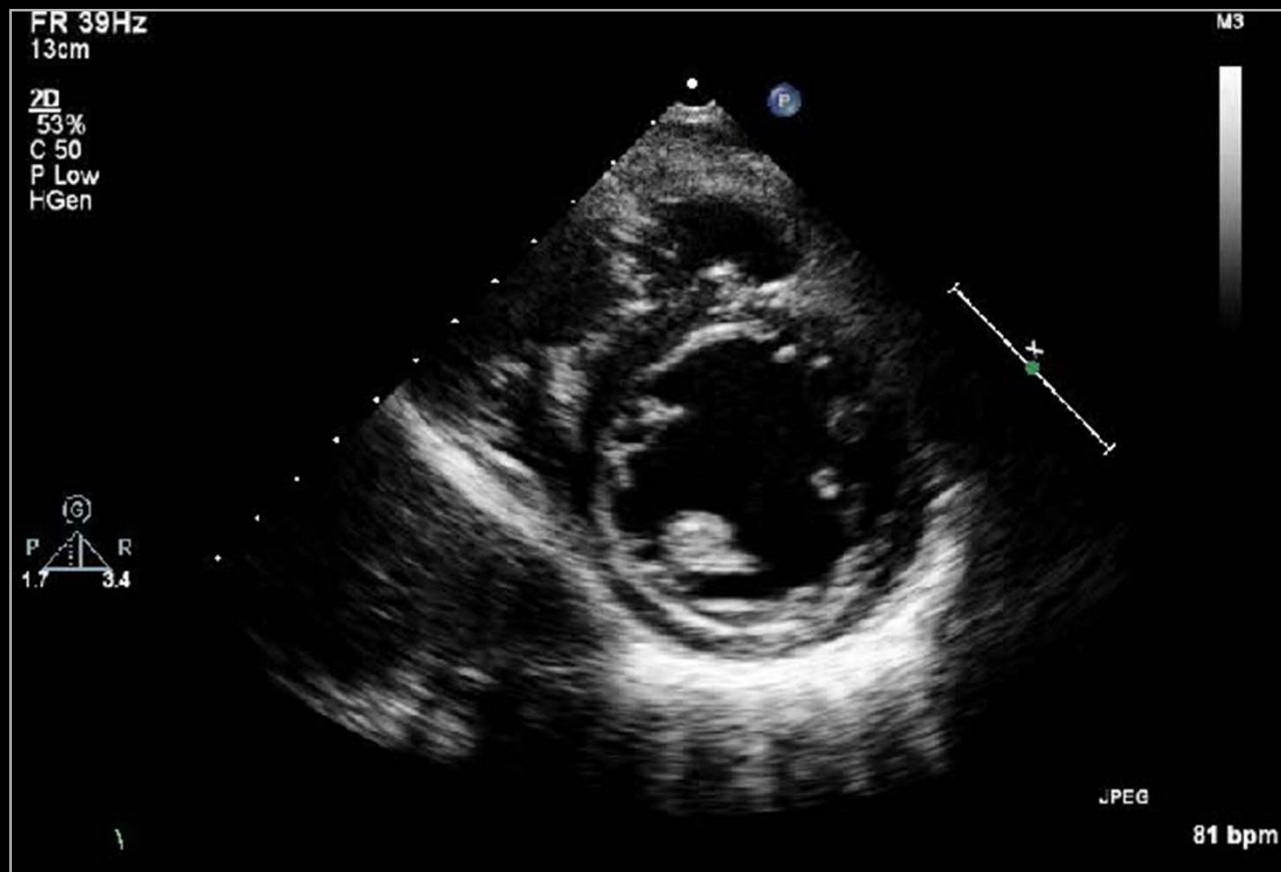# Patent Ductus Arteriosus



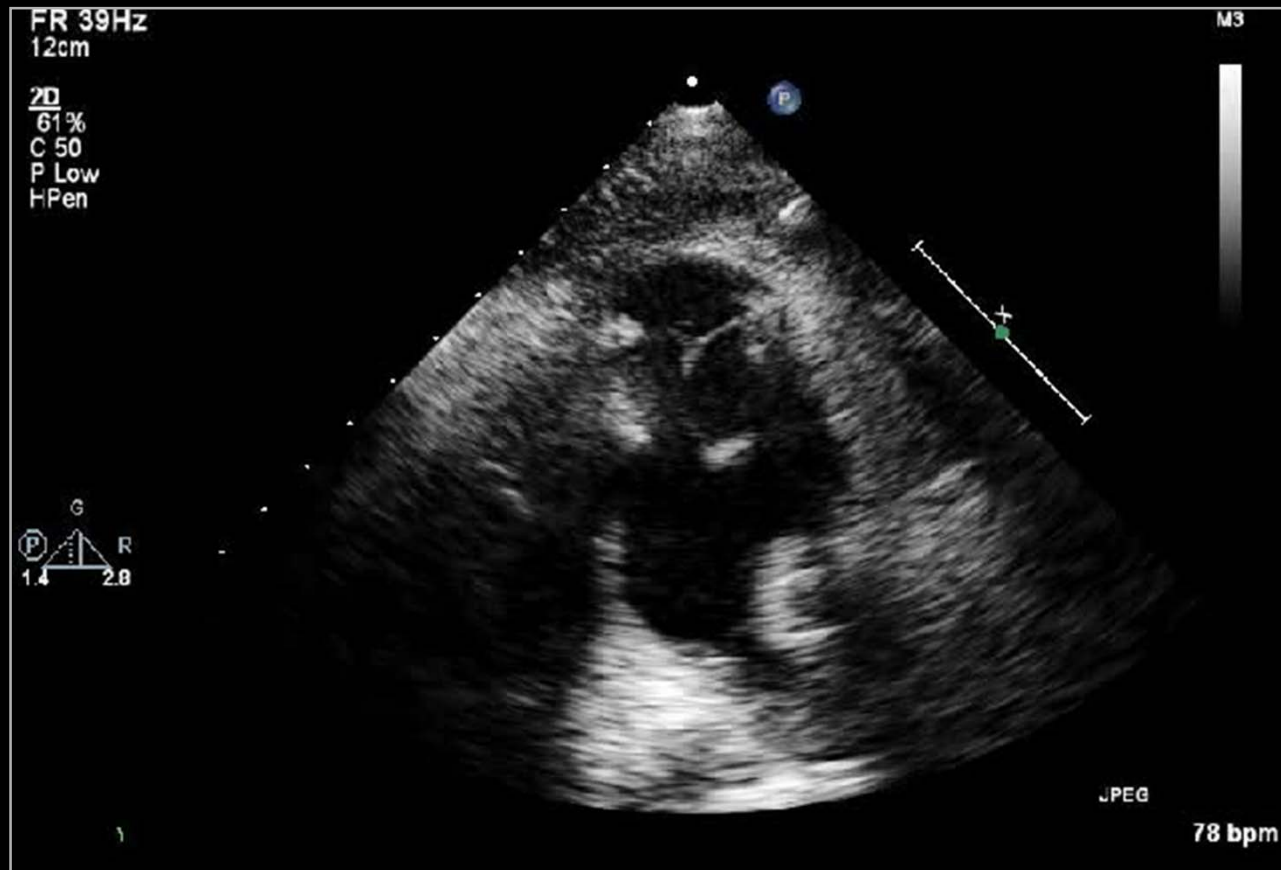# s/p TOF Total Correction



# s/p TOF Total Correction

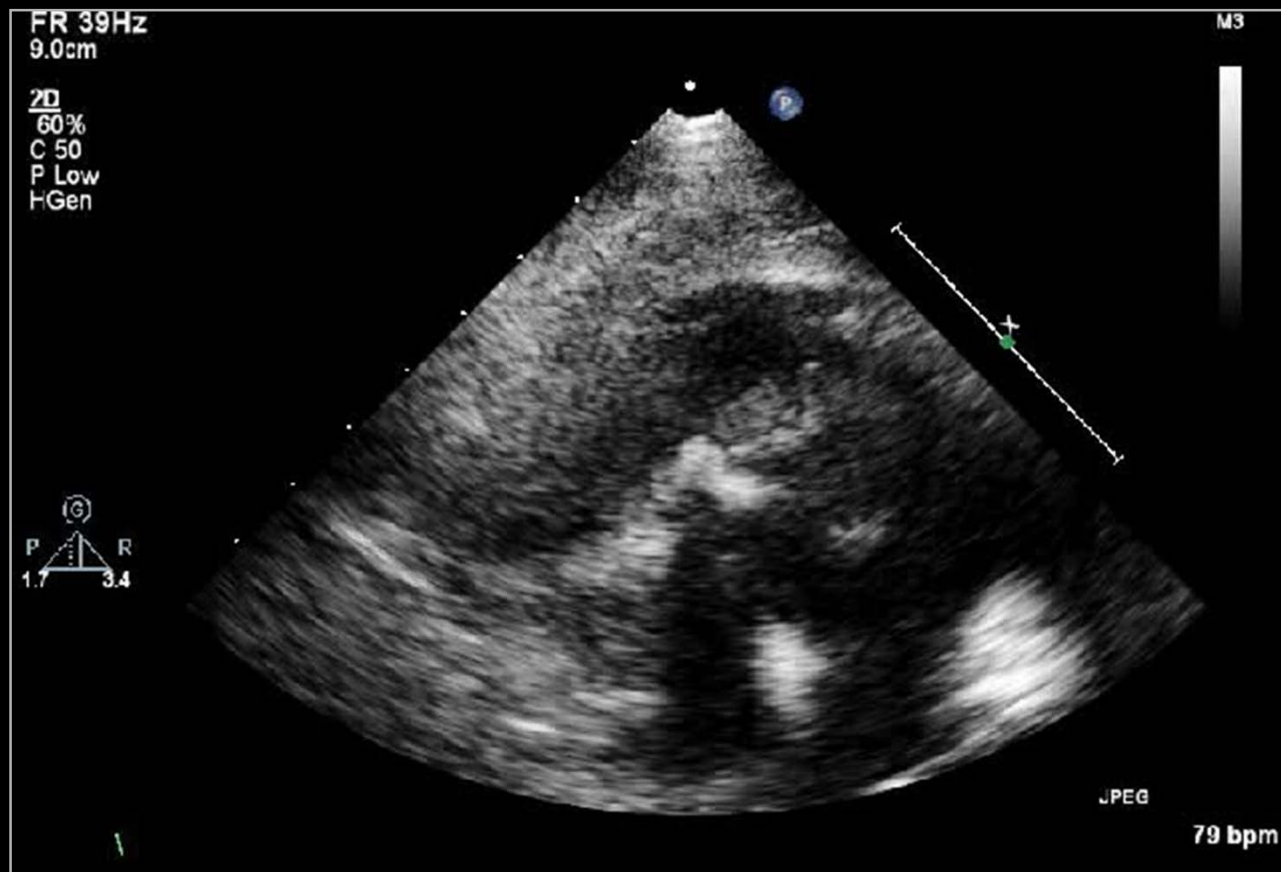


# s/p TOF Total Correction

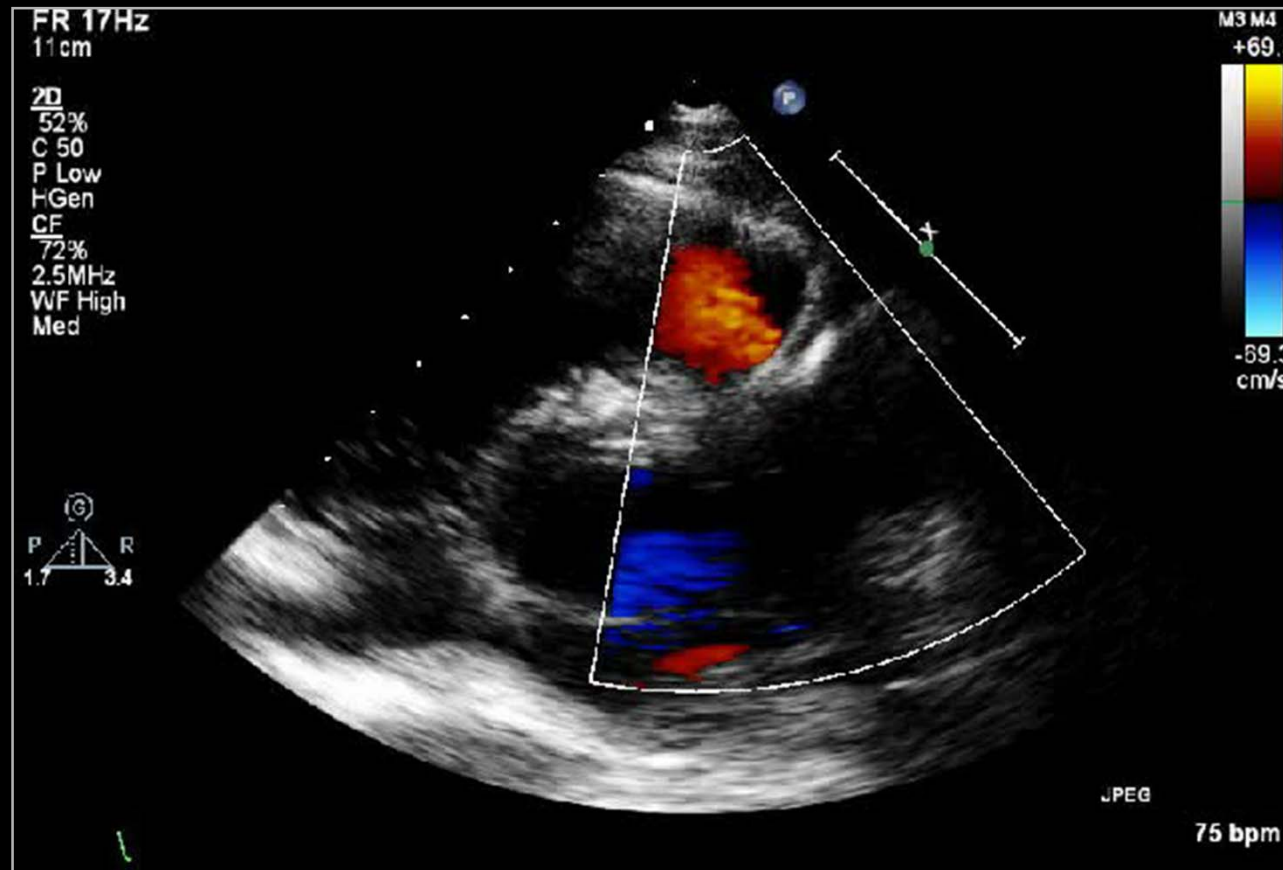




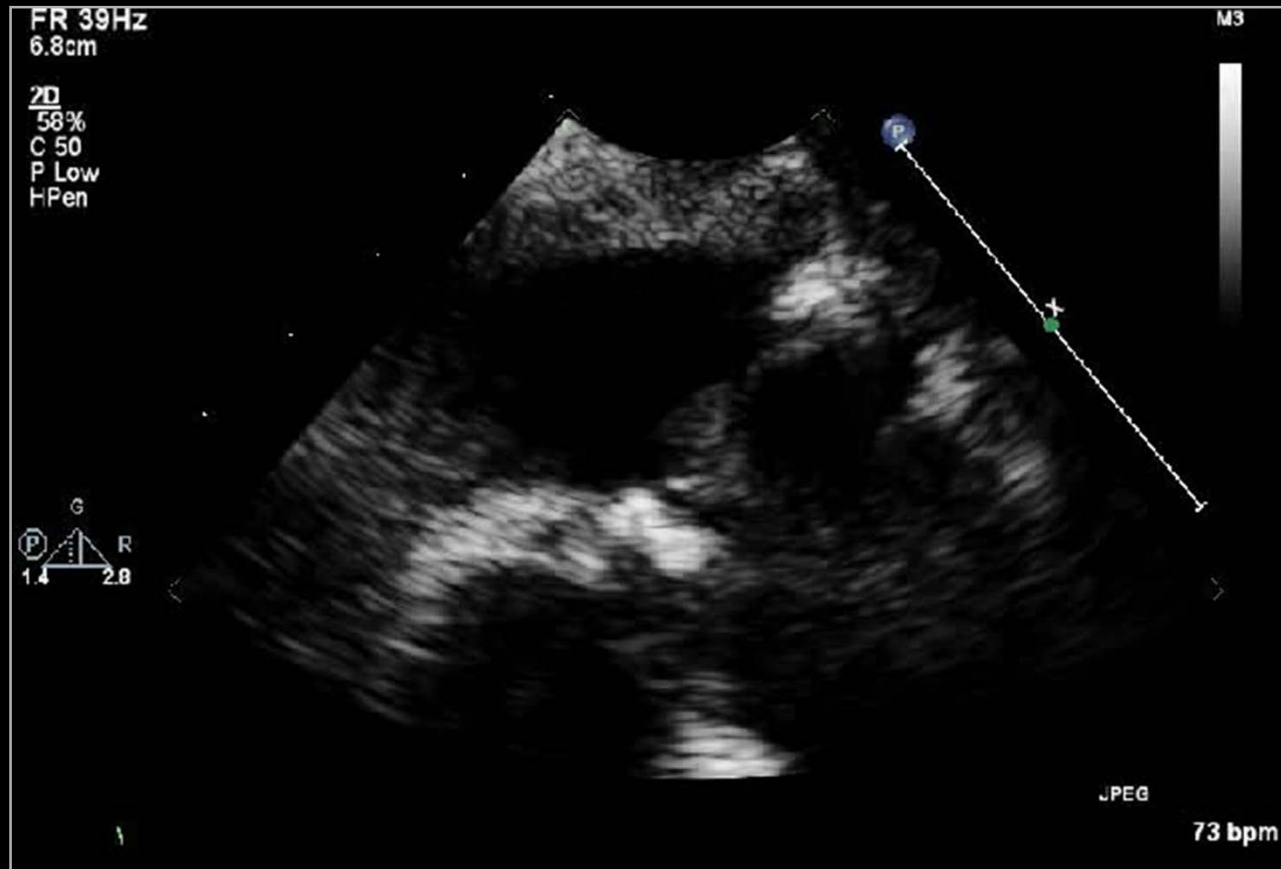
# s/p TOF Total Correction



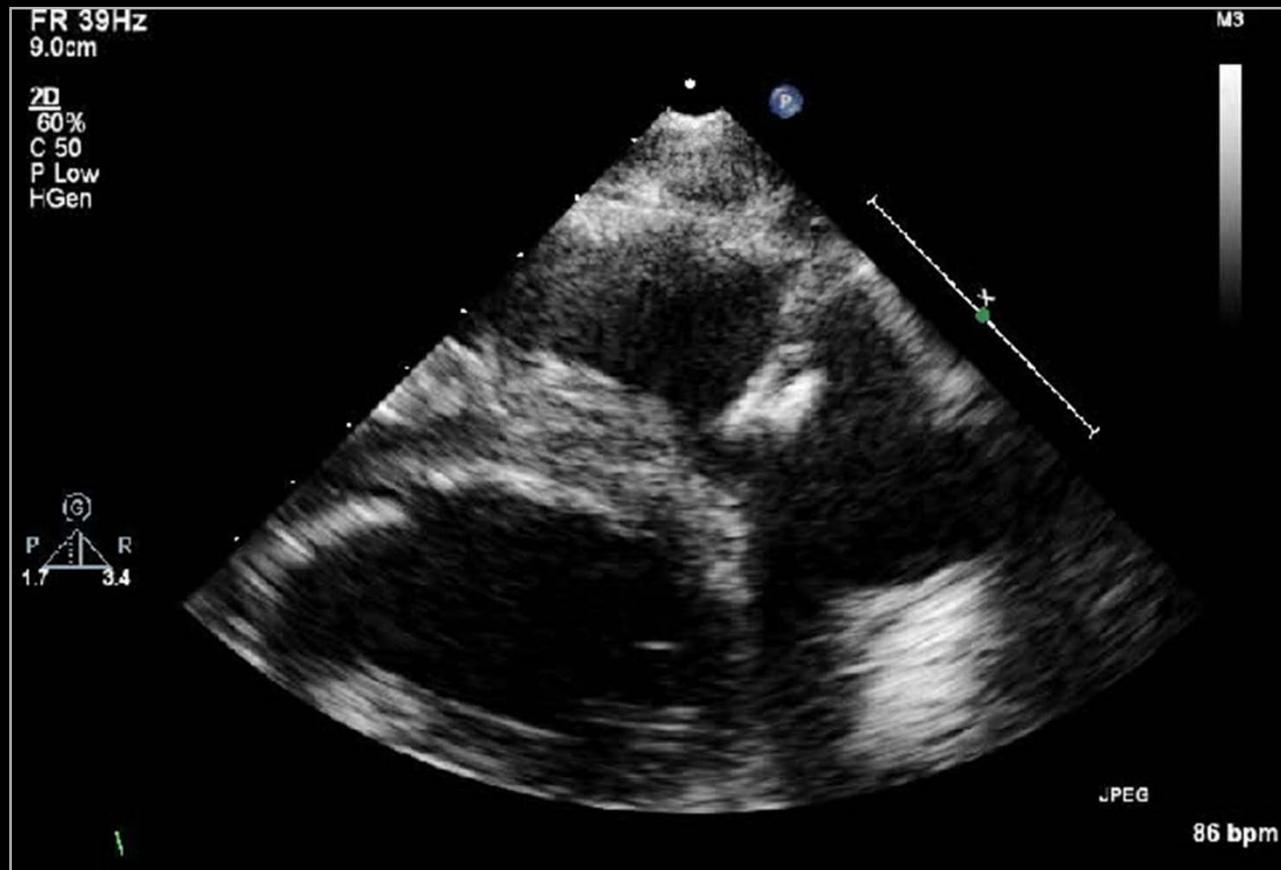
# s/p TOF Total Correction



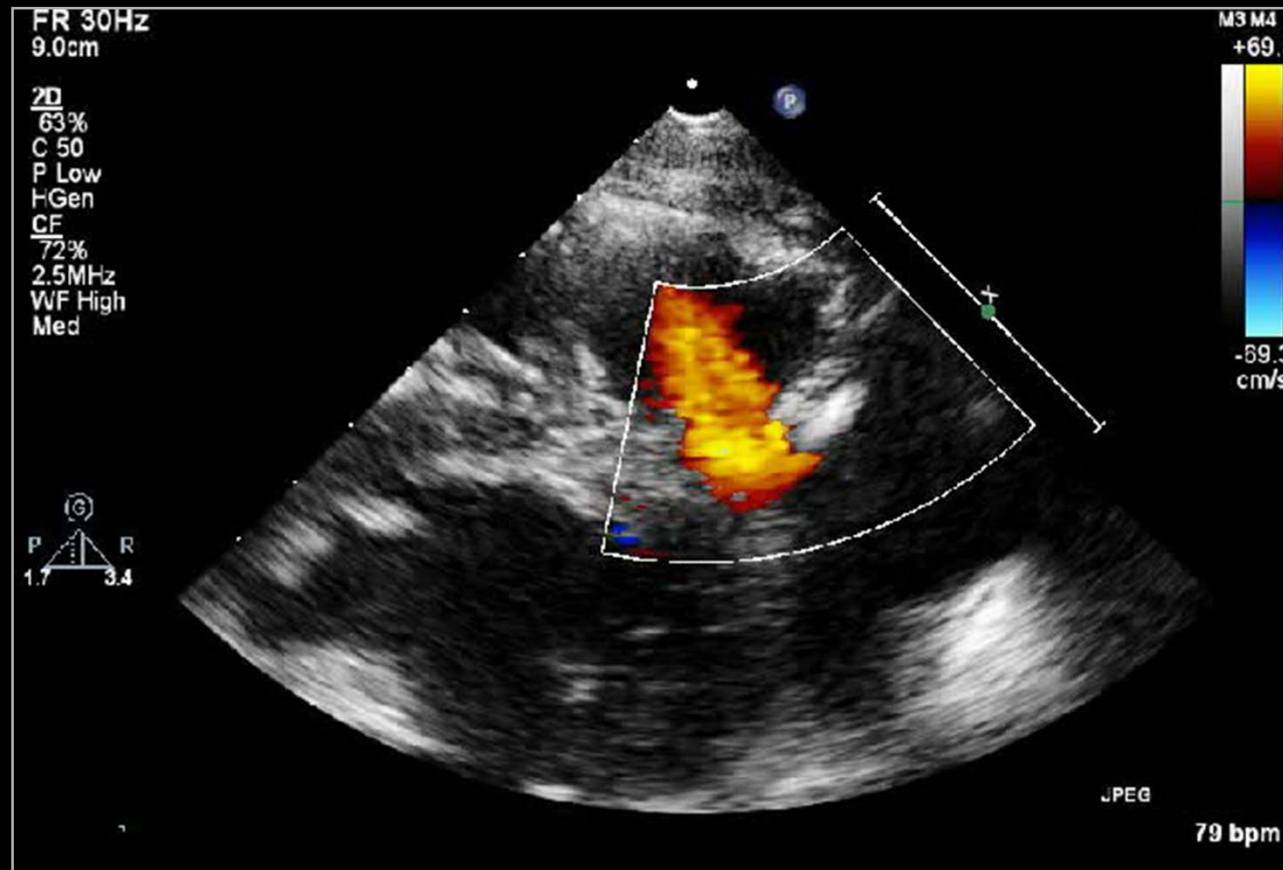
# s/p TOF Total Correction



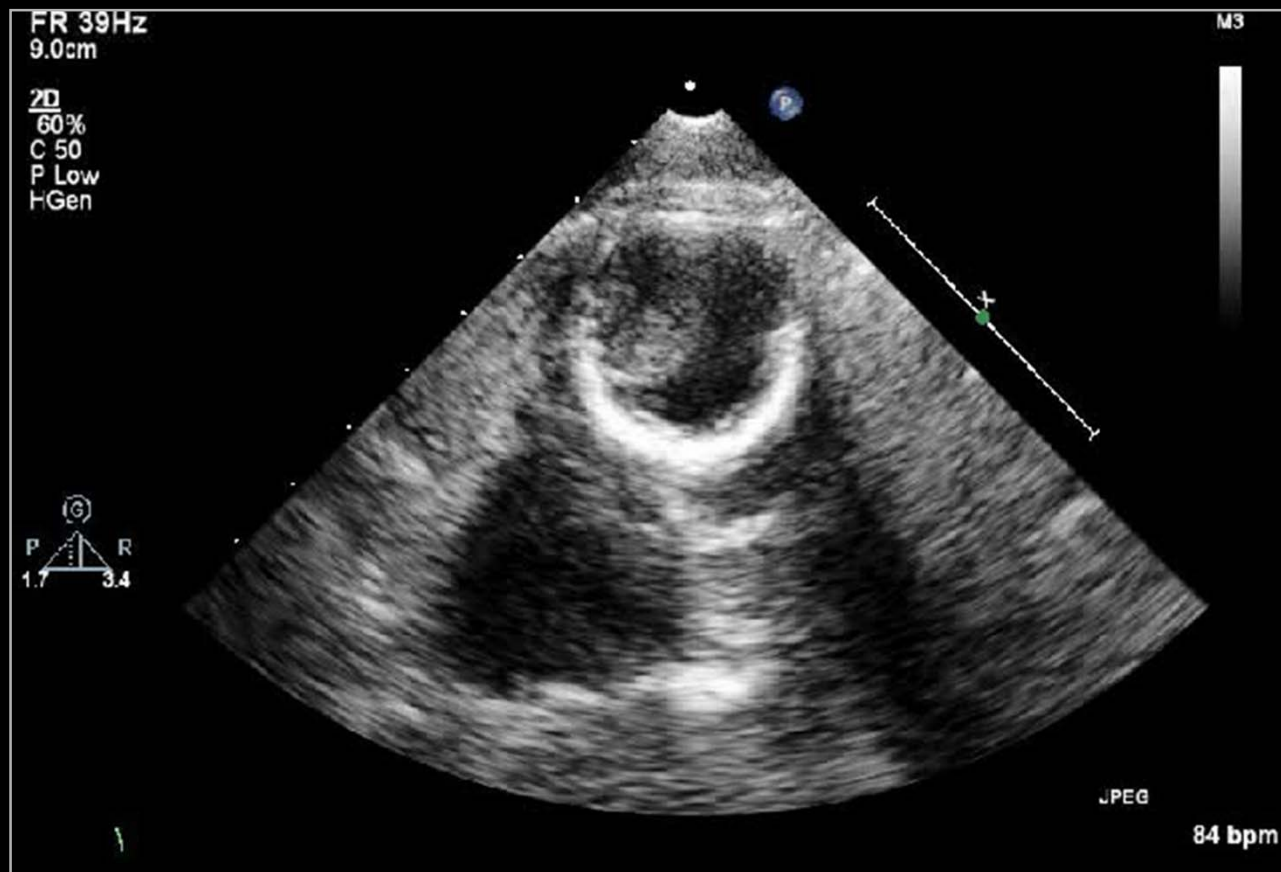
# s/p TOF Total Correction



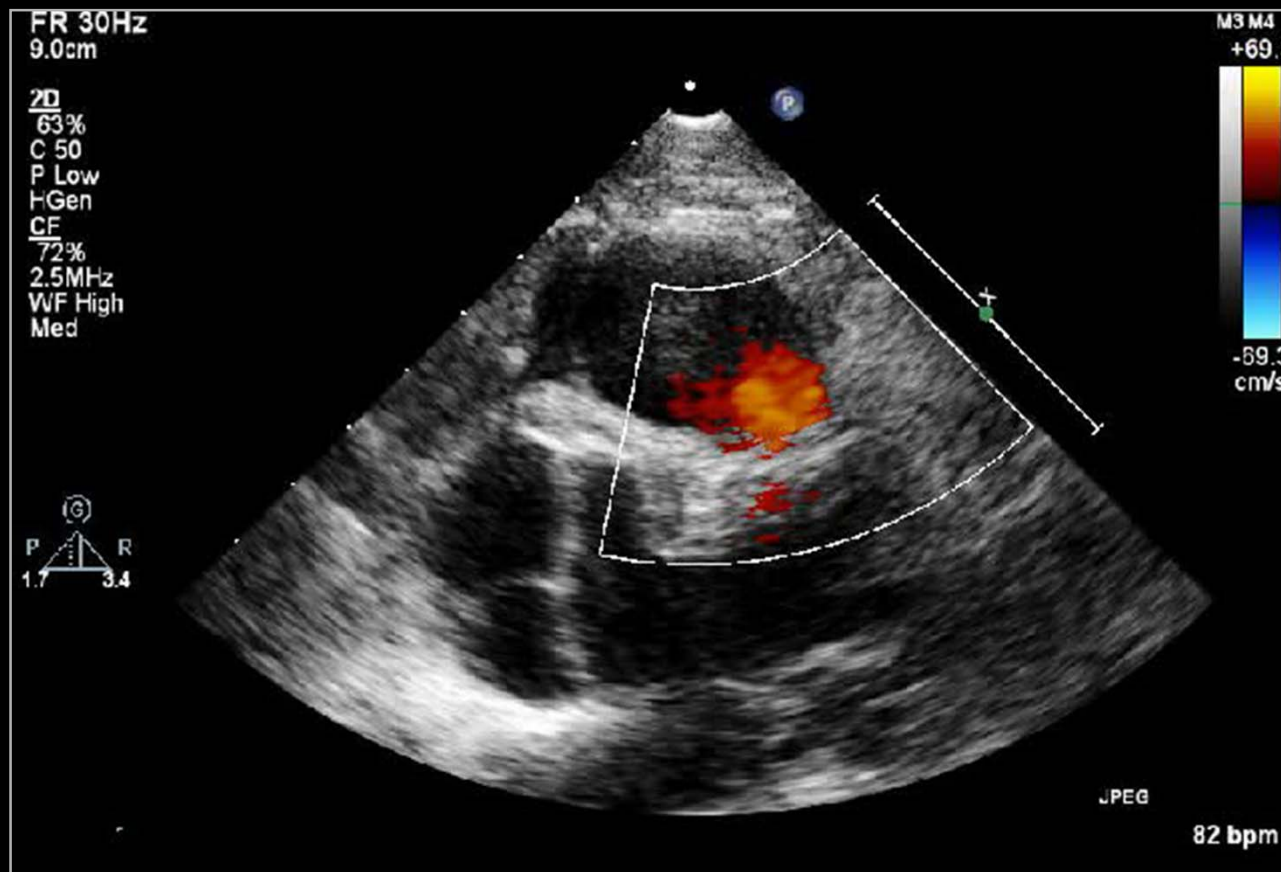
# s/p TOF Total Correction



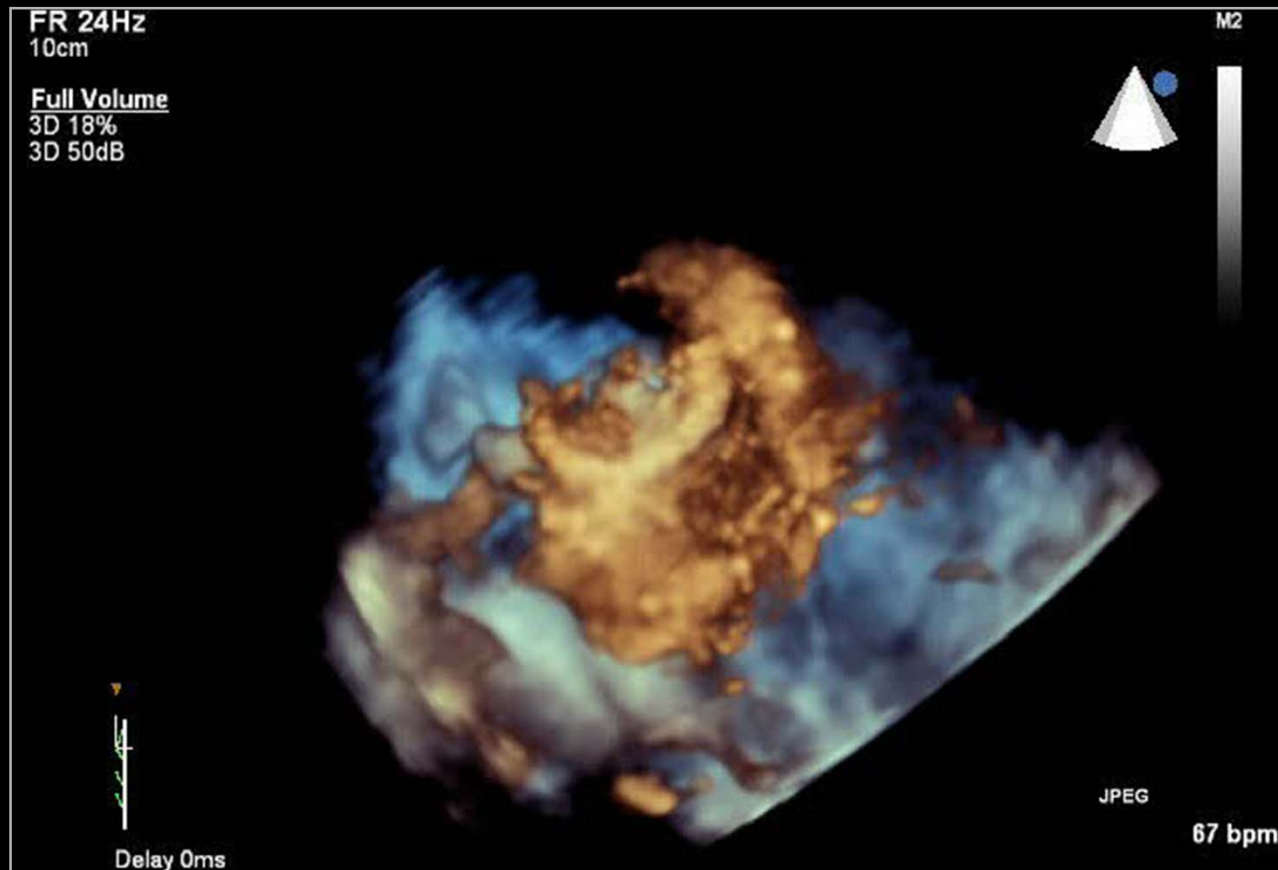
# s/p TOF Total Correction



# s/p TOF Total Correction

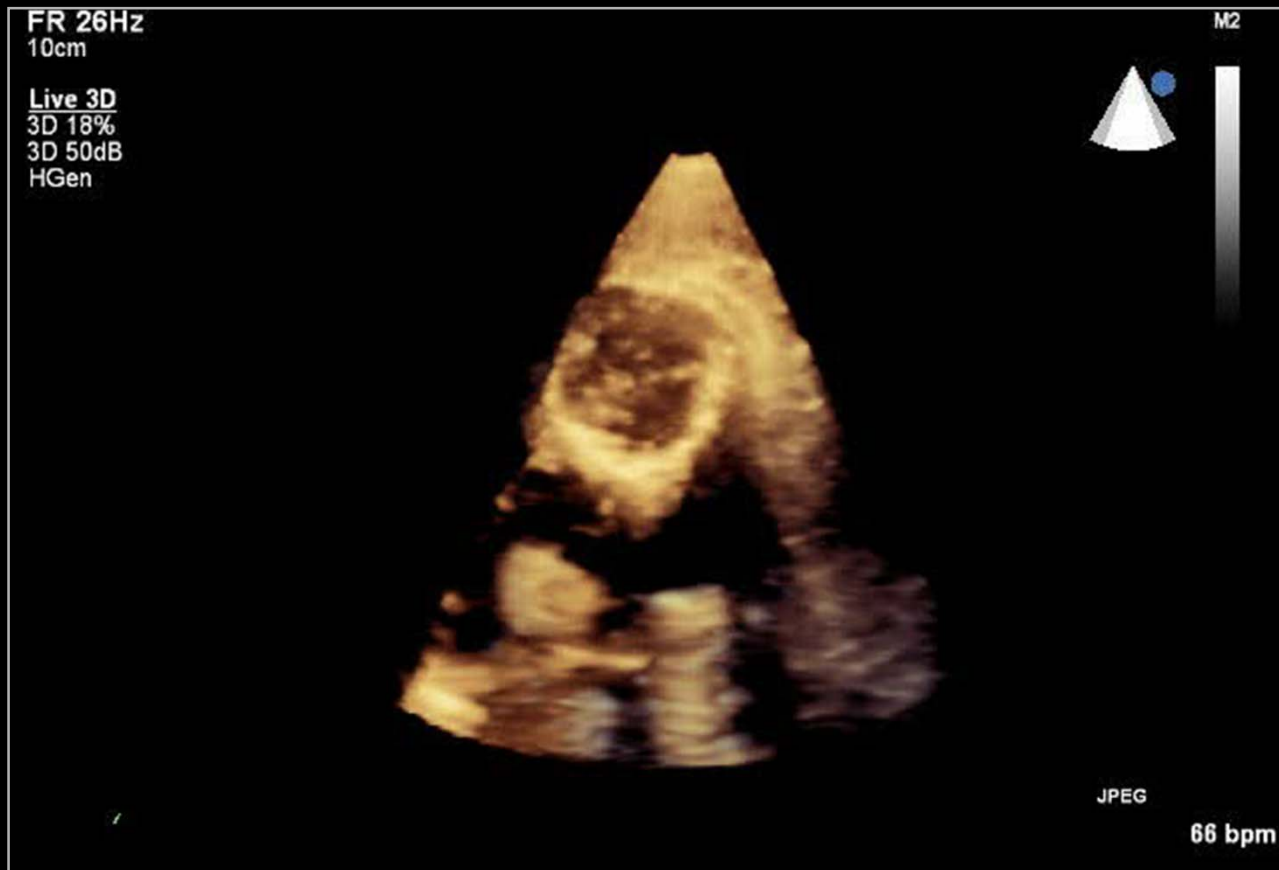


# s/p TOF Total Correction

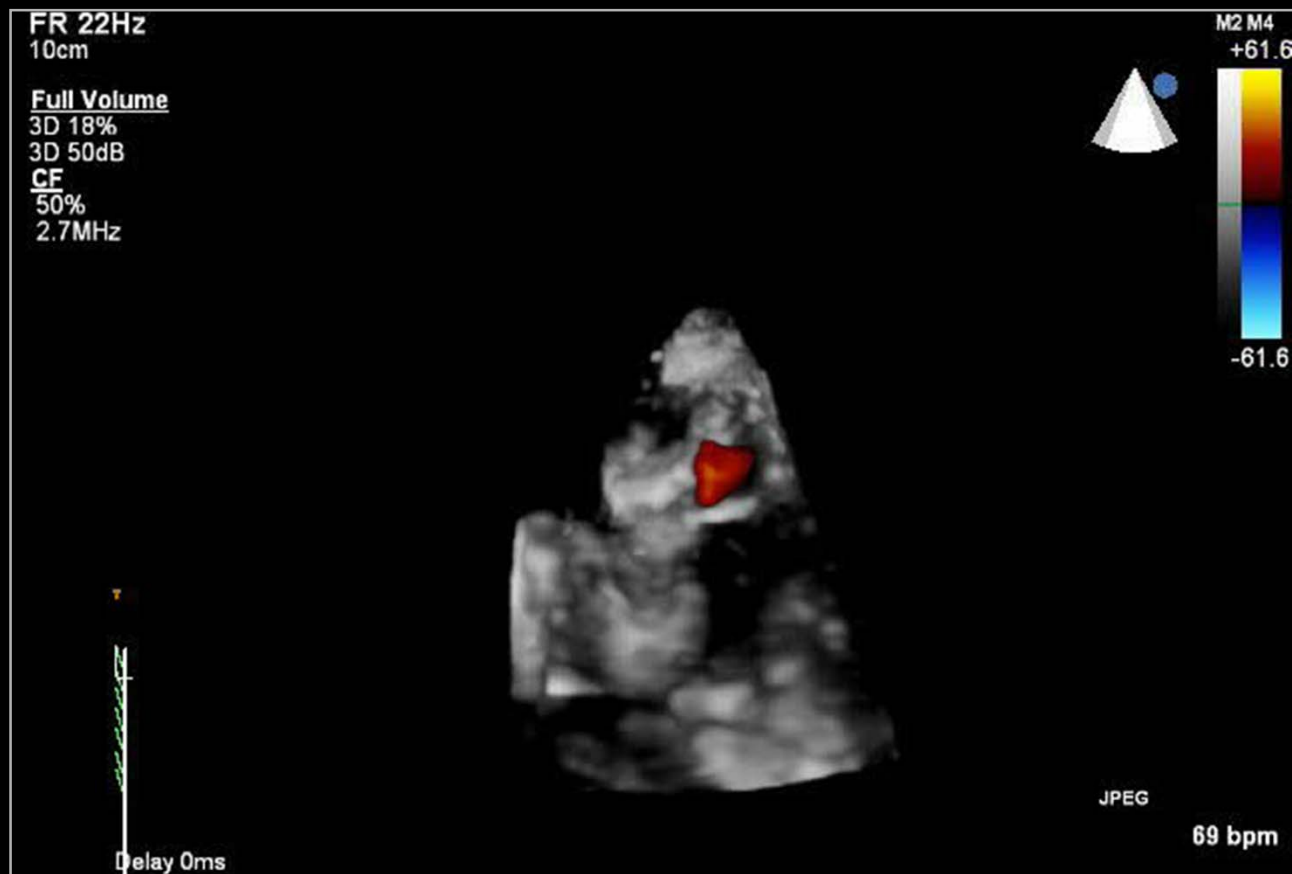



# s/p TOF Total Correction



# s/p TOF Total Correction



# Real-Time 3-Dimensional Echo

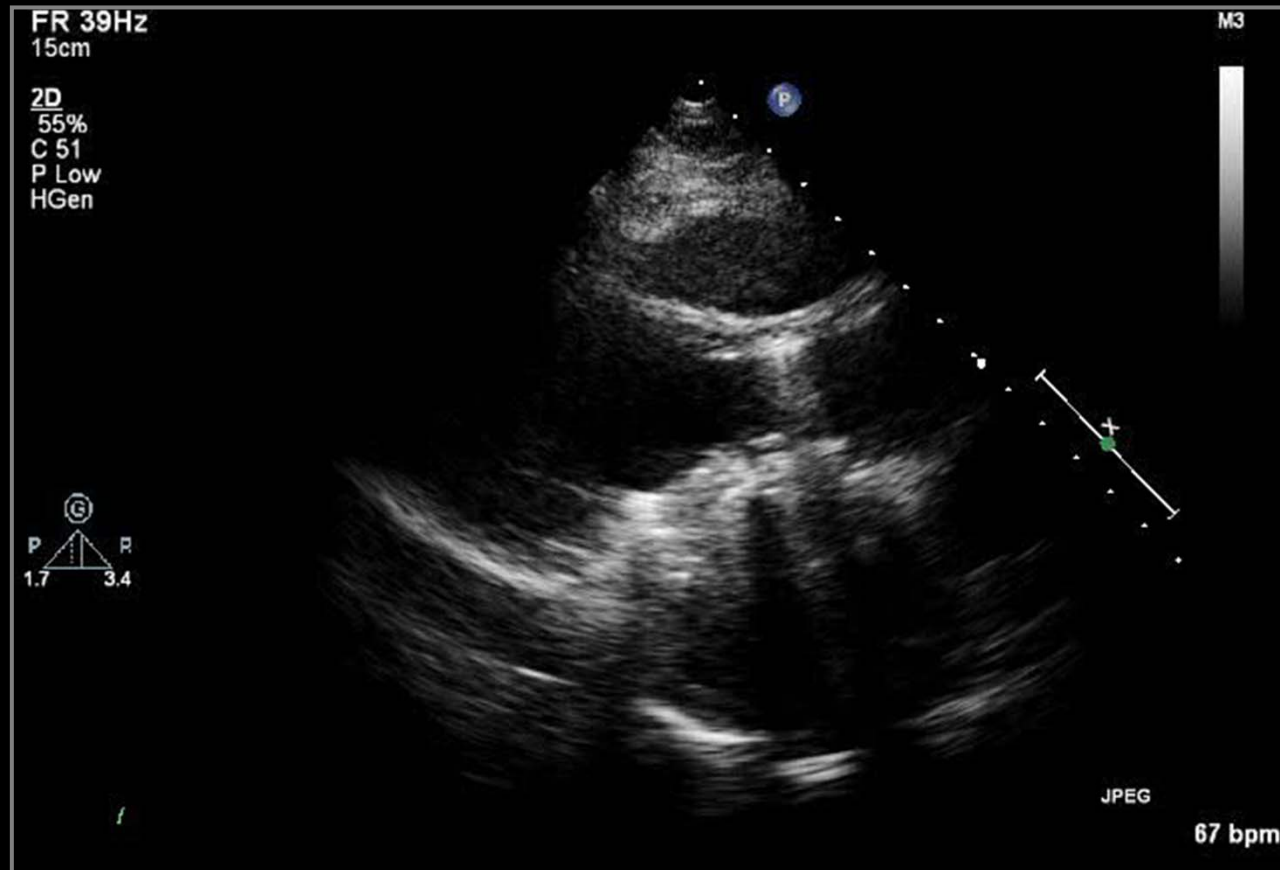
## ○ Unique 3D images

- Images which cannot be obtained from 2D echo
- **3D TTE**
  - Pulmonic valve
  - Tricuspid valve
- **3D TEE**
  - Mitral valve disease
  - Atrial septal defect
- **3D color Doppler images**
  - 3D features of valvular regurgitation

**Thank you for your attention.**

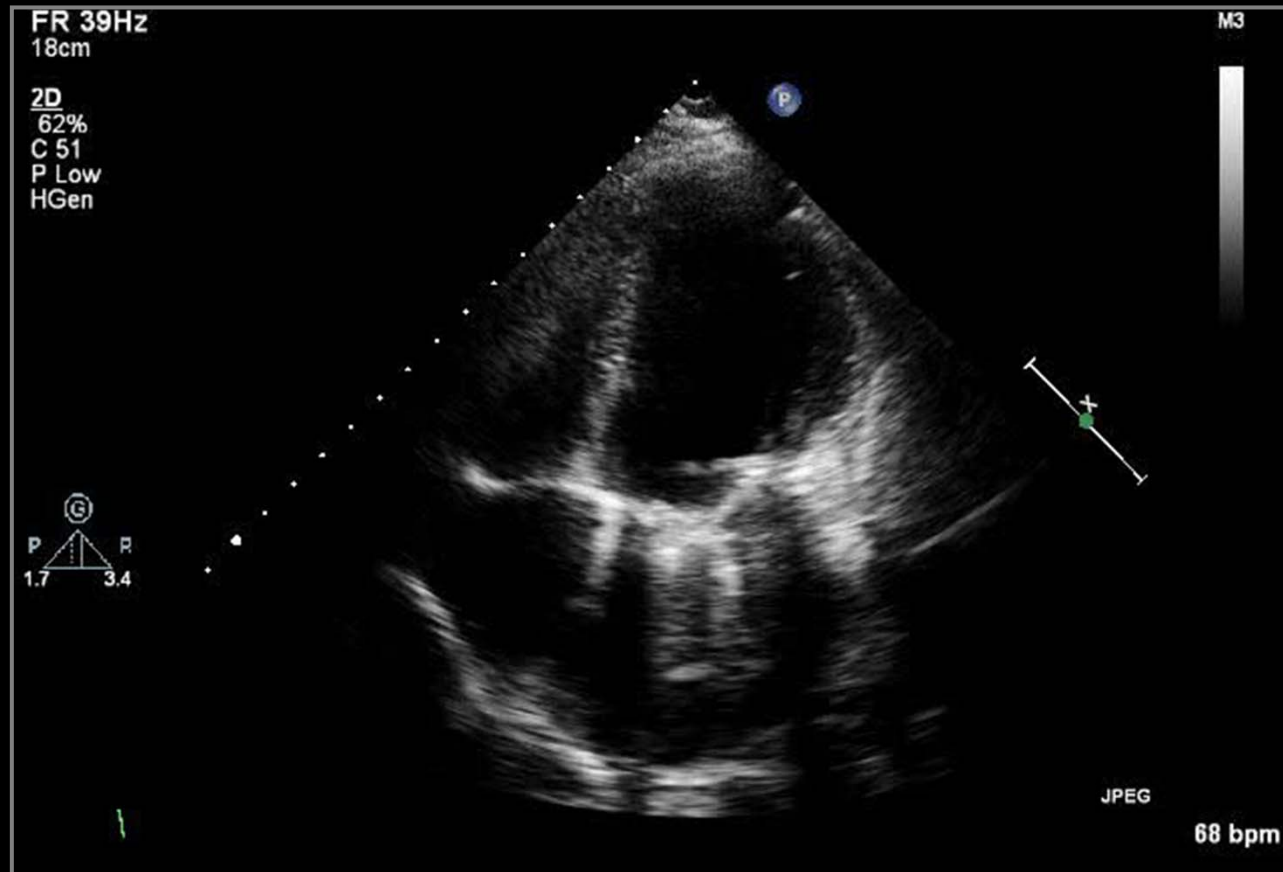


# s/p MV Replacement



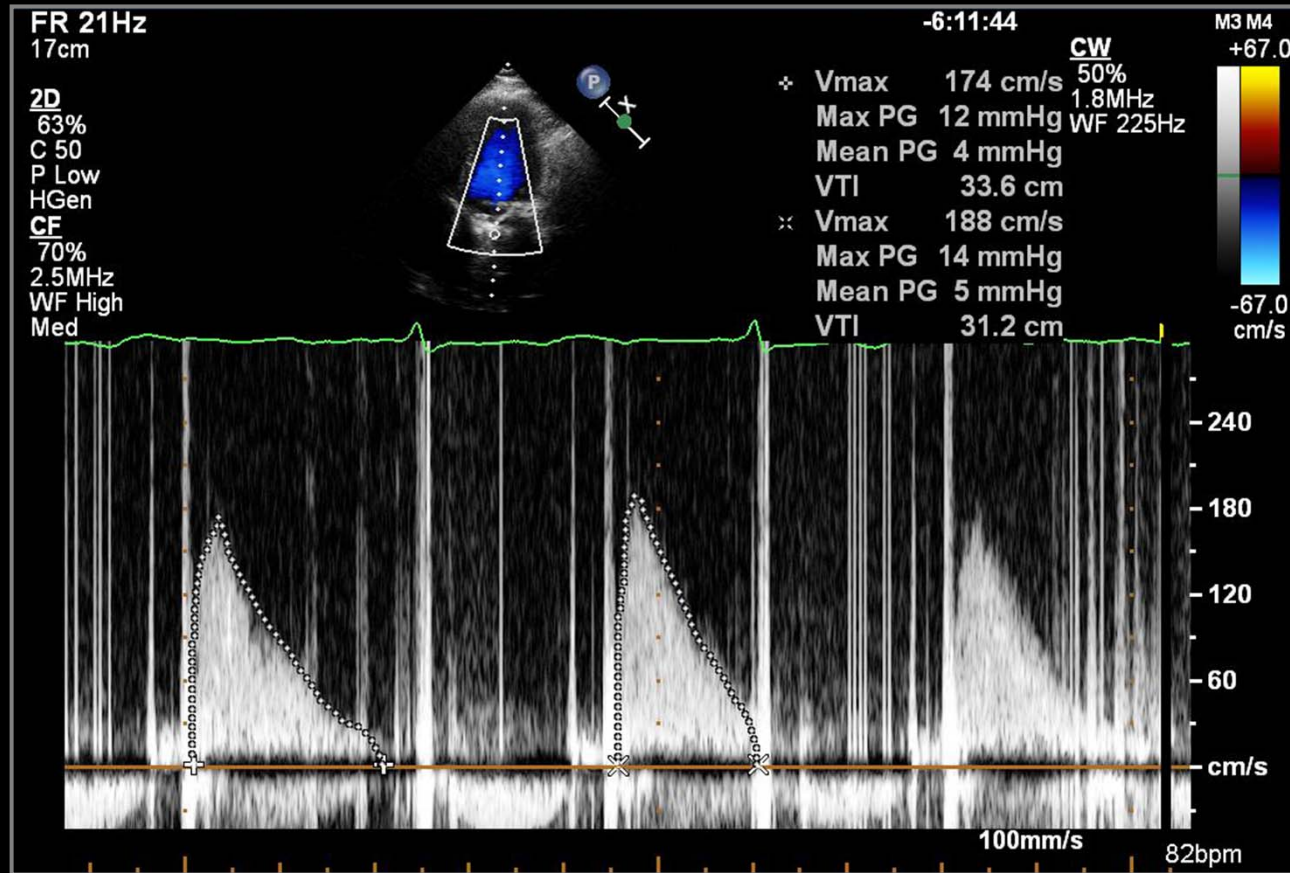
2009/08/20

# s/p MV Replacement



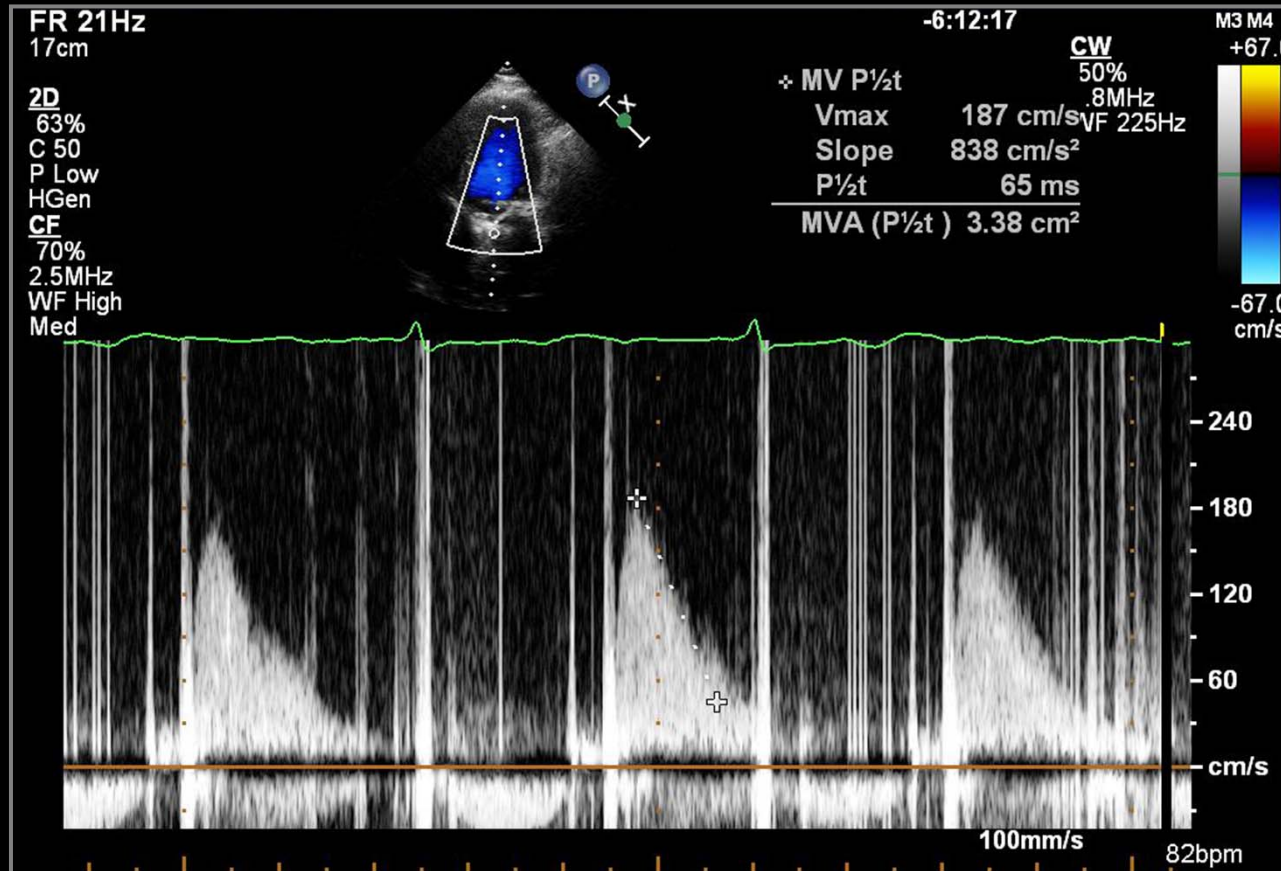
2009/08/20

# s/p MV Replacement



2009/08/20

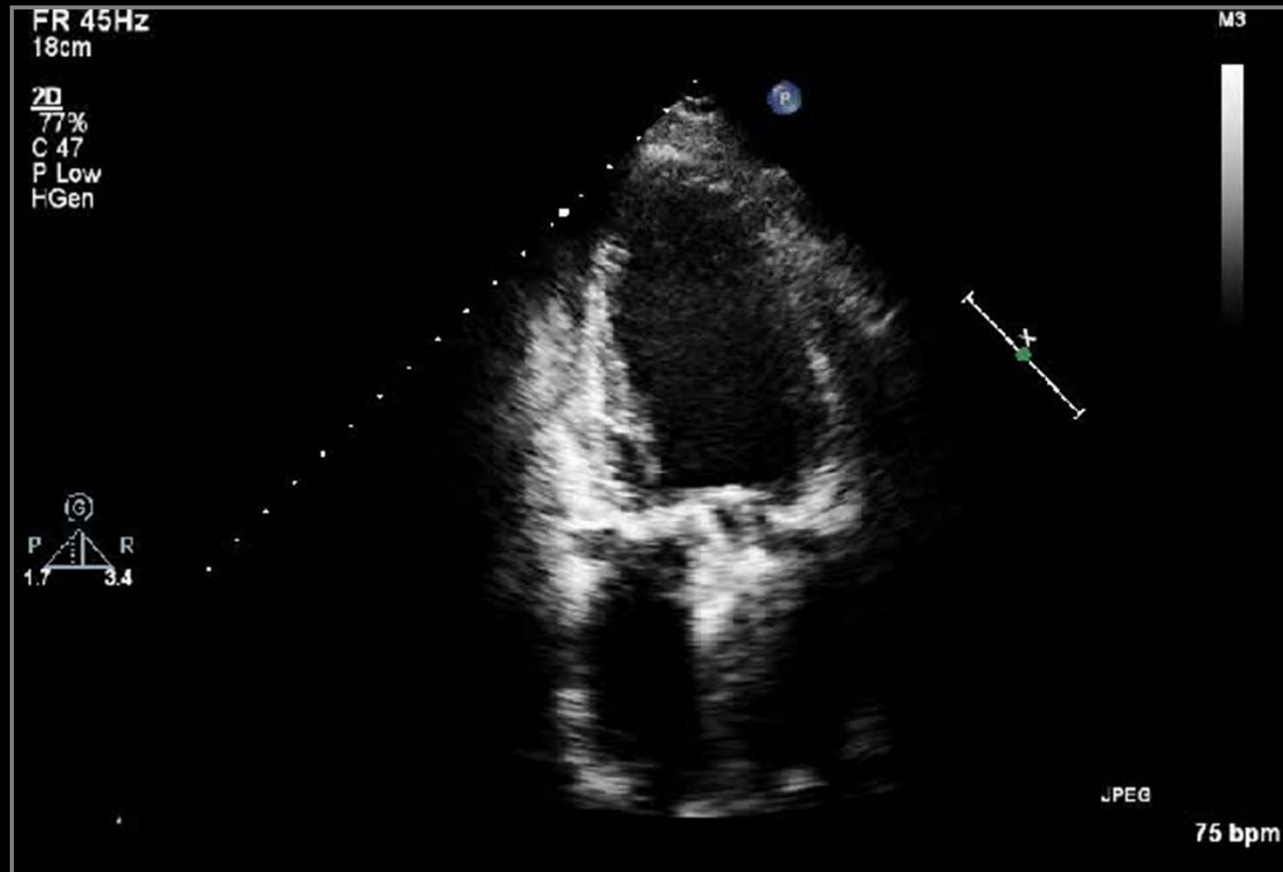
# s/p MV Replacement



2009/08/20

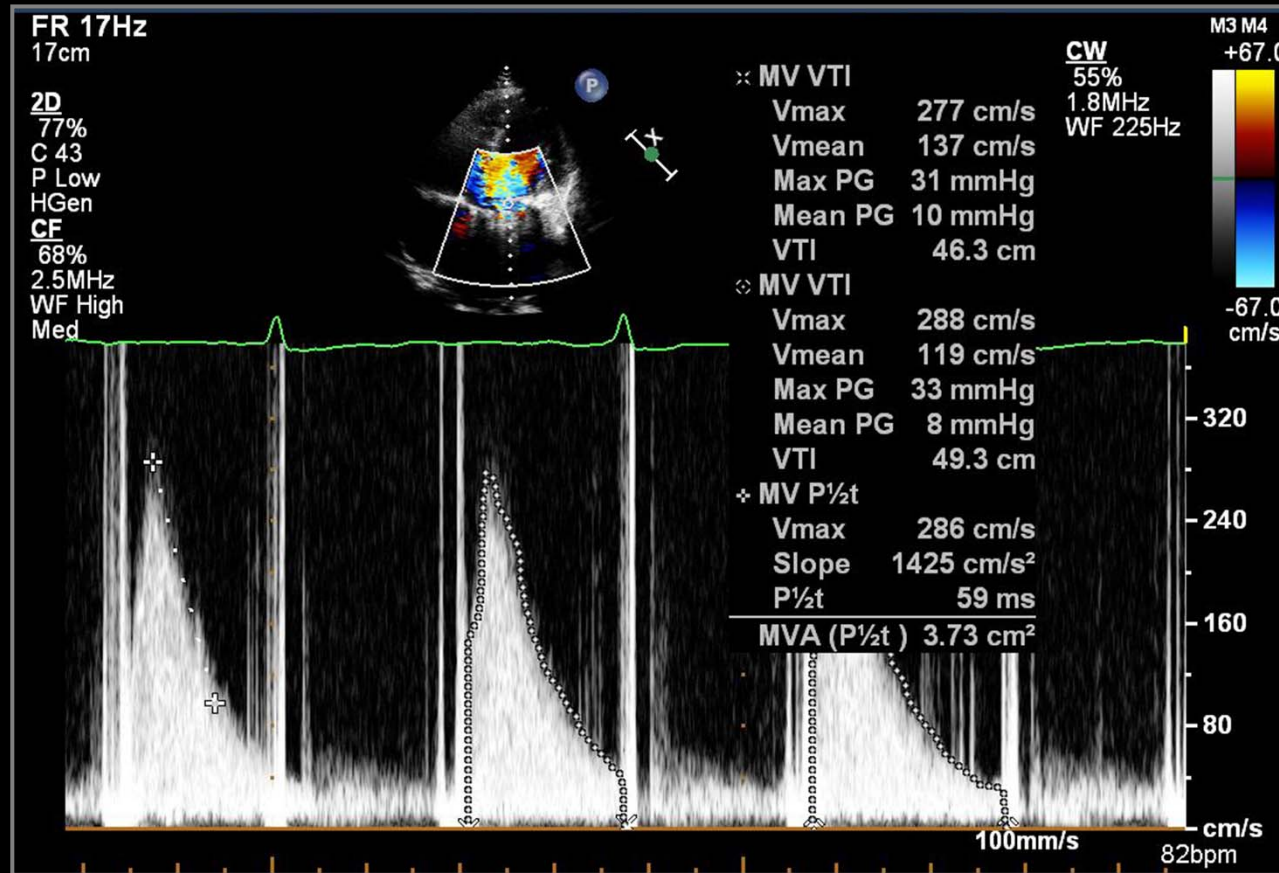


# s/p MV Replacement



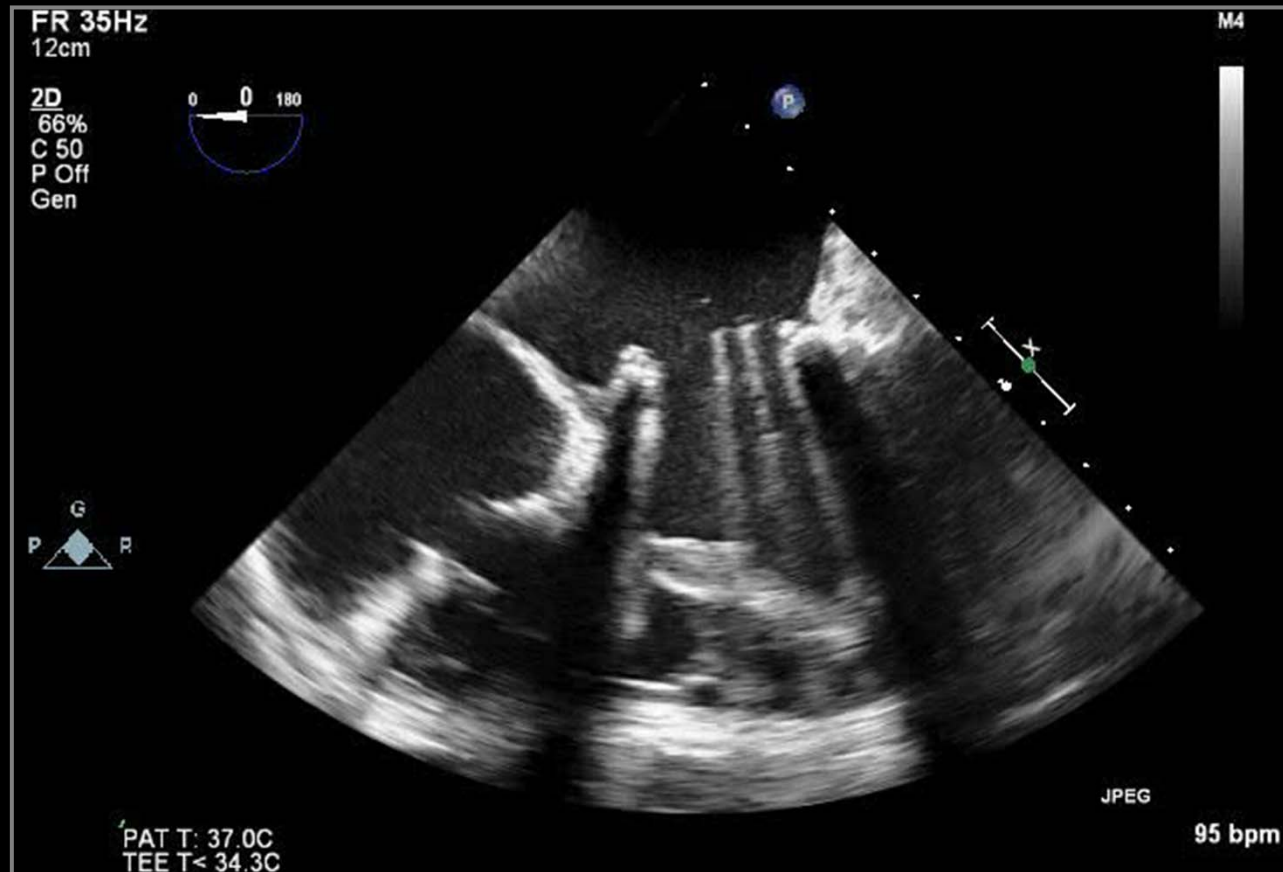
2010/12/24

# s/p MV Replacement



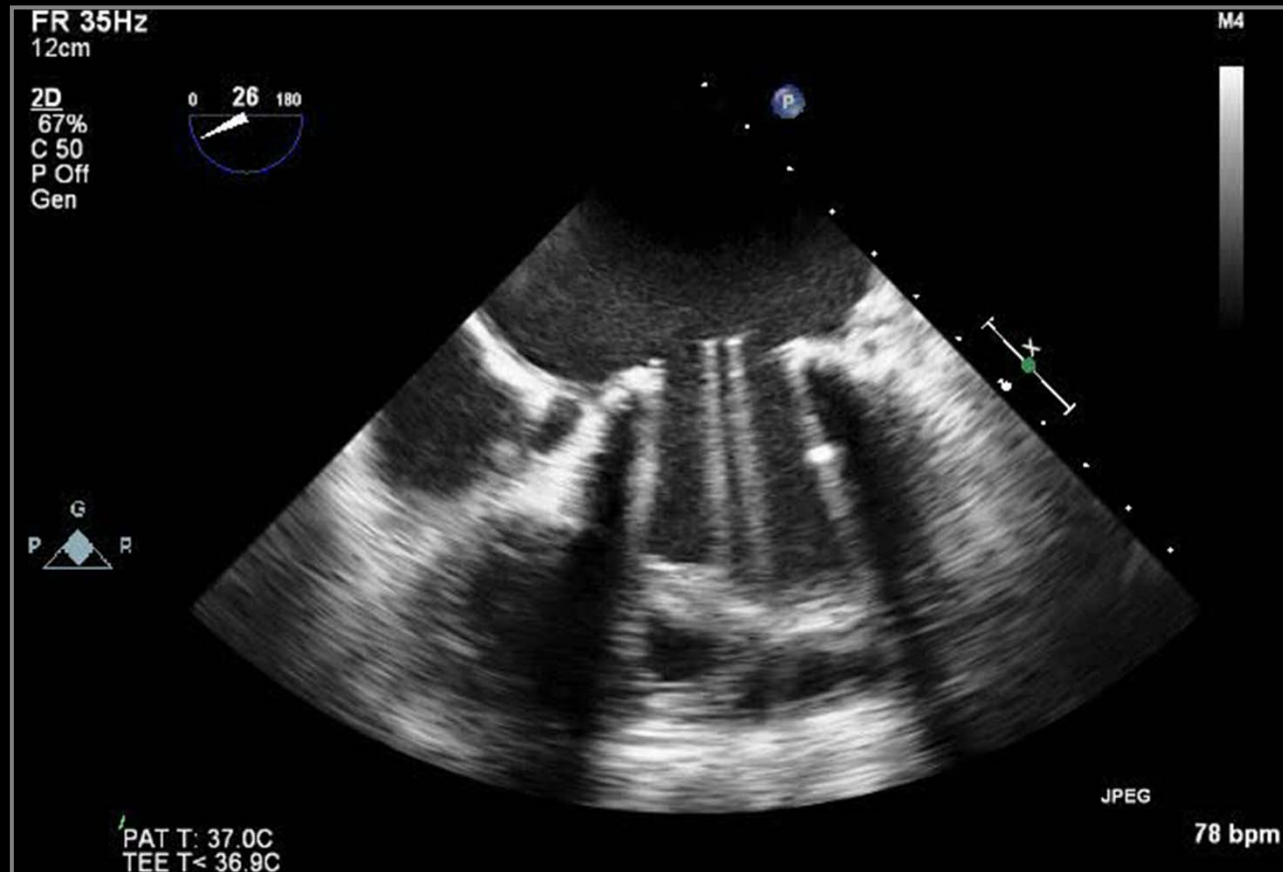
2010/12/24

# s/p MV Replacement



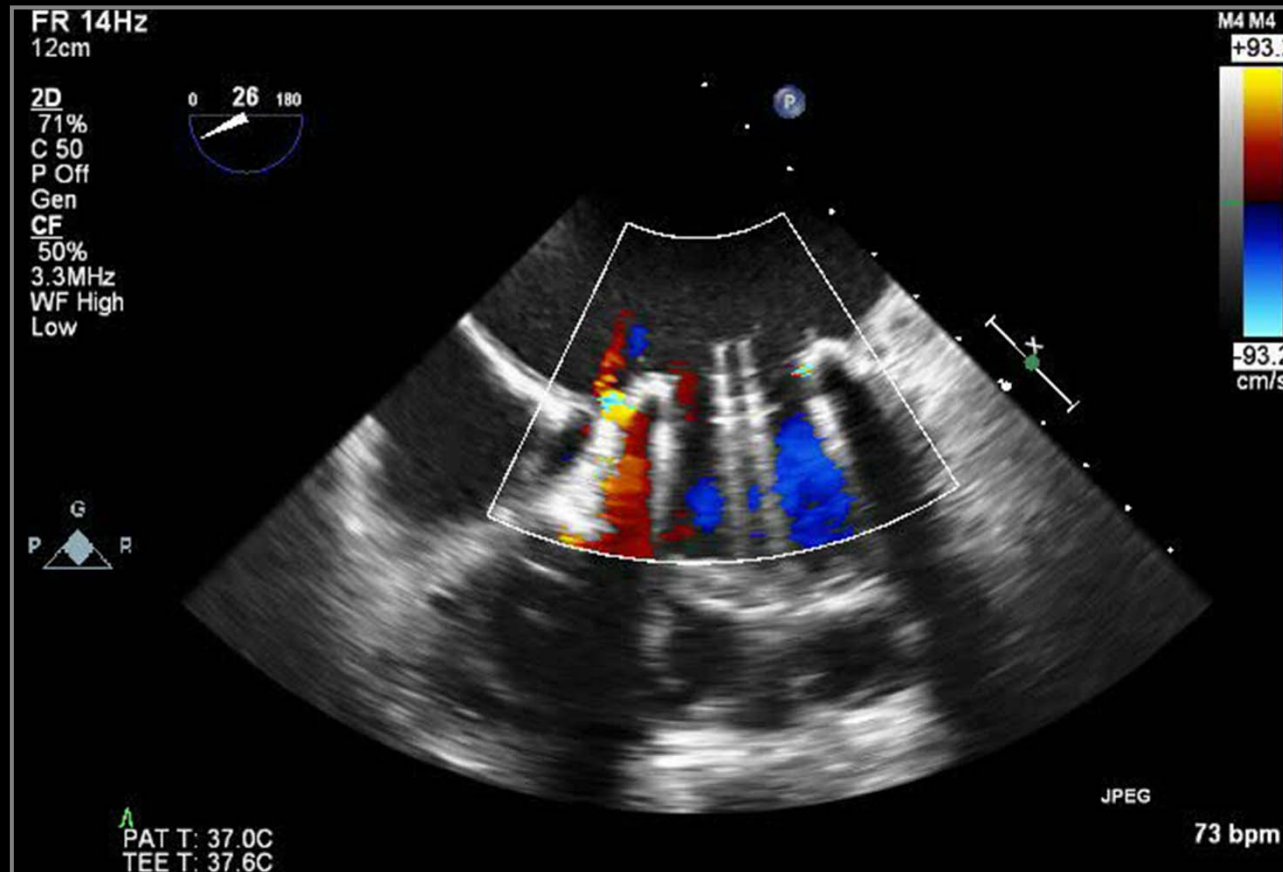
2010/12/24

# s/p MV Replacement



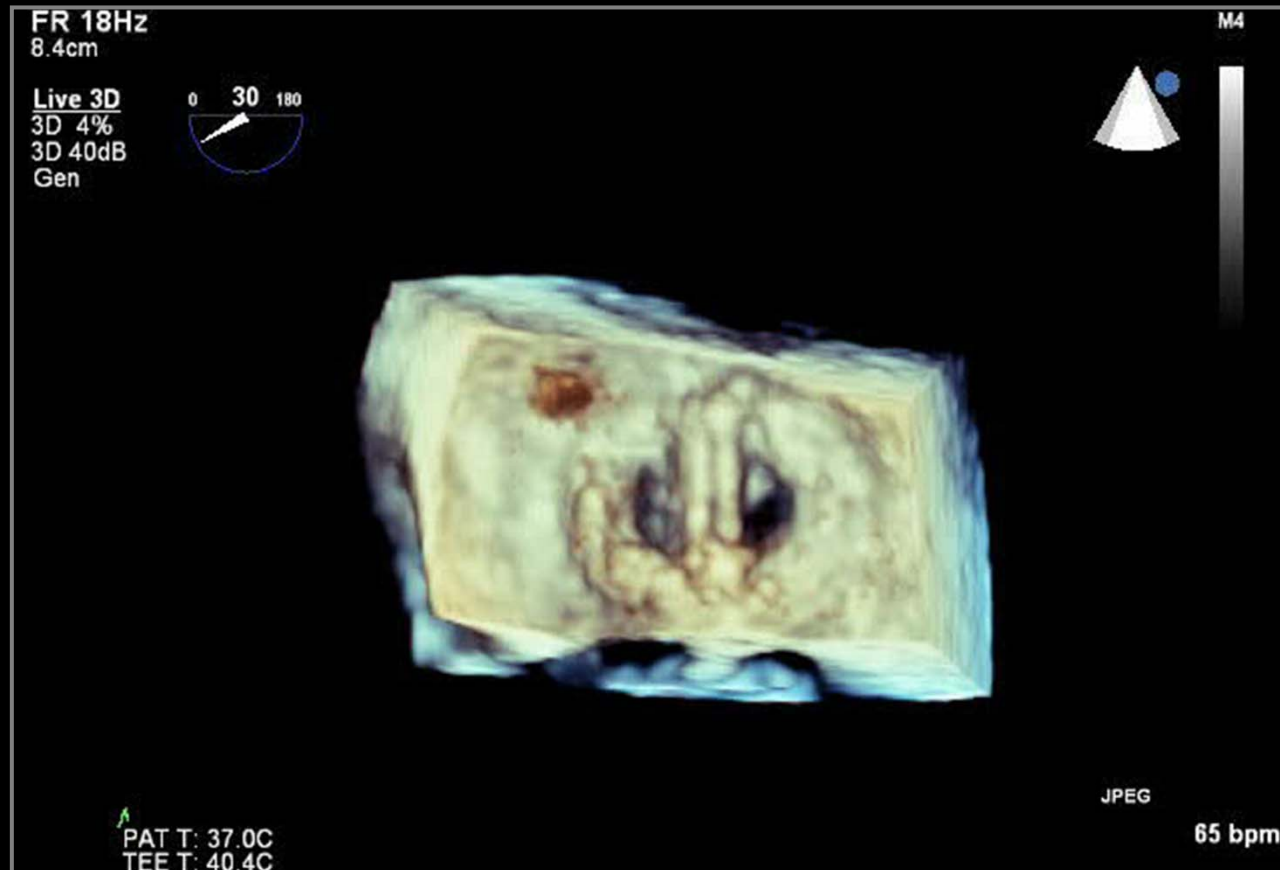
2010/12/24

# s/p MV Replacement



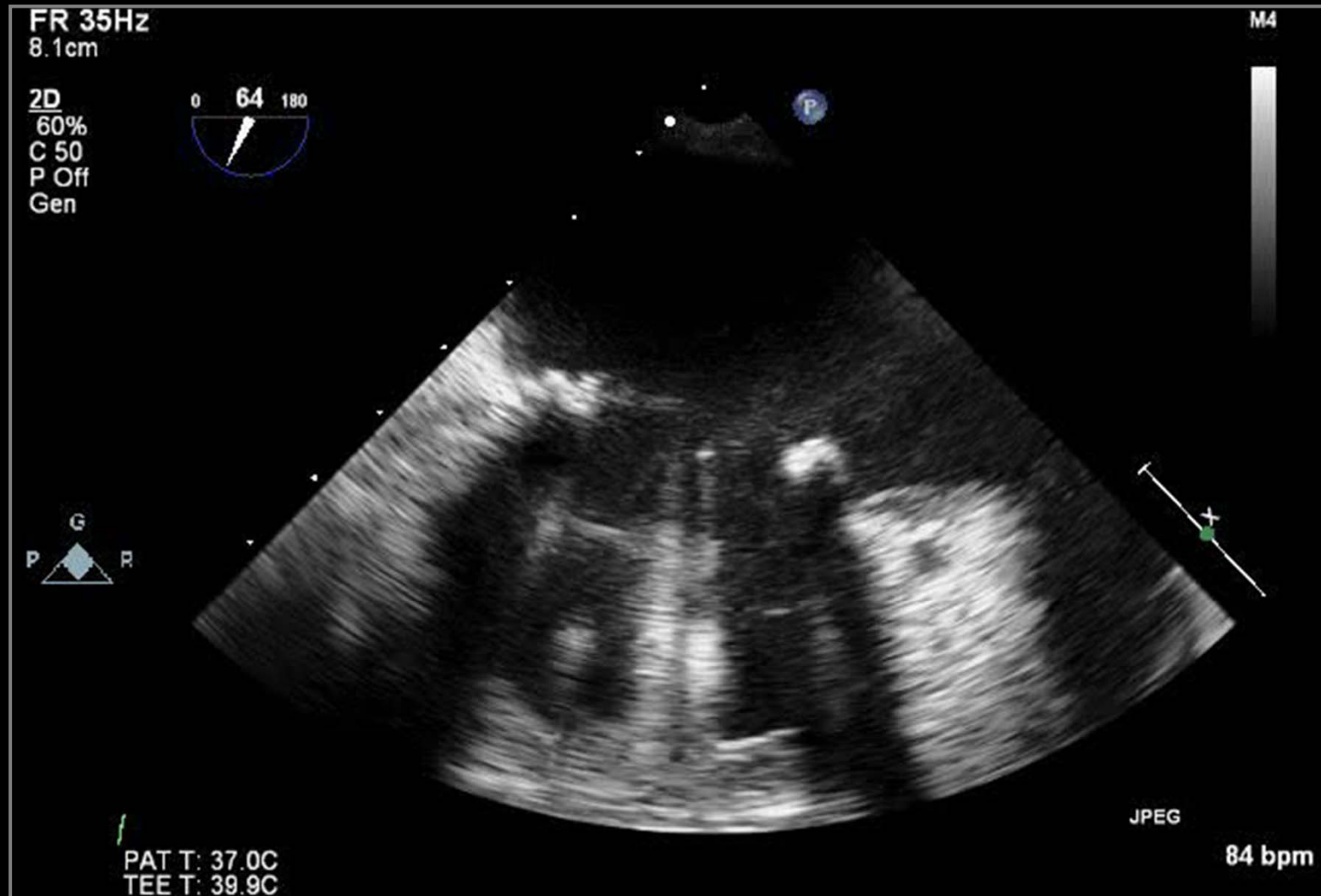
2010/12/24

# s/p MV Replacement

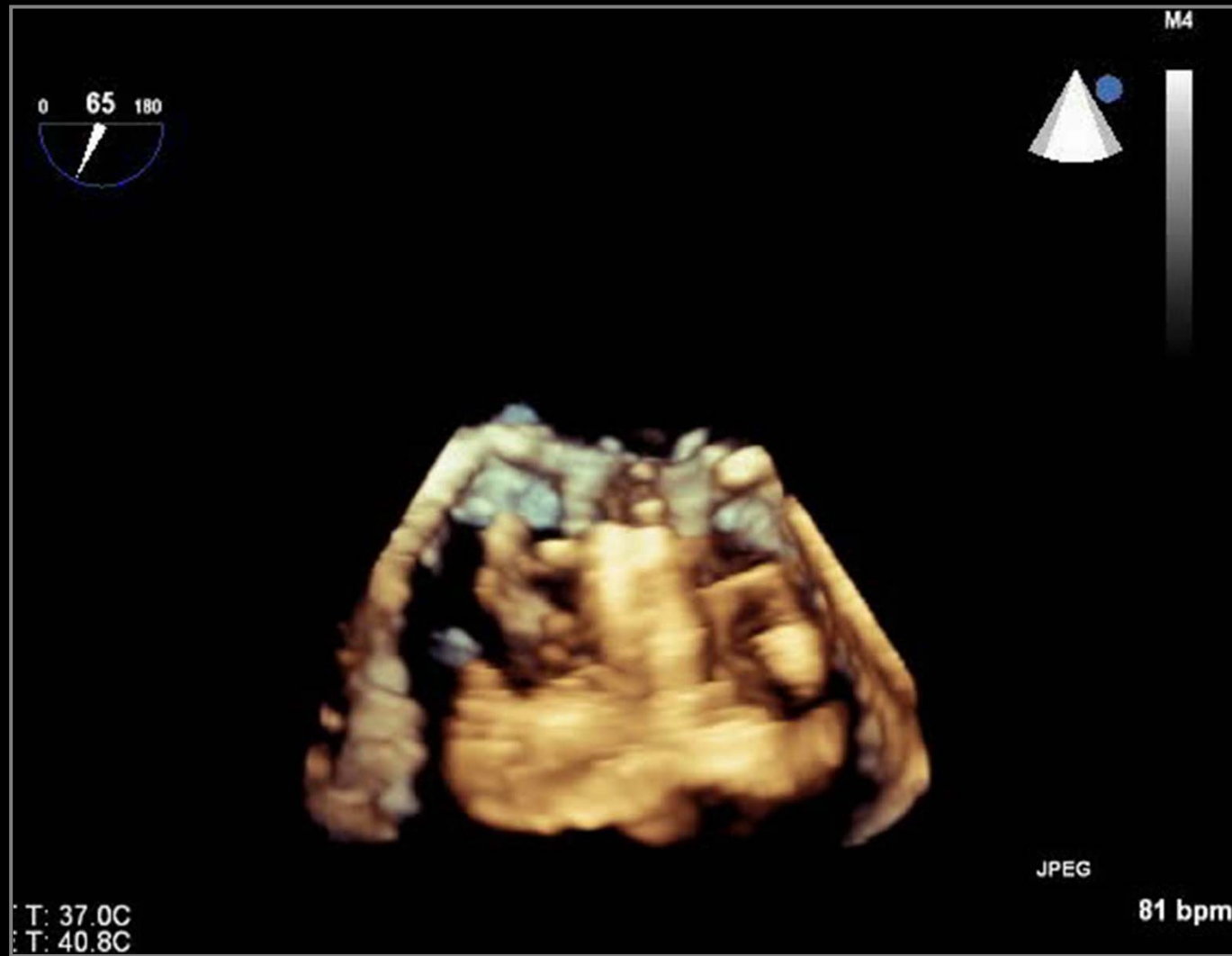


2010/12/24

# Prosthetic MV Malfunction

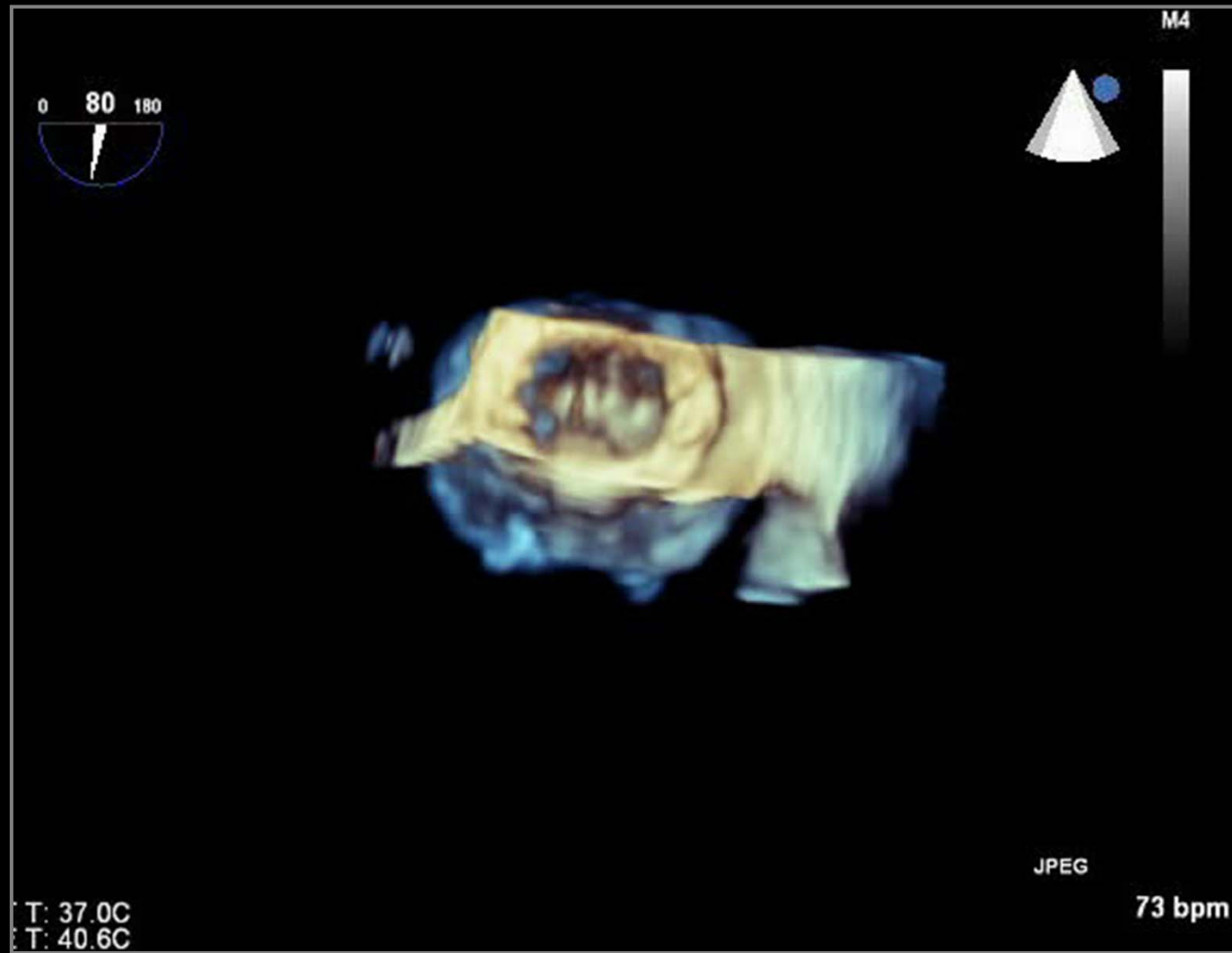


# Prosthetic MV Malfunction

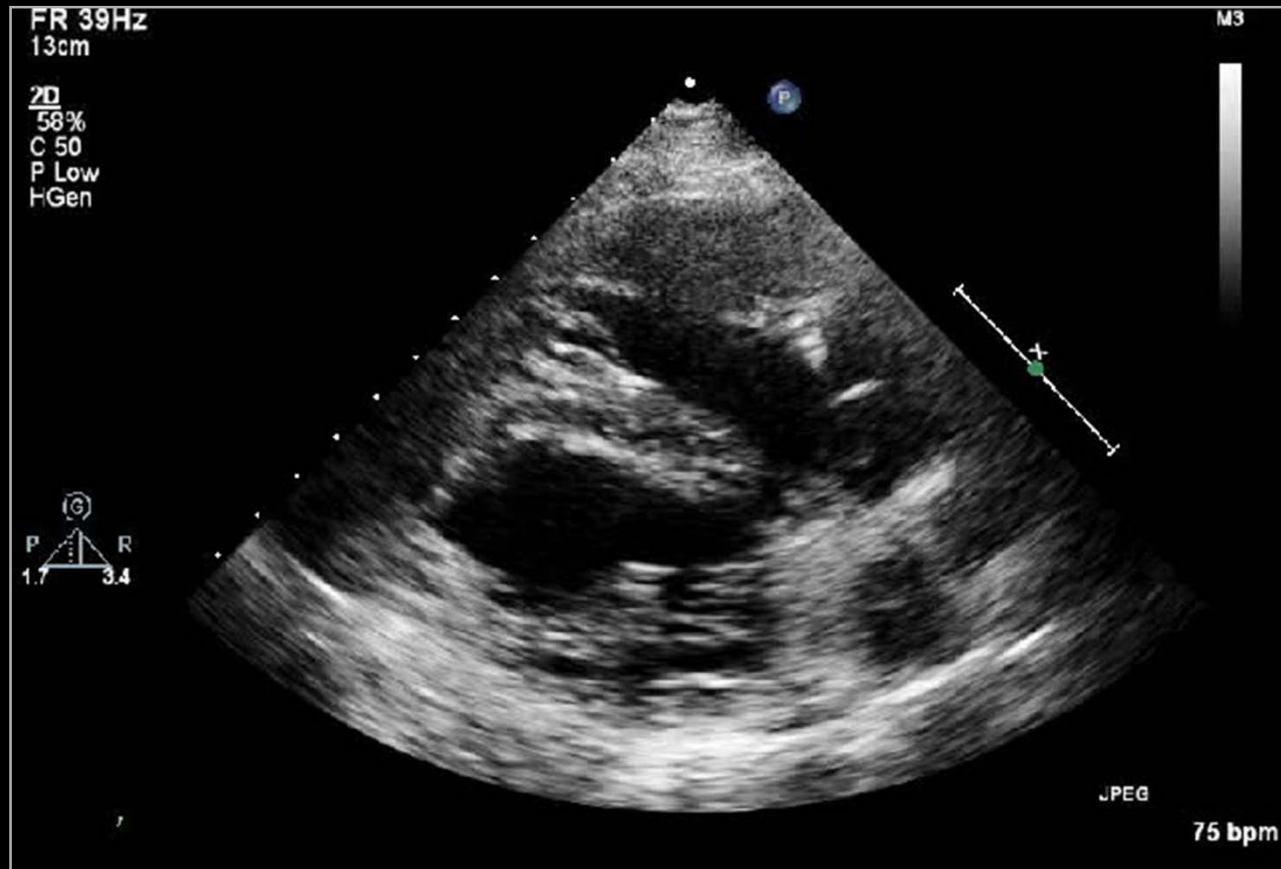




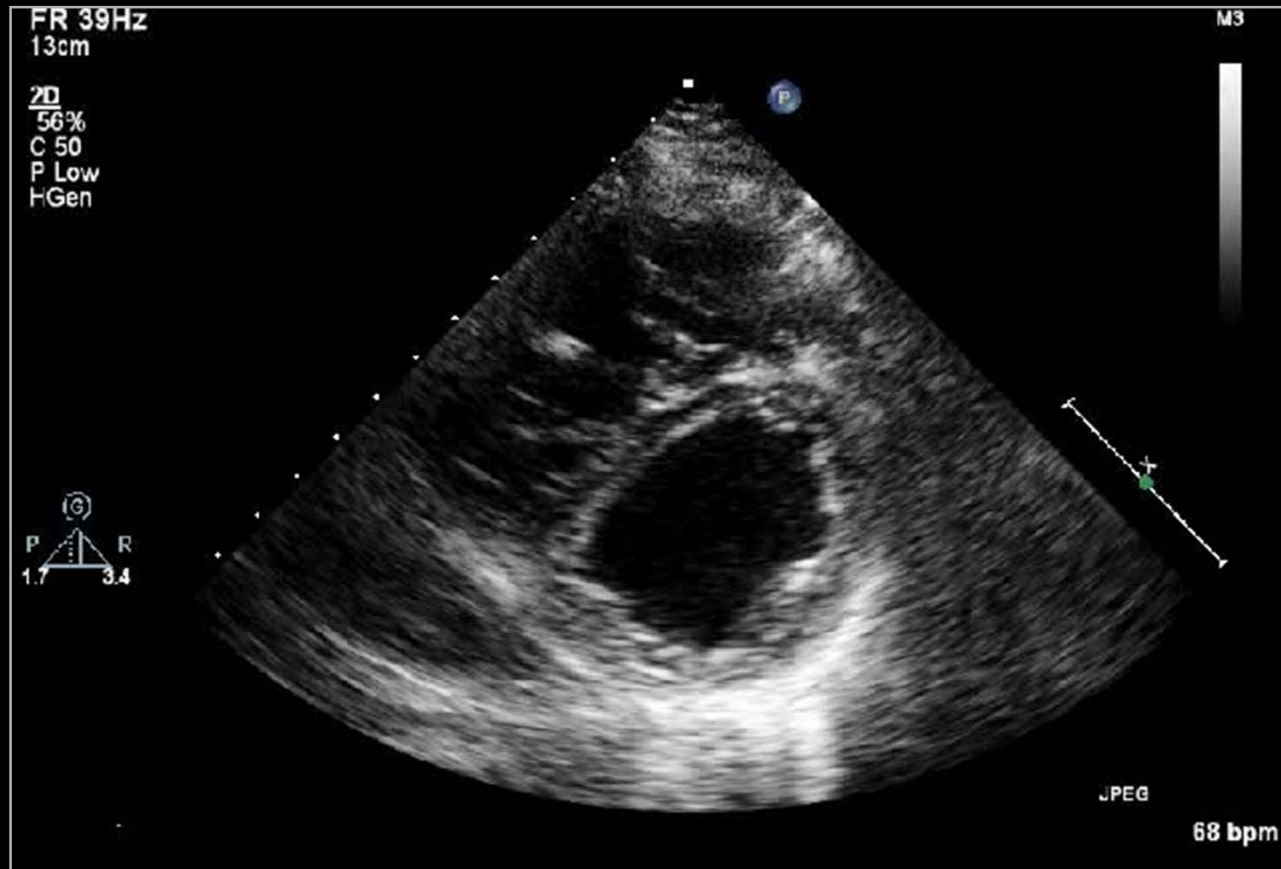
# Prosthetic MV Malfunction



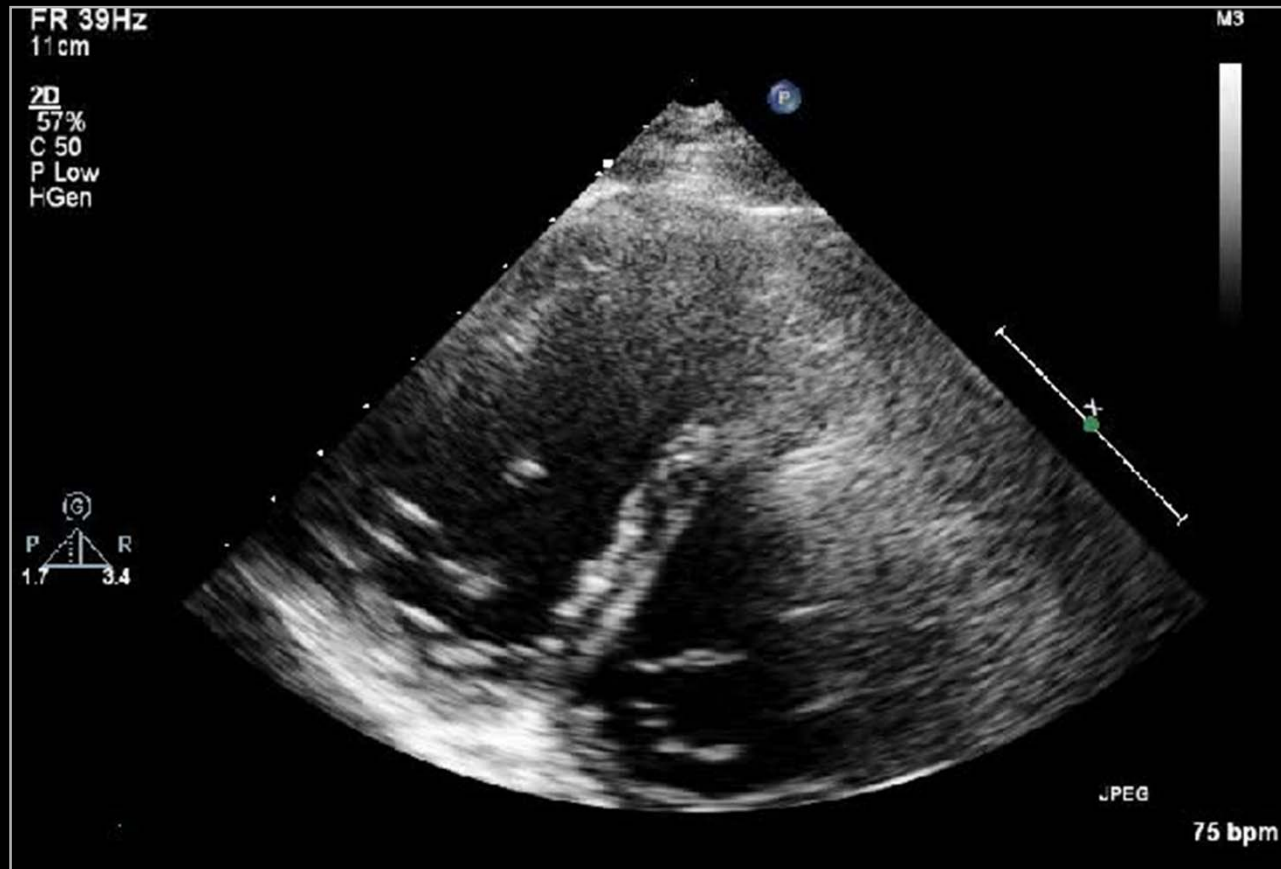# Tetralogy of Fallot



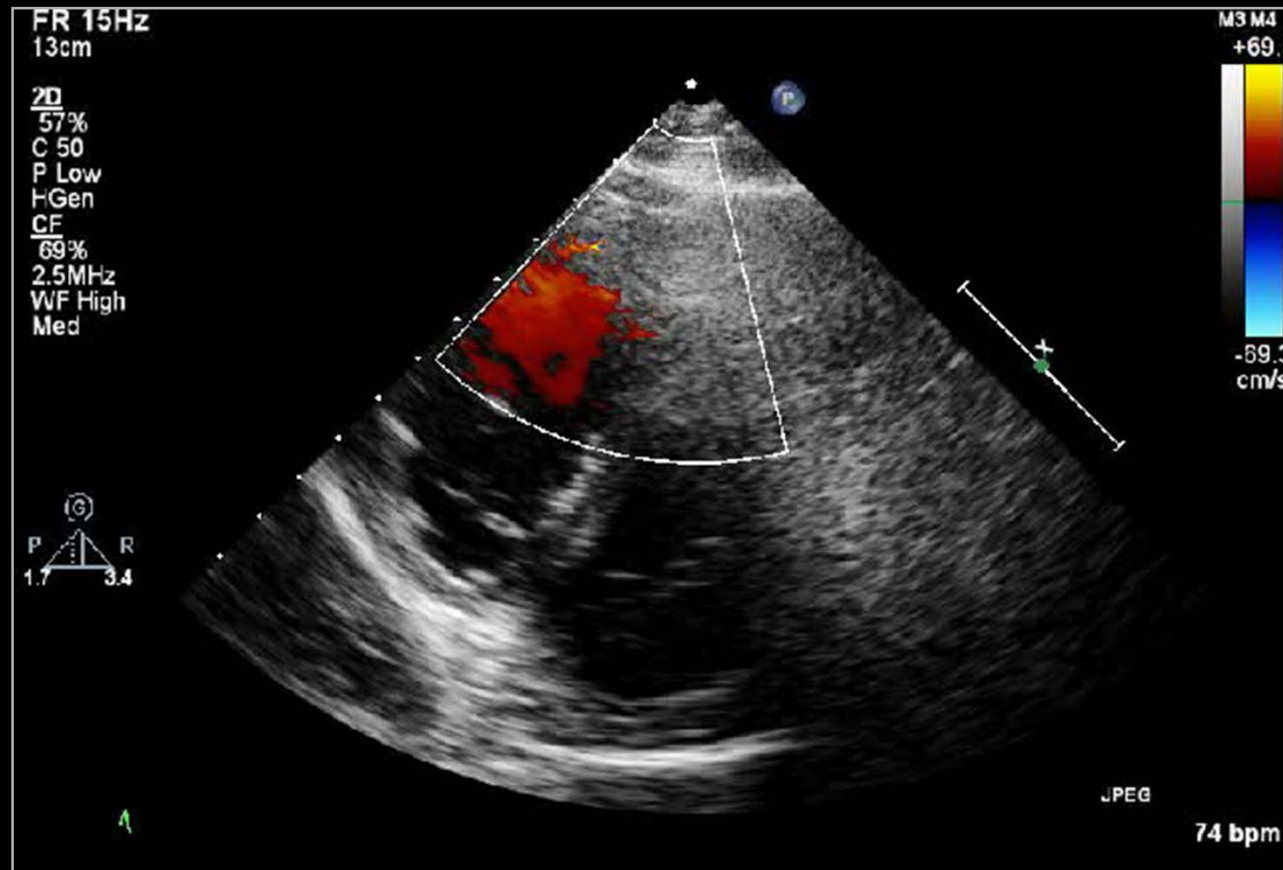
# Tetralogy of Fallot



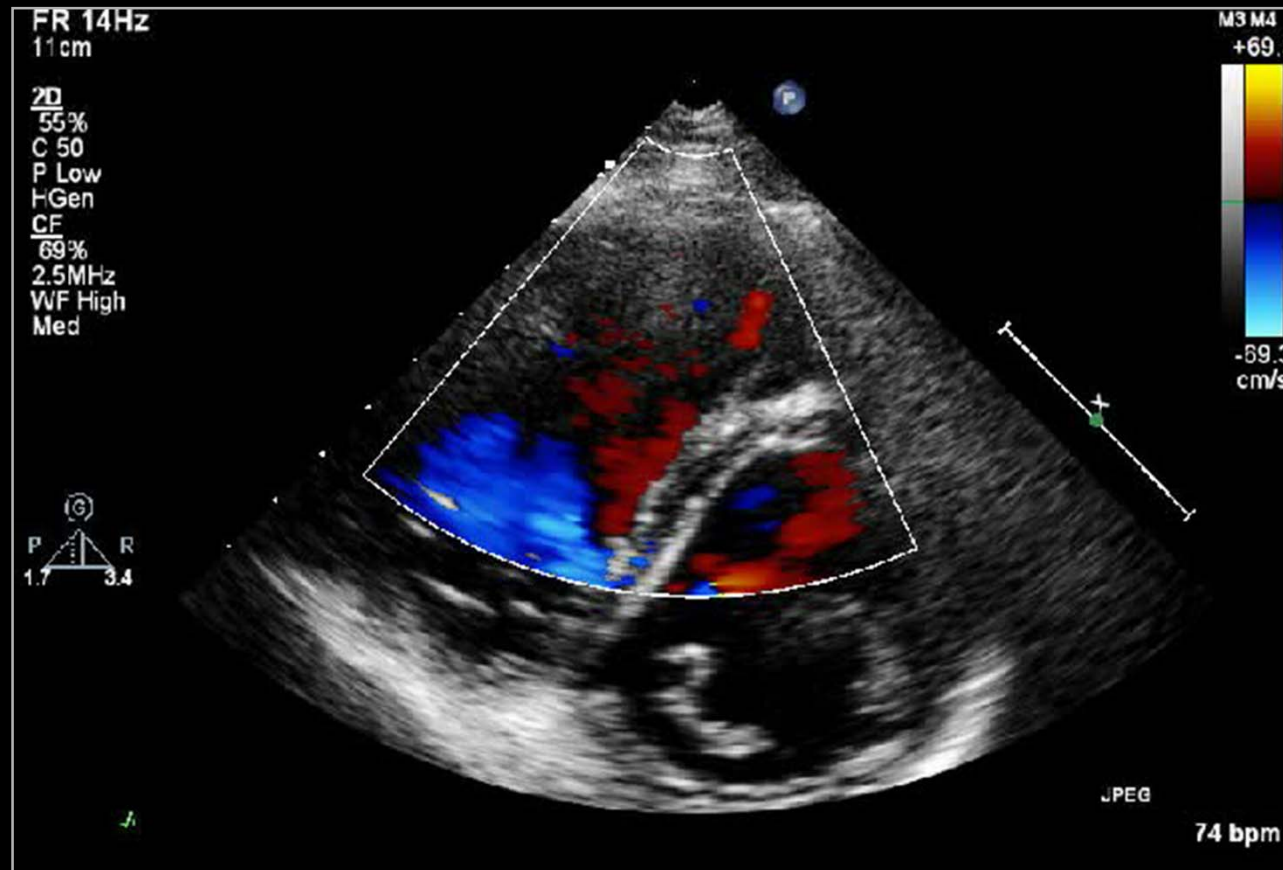
# Tetralogy of Fallot



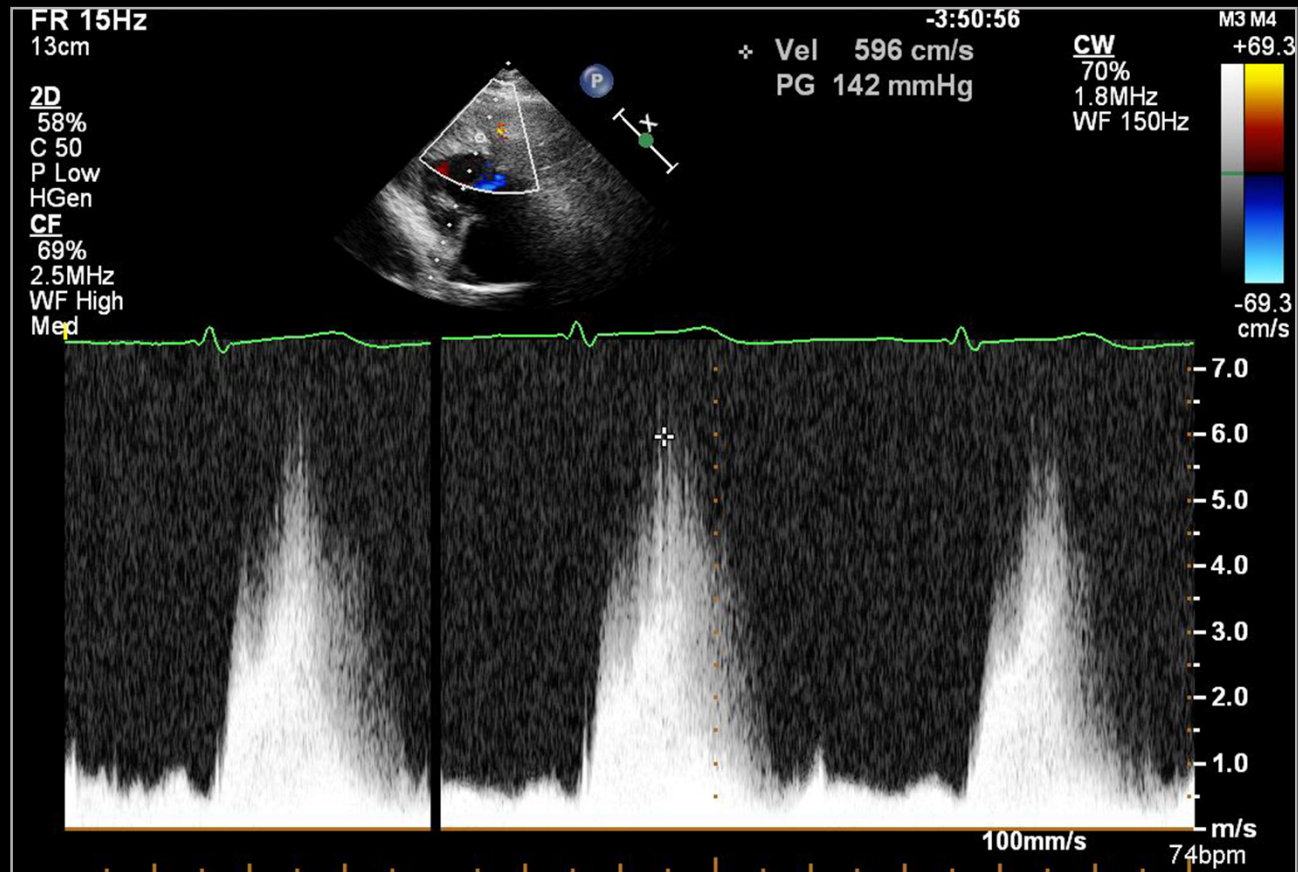
# Tetralogy of Fallot



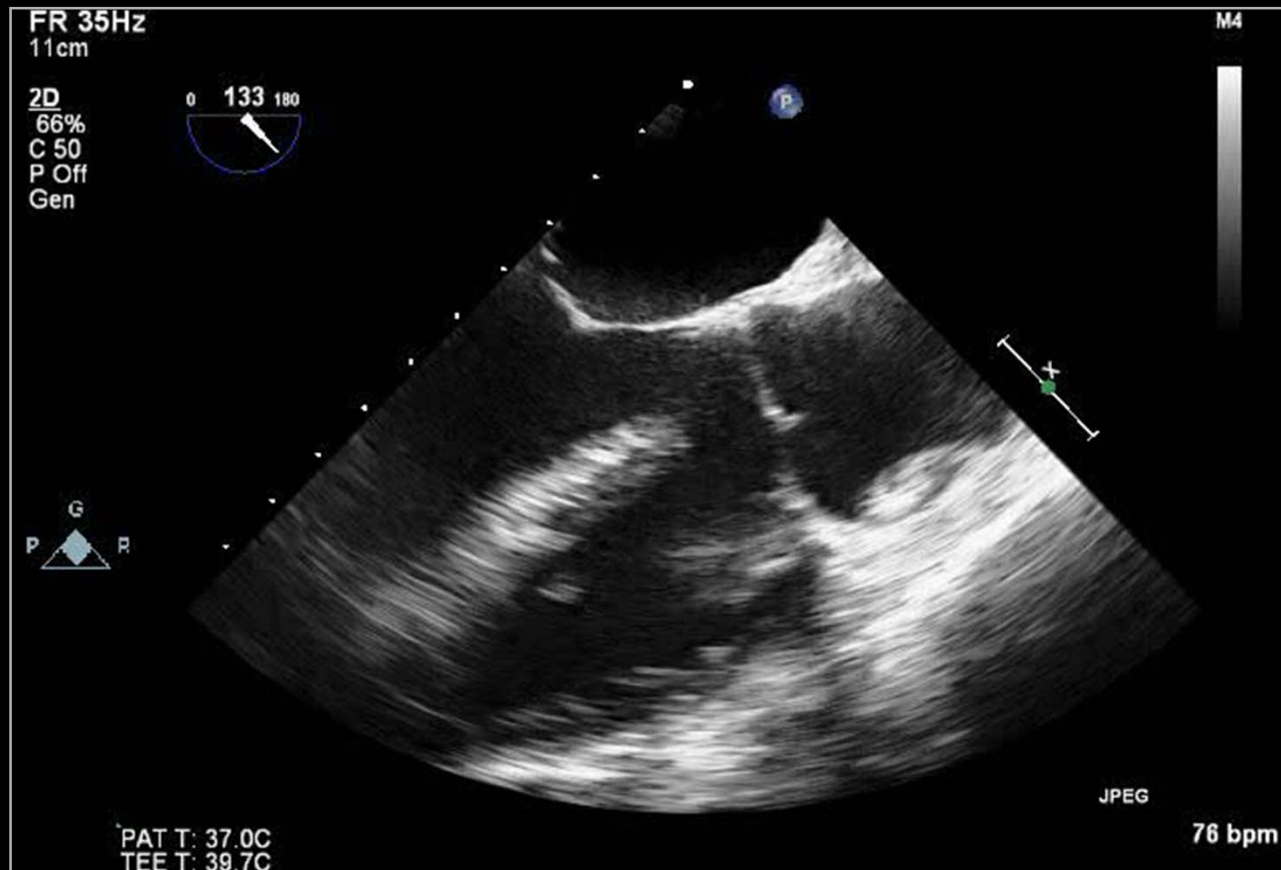
# Tetralogy of Fallot



# Tetralogy of Fallot

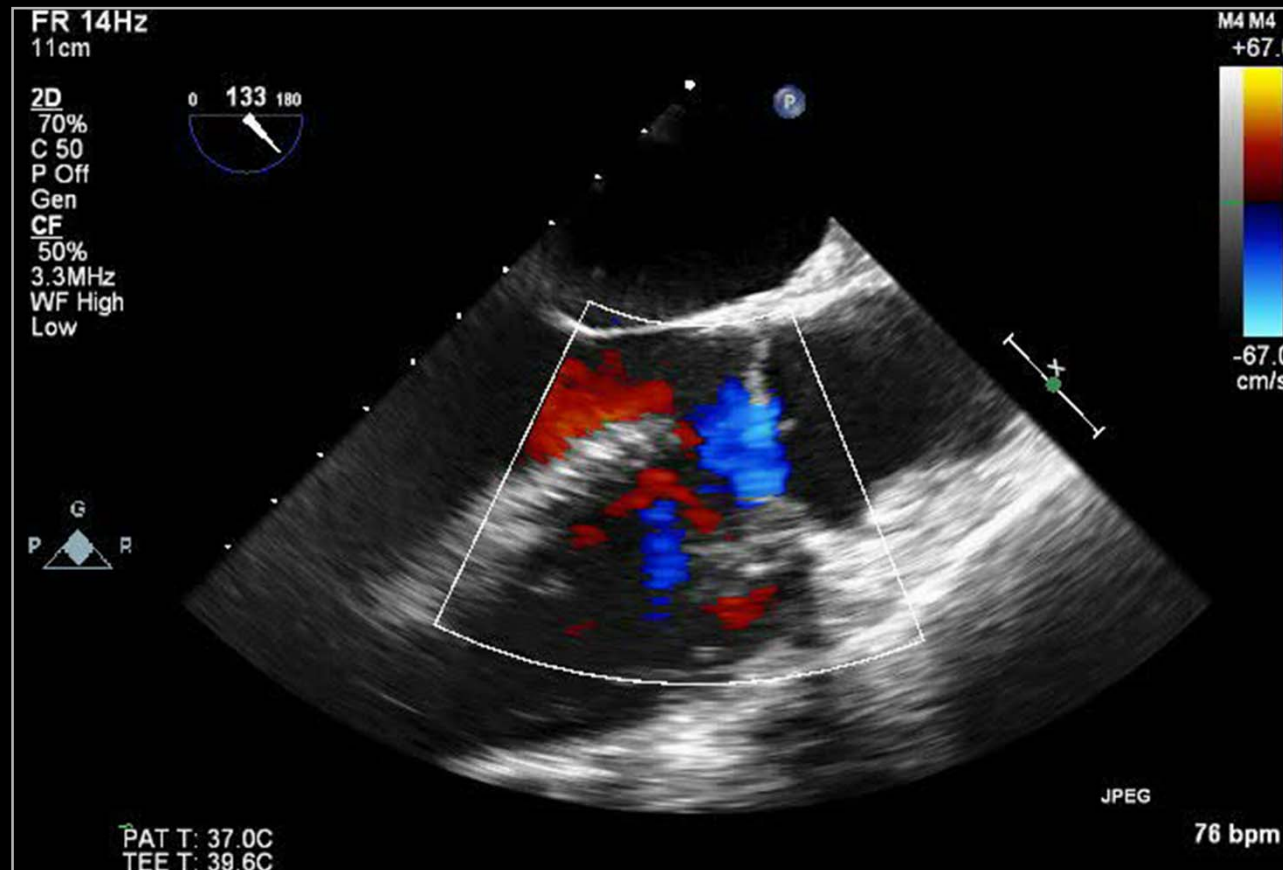


# Tetralogy of Fallot

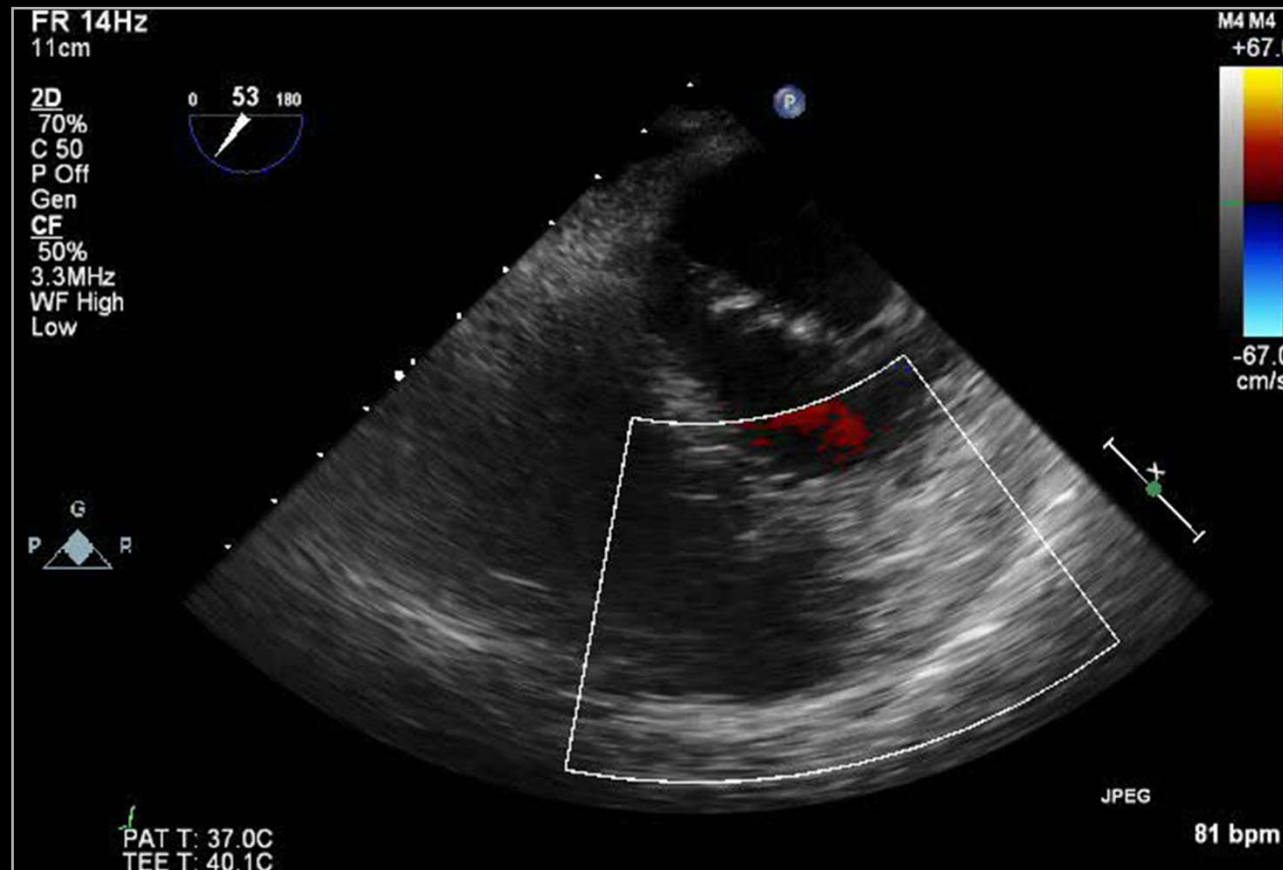




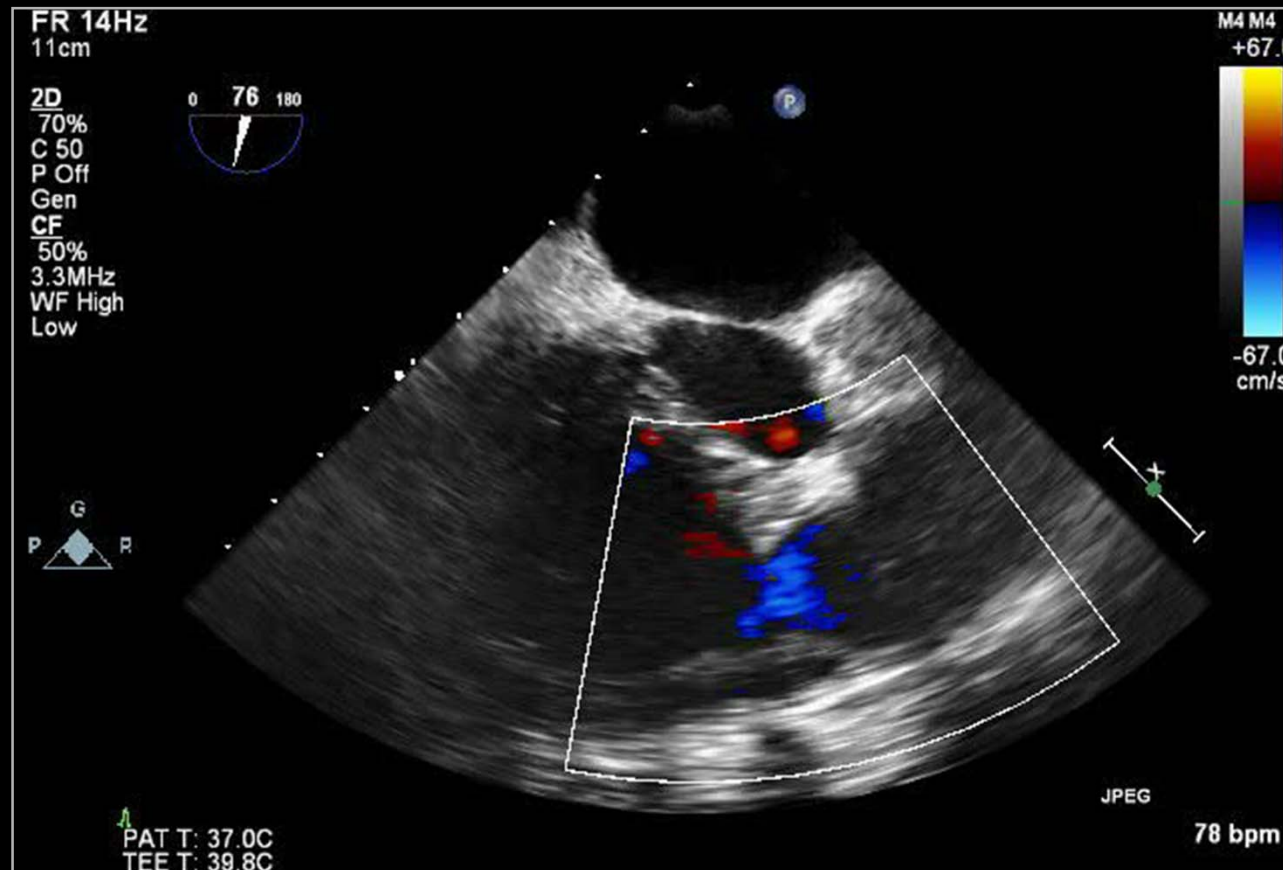
# Tetralogy of Fallot



# Tetralogy of Fallot



# Tetralogy of Fallot



# Tetralogy of Fallot

