Quantitative Assessment of Pulmonary Regurgitation by Echocardiography in Patients After Repaired TOF

2013. 4. 20.

서울대학교 어린이병원 소아청소년과

권보상

W. B.

TOF (large VSD, infundibular stenosis)

19 mo, 8.5 kg

Indication for surgery: cardiac failure, terminal

O2 Sat 25 % -> 94%

Ann Surg. 1955 September; 142(3): 418–442.

Survival of the patients with repaired TOF

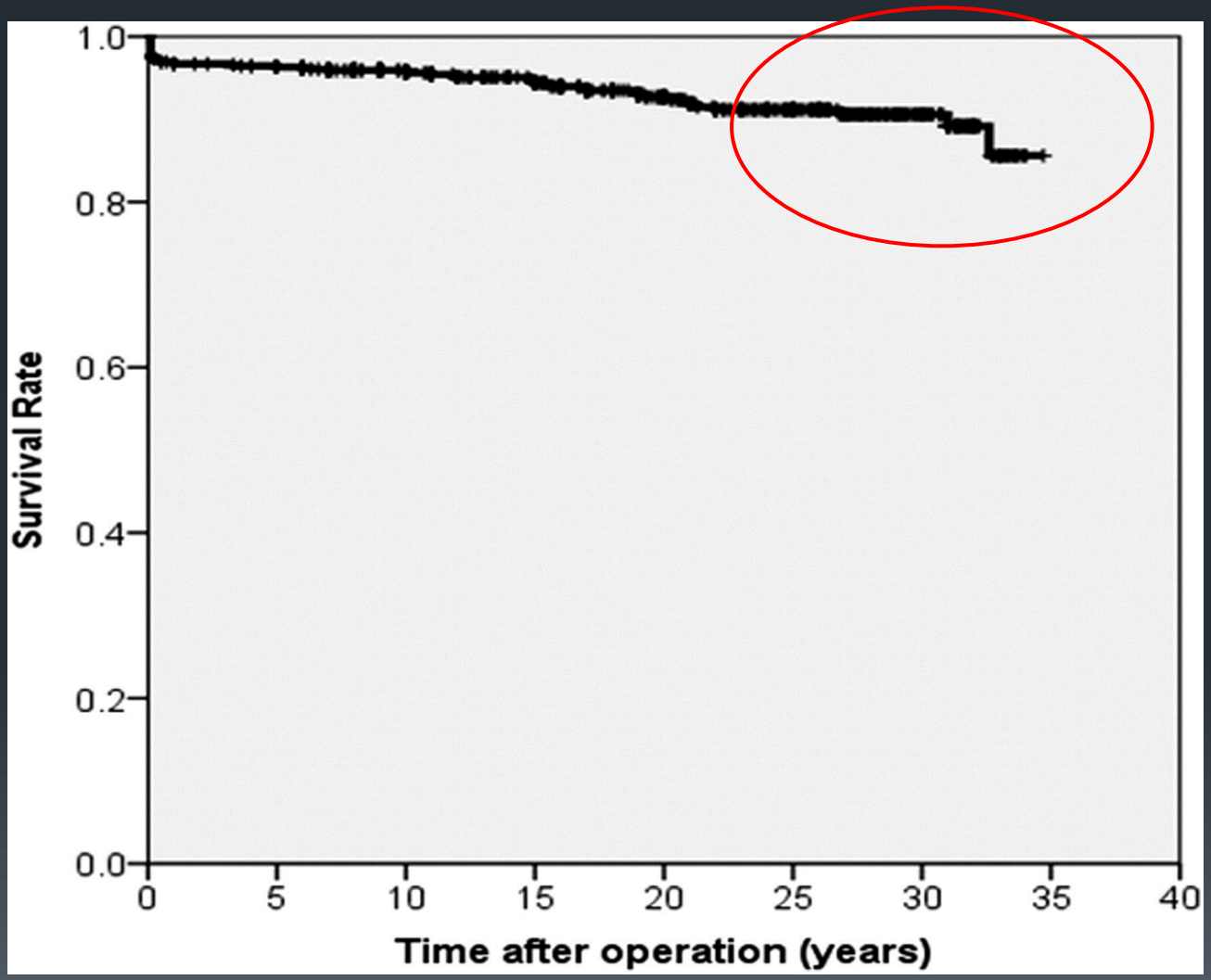

Chiu S et al. Circ Cardiovasc Qual Outcomes 2012;5:120-125

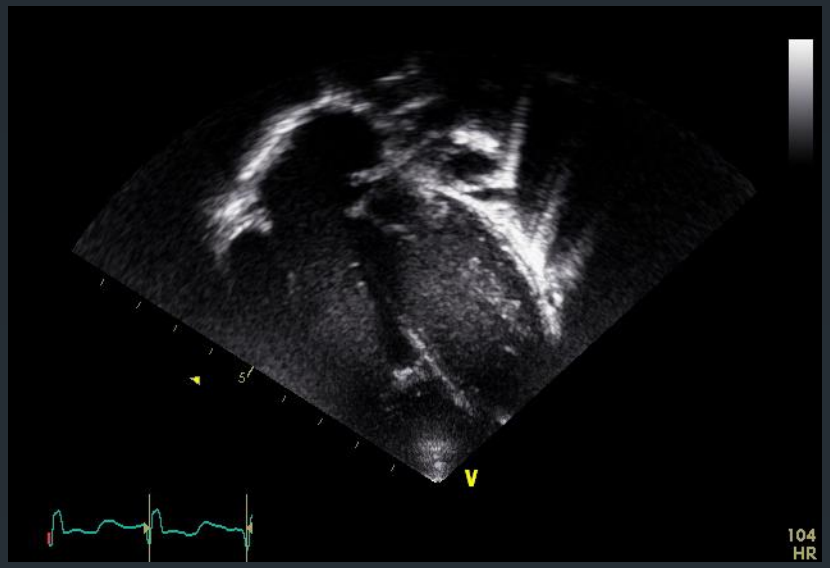
5
V
104
HR

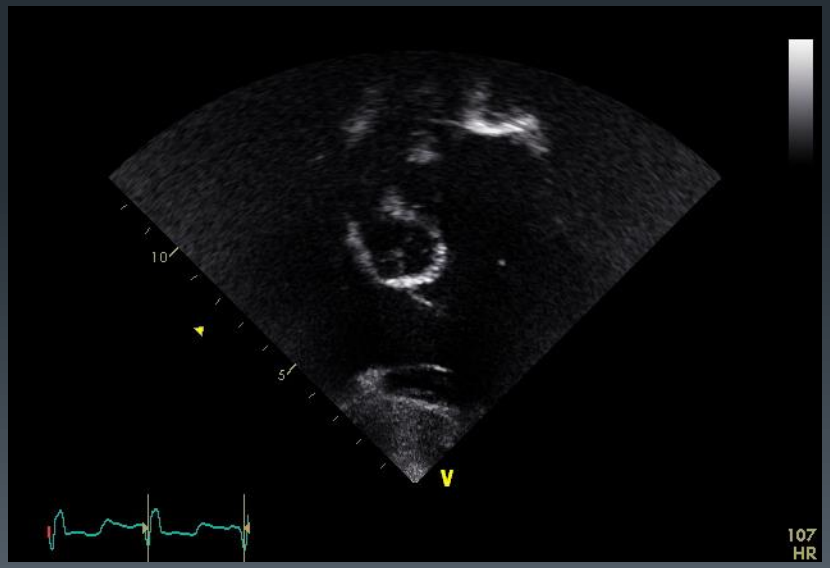
10
5
V
107
HR

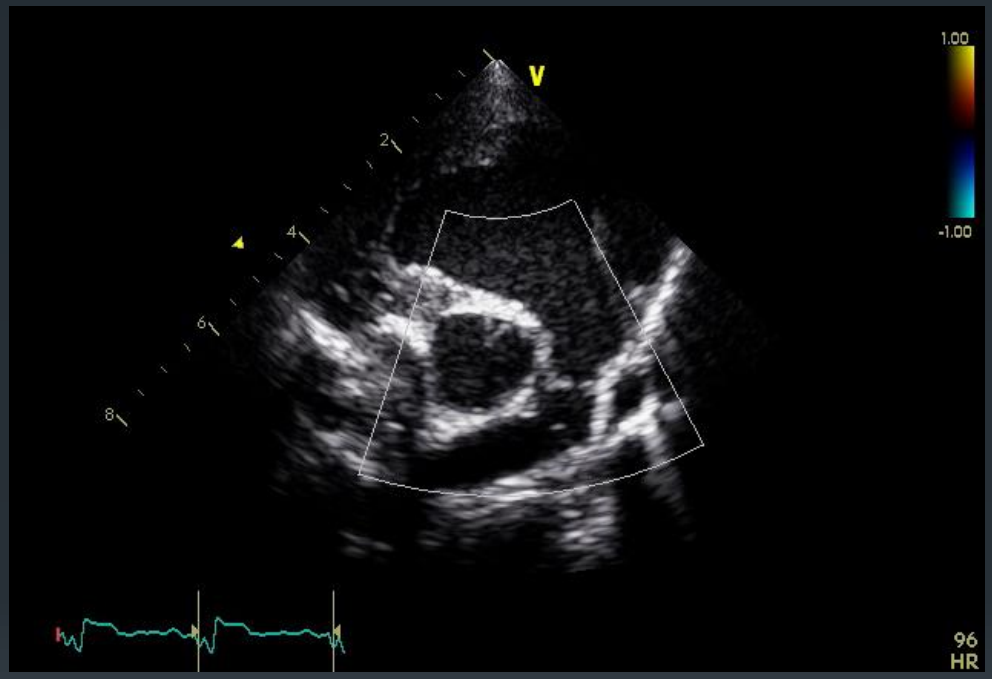
V
2
4
6
8
1.00
-1.00
96
HR

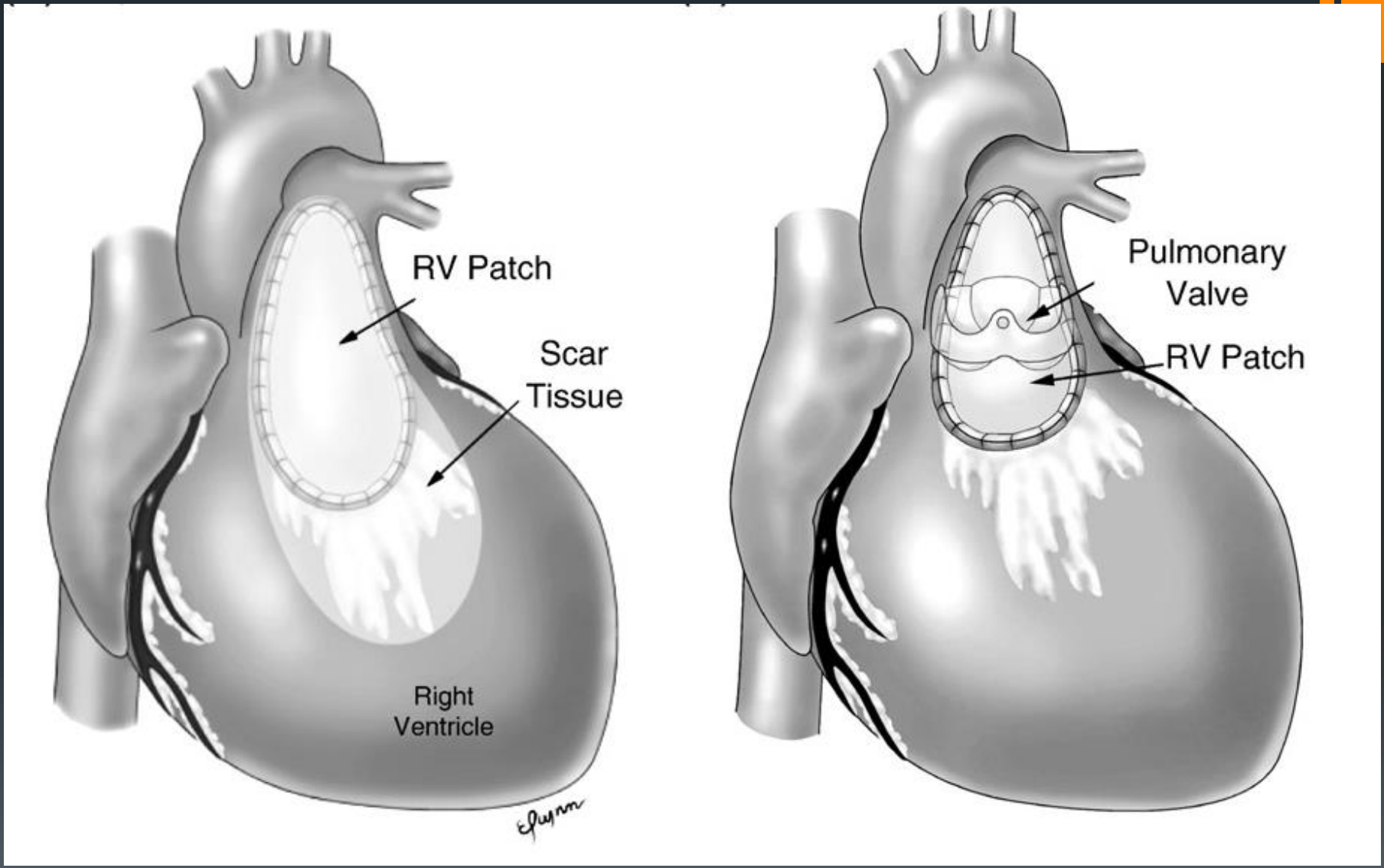

D. Tang et al. / Progress in Pediatric Cardiology 30 (2010) 51–62

Indications for Pulmonary Valve Replacement

- Moderate or severe pulmonary regurgitation (regurgitation fraction ≥25%)

MRI > Echo

- Asymptomatic patient with two or more of the following criteria
  - RV end-diastolic volume index >150 ml/m2 or Z-score >4. In patients whose body surface area falls outside published normal data: RV/LV EDV ratio >2
  - RV ESV index >80 ml/m2
  - RV EF <47%
  - LV EF <55%
  - Large RVOT aneurysm
  - QRS duration >140 ms
  - Sustained tachyarrhythmia related to right heart volume load
  - Other hemodynamically significant abnormalities: RVOTO, severe branch PS, moderate TR, residual L->R shunt (Qp/Qs ≥1.5),severe AR, Severe aortic dilatation (diameter ≥5 cm)

Echo = MRI

Geva Journal of Cardiovascular Magnetic Resonance 2011, 13:9

Indications for Pulmonary Valve Replacement

- Moderate or severe pulmonary regurgitation (regurgitation fraction ≥25%)

- Symptomatic patients
  - Symptoms and signs attributable to severe RV volume load documented by CMR or alternative imaging modality, fulfilling ≥1 of the quantitative criteria detailed above.
    - Exercise intolerance not explained by extra-cardiac causes with documentation by exercise testing with metabolic cart (≤70% predicted peak VO2 for age and gender not explained by chronotropic incompetence)
    - Signs and symptoms of heart failure (e.g., dyspnea with mild effort or at rest not explained by extracardiac causes, peripheral edema)
    - Syncope attributable to arrhythmia

Geva Journal of Cardiovascular Magnetic Resonance 2011, 13:9

Echocardiography in adults with TOF

1. Assessment of physiologic and hemodynamic parameters that influence outcome
   1. RV and LV size and function
   2. Pulmonary regurgitation and / or stenosis
   3. Tricuspid regurgitation
   4. (QRS duration >180 ms)

2. Assessment of anatomic criteria of unknown significance on outcomes: RVOT aneurysm, DCRV, aortic dilatation and aortic regurgitation

3. Assessment of suitability of RVOT morphology for transcatheter pulmonary valve implantation.

   RVOT diameter (< 22 mm), prior repair without a transannular patch

Wyman W. Lai, et al.(eds) Echocardiography in pediatric and congenital heart disease from fetus to adult. 2009

TR grade

	Mild	Moderate	Severe
TV	Usually normal	Normal/ abn	Abn/ fail leaflet /poor coaptation
RV/RA/IVC size	Normal	Normal or dilated	Usually dilated
Jet area-central jets (cm2)	<5	5-10	>10
VC width (cm)	Not defined	Not defined, but <0.7	>0.7
PISA radius	≤ 0.5	0.6-0.9	>0.9
Jet density and contour CW	Soft and parabolic	Dense, variable contour	Dense, triangular with early peaking
Hepatic vein flow	Systolic dominance	Systolic blunting	Systolic reversal

>35% RA area
IVC retrograde flow

J Am Soc Echocardiogr 2003;16:777-802

PR grade

	Mild	Moderate	Severe
Pul valve	normal	Normal/abn	abn
RV size	normal	Normal/ dilated	Dilated
Jet size by CD	Thin (usually <10 mm in length) with narrow origin	Intermediate	Usually large, with a wide origin; maybe brief in duration
Jet density and deceleration rate -CW	Soft; slow deceleration	Dense, variable deceleration	Dense; steep deceleration, early termination of diastolic flow
Pulmonary systolic flow compared to systemic flow -PW	Slightly increased	intermediate	Greatly increased

J Am Soc Echocardiogr 2003;16:777-802

Echocardiographic Assessment of Pulmonary Regurgitation (PR)

- The ratio of jet width / RV outflow diameter: mild ≤1/3; moderate 1/3-2/3; and severe ≥ 2/3
- Ratio of duration of PR/ duration of diastole >0.77 correlates with PR regurgitant fraction > 24.5% by CMR
- Pressure half time <100 ms correlates with hemodynamically significant PR
- Presence of diastolic flow reversal in branch pulmonary arteries is associated with hemodynamically significant PR

Wyman W. Lai, et al.(eds) Echocardiography in pediatric and congenital heart disease from fetus to adult. 2009

Grading PR severity – color Doppler

- Mild : small flame below the pulmonary valve
- Moderate : jet in the right ventricular outflow tract (RVOT) with retrograde diastolic flow in the pulmonary artery
- Severe: retrograde diastolic flow in both pulmonary artery branches.

Grading PR severity – color Doppler

- Regurgitant jet width (measured at valve level during early diastole)
- RVOT diameter measured at valve level
- Regurgitant jet width / RVOT diameter (< 0.3, >0.6)

Am Heart J 2004;147:165–172

Color flow and *CW* Doppler

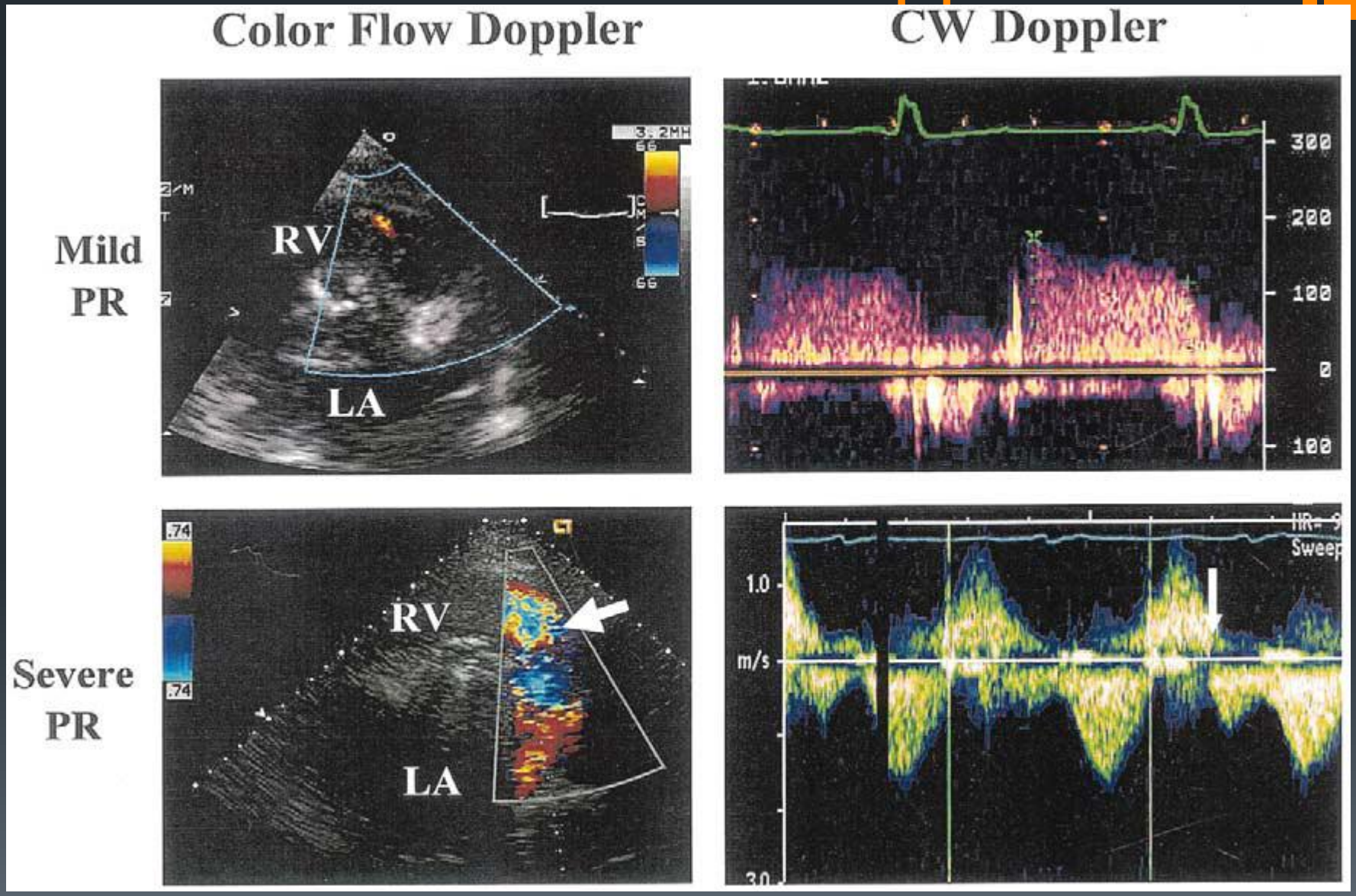

J Am Soc Echocardiogr 2003;16:777-802

Severity of PR assessed by continuous wave Doppler.

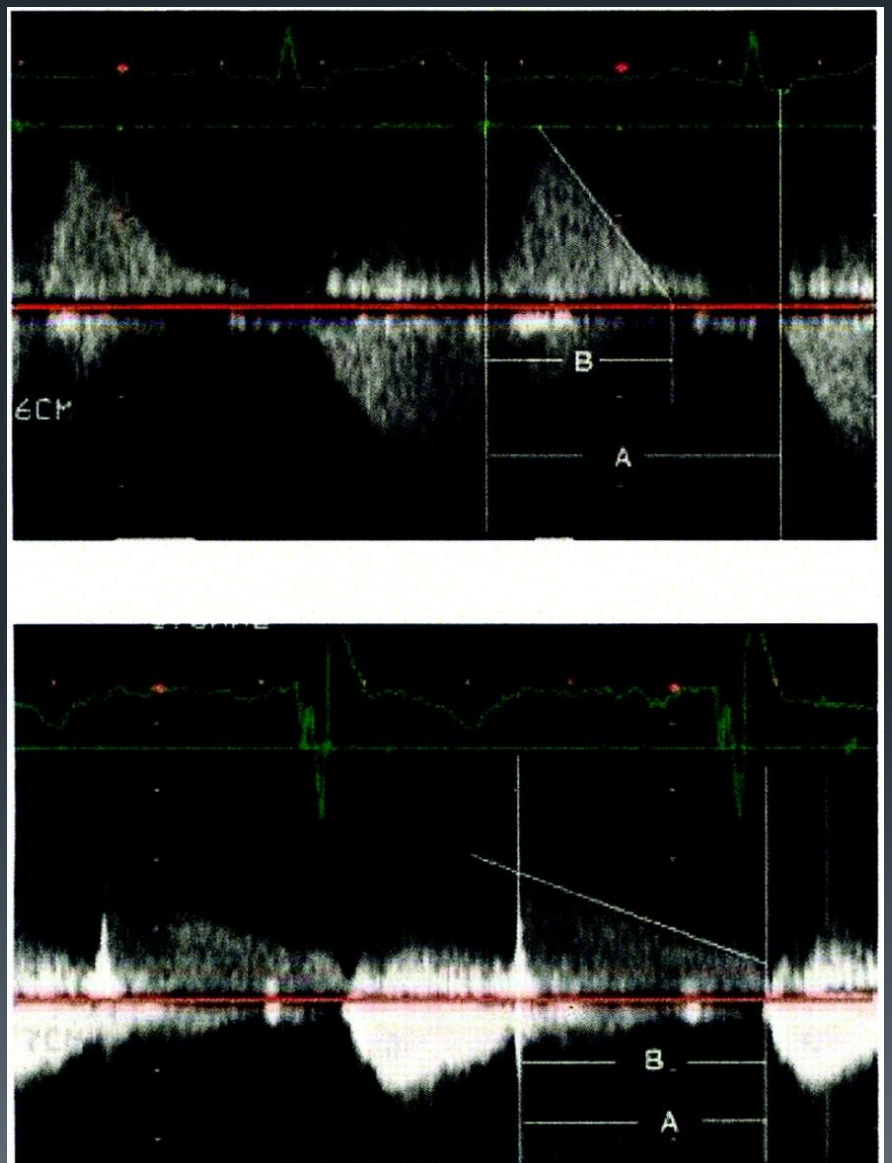

Bouzas B et al. Eur Heart J 2005;26:433-439

PR severity (CW Doppler)

- PR duration: from the onset in early diastole to the end of the PR Doppler signal
- Total diastolic time: measured from the end of forward pul flow (coinciding with the onset of the retrograde PR flow) to the beginning of the next forward pulmonary flow curve
- The ratio btw duration of PR and total diastolic time = PR index (Pri)
  - Mild : through diastole
  - Moderate: late diastole
  - Severe: mid-diastole or earlier

>0.77 : significant PR

Am Heart J 2004;147:165–172

PR severity (CW Doppler)

	Group I (PRF ≤24.5%)	Group II (PRF >24.5%)	*P*
R-R interval (ms)	835.5 ± 108.3	795 ± 92.7	.3
MV-E (cm/s)	87 ± 16	88 ± 33	.91
MV-A (cm/s)	58 ± 17	52 ± 16	.22
MV: E/A ratio	1.58 ± 4.3	1.78 ± 0.7	.26
TV-E (cm/s)	57 ± 14	55 ± 16	.57
TV-A (cm/s)	45 ± 12	40 ± 13	.18
TV: E/A ratio	1.2 ± 0.3	1.4 ± 0.5	.27
Vmax TR (cm/s)	290 ± 70	296 ± 47	.75
Vmax Ao (cm/s)	103 ± 23	101 ± 19	.69
Vmax PA(cm/s)	222 ± 77	201 ± 63	.29
Diastolic time (ms)	517 ± 131	532 ± 135	.7
PR time (ms)	440 ± 135	340 ± 60	.001
PRi (PR/diastolic)	0.91 ± 0.11	0.61 ± 0.11	<.001
PA diameter (cm)	2.3 ± 0.4	2.4 ± 0.5	.11
PR width on color (cm)	0.7 ± 0.5	1.4 ± 0.4	<.001
PR width/PAD ratio	0.3 ± 0.2	0.6 ± 0.2	<.001

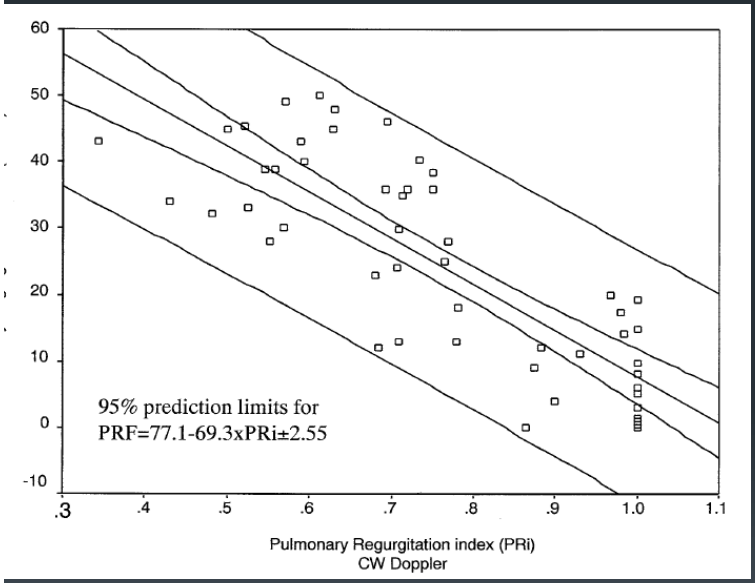

PRF (MRI) =77.1-69.3 x PRi (echo) ± 2.55

Am Heart J 2004;147:165–172

Pressure half-time / PR

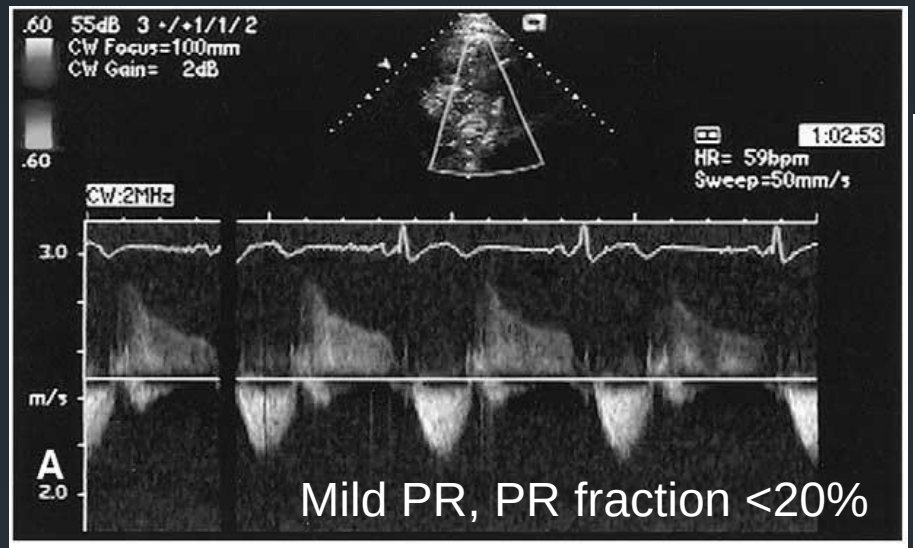

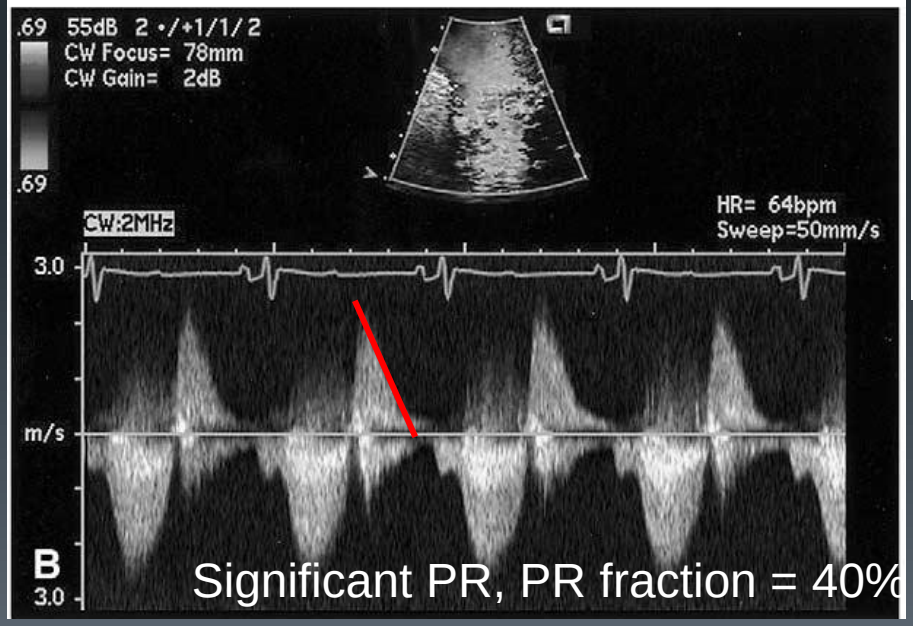

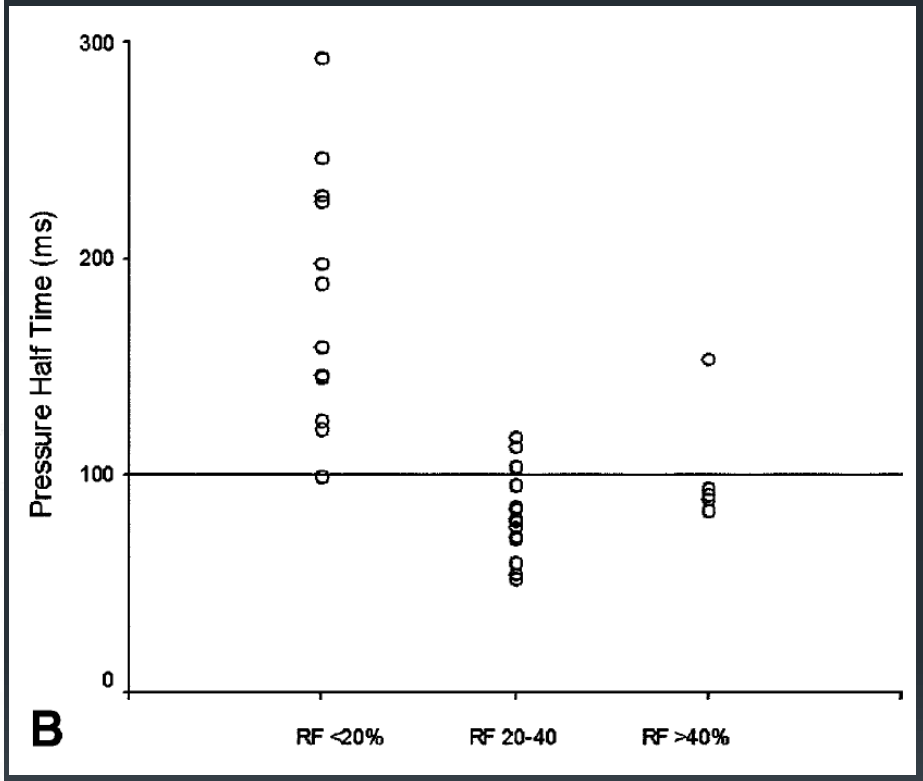

PHT < 100 ms
significant PR

J Am Soc Echocardiogr 2003;16:1057–1062

Quantifying Pulmonary Regurgitation in repaired TOF

DSTVI =0.27+0.011 x PRF

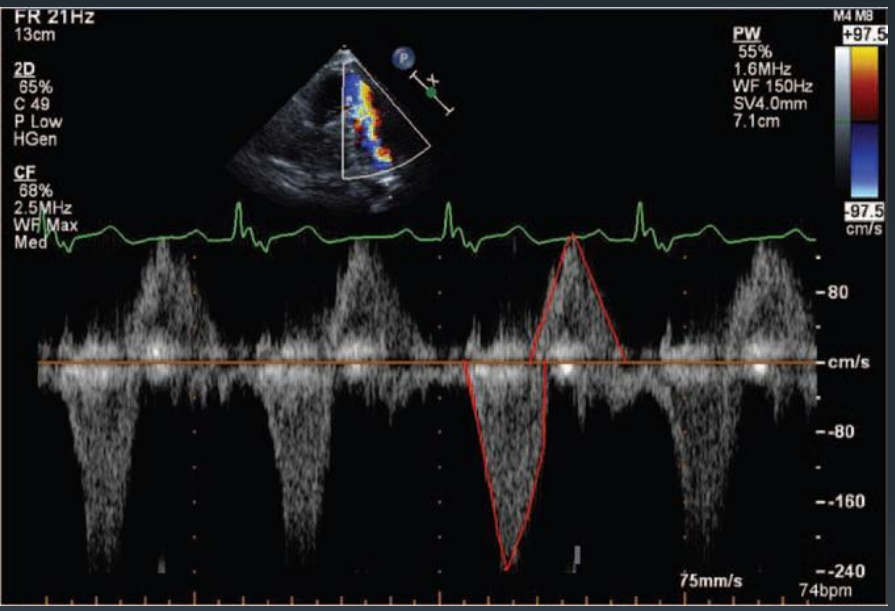

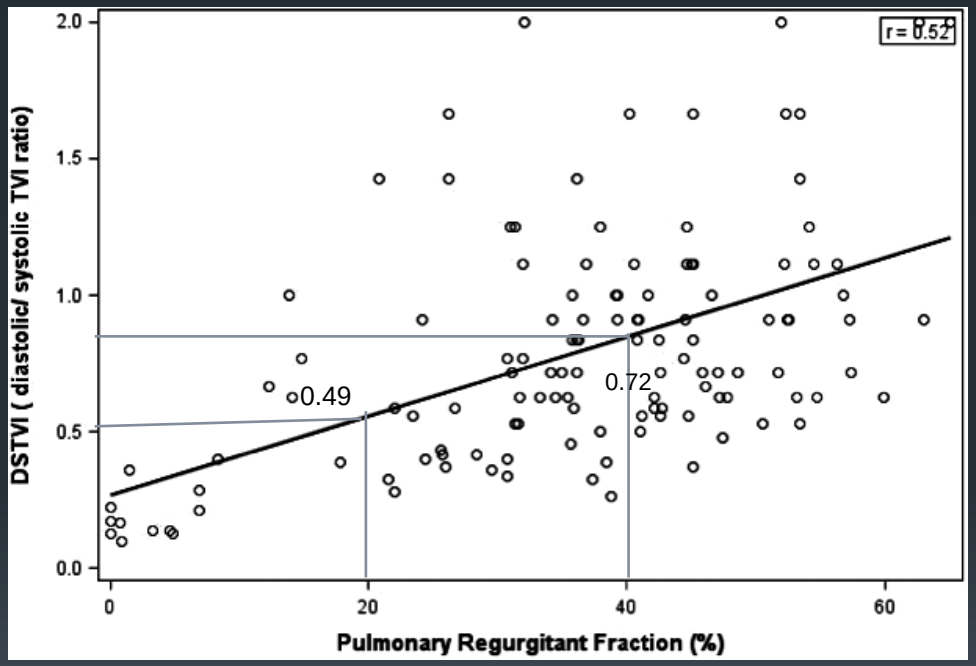

PW in MPA

The ratio of diastolic / systolic time velocity integral (DSTVI)

Circ Cardiovasc Imaging 2012;5;637-643

Determinants of the degree of pulmonary regurgitation

(1) Regurgitation orifice area (ROA)

(2) RV compliance

(3) Diastolic pressure difference between the main pulmonary artery (MPA) and the RV

(4) Capacitance of the pulmonary arteries

(5) Duration of diastole

$$\text{PR volume} = \text{ROA} \times C \times \text{DT} \times (P2 - P1)^{0.5}$$

(other factors: pulmonary vascular resistance, LV function)

ROA = regurgitation orifice area; C = constant (empiric number); DT = diastolic time; (P2 - P1) = mean diastolic pressure difference between the MPA and RV

AR 가 달리 MPA 와 RV 이완기 압력차이가 작다. (P2-P1)보다 다른 인자가 중요, 예외적으로 severe PHT 환자에서는 small ROA 에서 많은 양의 PR 이 생김

DT 은 HR 에 영향을 받음

T. Geva. Journal of Cardiovascular Magnetic Resonance 2011, 13:9

1) Regurgitation orifice area (ROA)

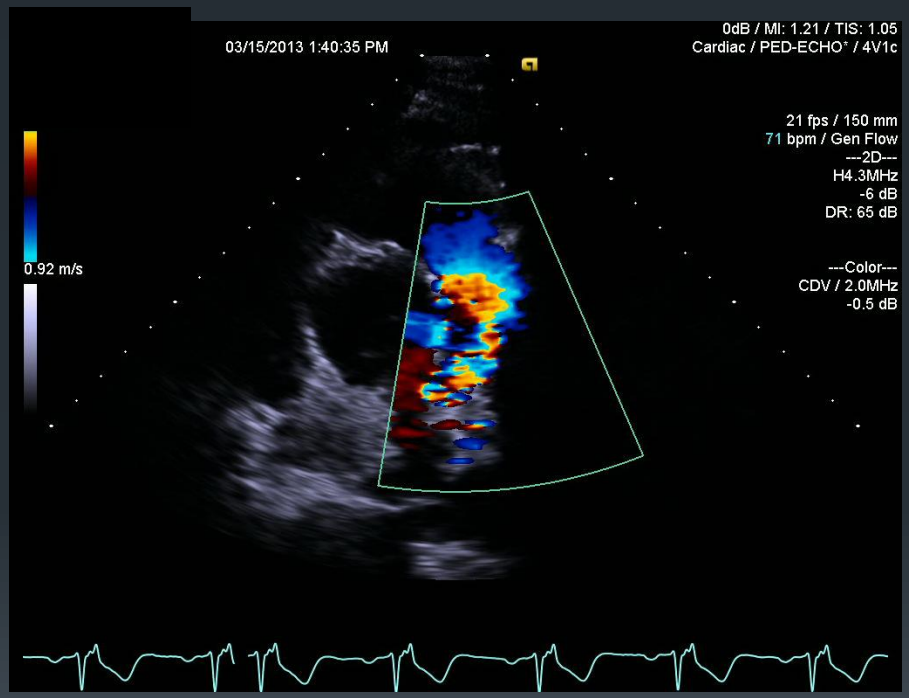

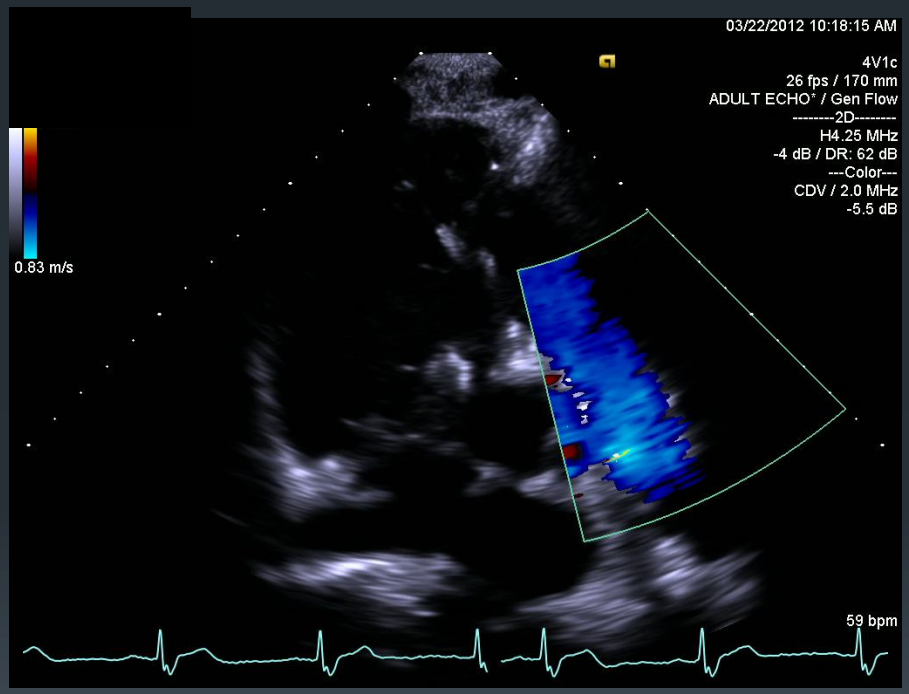

2) RV compliance

- Restrictive RV physiology
- RV size, systolic and diastolic function

RV diastolic function

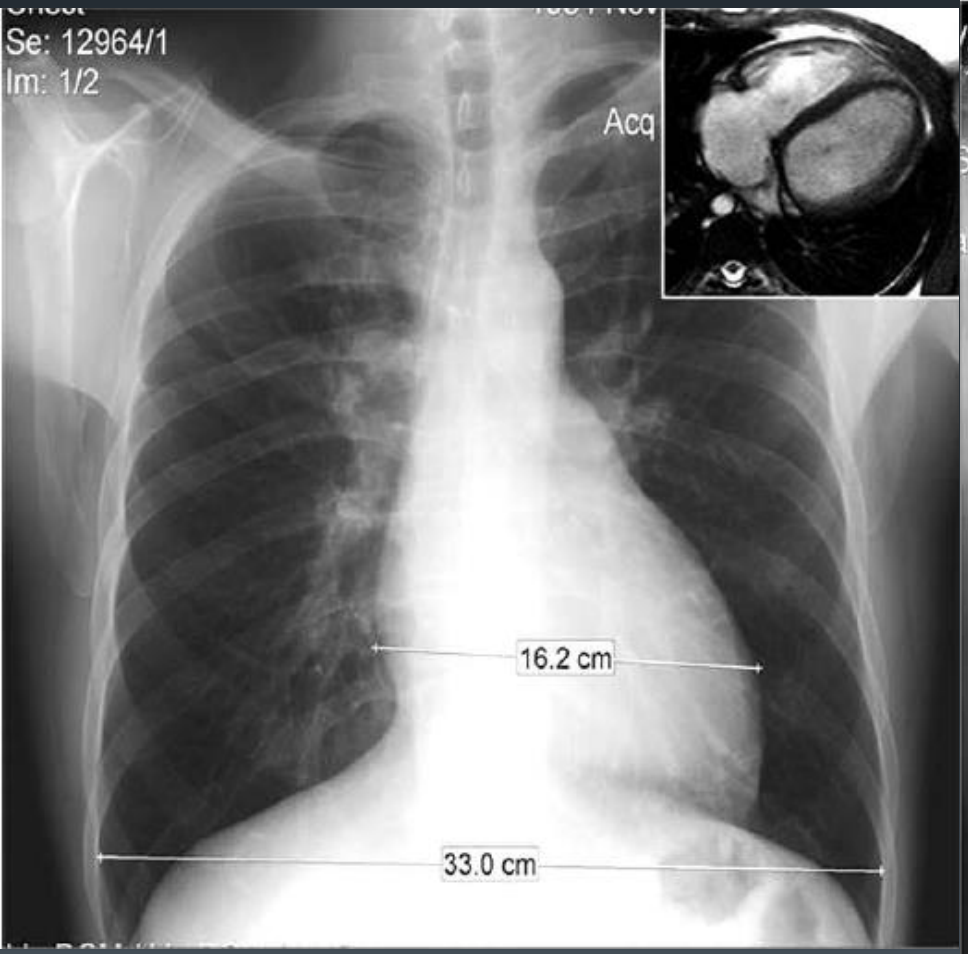

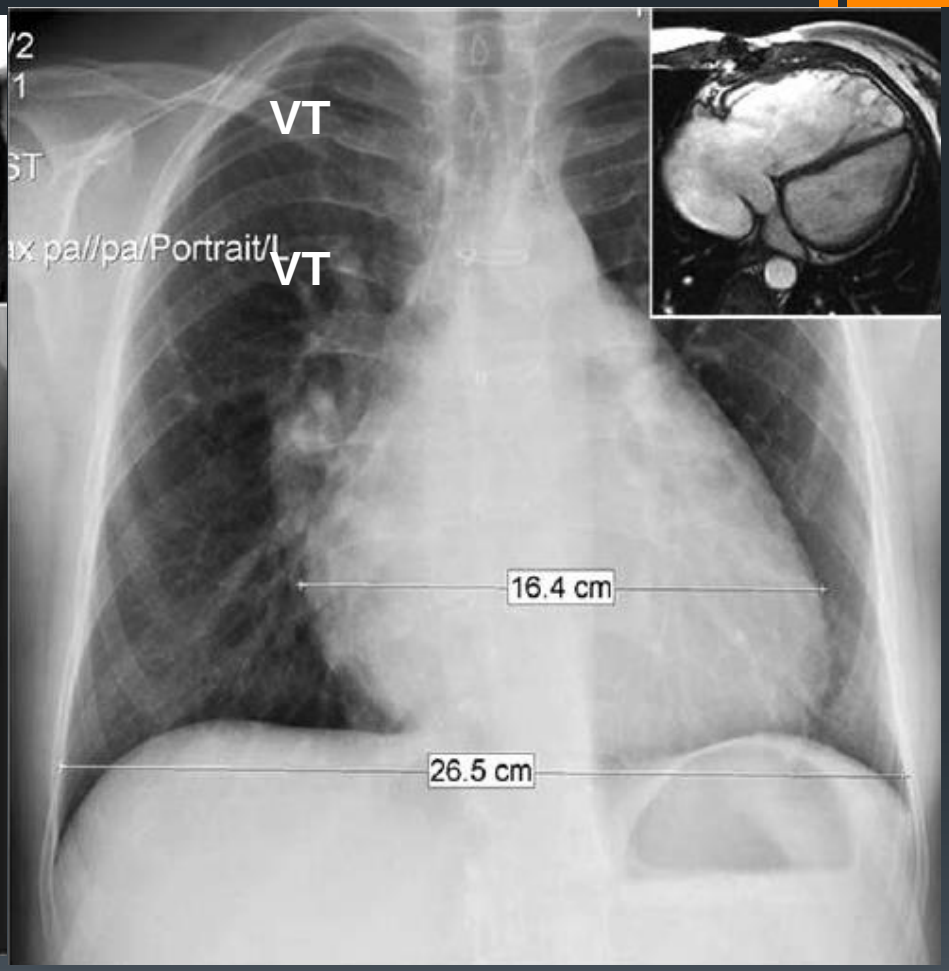

CT ratio =0.49

CT ratio =0.62

Semin Thorac Cardiovasc Surg Pediatr Card Surg Annu. 2006:3-10.

Restrictive RV physiology (PR)

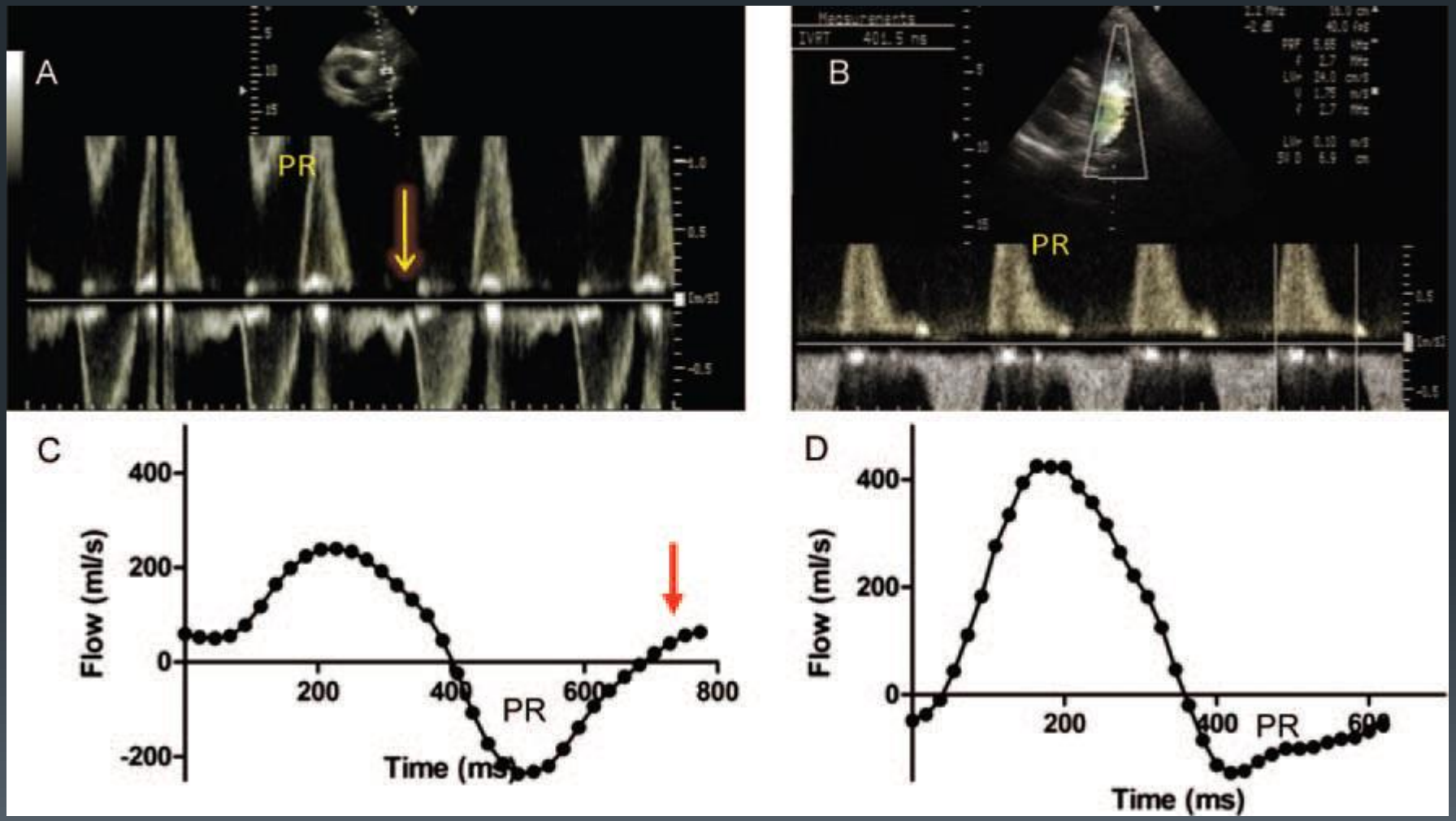

Semin Thorac Cardiovasc Surg Pediatr Card Surg Annu. 2006:3-10.

RV size / volume / function

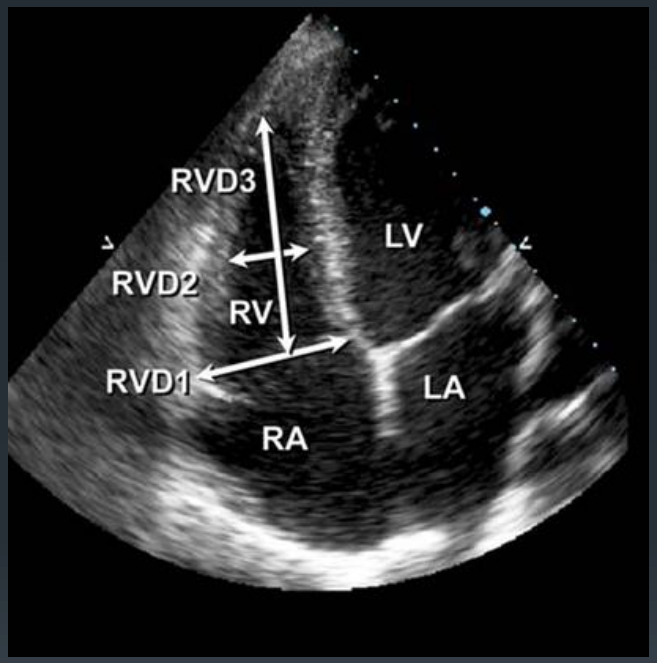

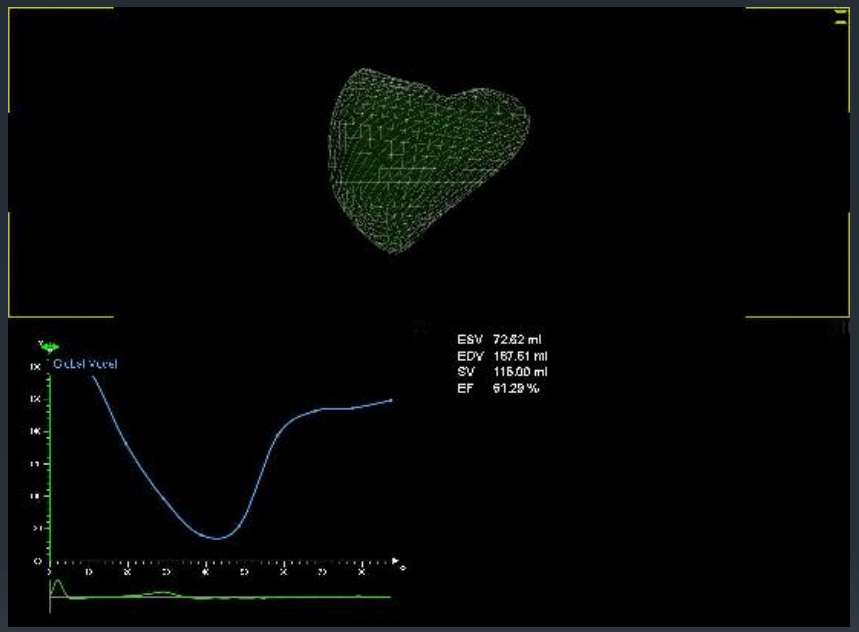

J Am Soc Echocardiogr 2010;23:685-713

Apical 4-chamber view

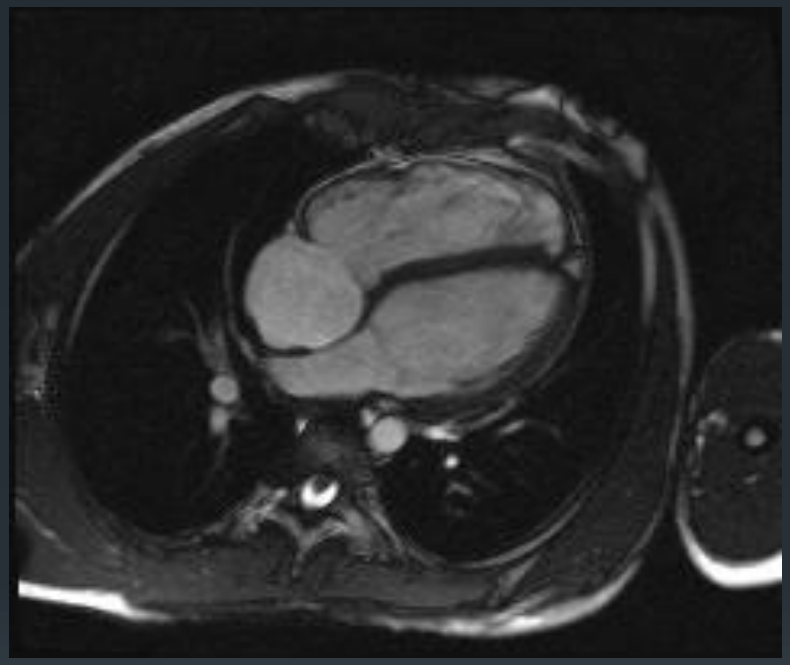

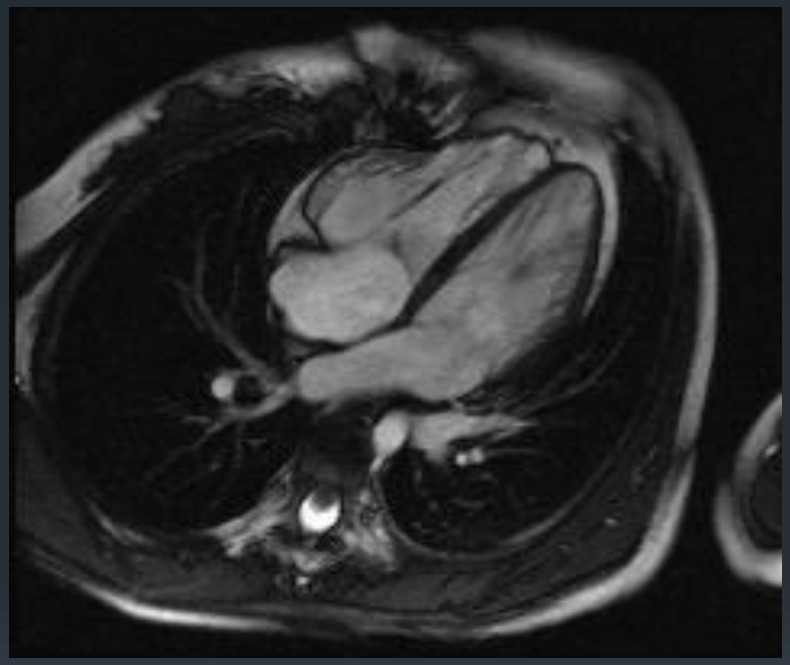

M/ 16 Yr 171 cm, 64 kg

RV EDVi 168 mL/m^2 RV EF 44%
LV EDVi 76 mL/m^2

F/ 21 yr 168 cm, 47 kg

RV EDVi 97 mL/m^2 RV EF 39%
LV EDVi 68 mL/m^2

RV

3D Echo RV volume / EF

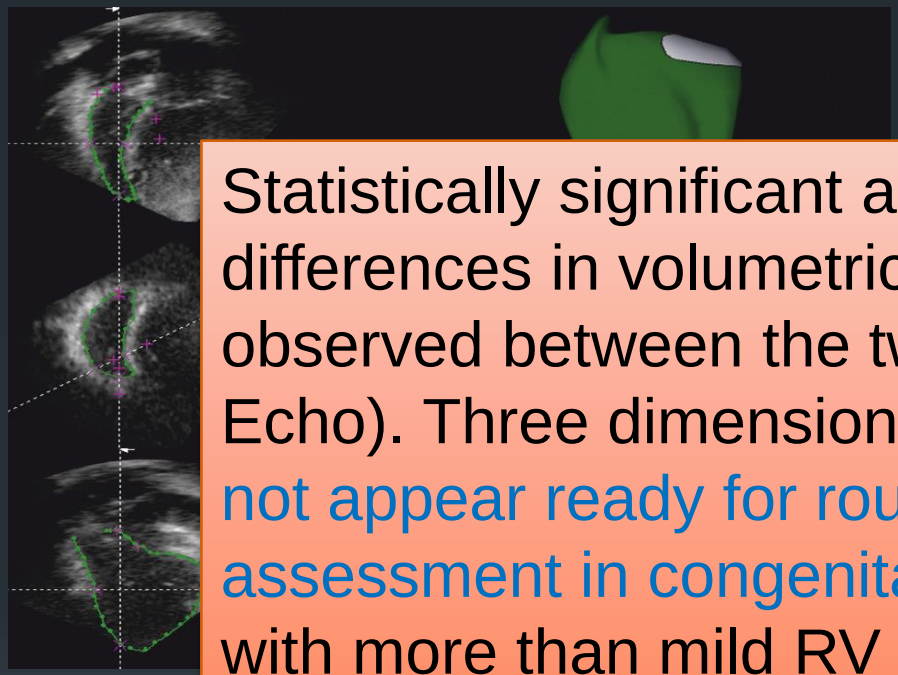

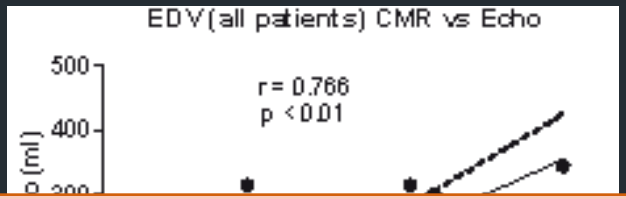

Statistically significant and clinically meaningful differences in volumetric measurements were observed between the two techniques (MRI vs. Echo). Three dimensional echocardiography does not appear ready for routine clinical use in RV assessment in congenital heart disease patients with more than mild RV dilatation at the current time.

	CMR EDV (ml)	3D Echo EDV (ml)	CMR ESV (ml)	3D Echo ESV (ml)	CMR EF%	3D Echo EF%
All patients	236 (107)	169 (78)	150 (88)	98 (60)	39 (10)	44 (11)
Tetralogy/TGA	270 (106)	190 (81)	178 (88)	114 (63)	36 (08)	42 (10)
Coarctation	148 (35)	114 (31)	79 (30)	58 (28)	48 (10)	52 (12)

Journal of Cardiovascular Magnetic Resonance 2011, 13:78

3D Echo in TOF

- The mean RV ejection fractions were 42 ± 8% on 3D ultrasound and 44 ± 7% on MRI (r = 0.89, P < .0001). The mean end-diastolic volumes were 249 ± 66 and 274 ± 82 mL and the mean end-systolic volumes 147 ± 50 and 159 ± 60 mL on 3D ultrasound and MRI, respectively.

  JASE 2010 Feb;23(2):127-33.

- Three-dimensional echocardiography underestimated ESV and EDV (P < 0.001) but agreement between 3DE and MRI was excellent (ICC = 0.88 and 0.87, respectively). Ejection fraction was 47.7 +/- 7.8 with 3DE and 47.9 +/- 6.7 with MRI, agreement between both methods was good (ICC = 0.72).

  Eur J Echocardiogr. 2009 Aug;10(6):784-92

- However, the accuracy of 3DE echo diminishes with larger RV volumes, in part due to current difficulty to include the entire RV in the imaged sector.

RV volume - indexed RV end-diastolic area (RVEDAi)

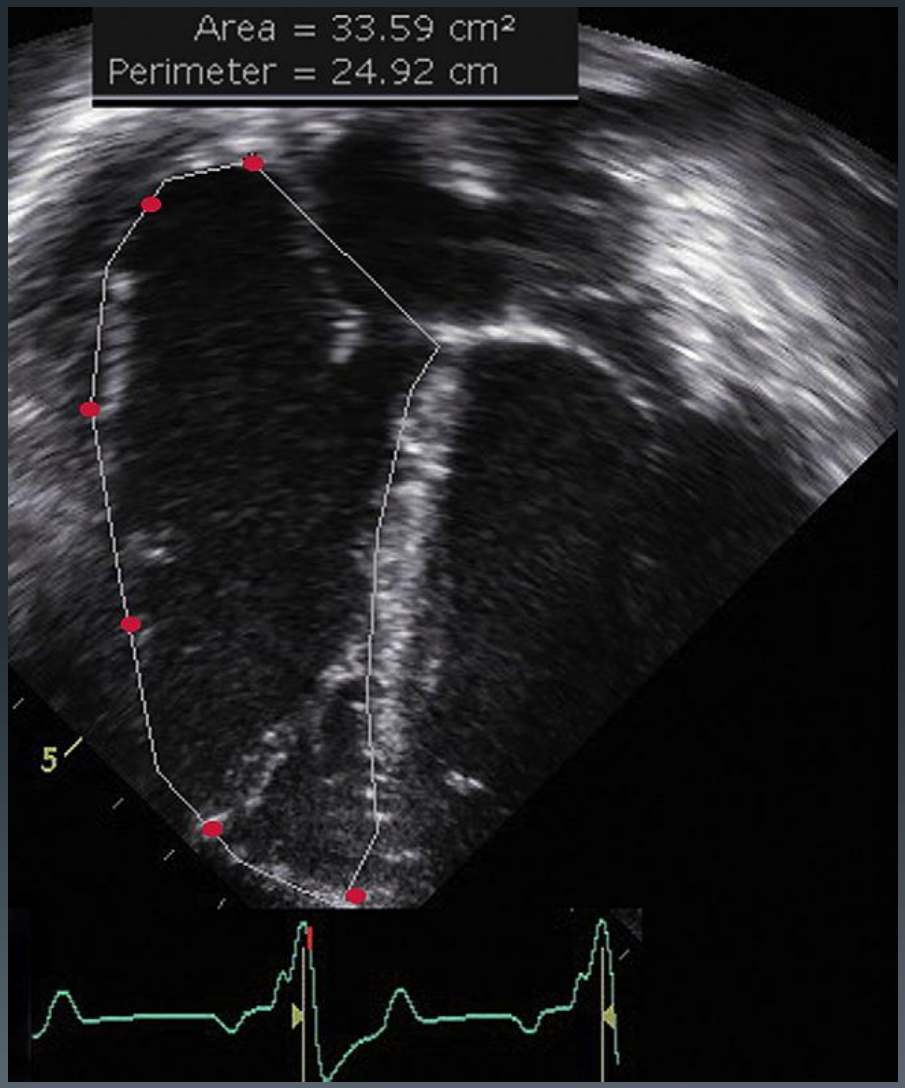

RVEDAi < 20 cm^2/m^2 had 100% specificity to predict indexed RV volume ≤170 mL/m^2

JASE 2012;25:518-23

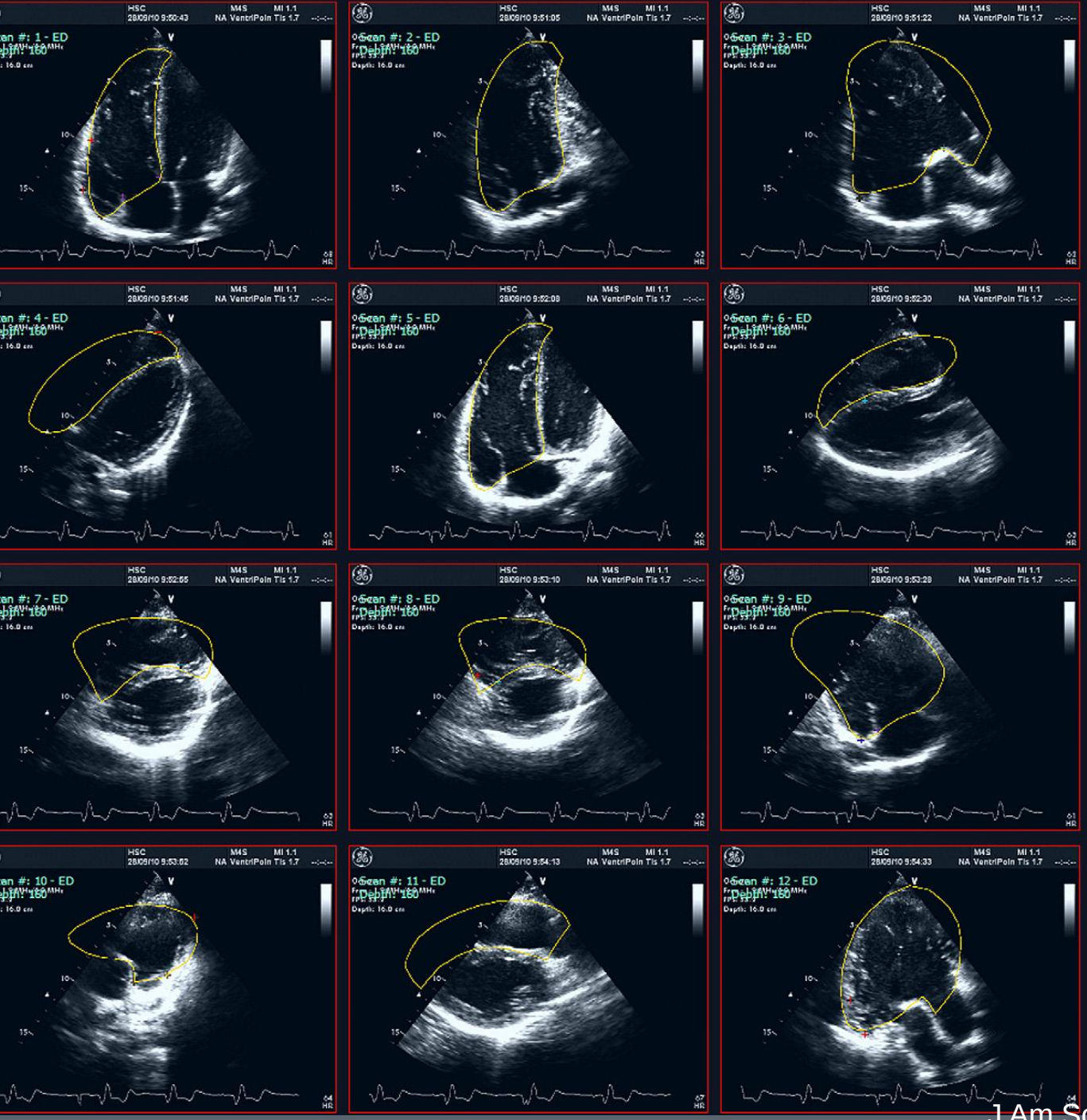

Three-dimensional (3D) knowledge-based reconstruction derived from two-dimensional echocardiographic imaging with magnetic tracking

J Am Soc Echocardiogr 2011;24:1191-8

2D Echo - based 3D reconstruction

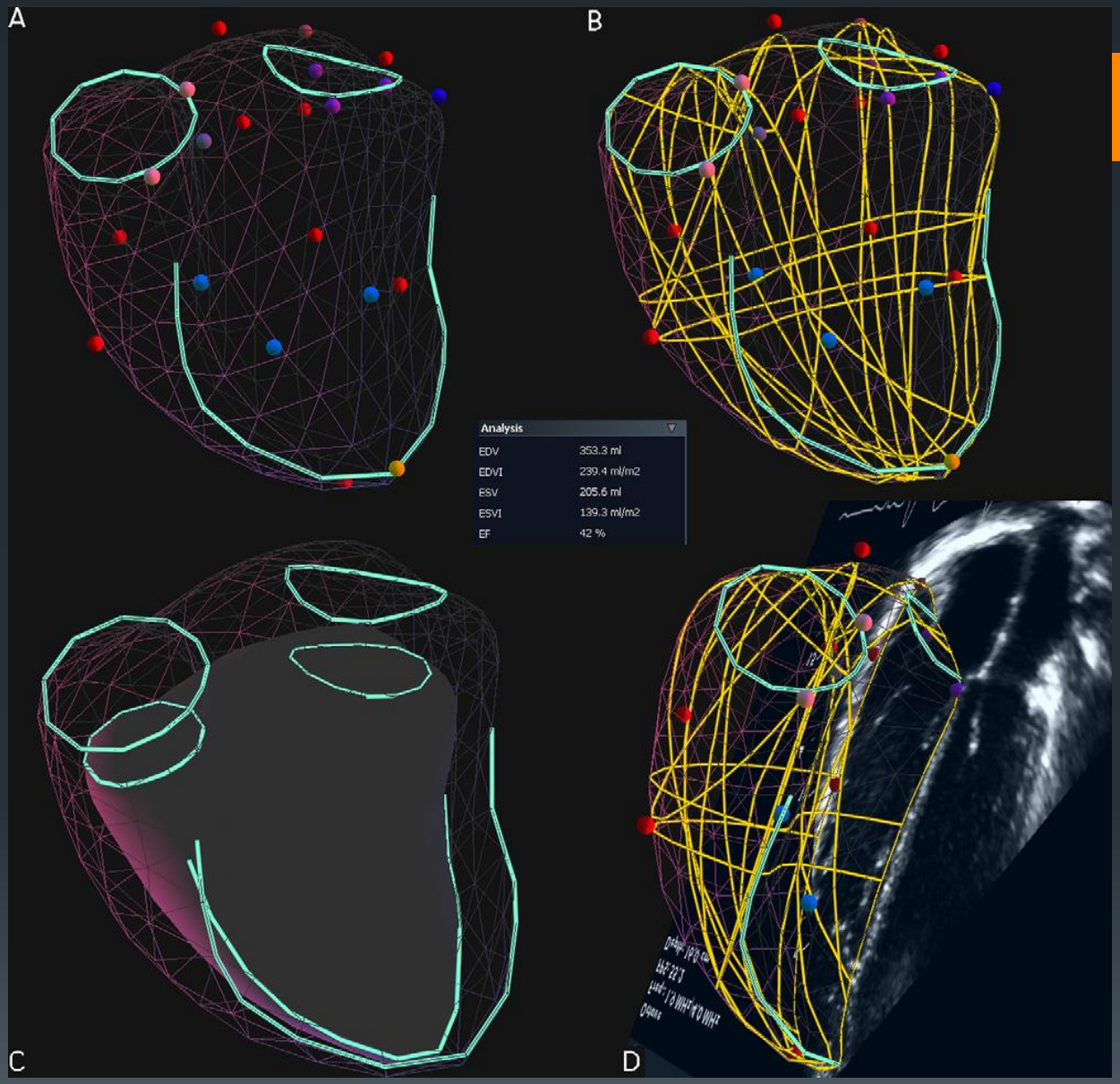

J Am Soc Echocardiogr 2011;24:1191-8

RV function

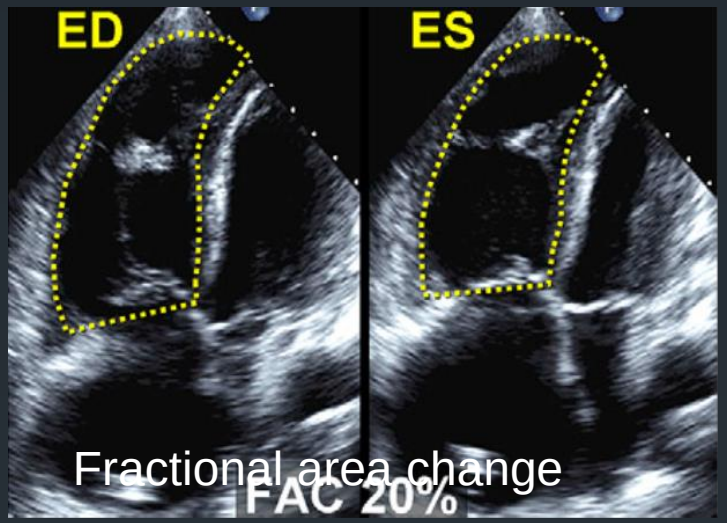

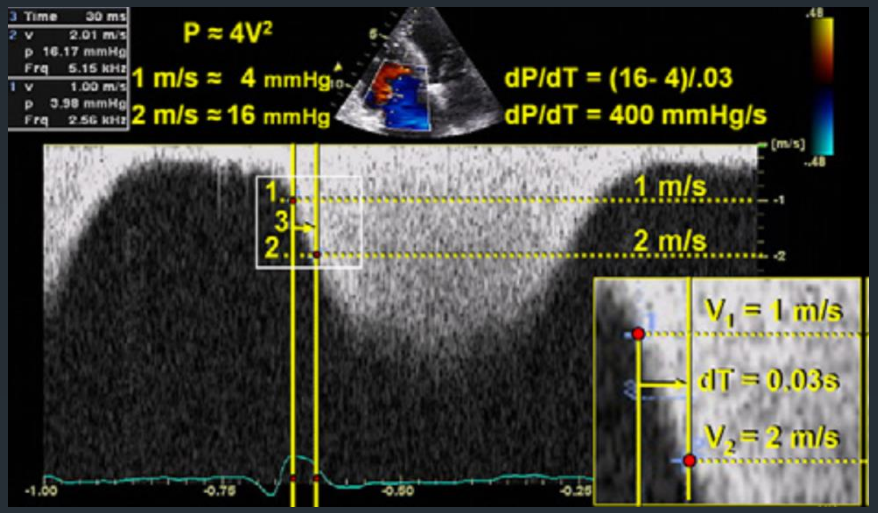

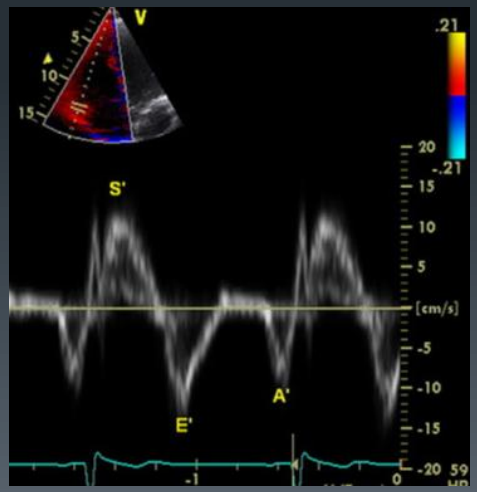

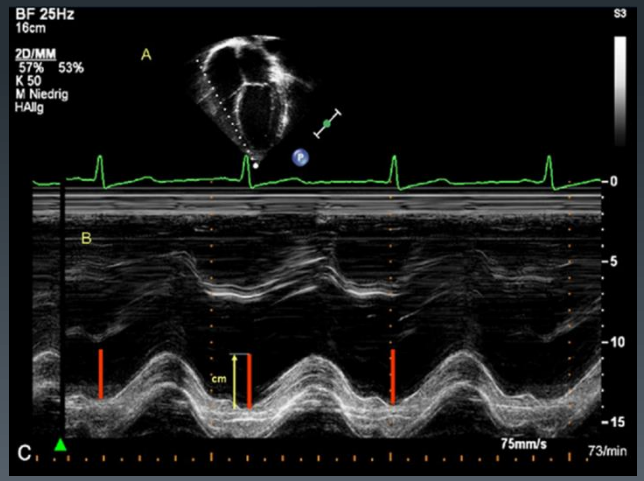

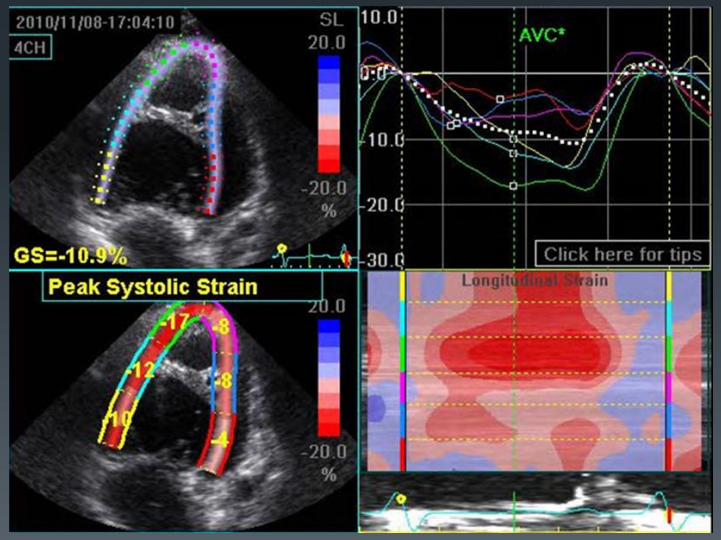

J Am Soc Echocardiogr 2010;23:685-713

3) Diastolic pressure difference between the main pulmonary artery (MPA) and the RV

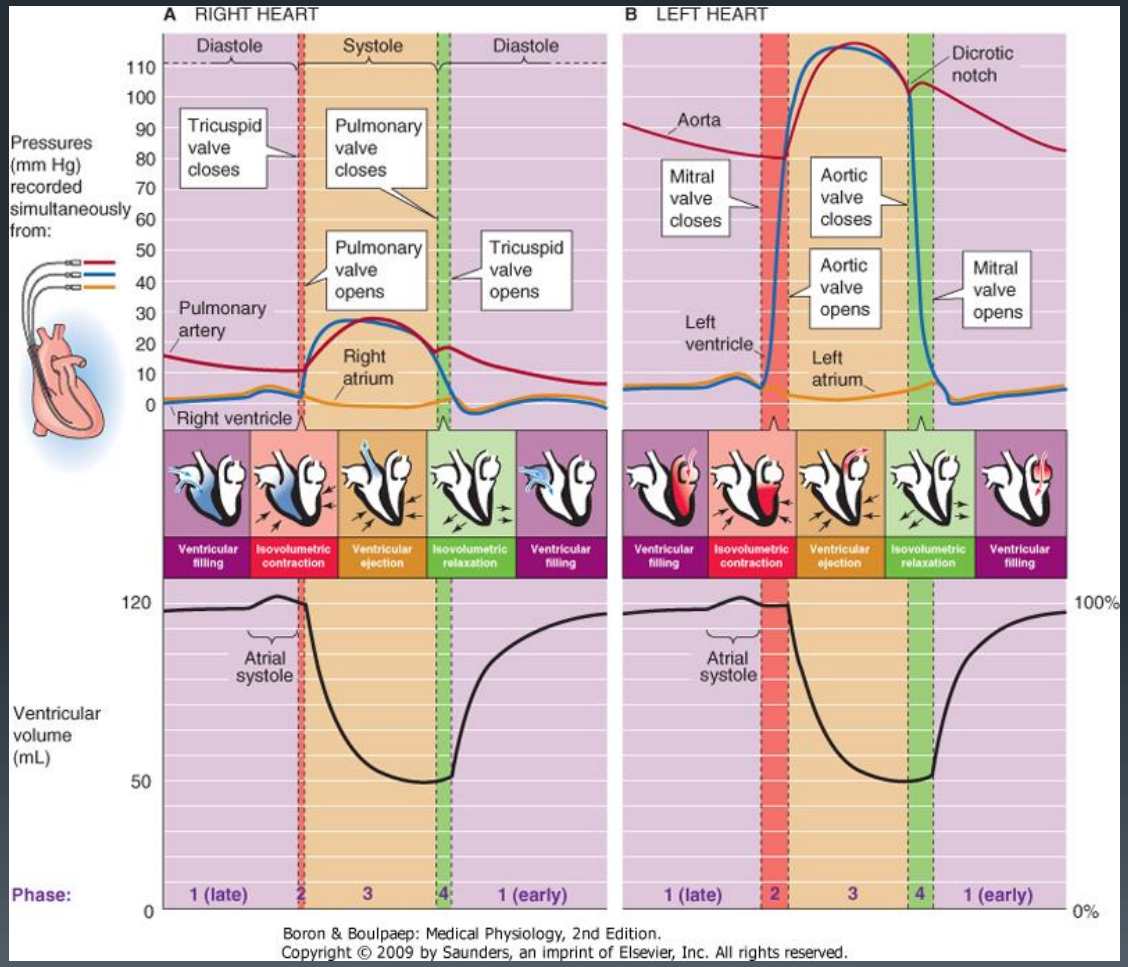

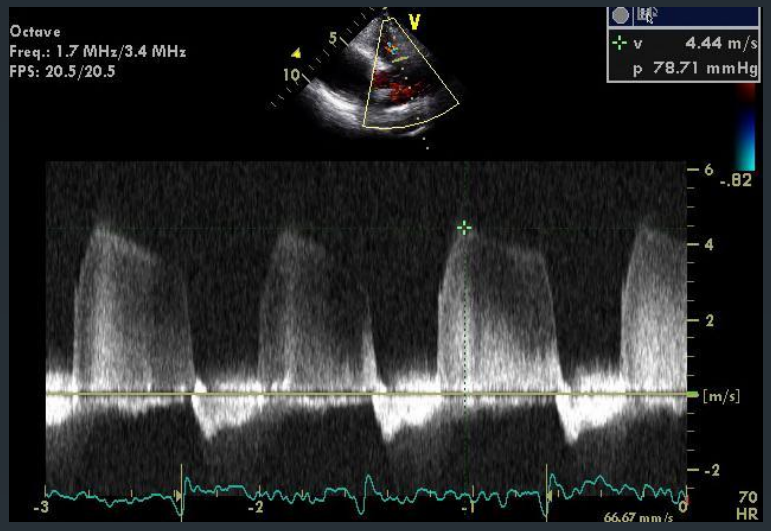

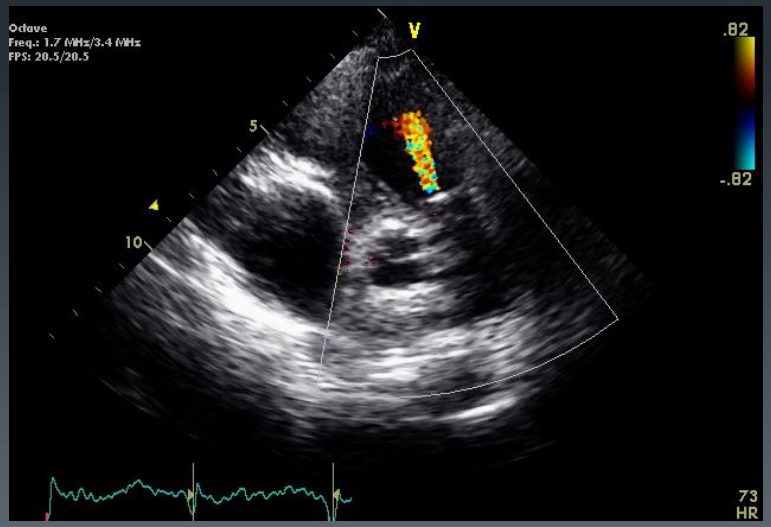

4) Capacitance of the pulmonary arteries

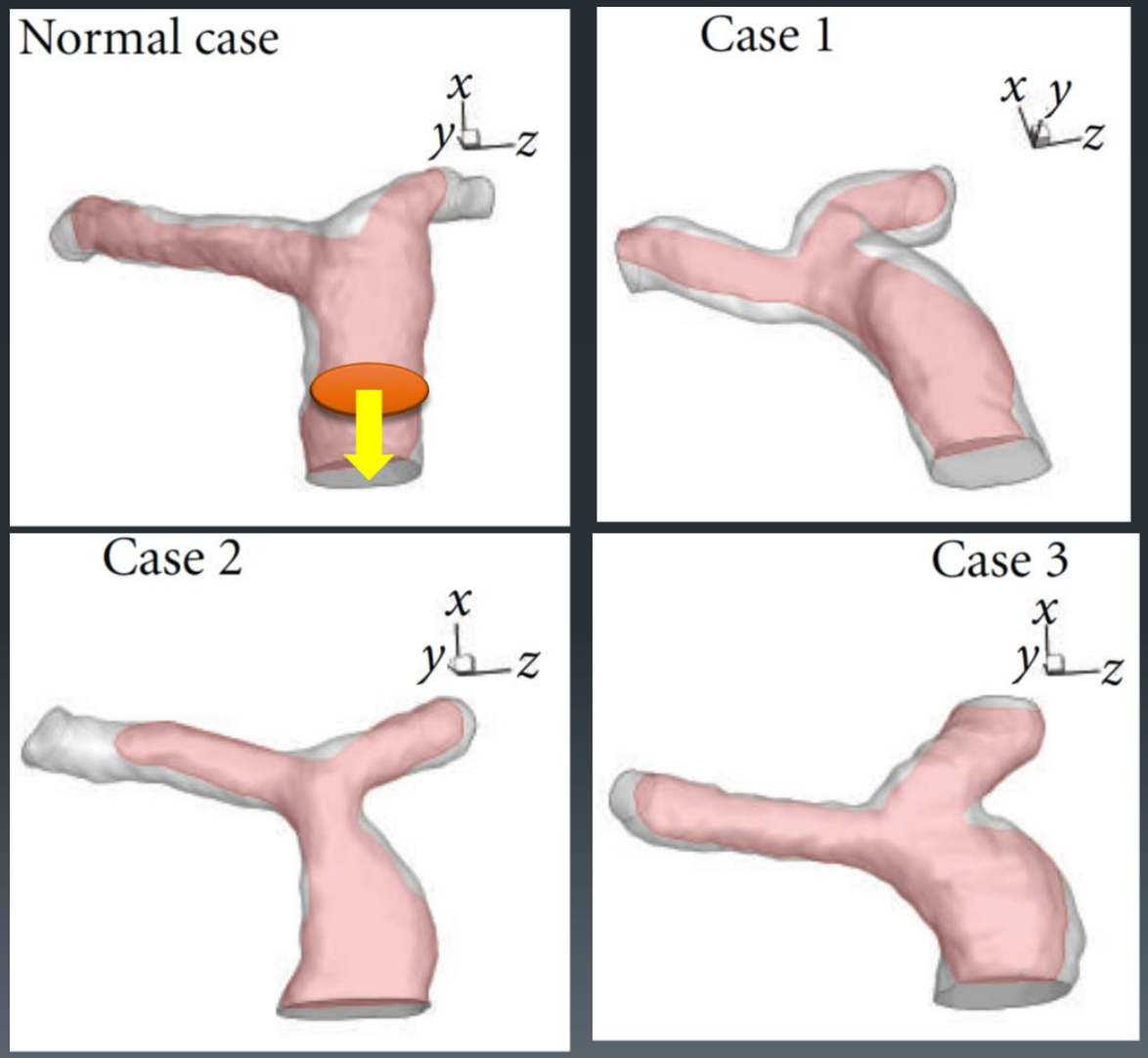

Comput Math Methods Med. Epub 2012 Dec 27

5) Duration of diastole

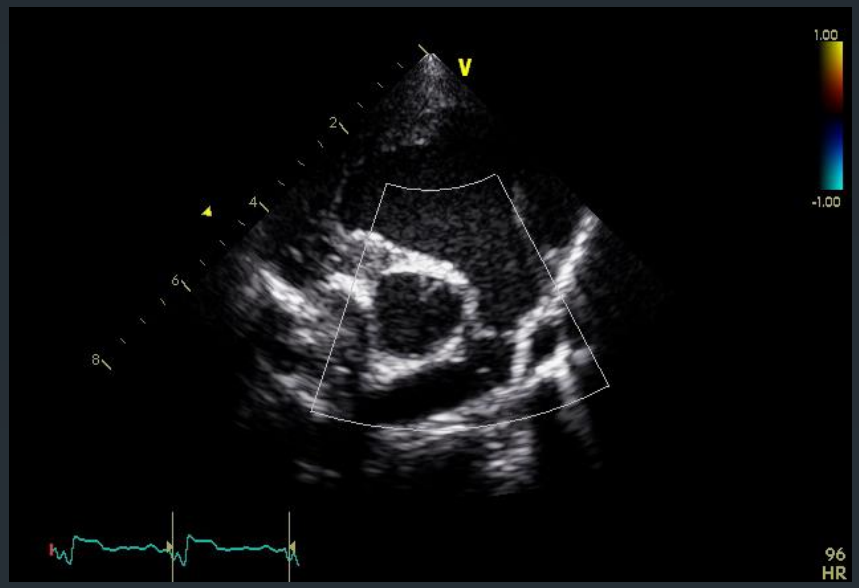

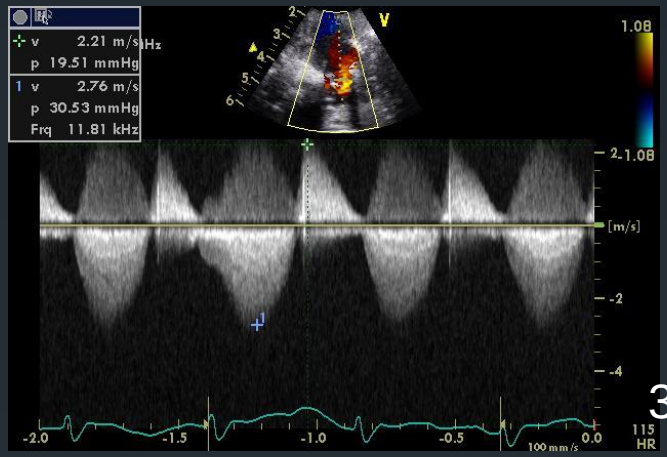

3 개월

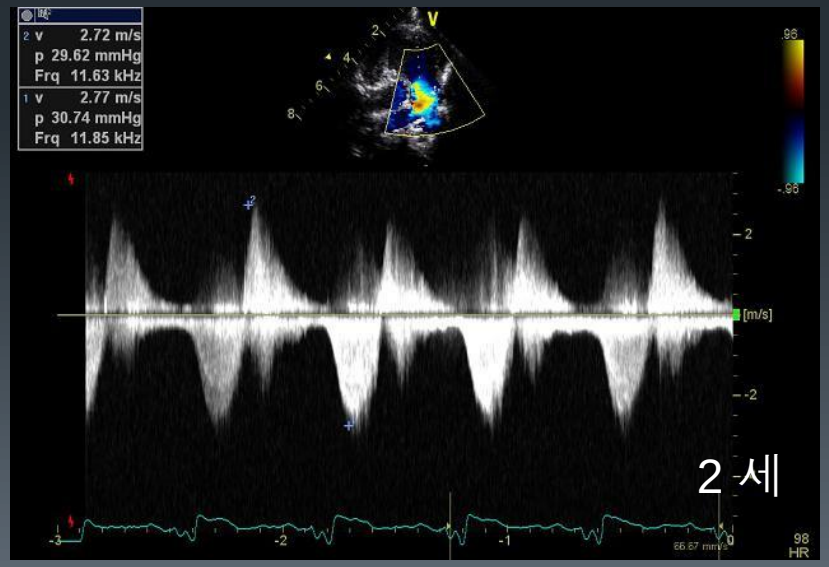

2 세

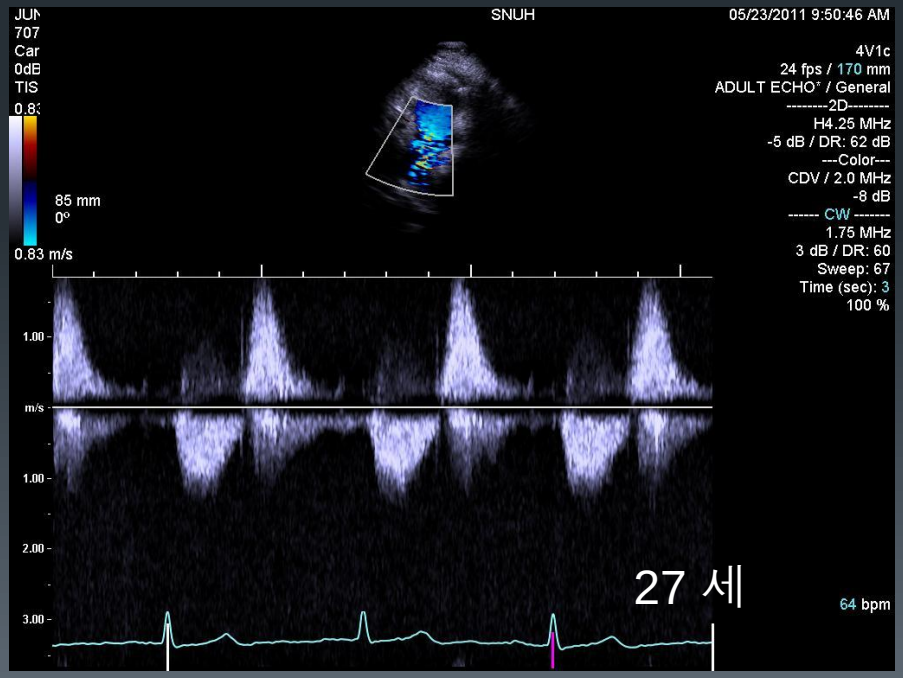

27 세

MRI - should we be measuring regurgitant fraction or regurgitant volume?

- Quantification of PR: two distinct method
  - Phase contrast (PC) analysis of flow through the MPA, retrograde flow
    - Indexed PR volume (mL/m^2) and PR fraction
  - Ventricular stroke volume (SV) differential measurements derived from steady-state free-precession cine imaging
    - Indexed PR volume (RVSV –LVSV) (mL/m^2), PR fraction (RVSV –LVSV / RVSV x 100 %)

European Heart Journal (2009) 30, 356–361

MRI - should we be measuring regurgitant fraction or regurgitant volume?

PR volume and PR fraction are not interchangable. PR volume may be a more accurate reflection of RV preload and may better represent physiologically significant PR as compared with PR fraction.

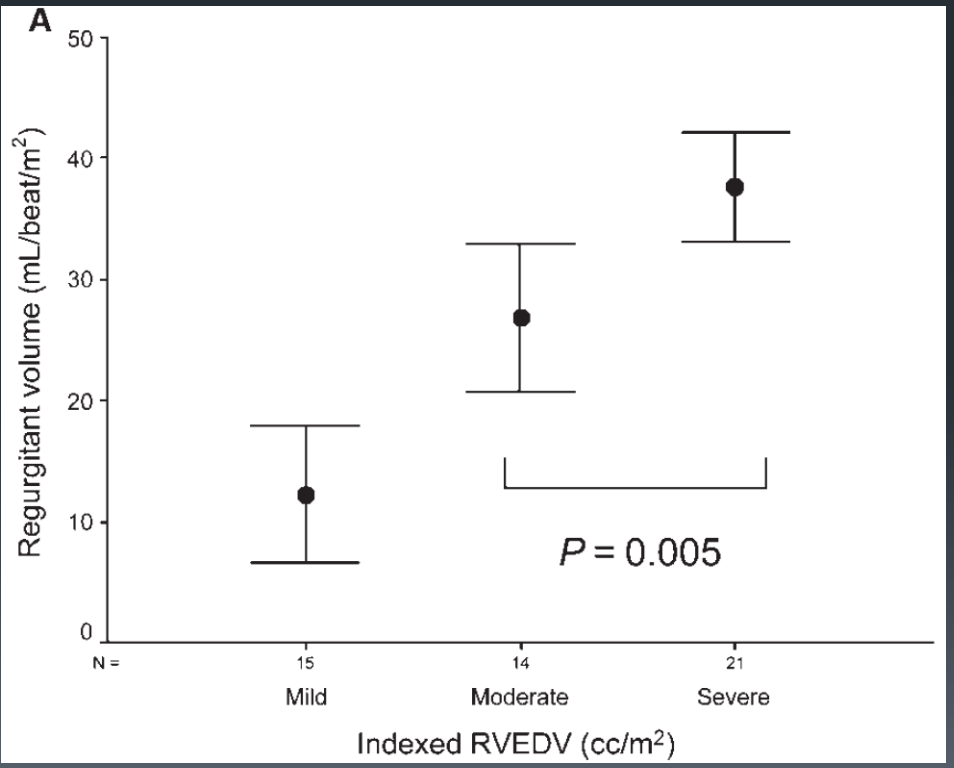

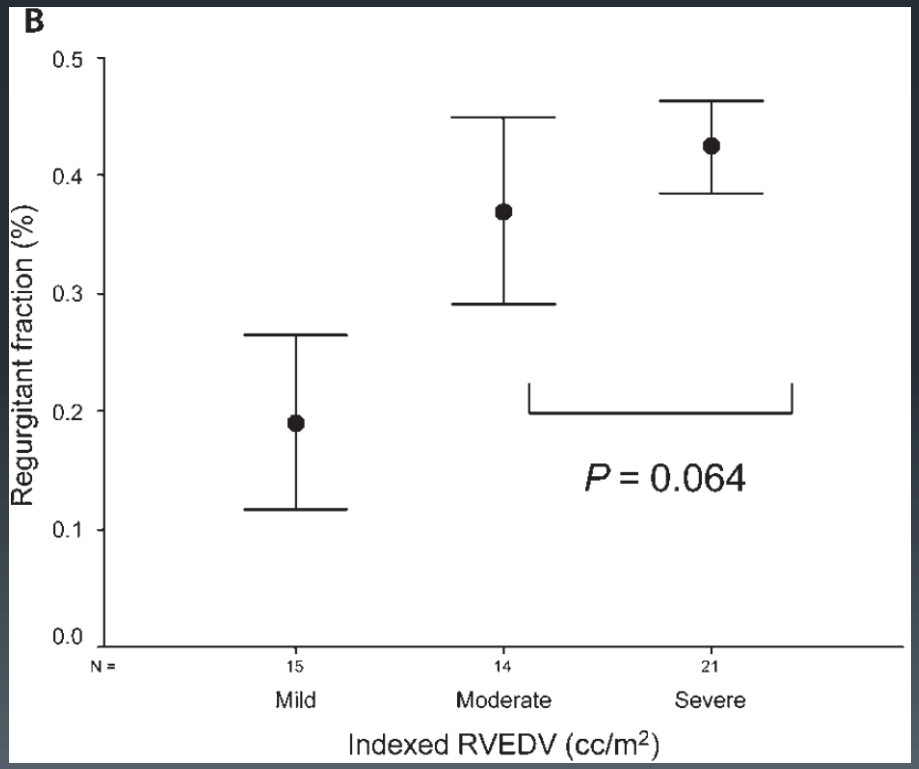

European Heart Journal (2009) 30, 356–361

Regurgitant volume?

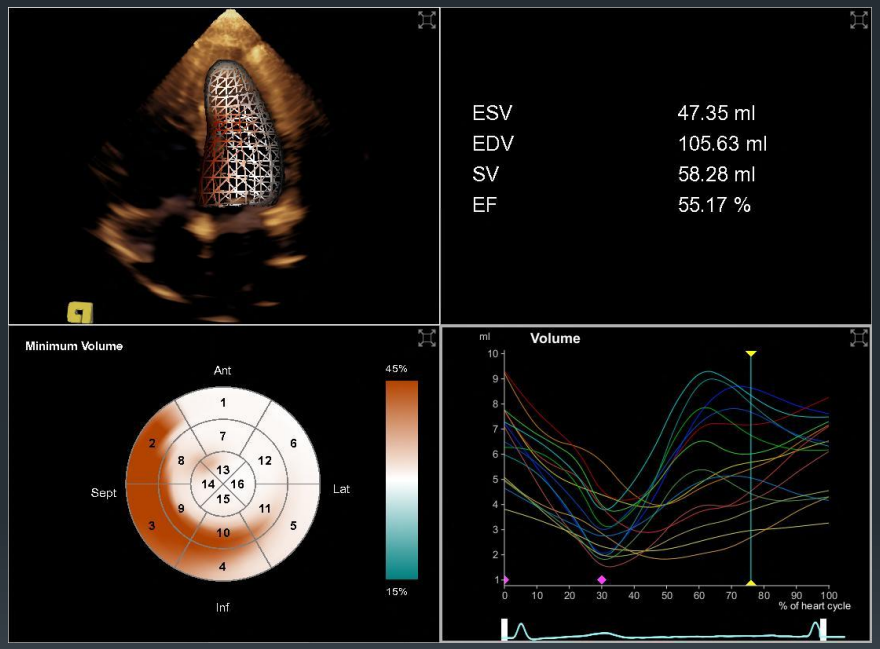

LV SV 58 mL

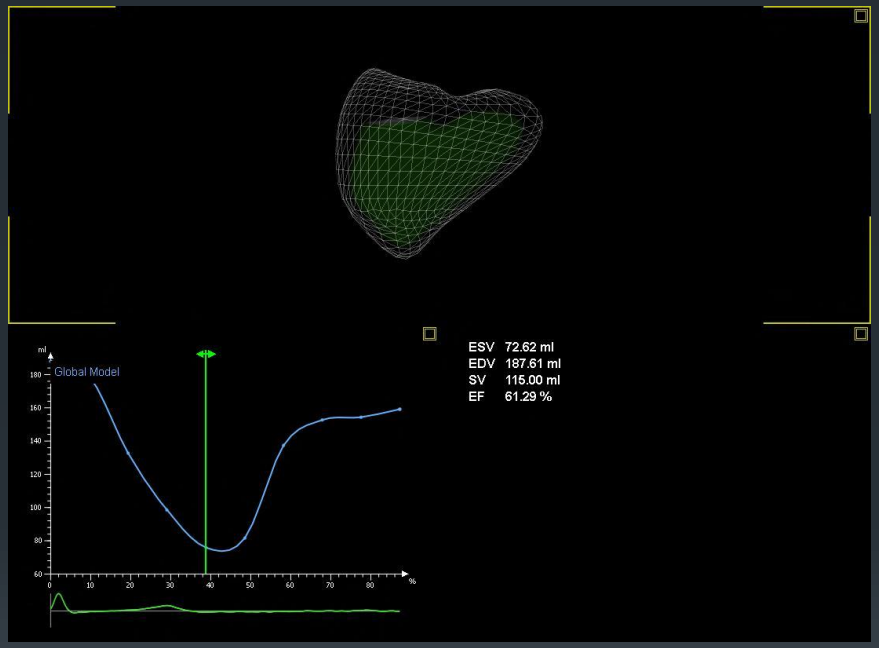

RV SV 115 mL

Regurgitant volume 115-58 mL
Regurgitant fraction (115-58)/ 115 x 100%

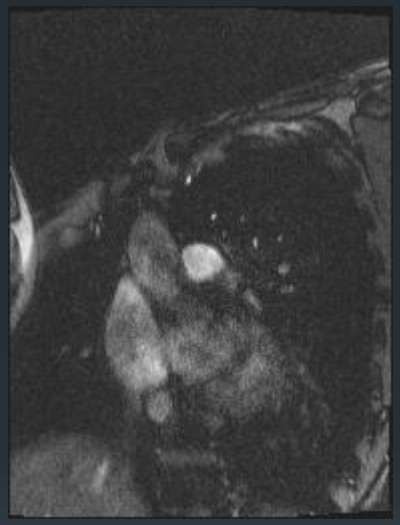

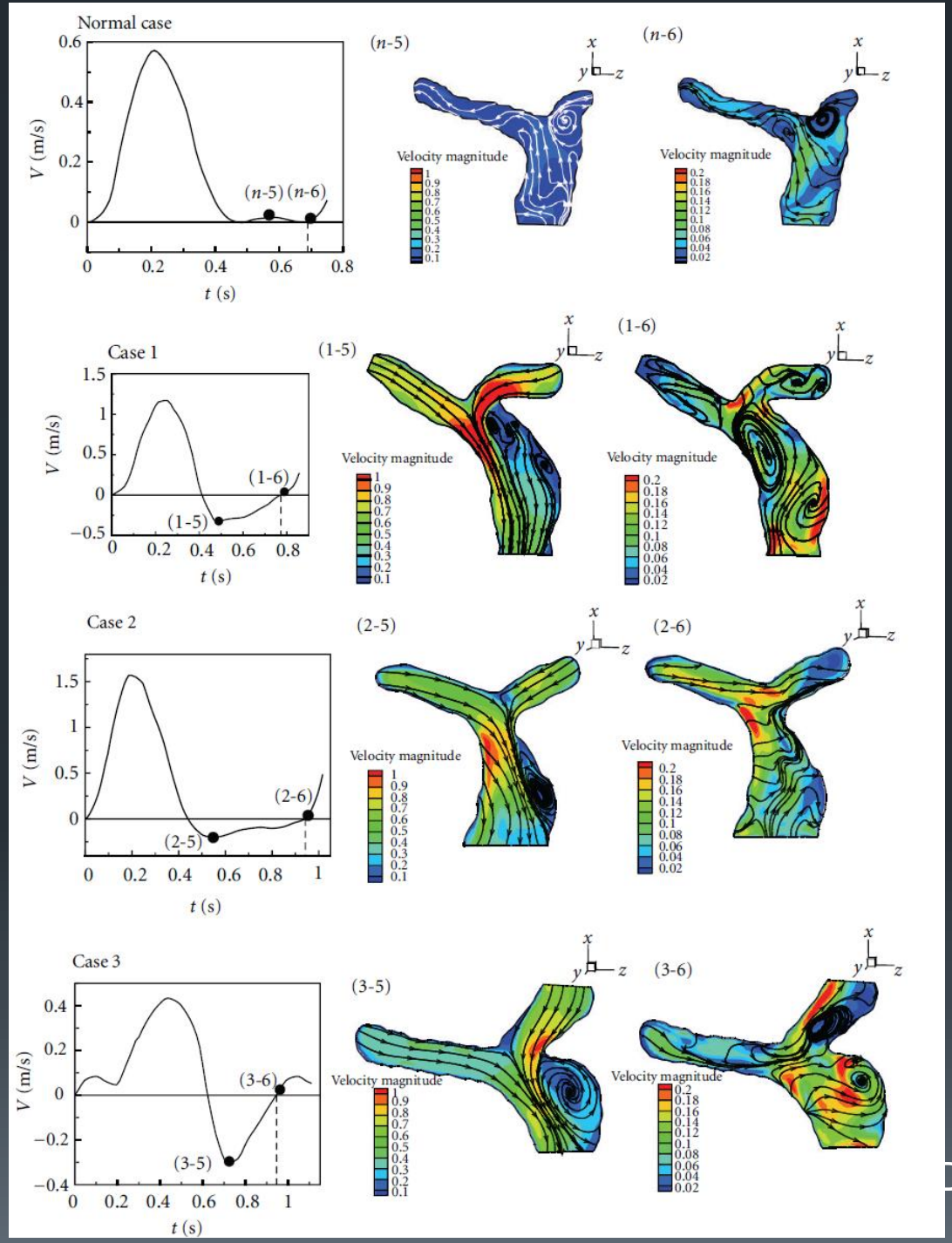

Diastolic phase

Comput Math Methods Med. Epub 2012 Dec 27

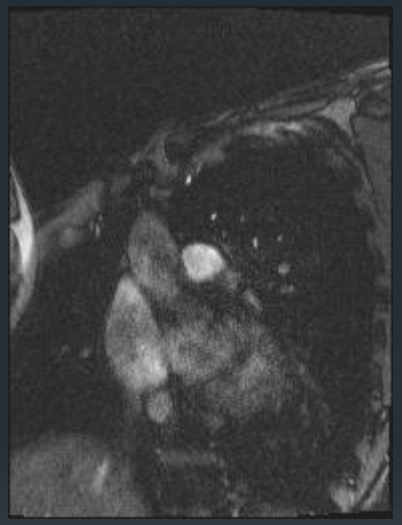

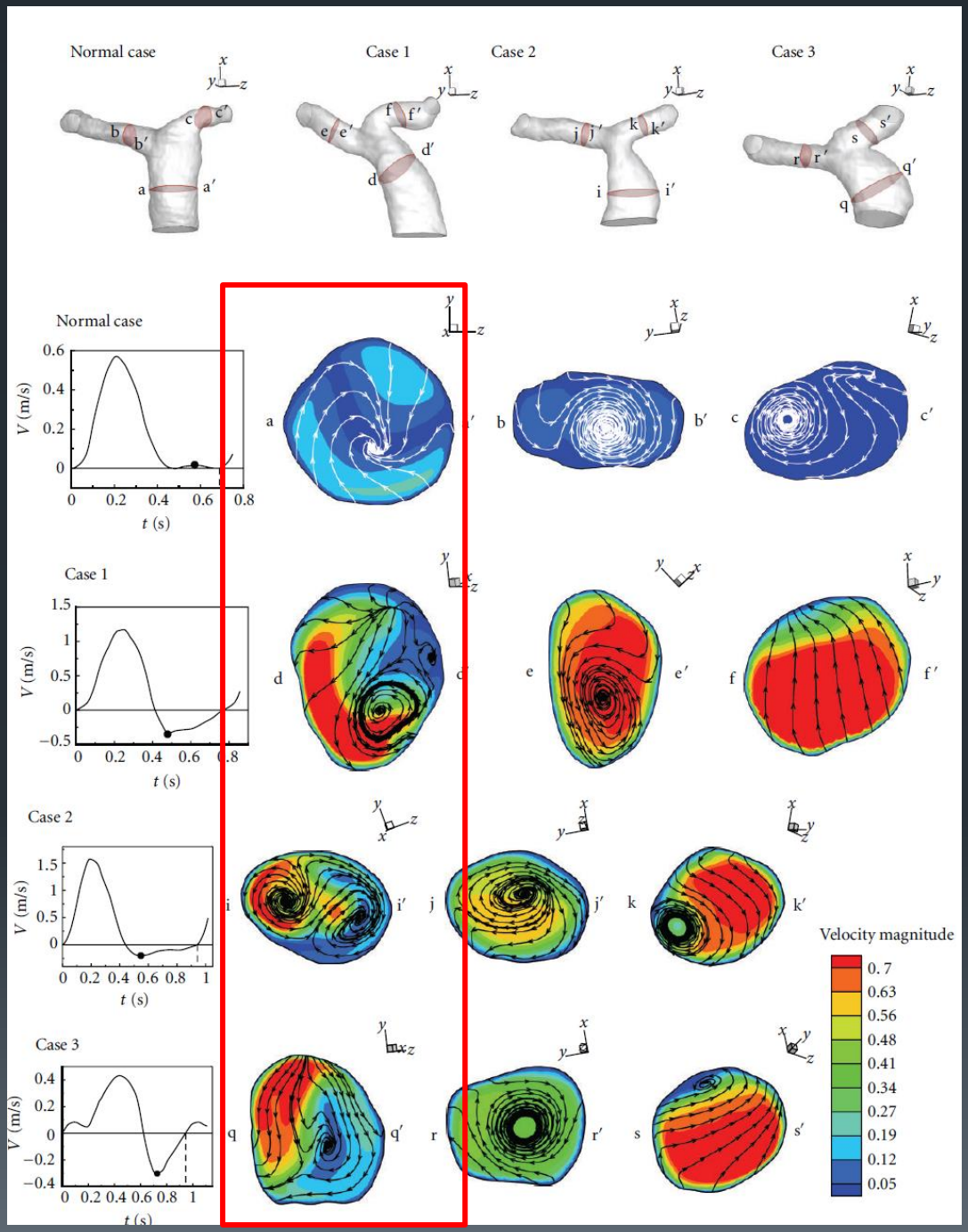

Diastolic phase cross-section

Comput Math Methods Med. Epub 2012 Dec 27

PR in RPA and LPA

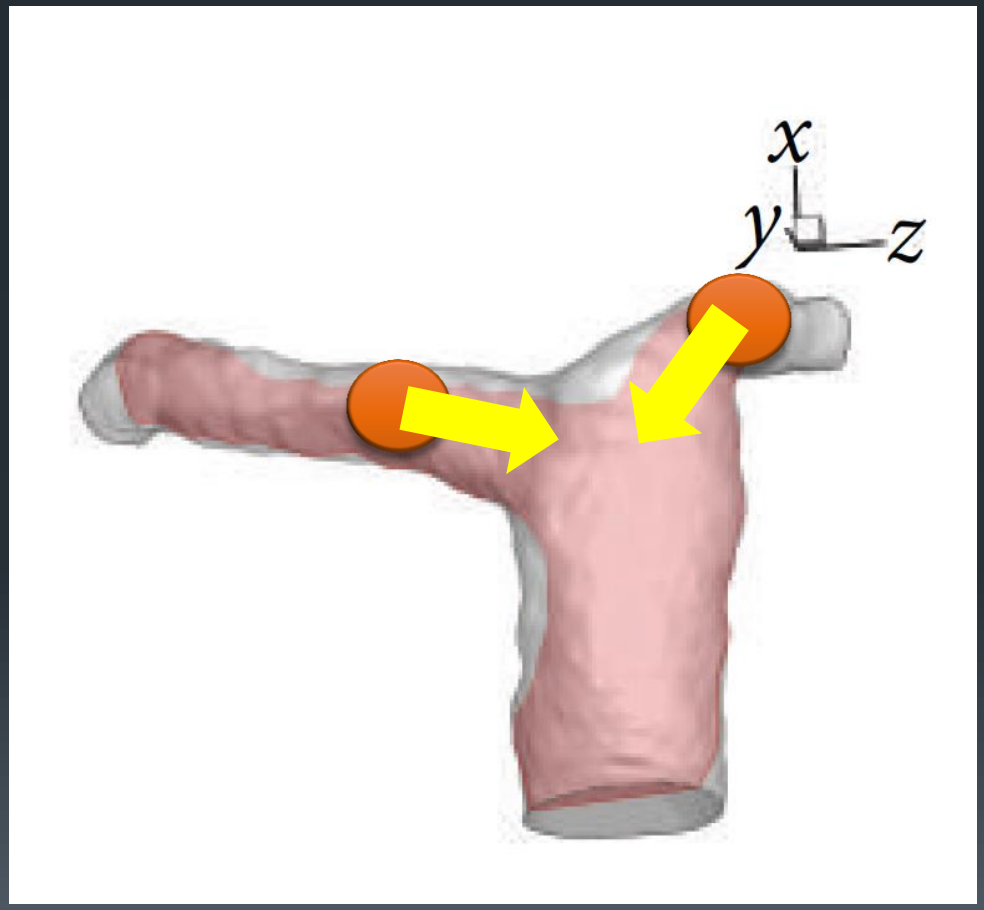

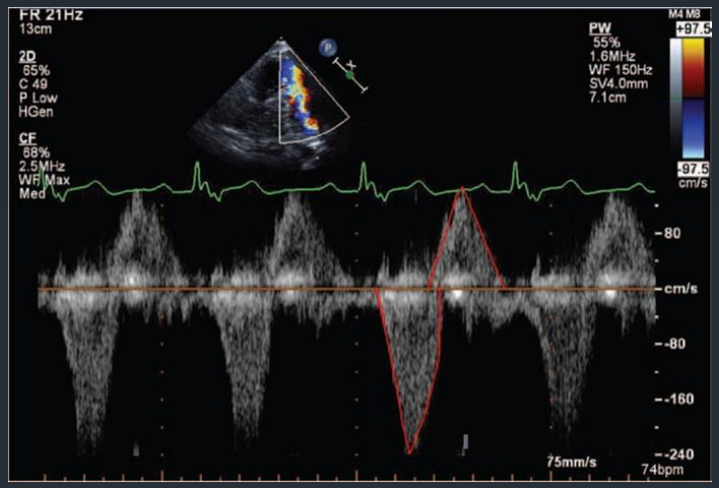

Comput Math Methods Med. Epub 2012 Dec 27

Table 2 Methods of Investigation in the Follow-Up of Patients With Repaired TOF

Methods of Investigation	Data Predictive of Outcomes	Additional, Potentially Helpful Data	Advantages	Disadvantages	Recommended Frequency in Clinically Stable Patients (mo)
History	Age at repair, length of follow-up, syncope, symptoms (NYHA class ≥II)	Associated morbidities, level of activity	Integral part of clinical evaluation	Might be difficult to discern cause of symptoms	12
Physical examination		Signs of heart failure, arrhythmia, signs of associated morbidities	Integral part of clinical evaluation	Not predictive of outcome	12
Chest radiogram	Heart size	Lung disease, detection of skeletal anomalies	Inexpensive	Does not assess size of individual cardiac chambers	Every several years
ECG	QRS duration	Conduction abnormalities; arrhythmias	Inexpensive; prognostic value	Limited assessment of arrhythmias	12
Holter	Sustained VT	High-grade ectopy, conduction	Noninvasive		12–24
Exercise					
Echocard					
Cardiac M	and end-systolic volumes, RV and LV ejection fraction	regurgitation, RVOT aneurysm, myocardial fibrosis, pulmonary artery anatomy, associated anomalies	value	pacemaker, AICD); metallic artifacts mainly from stainless steel coils; claustrophobia	
CT	Same as CMR	Pulmonary artery anatomy, associated anomalies	Noninvasive; provides an alternative when CMR is contraindicated or limited by artifacts	Exposure to ionizing radiation, relatively low temporal resolution	Only when the information cannot be obtained by CMR
Nuclear ventriculography		Biventricular function	Noninvasive	Limited accuracy for assessment of the RV; ionizing radiation exposure	Only when the information is not available by other tests
Electrophysiologic testing	Positive programmed ventricular stimulation	Arrhythmia mapping and characterization	Prognostic value; potential intervention	Invasive	When clinically indicated
Cardiac catheterization		Hemodynamic data, coronary artery assessment	Hemodynamic data; potential intervention	Invasive; ionizing radiation exposure	When clinically indicated

Echocardiogram (24 m)
Limited by poor acoustic windows;
Only qualitative assessment of RV size and function and valve regurgitation

RV FAC (factional area change)

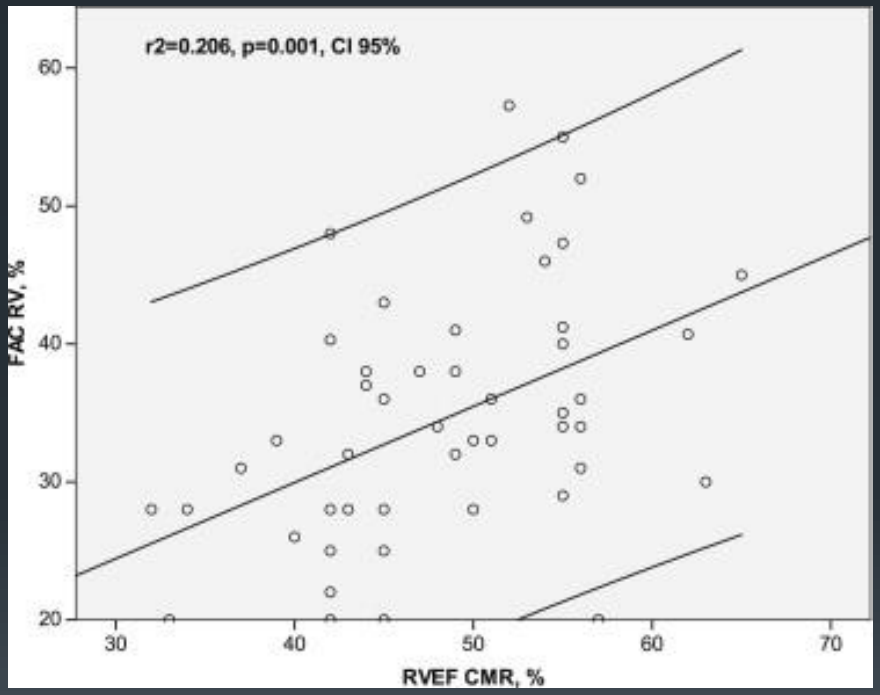

Am J Cardiol. 2013 Mar 15;111(6):908-13.

Blood flow in pulmonary arteries

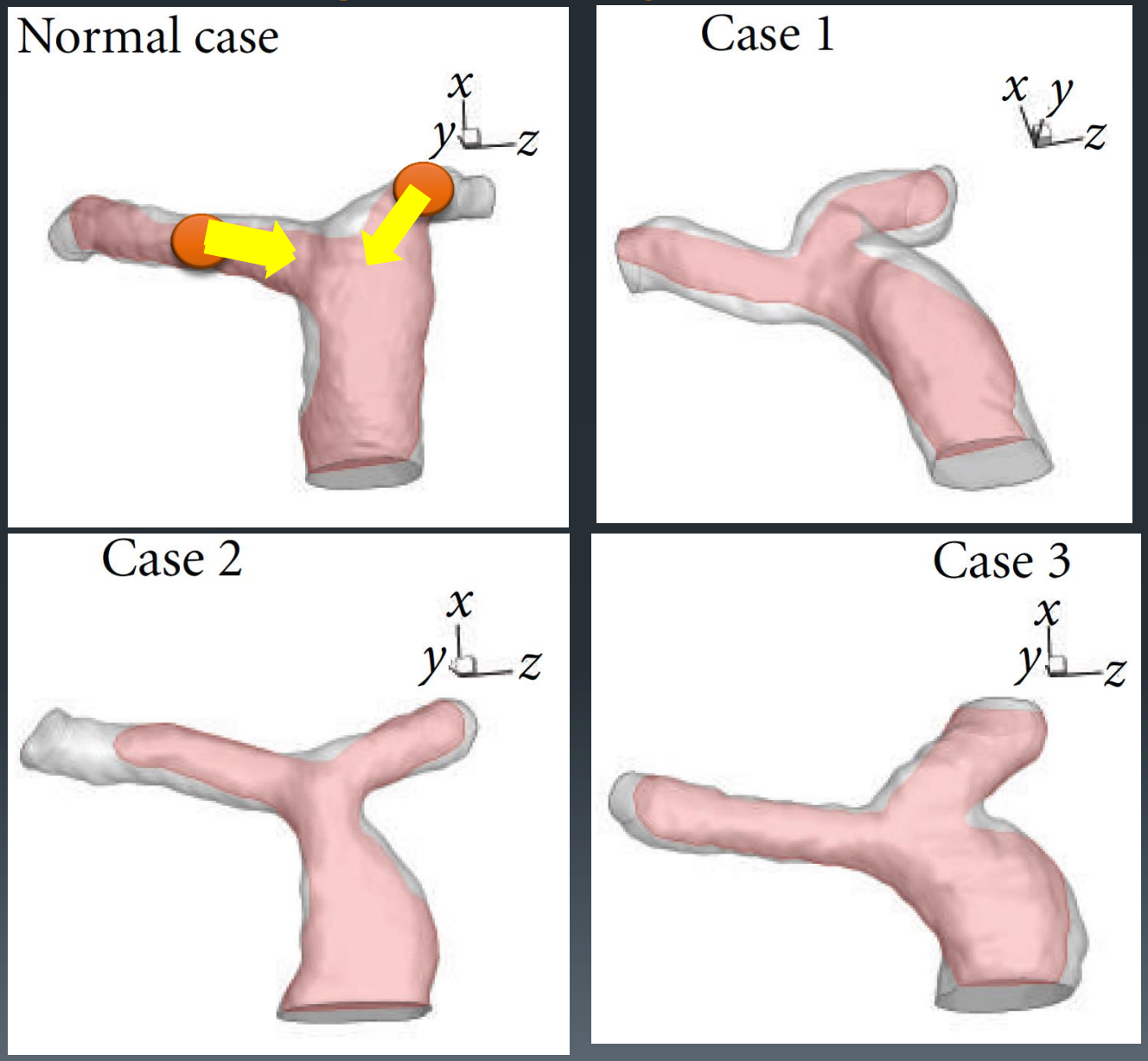

Comput Math Methods Med. Epub 2012 Dec 27

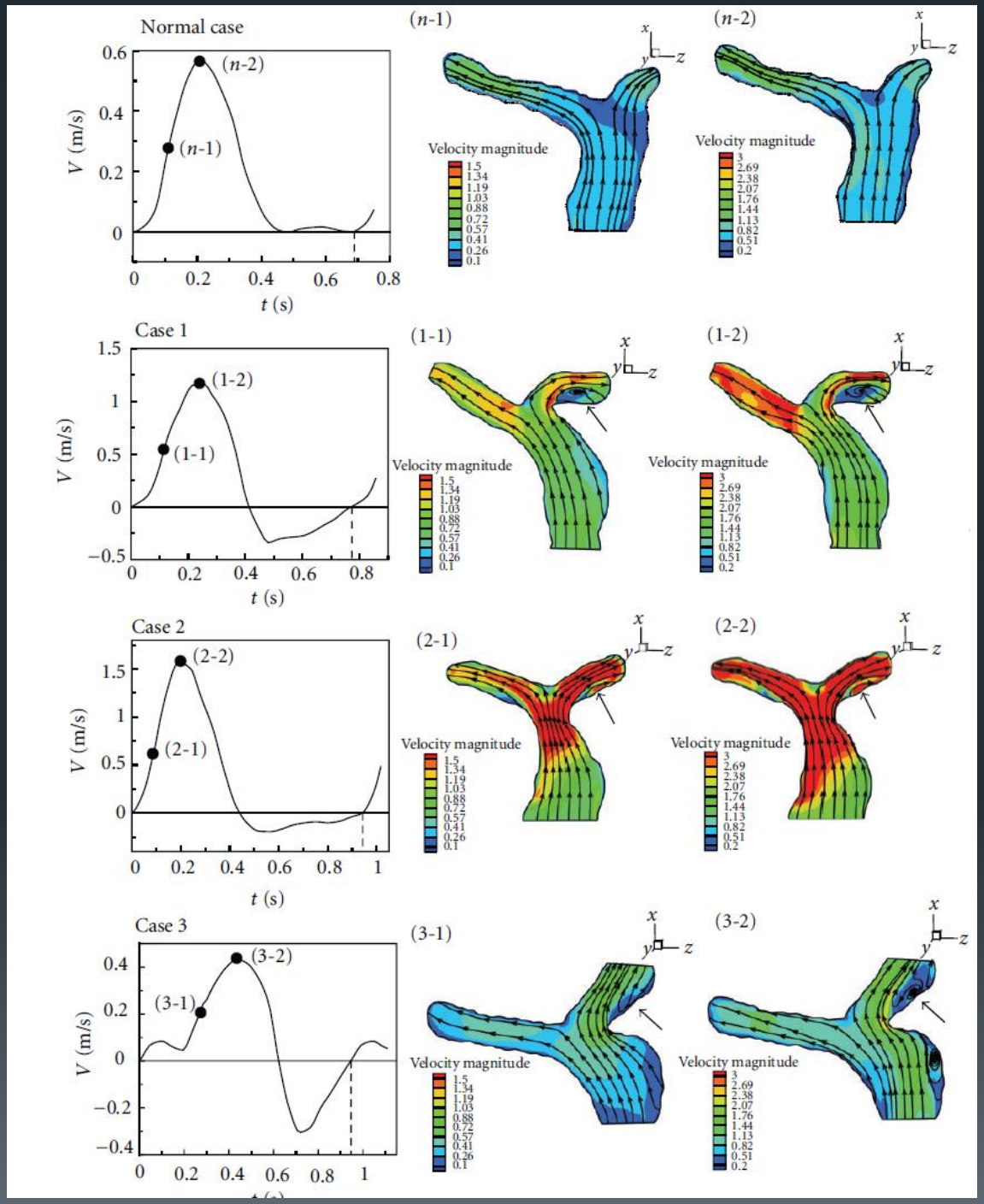

Systolic phase

Comput Math Methods
Med. Epub 2012 Dec 27

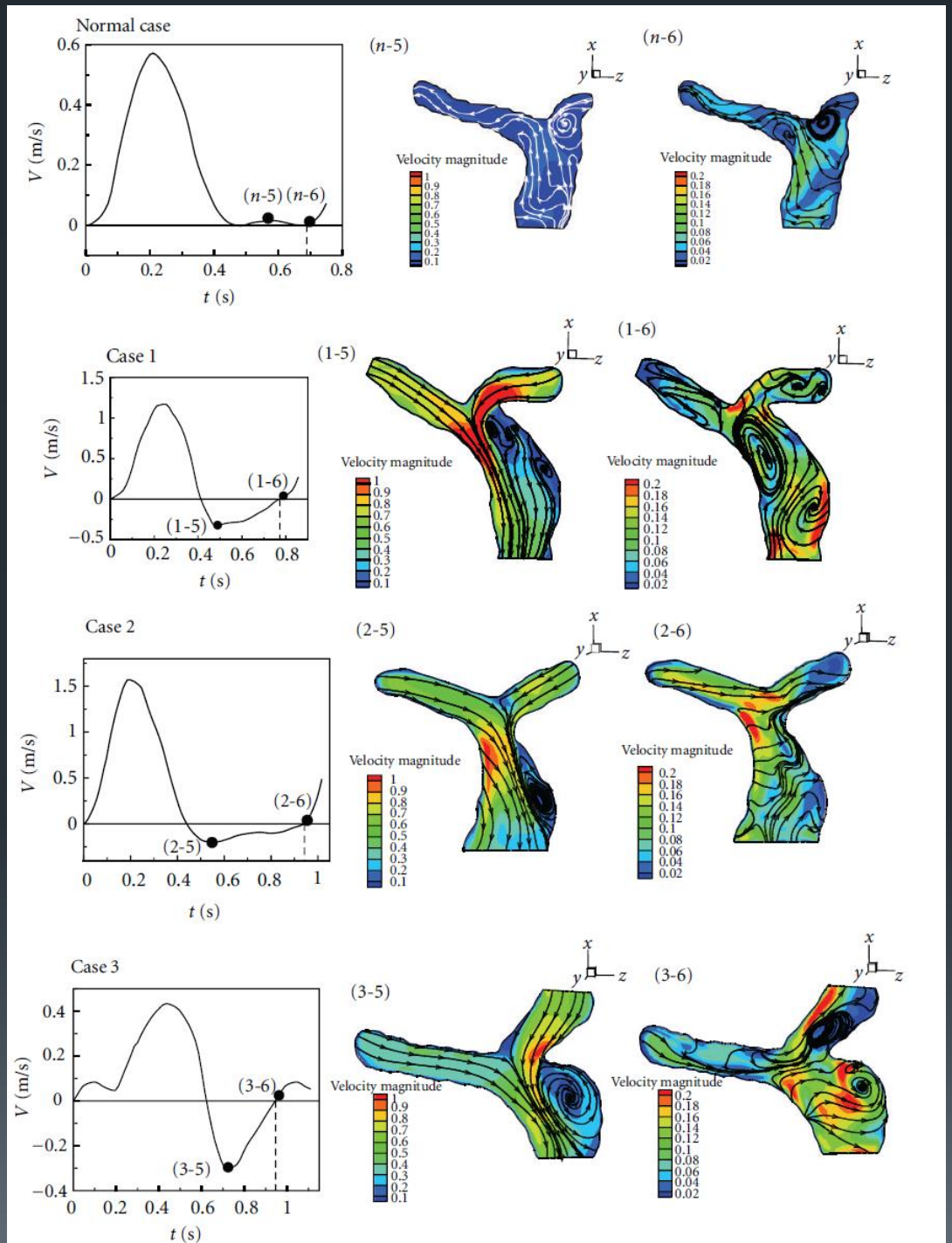

Diastolic phase

Comput Math Methods Med. Epub 2012 Dec 27


그녀를
믿지
마세요
Original Sound Track

EchoCG

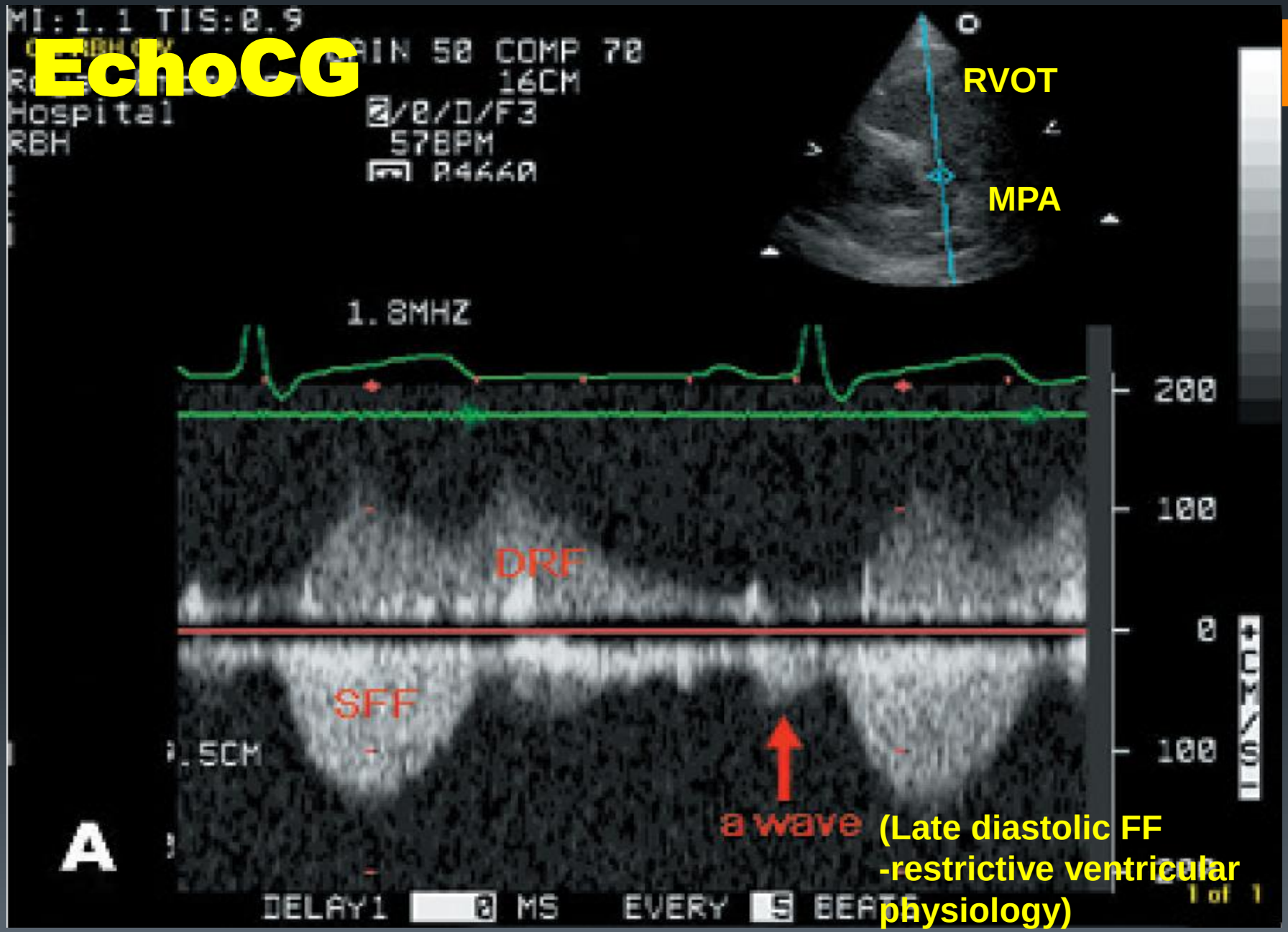

(Late diastolic FF -restrictive ventricular physiology)

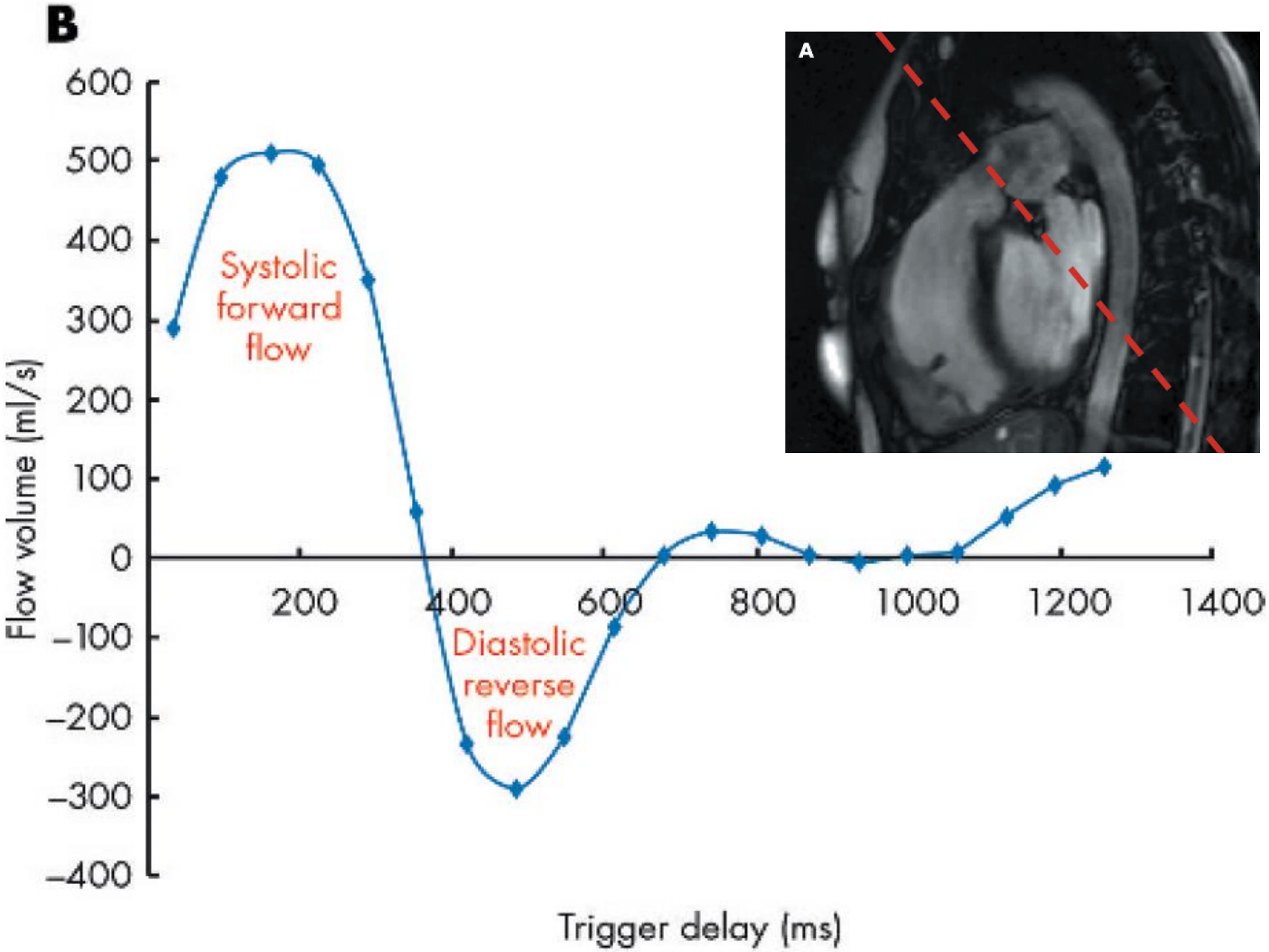
B
A
600
500
400
300
200
100
0
−100
−200
−300
−400
Flow volume (ml/s)
200
400
600
800
1000
1200
1400
Trigger delay (ms)
Systolic forward flow
Diastolic reverse flow

Doppler examination of pulmonary arterial flow in a patient with restrictive right ventricular physiology.

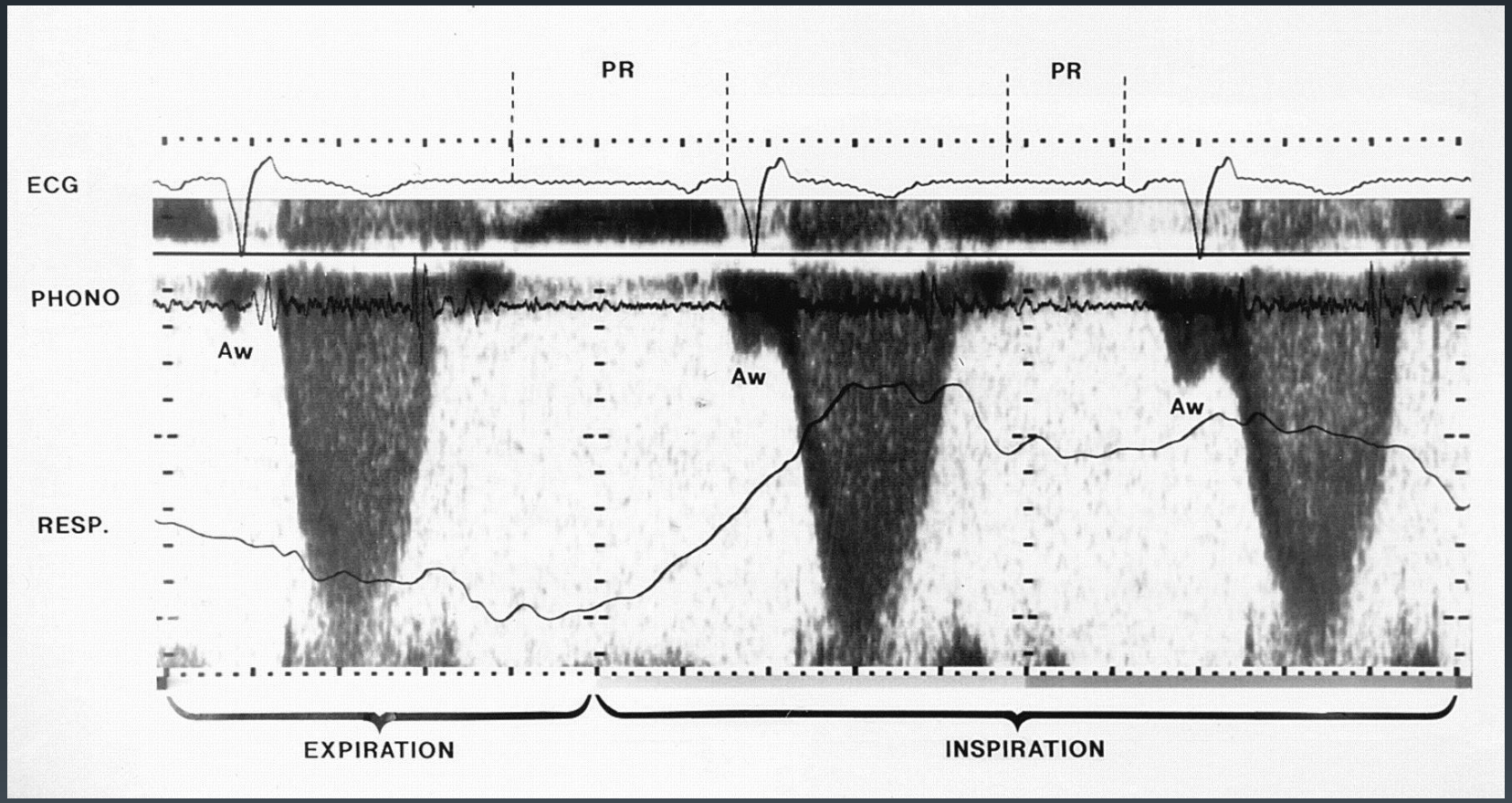

Gatzoulis M A et al. Circulation 1995;91:1775-1781

Transtricuspid Doppler inflow from a restrictive patient demonstrates early passive filling of the right ventricle and apparent filling during atrial systole

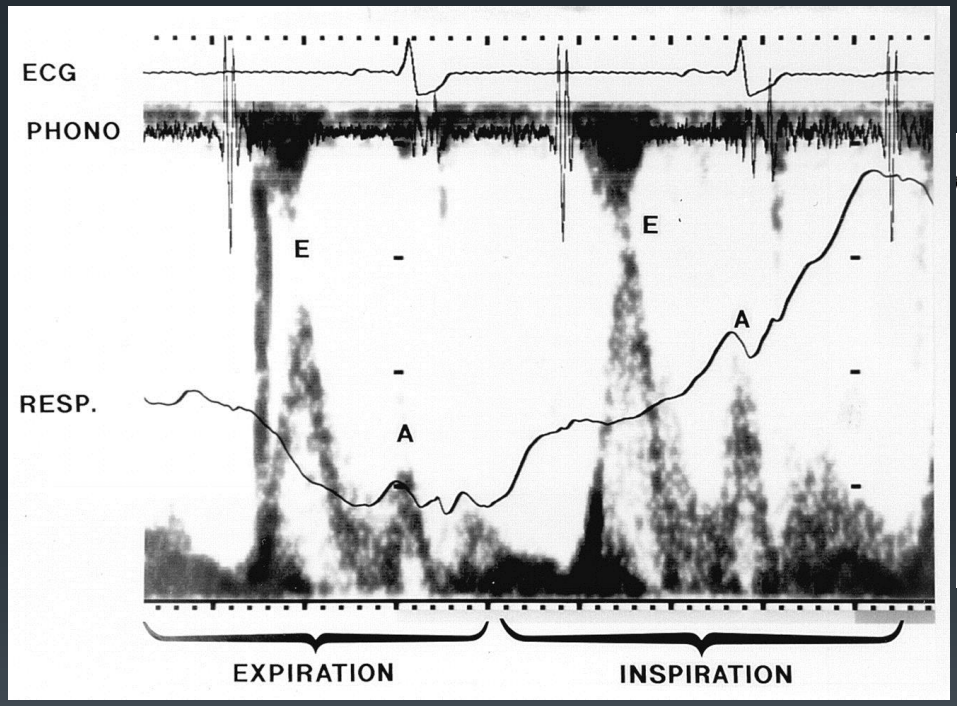

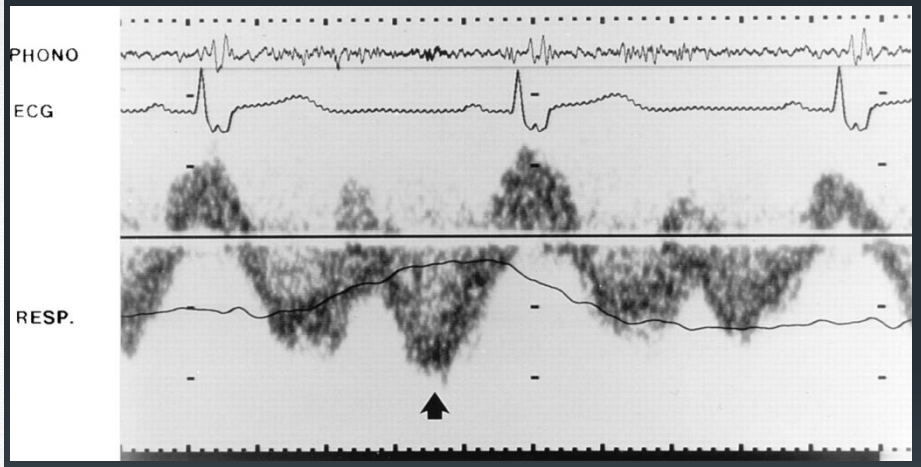

Transtricuspid Doppler inflow

SVC Doppler signal

Gatzoulis M A et al. Circulation 1995;91:1775-1781

- Immediate postop TOF: hypertrophic RV and low RV compliance, hypoplatic or low-normal PA, low capacitance of RV, relatively high HR (relative short duration of diastole) + relatively large ROA => minimized the impact of PR

RV remodeling / RV

- Chamber geometry, myofiber architecture, chamber contraction pattern, coronary artery anatomy and flow dynamic, disposition of the conduction system, and dependency on LV size and function

- Myocardium: a relatively thin compact layer + a prominent layer of trabeculations interspersed with deep recessess
- The orientation of the myofibers in the RV is more horizontal and contraction is predominantly from base-to-apex (longitudinal) with a lower degree of angular motion (twist)
- Supplied by a single coronary artery with nearly 50% of the flow occurring during diastole under normal conditions as oppose to ~90% in the LV.
- Conduction system in the RV comprises a single fascicle with a long course and a long delay in activation between the base and the distal infundibular free wall, resulting in peristalsis like motion
- Although RV function impacts LV function, the reverse is much more pronounced with 63% of RV pressure rise accounted for by LV contraction.

Geva Journal of Cardiovascular Magnetic Resonance 2011, 13:9

Indications for Pulmonary Valve Replacement

- moderate or severe pulmonary regurgitation (regurgitation fraction ≥25%)

- Asymptomatic patient with two or more of the following criteria
  - a. RV end-diastolic volume index >150 ml/m2 or Z-score >4. In patients whose body surface area falls outside published normal data: RV/LV EDV ratio >2
- b. RV ESV index >80 ml/m2
- c. RV EF <47%
- d. LV EF <55%
- e. Large RVOT aneurysm
- f. QRS duration >140 ms
- g. Sustained tachyarrhythmia related to right heart volume load
- h. Other hemodynamically significant abnormalities: RVOTO, severe branch PS, moderate TR
- ○ RVOT obstruction with RV systolic pressure
- ≥2/3 systemic
- ○ Severe branch pulmonary artery stenosis (<30%
- flow to affected lung) not amenable to transcatheter
- therapy
- ○ ≥ Moderate tricuspid regurgitation
- ○ Left-to-right shunt from residual atrial or
- ventricular septal defects with pulmonary-tosystemic
- flow ratio ≥ 1.5
- ○ Severe aortic regurgitation
- ○ Severe aortic dilatation (diameter ≥5 cm)

Restrictive RV physiology

- Pulmonary regurgitation: exercise intolerance, RV enlargement, late arrhythmias, and sudden death
- Restrictive RV physiology: antegrade pulmonary artery flow in late diastole -> seems to protect against RV dilation in pts after repair of TOF
  - Paradoxical effect of restrictive RV physiology in the early postop period and late after repair

Circulation. 1996; 94: 3276-3280

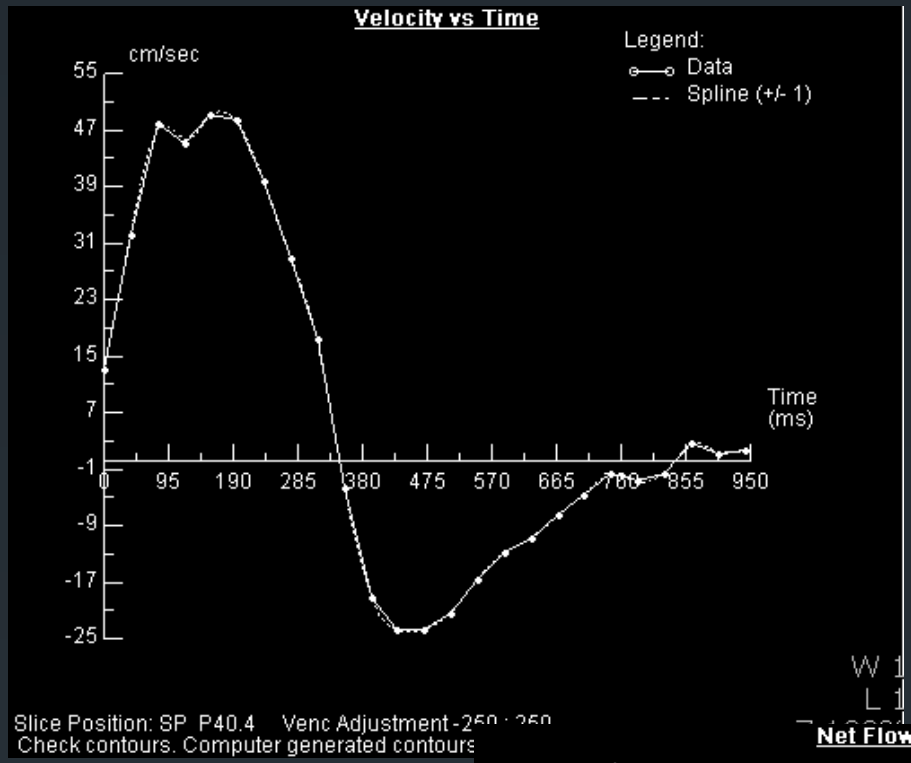
Velocity vs Time
cm/sec
Legend:
Data
Spline (+/- 1)
55
47
39
31
23
15
7
-1
-9
-17
-25
Time
(ms)
0
95
190
285
380
475
570
665
760
855
950
Slice Position: SP P40.4
Venc Adjustment
Check contours. Computer generated contours

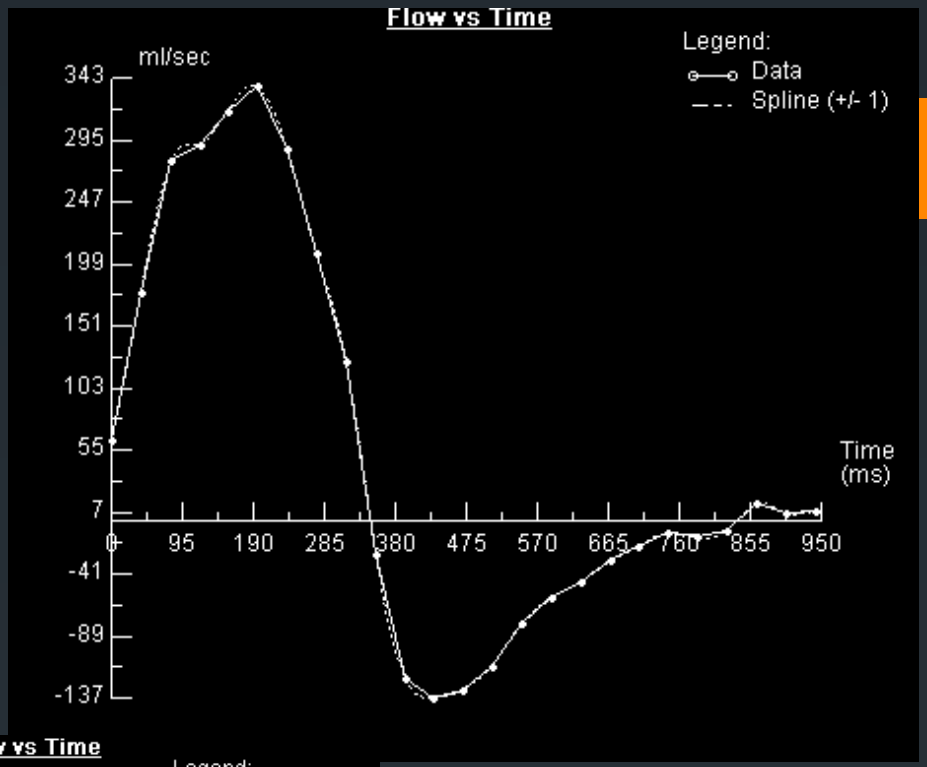
Flow vs Time
ml/sec
Legend:
Data
Spline (+/- 1)
343
295
247
199
151
103
55
7
-41
-89
-137
Time
(ms)
0
95
190
285
380
475
570
665
760
855
950

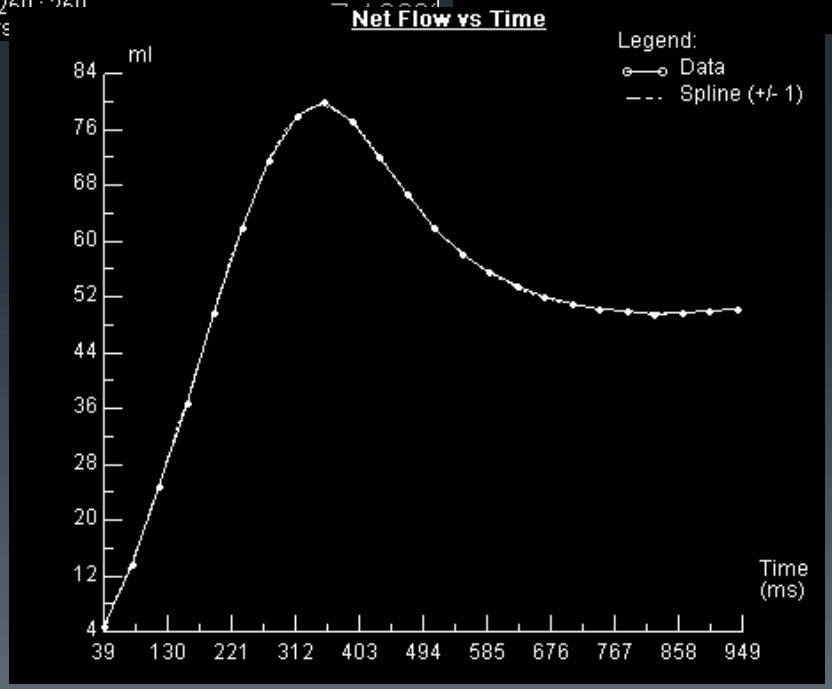
Net Flow vs Time
ml
Legend:
Data
Spline (+/- 1)
84
76
68
60
52
44
36
28
20
12
4
Time
(ms)
39
130
221
312
403
494
585
676
767
858
949

RV pressure-volume relationships

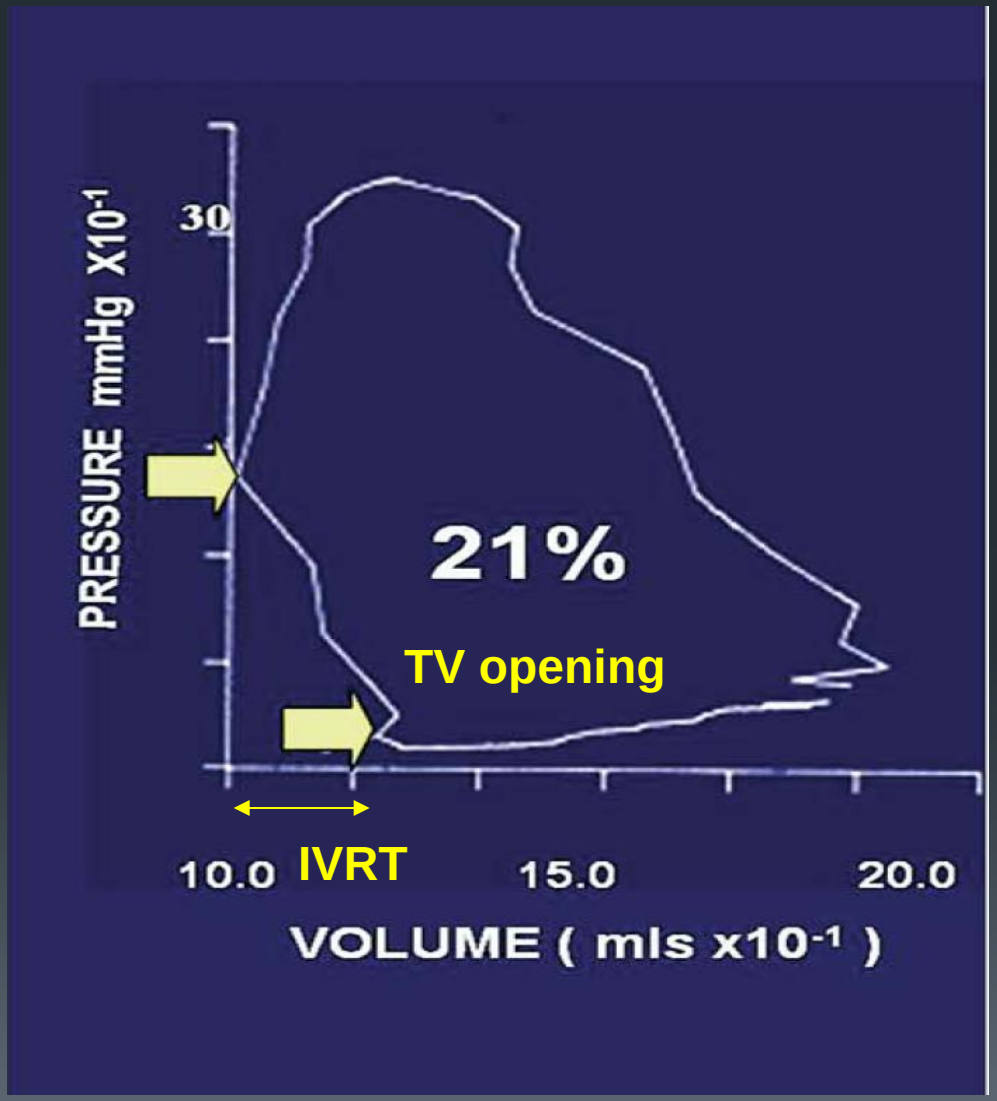

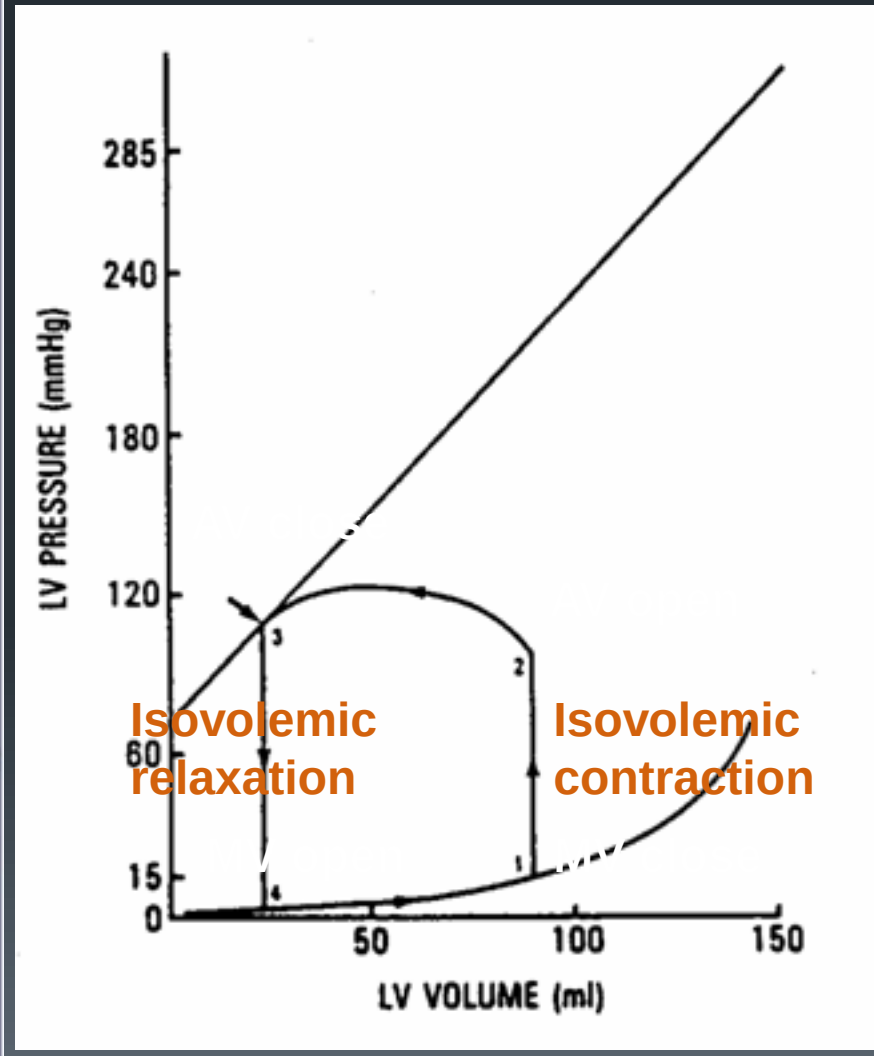

The effects of increasing afterload on PR

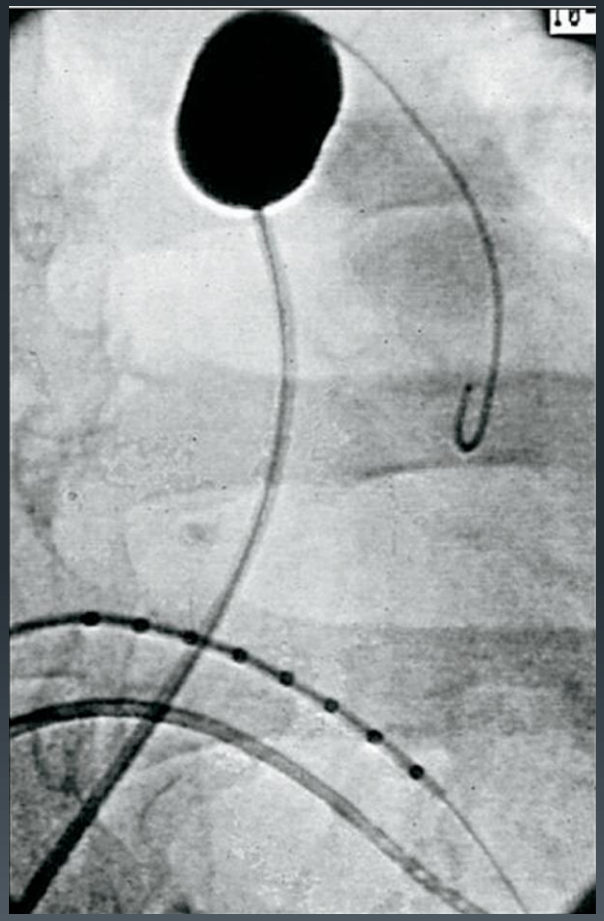

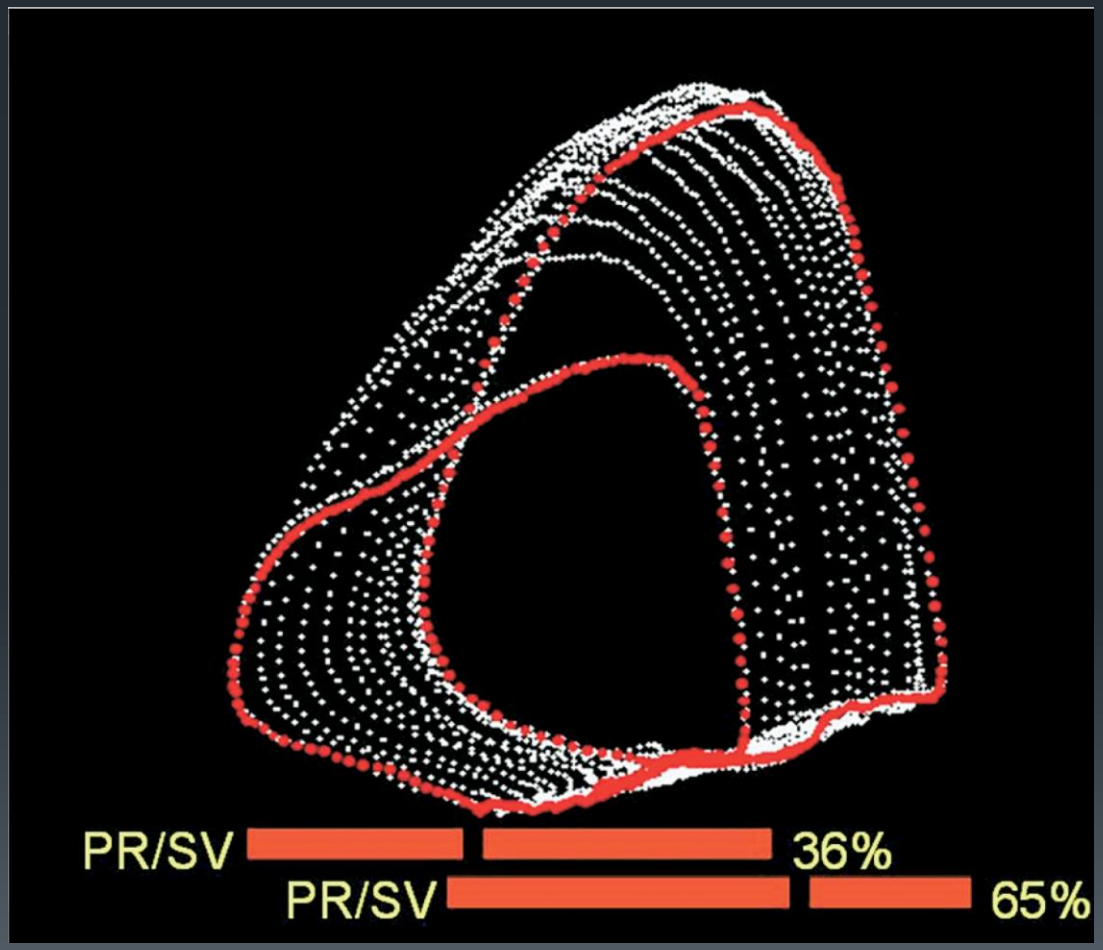

Evaluation of tricuspid regurgitation severity: Utility, advantages, and imitations

Parameter	Utility/Advantages	Limitations
RV/RA/IVC size	Enlargement sensitive for chronic significant TR. Normal size virtually excludes significant chronic TR.	Enlargement seen in other conditions. May be normal in acute significant TR
TV leaflet alterations	Flail valve specific for significant TR	Other abnormalities do not imply significant TR
Paradoxical septal motion (volume overload pattern)	Simple sign of severe TR	Not specific for TR
Jet area–Color flow	Simple, quick screen for TR	Subject to technical and hemodynamic factors. Underestimates severity in eccentric jets
Vena contracta width	Simple, quantitative, separates mild from severe TR	Intermediate values require further confirmation
PISA method	Quantitative	Validated in only a few studies
Flow quantitation –PW	Quantitative	Not validated for determining TR regurgitant fraction
Jet profile –CW	Simple, readily available	Qualitative, complementary data
Peak tricuspid E velocity	Simple, usually increased in severe TR	Depends on RA pressure and RV relaxation, TV area, and atrial fibrillation; Complementary data only
Hepatic vein flow	Simple; Systolic flow reversal is sensitive for severe TR	Influenced by RA pressure, atrial fibrillation.

J Am Soc Echocardiogr 2003;16:777-802

Evaluation of PR severity: Utility, advantages and imitations

Parameter	Utility/Advantages	Disadvantages
RV size	RV enlargement sensitive for chronic significant PR. Normal size virtually excludes significant PR	Enlargement seen in other conditions.
Paradoxical septal motion (volume overload pattern)	Simple sign of severe PR	Not specific for PR
Jet length –Color flow	Simple	Poor correlation with severity of PR
Vena contracta width	Simple quantitative method that works well for other valves	More difficult to perform; requires good images of pulmonary valve; lacks published validation
Jet deceleration rate –CW	Simple	Steep deceleration not specific for severe PR
Flow quantitation –PW	Quantitates regurgitant flow and fraction	Subject to significant errors due to difficulties of measurement of pulmonic annulus and a dynamic RVOT; not well validated

J Am Soc Echocardiogr 2003;16:777-802

Criteria for Pulmonary Valve Replacement

- Repaired TOF or similar physiology with moderate/severe PR (RF ≥25% measured by CMR) and two or more of the following criteria:
  1. RV EDV index ≥ 160 mL/m^2 (Z score>5)
  2. RV ESV index ≥ 70 mL/m^2
  3. LV EDV index ≤ 65 mL/m^2
  4. RV EF ≤ 45%
  5. RVOT aneurysm
  6. Clinical criteria: exercise intolerance, Sx & signs of HF, cardiac medications, syncope, sustained VT

Semin Thorac Cardiovasc Surg Pediatr Card Surg Ann 2006;9:11-22

Short axis view

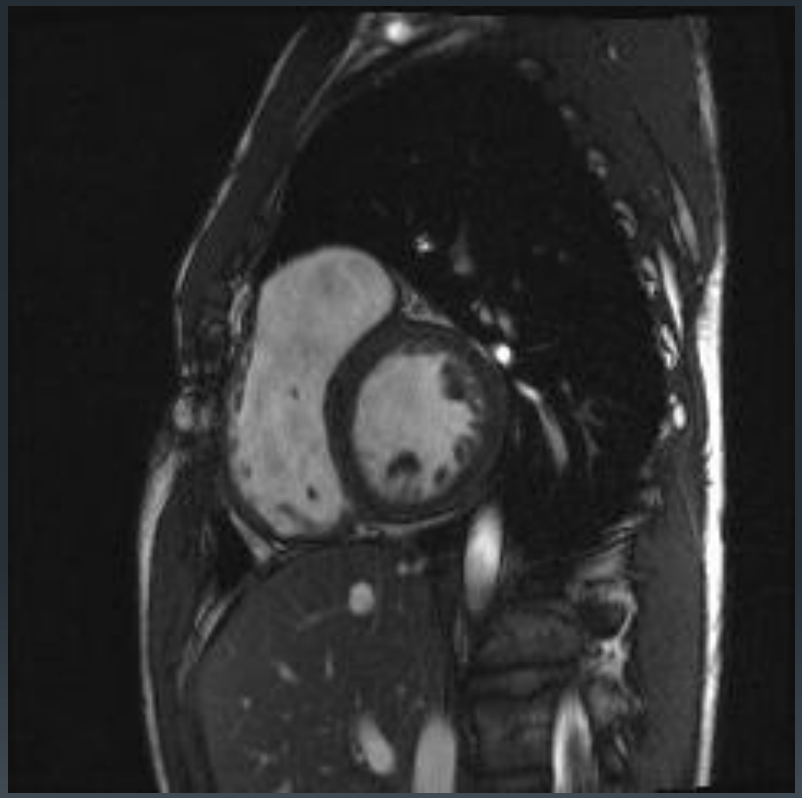

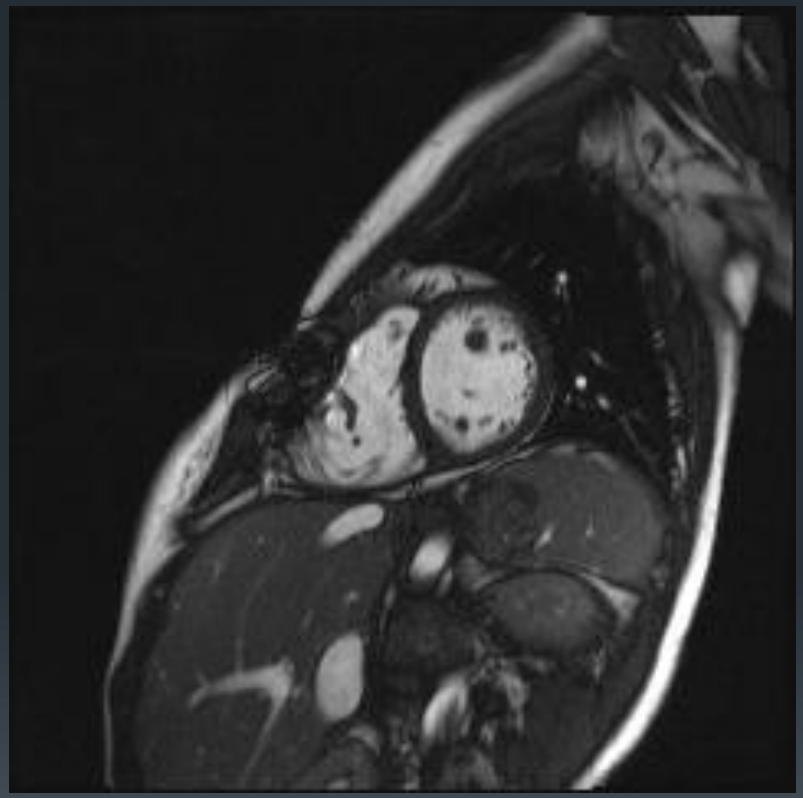

RVOT view