

# How to prevent pulmonary vein stenosis

**Yun, Tae-Jin**

*Asan Medical Center, University of Ulsan*

**How to prevent  
pulmonary vein stenosis**  
(upon TAPVD repair)

**Yun, Tae-Jin**

*Asan Medical Center, University of Ulsan*

# Typical Scenario of Post-repair PVS

- **2 days / F**
- **Obstructive infracardiac TAPVD**
- **Conventional repair for TAPVD**
- **Immediate post-op Echocardiography**  
: Mild anastomotic site stenosis with turbulent flow
- **Post-op 6 months Echocardiography**  
: Severe anastomotic site / individual stenosis
- **A series of reoperations to relieve PR-PVS**

# Individual PV stenosis

**Intrinsic predisposition  
toward PVS?**

# Individual PV stenosis

Intrinsic predisposition  
towards PVS?



# Post-repair PVS

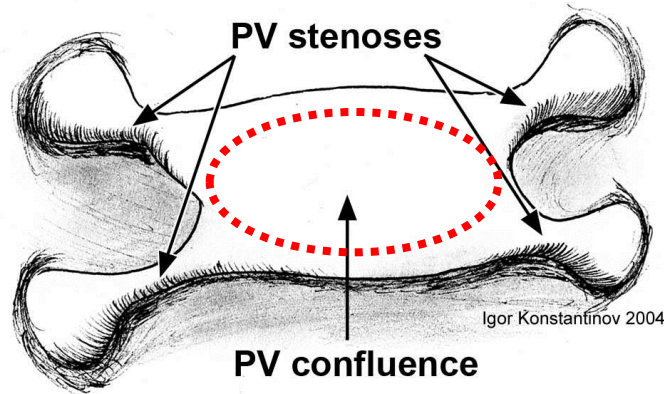
~~Intrinsic predisposition  
towards PVS?~~

Anastomotic Site  
Stenosis



Individual Vein  
Stenosis

**A**



# Post-repair PVS

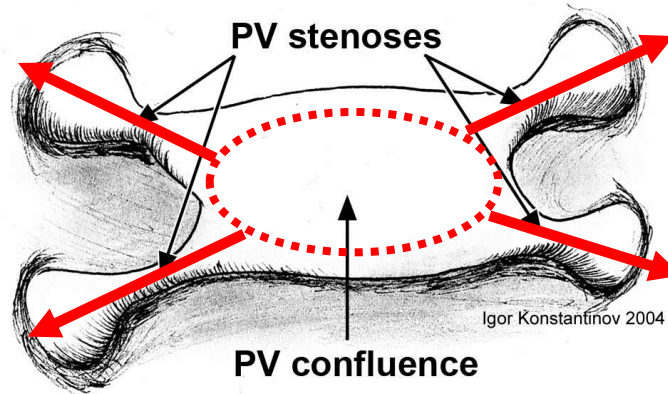
Intrinsic predisposition  
towards PVS?

Anastomotic Site  
Stenosis



Individual Vein  
Stenosis

**A**



Proximal Progression  
of PVS

# Experimental Model of PVS

## Alterations in Elastin and Collagen Related to the Mechanism of Progressive Pulmonary Venous Obstruction in a Piglet Model A Hemodynamic, Ultrastructural, and Biochemical Study

Jay I. LaBourene, John G. Coles, Dorothy J. Johnson, Arun Mehra, Fred W. Keeley, and Marlene Rabinovitch

We created an animal model to understand better the pathogenesis and underlying mechanism of progressive central pulmonary venous (PV) obstruction, a condition not amenable to current therapy. Twenty piglets underwent banding of their PVs, 18 had a sham operation, and 12 were nonoperated controls. After 1, 3, and 6 weeks hemodynamic data were obtained and correlated with ventricular weights, PV and pulmonary artery (PA) distensibilities (at 1 week), morphometric structural and ultrastructural analyses, and biochemical assessment of elastin determined gravimetrically (and by desmosine level at 1 week), collagen, and elastase activity. At 1 week, PV banding was associated with increased PV compliance ( $p < 0.05$ ). At 3 weeks, an increased PA pressure ( $P_{pa}$ ) ( $p < 0.05$ ) was observed, unaccompanied by a rise in PV pressure ( $P_{pv}$ ). In the PV, however, there was breakdown of the internal elastic lamina with apparent migration of smooth muscle cells from media to subendothelium. At 6 weeks, a rise in  $P_{pv}$  ( $p < 0.01$ ), a further rise in  $P_{pa}$  ( $p < 0.01$ ), and right ventricular hypertrophy ( $p < 0.005$ ) were observed. We also observed mild PV intimal thickening ( $p < 0.01$ ), complete degradation of elastic laminae ( $p < 0.05$ ), and an increase in collagen assessed morphometrically ( $p < 0.01$ ). The banding procedure resulted in an overall increase in PV elastin synthesis and in the proportion of elastin determined gravimetrically ( $p < 0.05$  for both) but not by desmosine level, suggesting the possibility of poor cross-linking of elastin, which might account for the early increased distensibility of the PV. However, our assay could not detect an increase in elastase activity associated with either the increased distensibility or the ultrastructural changes of elastin degradation. The increased  $P_{pa}$  was not associated with significant PA biochemical or structural changes. We speculate that in response to distal venous obstruction, early remodeling of the PVs increases distensibility, protecting the lung from venous congestion and blunting a rise in  $P_{pv}$ . PA hypertension precedes the rise in  $P_{pv}$ , likely because of reflex vasoconstriction. The subsequent modest rise in  $P_{pv}$  is already associated with extensive fibrosis of the PV, suggesting a reason for unsuccessful current therapy and a need for consideration of earlier assessment and intervention. (*Circulation Research* 1990;66:438-456)

Progressive obstruction of the central pulmonary veins can occur as a primary congenital heart defect<sup>1</sup> or in association with lesions

From the Departments of Cardiology, Pathology, Cardiovascular Surgery, and Biochemistry, The Hospital for Sick Children, and from the Departments of Pediatrics, Pathology, Surgery, and Biochemistry, University of Toronto, Toronto, Ontario, Canada.

Supported by grants T-724, T-1082, and AN-625 from The Heart and Stroke Foundation of Ontario. J.I.L. is a Research Fellow of the Canadian Heart Foundation; M.R. is a Career Investigator of the Heart and Stroke Foundation of Ontario.

Address for correspondence: Marlene Rabinovitch, MD, Department of Cardiology, The Hospital for Sick Children, 555 University Avenue, Toronto, Ontario M5G 1X8, Canada.

Received March 21, 1989; accepted August 28, 1989.

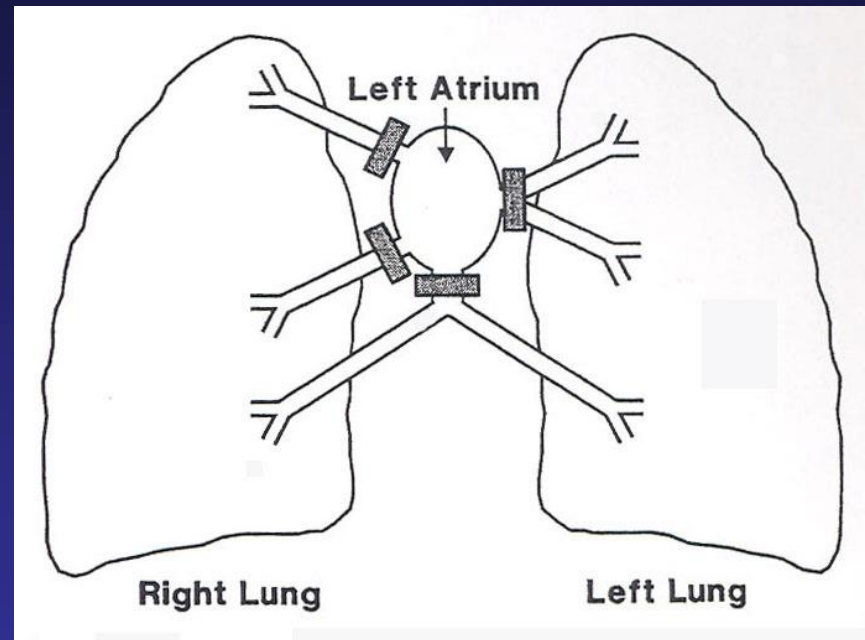
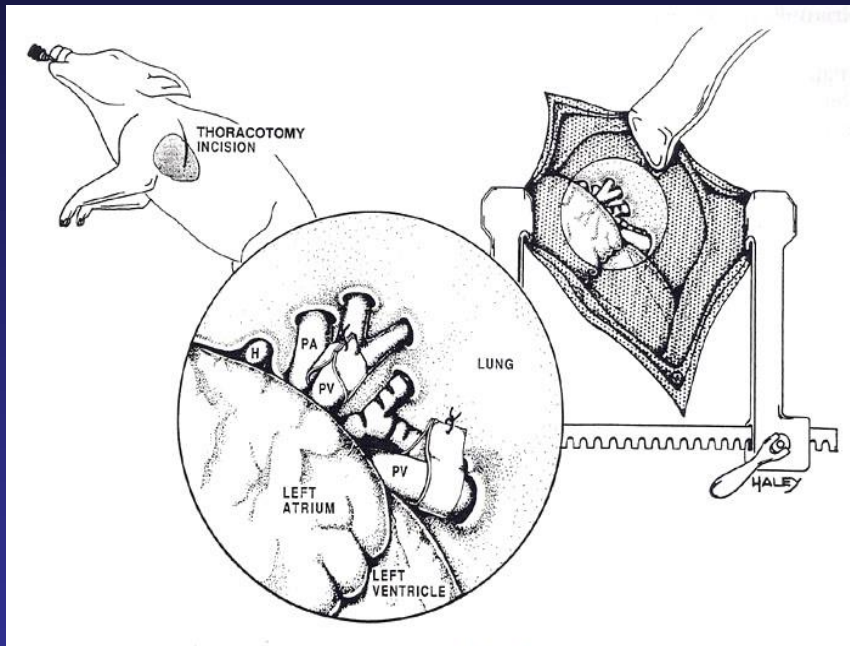
such as total anomalous pulmonary venous drainage.<sup>2</sup>

It is also seen after corrective surgery for cardiac defects such as transposition of the great arteries.<sup>3</sup> Since initially pulmonary venous pressure is normal or mildly elevated, particularly if there is uneven obstruction of the veins,<sup>4,5</sup> attempted repair by balloon dilatation or surgical reimplantation is usually delayed until more severe disease is apparent. Both procedures have been largely unsuccessful due to recurring obstruction.<sup>6,7</sup> Therefore, it seems that the approach and timing of intervention are inappropriate, and that a better understanding of the mechanism of progressive pulmonary venous obstruction would allow for a more successful treatment plan.

- Rabinovitch et al (1990)
- Piglet model of PVS
- 60 piglets
  - 20 PV banding
  - 18 Sham operation
  - 12 no operation control
- Observation for 1,3 and 6 weeks



# Experimental Model of PVS



# Experimental Model of PVS

1 week



3 weeks



6 weeks



# Experimental Model of PVS

1 week



3 week



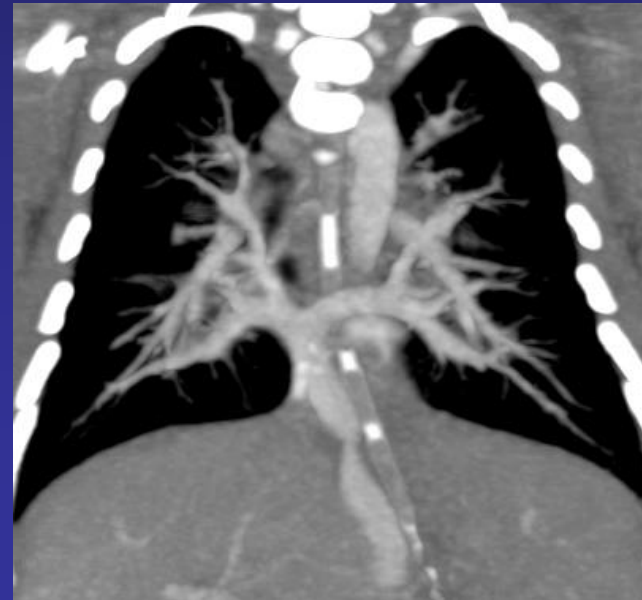6 week



**Pulmonary venoocclusive disease?**

# Who develops PR-PVS?

- Small confluence and individual PVs
- Unfavorable PV morphology



# Factors Associated With Mortality and Reoperation in 377 Children With Total Anomalous Pulmonary Venous Connection

Tara Karamlou, MD\*; Rebecca Gurofsky, BSc\*; Eisar Al Sukhni;  
John G. Coles, MD; William G. Williams, MD; Christopher A. Caldarone, MD;  
Glen S. Van Arsdell, MD; Brian W. McCrindle, MD, MPH

**Background**—We sought to determine era-specific changes in the incidence of mortality and reoperation in children with total anomalous pulmonary venous connection.

**Methods and Results**—We reviewed the records of 377 children presenting from 1946 to 2005 with total anomalous pulmonary venous connection. Multivariable parametric regression models determined the incidence and risk factors for death and reoperation after repair. Pulmonary venous connection was supracardiac in 44%, infracardiac in 26%, cardiac in 21%, and mixed in 9%. Pulmonary venous obstruction was present in 48% at presentation, most frequently with infracardiac connection type ( $P<0.001$ ). In total, 327 patients were repaired (median age, 1.7 months). Overall survival from repair was  $65\pm 6\%$  at 14 years, with a current survival of 97%. Significant ( $P<0.01$ ) incremental risk factors for postrepair death were cardiac connection type, earlier operation year, younger age at repair, use of epinephrine postoperatively, and postoperative pulmonary venous obstruction. More recent operation year was associated with younger age at repair ( $P<0.001$ ), decreased use of deep hypothermic circulatory arrest ( $P<0.001$ ), and use of specific drugs postoperatively ( $P<0.001$ ). Risk-adjusted estimated 1-year survival for a patient repaired at birth with unfavorable morphology in 2005 is 37% (95% CI, 8 to 80) compared with 96% (95% CI, 91 to 99) for a patient with favorable morphology repaired at 1 year of age. Freedom from reoperation was  $82\pm 6\%$  at 11 years after repair, with increased risk associated with mixed connection type ( $P=0.04$ ) and postoperative pulmonary venous obstruction ( $P<0.001$ ).

**Conclusions**—Mortality after total anomalous pulmonary venous connection repair has decreased but remains highest in young patients and in those with cardiac connection type or pulmonary venous obstruction. Unfavorable anatomic characteristics remain important determinants of postrepair survival despite improved perioperative care. (*Circulation*. 2007;115:1591-1598.)

**Key Words:** congenital defects ■ pulmonary veins ■ risk factors ■ surgery ■ survival

# Total Anomalous Pulmonary Venous Connection

## Morphology and Outcome From an International Population-Based Study

Anna N. Seale, MBBChir, MRCP; Hideki Uemura, MD, MPhil, FRCS;

Steven A. Webber, MBChB, MRCP; John Partridge, FRCR, FRCP, FRANZCR; Michael Roughton, MSc;

Siew Y. Ho, PhD, FRCPath; Karen P. McCarthy, BSc; Sheila Jones, BSc; Lynda Shaughnessy, BN;

Jan Sunnegardh, MD, PhD; Katarina Hanseus, MD, PhD; Hakan Berggren, MD, PhD;

Sune Johansson, MD; Michael L. Rigby, MD, FRCP; Barry R. Keeton, MB, BS, FRCP, FRCPC;

Piers E.F. Daubeney, DM, FRCPC; on behalf of the British Congenital Cardiac Association


**Background**—Late mortality after repair of total anomalous pulmonary venous connection is frequently associated with pulmonary venous obstruction (PVO). We aimed to describe the morphological spectrum of total anomalous pulmonary venous connection and identify risk factors for death and postoperative PVO.

**Methods and Results**—We conducted a retrospective, international, collaborative, population-based study involving all 19 pediatric cardiac centers in the United Kingdom, Ireland, and Sweden. All infants with total anomalous pulmonary venous connection born between 1998 and 2004 were identified. Cases with functionally univentricular circulations or atrial isomerism were excluded. All available data and imaging were reviewed. Of 422 live-born cases, 205 (48.6%) had supracardiac, 110 (26.1%) had infracardiac, 67 (15.9%) had cardiac, and 37 (8.8%) had mixed connections. There were 2 cases (0.5%) of common pulmonary vein atresia. Some patients had extremely hypoplastic veins or, rarely, discrete stenosis of the individual veins. Sixty (14.2%) had associated cardiac anomalies. Sixteen died before intervention. Three-year survival for surgically treated patients was 85.2% (95% confidence interval 81.3% to 88.4%). Risk factors for death in multivariable analysis comprised earlier age at surgery, hypoplastic/stenotic pulmonary veins, associated complex cardiac lesions, postoperative pulmonary hypertension, and postoperative PVO. Sixty (14.8%) of the 406 patients undergoing total anomalous pulmonary venous connection repair had postoperative PVO that required reintervention. Three-year survival after initial surgery for patients with postoperative PVO was 58.7% (95% confidence interval 46.2% to 69.2%). Risk factors for postoperative PVO comprised preoperative hypoplastic/stenotic pulmonary veins and absence of a common confluence.

**Conclusions**—Preoperative clinical and morphological features are important risk factors for postoperative PVO and survival. (*Circulation*. 2010;122:2718-2726.)

**Key Words:** follow-up studies ■ pulmonary veins ■ pulmonary vein stenosis ■ heart defects, congenital

# How to prevent pulmonary vein stenosis



**Primary (pre-emptive) sutureless  
repair for TAPVD with unfavorable  
PV anatomy!**

# Sutureless Repair of PV

- Sutureless technique for PVS
- Coles procedure
- Pericardial Marsupialization
- Chirurgicale sans suture
- Atriopericardial anastomosis



# **Sutureless repair (SR)**

- Theoretical advantage -

- **Avoid geometric distortion**
- **No suture material on PVs**
- **Avoid restriction of ostial growth**

# Chirurgicale sans suture (1996)



Lacour-Gayet FG

F. Lacour-Gayet\*, C. Rey\*\*  
et C. Planché\*

FAIT CLINIQUE

## Sténose des veines pulmonaires. Description d'une technique chirurgicale sans suture utilisant le péricarde *in situ*

### Summary

Pulmonary Vein Stenosis. Description of a Sutureless Surgical Technique Using the Pericardium *in situ*.

Pulmonary vein stenosis is a rare cardiac disease associated with a disastrous prognosis. Nowadays, it is more often a iatrogenic complication, following neonatal surgical repair of total anomalous pulmonary venous drainage (TAPVD). It is as well a native congenital anomaly. The responsible histologic lesion is an intimal hyperplasia that proliferates to involve the extracardiac segment of the pulmonary veins. This lesion tends to be extremely recurrent following surgical or angioplastic attempts. A new sutureless surgical technique, that tunnelizes the pulmonary veins to the left atrium through the pericardium, is described. This method was successfully applied in a 2.5 years old child, presenting with bilateral stenosis of pulmonary veins, following neonatal repair of a TAPVD. The result, controlled 6 months later, by catheterization and angiography was judged satisfactory. This new technique, that has to be confirmed by a longer follow up, may provide a therapeutic answer to this challenging disease. Arch Mal Cœur 1996 ; 89 : 633-6.

### Résumé

La sténose des veines pulmonaires est une affection rare dont le pronostic est redoutable. Elle est, actuellement, le plus souvent iatrogénique, compliquant la chirurgie néonatale du retour veineux pulmonaire anormal total. Elle est ailleurs primitive, congénitale. La lésion histologique causale est une hyperplasie intimale proliférative gagnant progressivement le segment extracardiaque des veines pulmonaires. Cette lésion a tendance à récidiver après toute tentative chirurgicale ou angioplastique. Une nouvelle technique chirurgicale sans suture, tunnelisant les veines pulmonaires à l'oreillette gauche, à travers le péricarde cloisonné est décrite. Cette méthode a été utilisée avec succès chez un enfant de 2 ans et demi, atteint de sténose bilatérale des veines pulmonaires, acquise après chirurgie néonatale d'un retour veineux pulmonaire anormal total. Le résultat contrôlé à 6 mois par cathétérisme et angiographie est jugé satisfaisant. Cette nouvelle technique, qui doit être validée par un recul plus important, peut apporter une solution thérapeutique de cette affection redoutable. Arch Mal Cœur 1996 ; 89 : 633-6.

La sténose des veines pulmonaires est une affection rare dont le pronostic est redoutable. « Aucun traitement chirurgical ne permet d'obtenir la guérison ou une palliation à long terme de cette affection létale » [1].

neux pulmonaire anormal total. Elle est ailleurs primitive, congénitale survenant isolément ou en association avec une autre cardiopathie [1-3]. Une ou plusieurs veines pulmonaires peuvent être sténosées ; les lésions pouvant être uni ou bilatérales.

### ASPECTS ANATOMOCLINIQUES

Actuellement, la sténose des veines pulmonaires est le plus souvent iatrogénique, compliquant la chirurgie néonatale du retour ve-

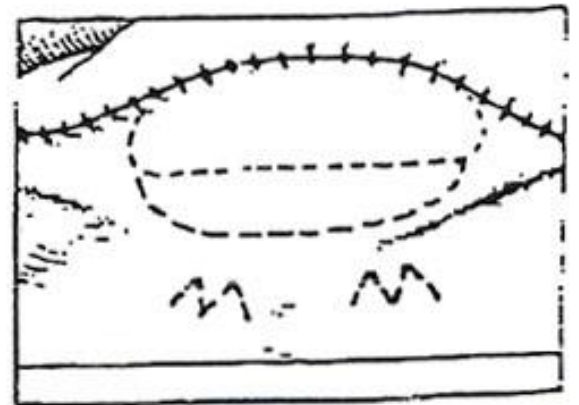
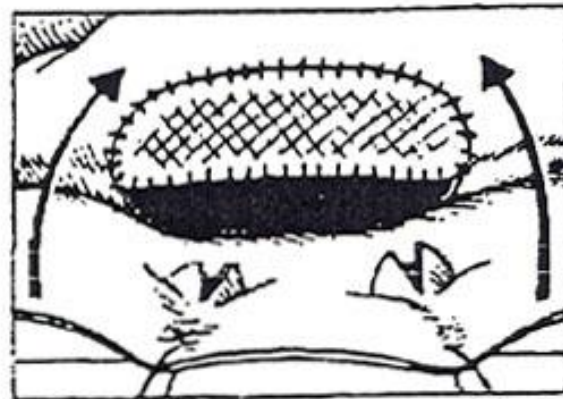
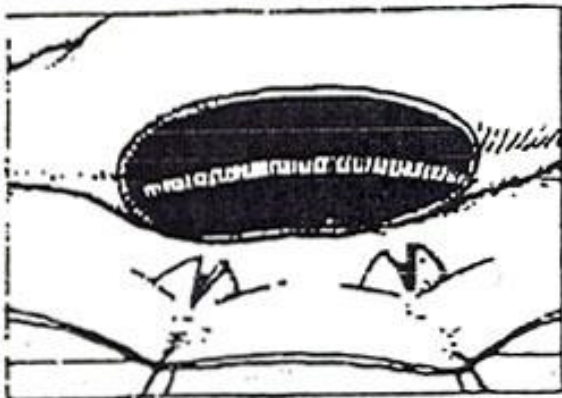
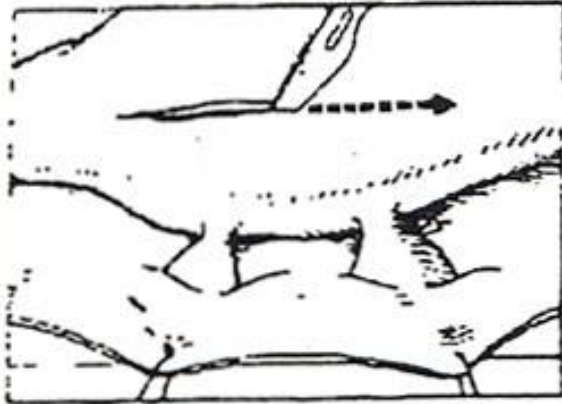
Il faut distinguer au plan anatomo-pathologique, les sténoses anastomotiques survenant à distance des ostiums veineux pulmonaires et liées à un défaut de croissance de l'anastomose, des sténoses ostiales veineuses pulmo-

(\*) Service de chirurgie cardiaque pédiatrique, hôpital Marie-Lannelongue, 133, av. de la Résistance, 92390-Le Plessis-Robinson.

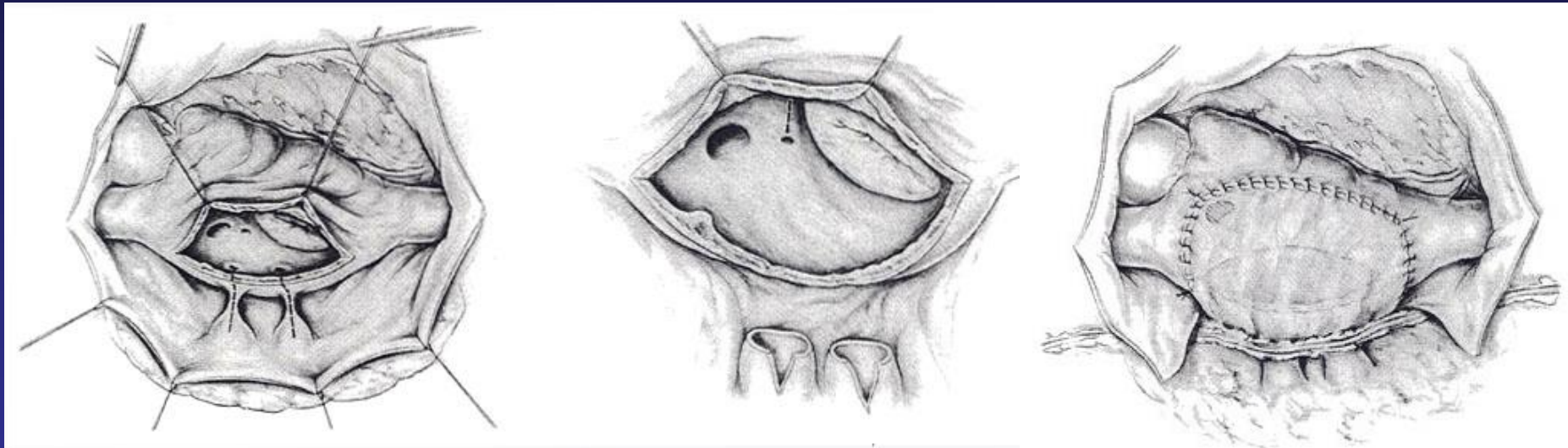
(\*\*) Service de cardiologie pédiatrique, hôpital cardiologique de Lille, boulevard du Pr. J.-Leclercq, 59037 Lille Cedex.

(Tirés à part : Dr F. Lacour-Gayet).

# Chirurgicale sans suture (1996)



# Sutureless in situ pericardial repair (Lacour-Gayet, 1999)



# Pericardial Marsupialization (2006)



Edward L. Bove

CARDIOVASCULAR

## Management of Congenital and Acquired Pulmonary Vein Stenosis

Eric J. Devaney, MD, Andrew C. Chang, MD, Richard G. Ohye, MD, and Edward L. Bove, MD

Section of Cardiac Surgery, Division of Pediatric Cardiac Surgery, University of Michigan School of Medicine, Ann Arbor, Michigan

**Background.** Pulmonary vein (PV) stenosis, whether congenital or after repair of total anomalous pulmonary venous connection (TAPVC), continues to carry a poor prognosis.

**Methods.** A retrospective review identified 36 patients who underwent repair of PV stenosis between December 1989 and June 2003. Fourteen with congenital PV stenosis underwent scar excision and primary repair (n = 2), intraoperative stent placement (n = 4), or sutureless pericardial marsupialization (n = 8). Twenty-two with acquired PV stenosis after TAPVC repair underwent anastomotic revision and/or vein repair (n = 11) or sutureless pericardial marsupialization (n = 11). Follow-up ranged from 1 month to 14 years (median, 30 months).

**Results.** Among the 14 patients with congenital PV stenosis, 8 died (3 early deaths, 4 late deaths with restenosis, and 1 late noncardiac death). Among the six

survivors, five (4 after marsupialization) have not developed restenosis. Among 11 of 22 patients with acquired PV stenosis undergoing anastomotic revision or vein repair, there were 5 deaths (2 early, 2 late with restenosis, and 1 late noncardiac death) and 1 of the six survivors has developed restenosis. Of the remaining 11 undergoing marsupialization, there was one late death (with restenosis) and 10 survivors have no restenosis. Congenital etiology, use of marsupialization technique, presence of associated defect, and extent of disease were identified as risk factors for poor outcome.

**Conclusions.** Patients with pulmonary vein stenosis continue to have a guarded prognosis. Sutureless pericardial marsupialization was associated with satisfactory midterm results and appears superior to other conventional techniques.

(Ann Thorac Surg 2006;81:992-6)

© 2006 by The Society of Thoracic Surgeons

36 patients with PVS

From 1989 to 2003

Sutureless repair in 8 since 1998

# Coles procedure (1998, Najm et al)



Coles JG

## A SUTURELESS TECHNIQUE FOR THE RELIEF OF PULMONARY VEIN STENOSIS WITH THE USE OF IN SITU PERICARDIUM

Hani K. Najm, MD, Christopher A. Caldarone, MD, Jeffery Smallhorn, MD, and John G. Coles, MD,  
Toronto, Ontario, Canada

Pulmonary vein (PV) stenosis develops as a progressive and usually lethal complication after surgical repair of total anomalous PV connection. Conventional surgical repair for the management of recurrent PV stenosis has been generally unsuccessful because of proliferative neointimal hyperplasia resulting in recurrent PV obstruction. The factors that result in recurrent stenosis after the usual types of patch venoplasty are unknown. We speculated that direct suturing of PVs and patch material may be the substrate for turbulent blood flow triggering intimal hyperplasia and eventual narrowing of the vein. On the basis of these considerations, we developed a sutureless technique for repairing PV stenosis with in situ pericardium. We present here its early but promising results.

### Patients

**PATIENT 1.** Patient 1 was born in January 1995 with infradiaphragmatic total anomalous PV connection and severe obstruction of the descending vertical vein. On day 1, the infradiaphragmatic anomalous vein was ligated and the confluence was anastomosed to the left atrium under conditions of hypothermic circulatory arrest. At 6 months, the child had conspicuous tachypnea. Echocardiography revealed obstructed left PVs with a mean gradient of 7 mm Hg (peak 16 mm Hg) and suprasystemic right ventricular pressure. Angiography demonstrated variable obstruction of all four PVs, with a mean pulmonary artery pressure of 38 mm Hg (systolic 92 mm Hg). At reoperation, obstruction of all PVs was confirmed. Under conditions of circulatory arrest, a pedicled flap of free right atrial wall–superior vena cava junction based at the inferior vena cava was used to patch the right-sided veins and carried behind the aorta to patch the left upper PV. The left lower vein was repaired with a flap created from the left atrial appendage.<sup>1</sup>

After that operation, the child had repeated admissions with respiratory tract infections, complicated at 1 year by hemoptysis. Echocardiography revealed recurrence of obstruction. At the second reoperation, atretic left-sided veins and severe stenosis of right-sided veins were noted.

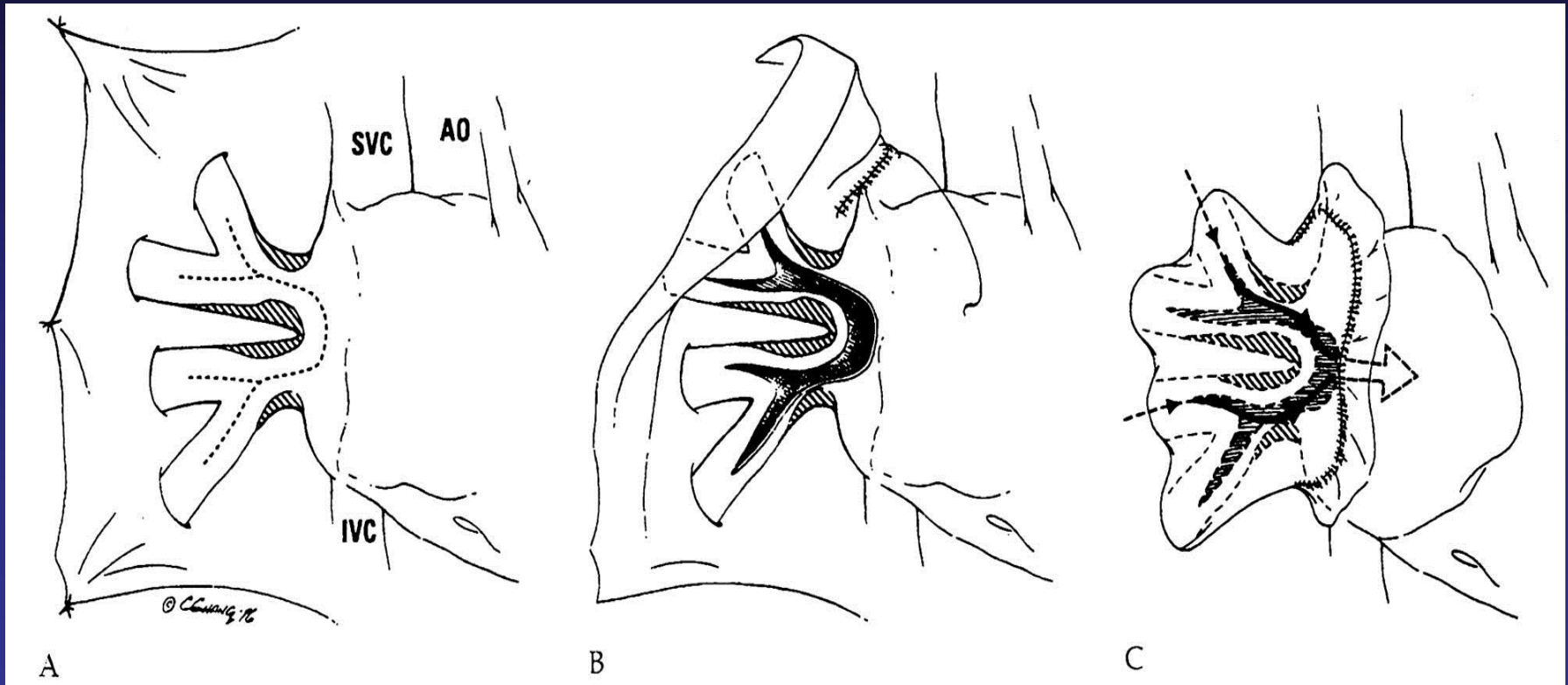
The PVs were opened, and an in situ pericardial sutureless patch was used for reconstruction. Echocardiography a year later showed patent veins, with mean gradients of 4 mm Hg on the right side and 5 mm Hg on the left. The estimated mean pulmonary artery pressure was 10 mm Hg. Perfusion lung scan showed 67% perfusion on the right side and 33% on the left. The child currently has no symptoms.

**PATIENT 2.** Patient 2, a female infant, was born on January 1995 with total anomalous PV connection to coronary sinus with echocardiographic evidence of partial obstruction. At 2 weeks, she underwent repair consisting of unroofing of the coronary sinus, as described by Van Praagh and Harken.<sup>2</sup> On completion of the procedure, the patient could not be weaned from cardiopulmonary bypass. At this time the right ventricular pressure was suprasystemic. The child was placed on extracorporeal membrane oxygenator and subsequently weaned after 3 days, with delayed sternal closure in 10 days as a result of persistent hemodynamic instability. Echocardiographic findings before discharge revealed unobstructed PV confluence–left atrium connection. However, echocardiography 4 months later revealed an obstructed right upper PV with a mean right ventricular pressure of 25 mm Hg. Perfusion scan showed 87% perfusion to the left lung and 13% to the right. Eleven months after the operation, echocardiography and cardiac catheterization revealed pulmonary hypertension, with a mean pulmonary artery pressure of 34 mm Hg and anatomically right PV stenosis.

At reoperation, the presence of severe bilateral PV stenosis extending from left atrium a variable distance into the intraparenchymal PVs was confirmed. An in situ pericardial baffle was used for repair, as described here. Cardiac catheterization 6 months later revealed normal venous drainage on the left side and mild obstruction on the right side. The mean pulmonary artery pressure was 16 mm Hg. Perfusion lung scan showed 42% to left lung and 58% to right. The child has no symptoms at 15 months of postoperative follow-up.

**Technique.** Standard cardiopulmonary bypass technique is used. The incision is made into the left atrium and extended into both upper and lower PV ostia separately

# Coles procedure (1998)



# Coles procedure (2005, Yun et al)



Coles JG

## Conventional and sutureless techniques for management of the pulmonary veins: Evolution of indications from postrepair pulmonary vein stenosis to primary pulmonary vein anomalies

Tae-Jin Yun, MD  
John G. Coles, MD  
Igor E. Konstantinov, MD, PhD  
Osman O. Al-Radi, MD  
Rachel M. Wald, MD  
Vitor Guerra, MD  
Nito C. de Oliveira, MD  
Glen S. Van Arsdell, MD  
William G. Williams, MD  
Jeffrey Smallhorn, MD  
Christopher A. Caldarone, MD

**Objective:** We have previously reported a limited but favorable experience with a novel sutureless technique for surgical management of postoperative pulmonary vein stenosis occurring after repair of total anomalous pulmonary venous drainage. Because this technique requires integrity of the retrocardiac space for hemostasis, extension of the technique to the primary repair of pulmonary vein anomalies requires evaluation. This analysis reviews our experience with the sutureless technique in patients with postrepair pulmonary vein stenosis, as well as our extension of the technique into primary repair of pulmonary vein anomalies.

**Methods:** Retrospective univariable-multivariable analysis of all pulmonary vein stenosis procedures and sutureless pulmonary vein procedures over a 20-year period was performed. Cox proportional hazards modeling was used to identify variables associated with freedom from reoperation or death.

**Results:** Sixty patients underwent 73 procedures, with pulmonary vein stenosis present in 65 procedures. The sutureless technique was used in 40 procedures. Freedom from reoperation or death at 5 years after the initial procedure was 49%. Unadjusted freedom from reoperation or death was greater with the sutureless technique for patients with postrepair pulmonary vein stenosis ( $P = .04$ ). By using multivariable analysis, a higher pulmonary vein stenosis score was associated with greater risk of reoperation or death. After adjustment, the sutureless repair was associated with a nonsignificant trend toward greater freedom from reoperation or death ( $P = .12$ ). Despite the absence of retrocardiac adhesions, operative mortality was not increased with the sutureless technique ( $P = .64$ ). Techniques to control bleeding (intrapleural hilar reapproximation) and improve exposure (inferior vena cava division) were identified.

**Conclusion:** The sutureless technique for postrepair pulmonary vein stenosis is associated with encouraging midterm results. Extension of the indications for the technique to primary repair appears safe with the development of simple intraoperative maneuvers.

From the Division of Cardiovascular Surgery and Cardiology at The Hospital for Sick Children and University of Toronto, Toronto, Ontario, Canada.

Read at the Eighty-fourth Annual Meeting of The American Association for Thoracic Surgery, Toronto, Ontario, Canada, April 25-28, 2004.

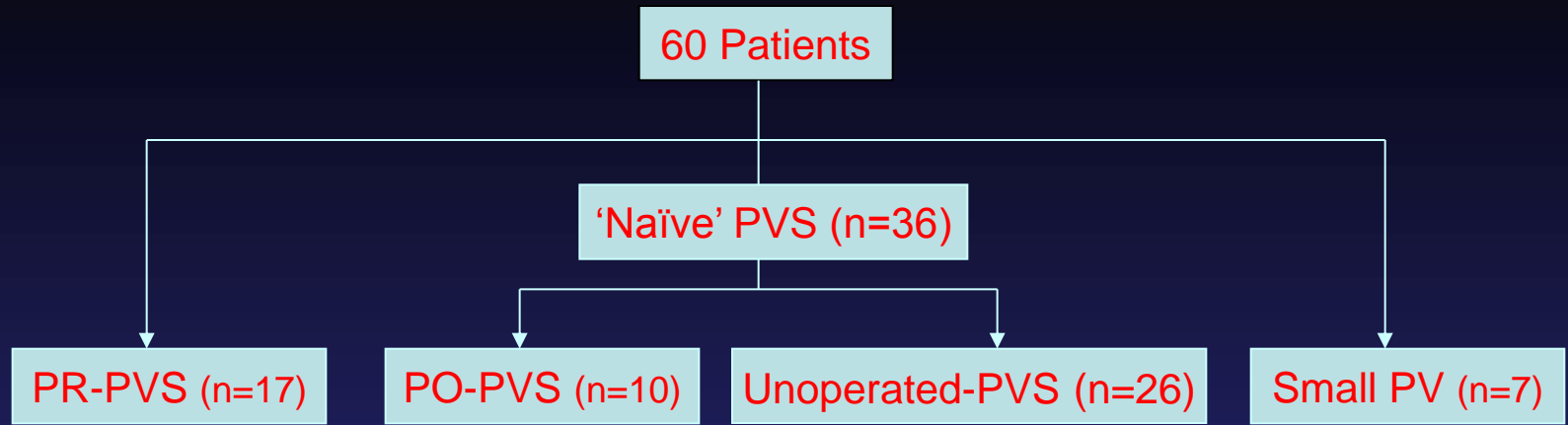
Received for publication April 25, 2004; revisions received Aug 20, 2004; accepted for publication Aug 25, 2004.

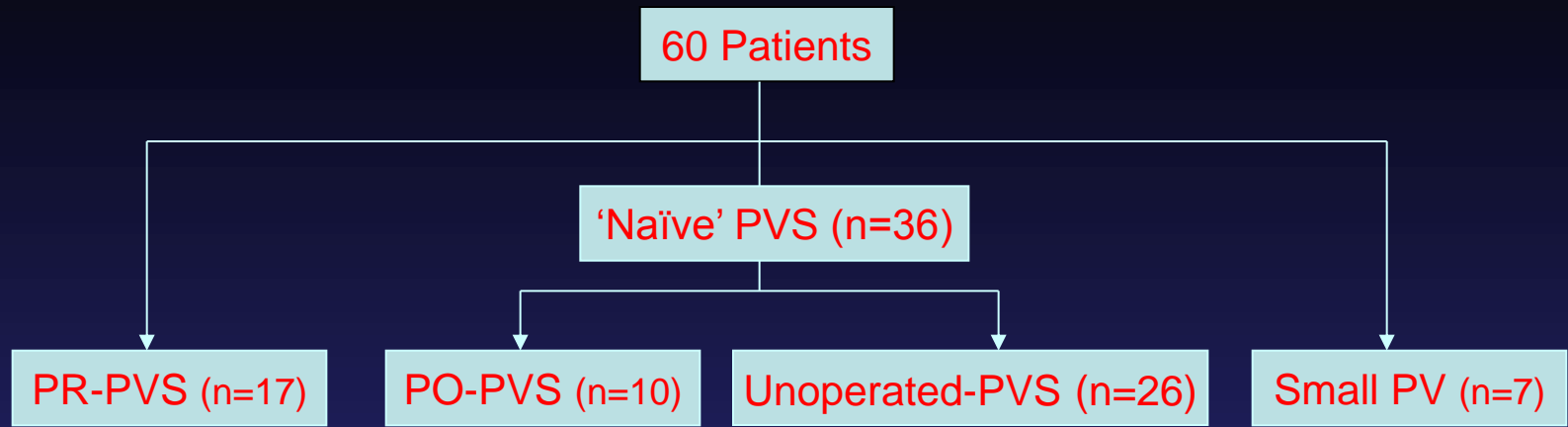
Address for reprints: Christopher Caldarone, MD, Division of Cardiovascular Surgery, The Hospital for Sick Children, 535 University Ave, Toronto, Ontario, Canada, M5G 1X8 (E-mail: christopher.caldarone@sickkids.ca).

J Thorac Cardiovasc Surg 2005;129:167-74  
0022-5223/\$30.00

Copyright © 2005 by The American Association for Thoracic Surgery  
doi:10.1016/j.jtcvs.2004.08.043



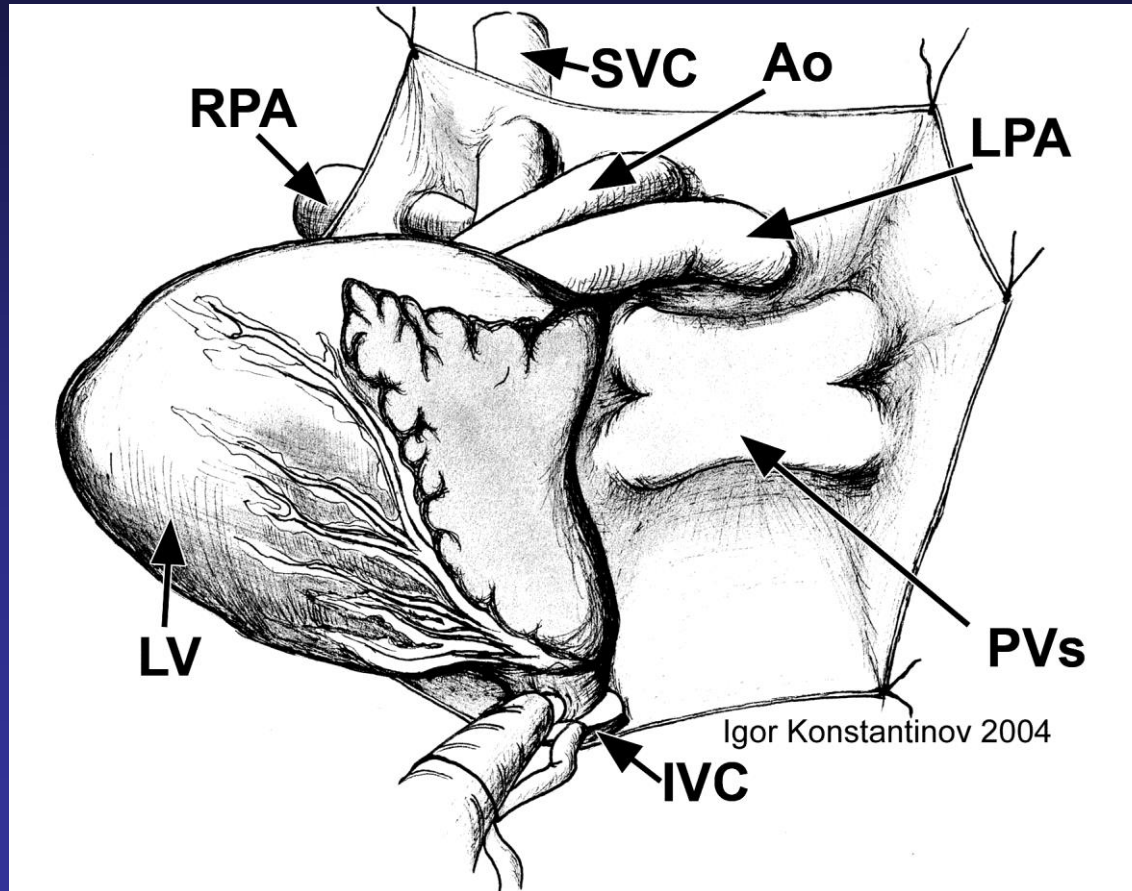




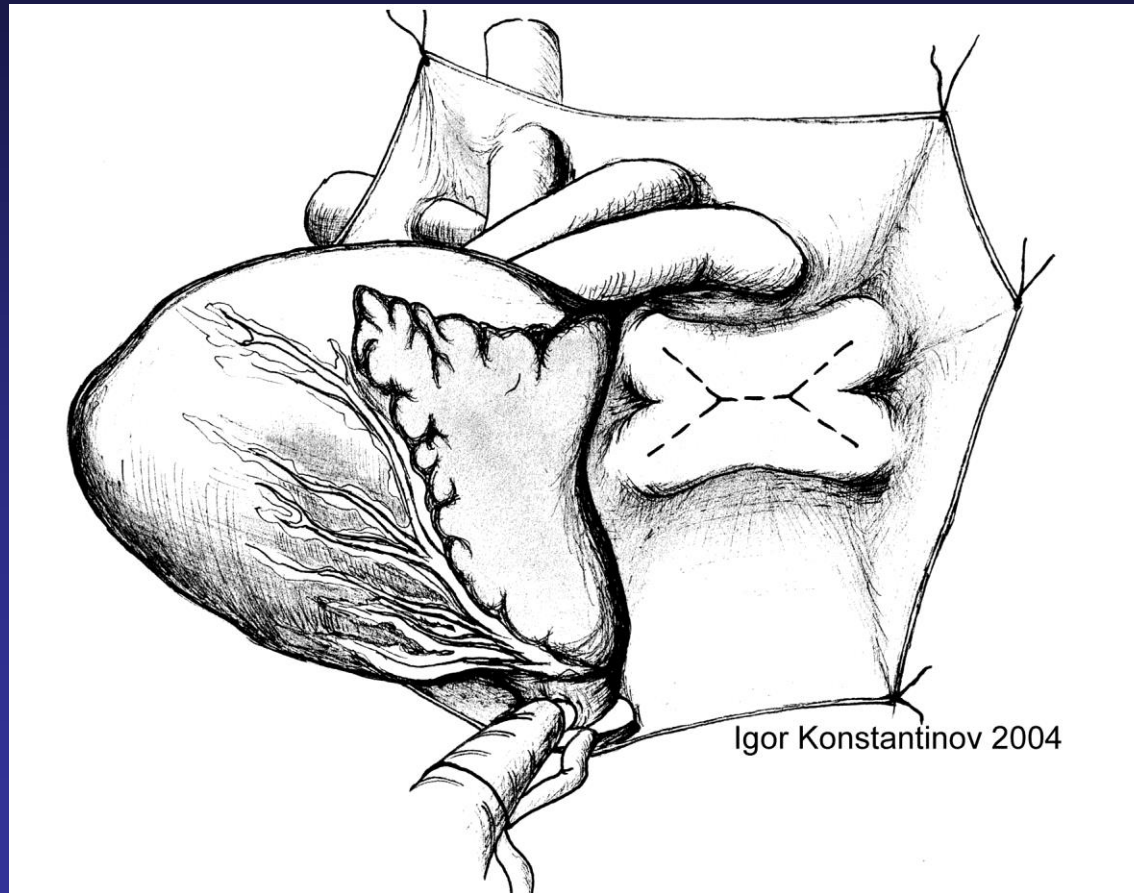
<b>Sutureless repair (SR)</b>	<b>7 (3)*</b>
<b>Patch pulmonary venoplasty (PVP)</b>	<b>0 (0)</b>
<b>Ostial endovenectomy (OE)</b>	<b>0 (0)</b>
<b>Stent</b>	<b>0 (0)</b>
<b>Atrial PVP</b>	<b>0 (0)</b>

**\* Reop or death**

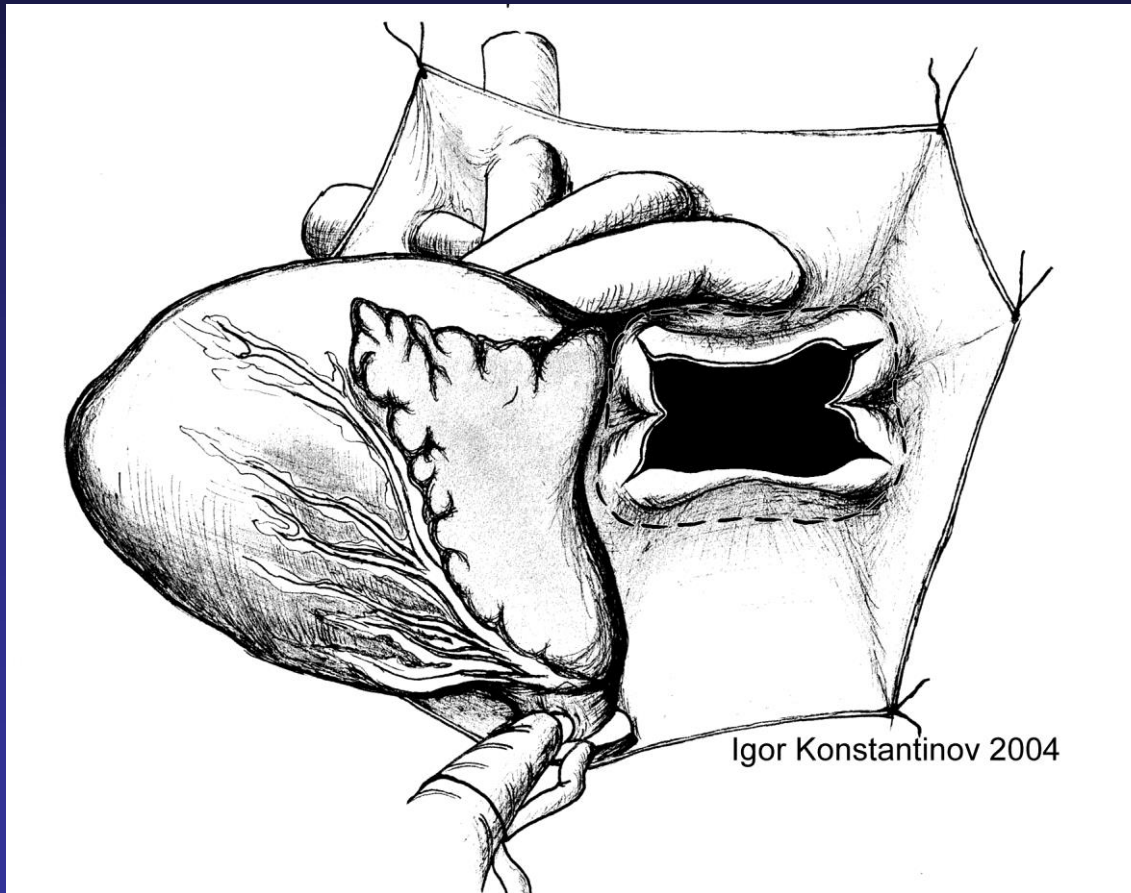
# Modified Coles procedure (primary sutureless repair)



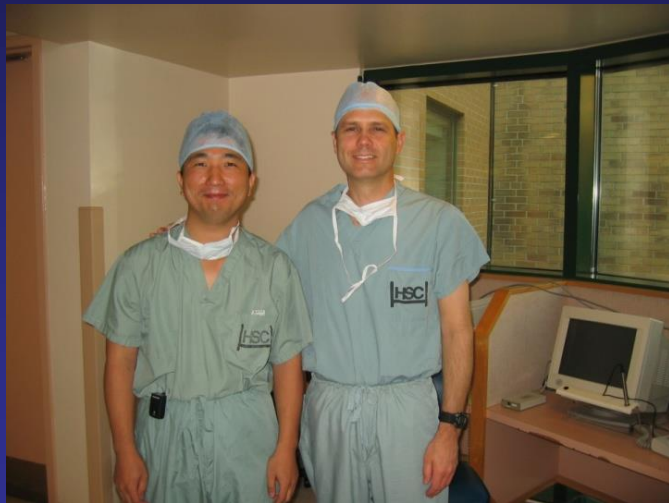# Modified Coles procedure (primary sutureless repair)



# Modified Coles procedure (primary sutureless repair)



# Contemporary management of RAI (Yun et al, JTCVS 2006)



## Contemporary management of right atrial isomerism: Effect of evolving therapeutic strategies

Tae-Jin Yun, MD,<sup>a</sup> Osman O. Al-Radi, MD,<sup>b</sup> Ian Adatia, MD,<sup>c</sup> Christopher A. Caldarone, MD,<sup>b</sup> John G. Coles, MD,<sup>b</sup> William G. Williams, MD,<sup>b</sup> Jeffrey Smallhorn, MD,<sup>b</sup> and Glen S. Van Arsdell, MD<sup>b</sup>



Earn CME credits at  
<http://cme.ctsnetjournals.org>

**Objectives:** Infants with right atrial isomerism have poor outcomes because of a complex combination of cardiac anomalies. Aggressive management of total anomalous pulmonary venous drainage might have a positive effect on the prognosis.

**Methods:** Outcomes of all children with right atrial isomerism from 1994 to the present were reviewed. Management of total anomalous pulmonary venous drainage evolved from no repair or conventional surgical technique to primary sutureless repair on initial palliation. Cox survival models were used to identify variables associated with reduced survival.

**Results:** There were 55 children enrolled in the study. The median age at the initial visit was 2 days. Fifty-one patients had total anomalous pulmonary venous drainage (obstructive in 22 patients). Withdrawal of treatment occurred in 11 (20%) of 55 patients during an interval of institutional bias toward no treatment. Thirteen (24%) of 55 patients had palliations without total anomalous pulmonary venous drainage repair, and 3 (23%) of 13 survived. Thirty-one (56%) of 55 patients had operations that included total anomalous pulmonary venous drainage repair, of whom 13 (42%) of 31 underwent primary sutureless repair for total anomalous pulmonary venous drainage. Sixteen (52%) of 31 survived, and their current status 1 to 10 years (median, 5.8 years) after repair is post-Fontan (7/16 [44%]), postbidirectional Glenn (6/16 [38%]), and others (3 [20%]). In patients who underwent total anomalous pulmonary venous drainage repair (n = 31), 2 risk factors of decreased survival were identified: drainage site obstruction and infracardiac or mixed-type total anomalous pulmonary venous drainage. After adjustment, sutureless repair appeared to be associated with improved survival (hazard ratio, 0.43), but this beneficial effect did not reach significance ( $P = .19$ ).

**Conclusions:** Mortality continues to be high; however, aggressive total anomalous pulmonary venous drainage repair for right atrial isomerism has resulted in improved survival. The role of primary sutureless repair for total anomalous pulmonary venous drainage remains to be defined.

# What to expect after repair of total anomalous pulmonary venous connection: data from 193 patients and 2902 patient years<sup>†</sup>

Jürgen Hörer<sup>a,\*</sup>, Caroline Neuray<sup>a</sup>, Manfred Vogt<sup>b</sup>, Julie Cleuziou<sup>a</sup>, Jelena Kasnar-Samprec<sup>c</sup>,  
Rüdiger Lange<sup>a</sup> and Christian Schreiber<sup>a</sup>

<sup>a</sup> Department of Cardiovascular Surgery, German Heart Center Munich at the Technical University, Munich, Germany

<sup>b</sup> Department of Pediatric Cardiology and Congenital Heart Disease, German Heart Center Munich at the Technical University, Munich, Germany

\* Corresponding author. Department of Cardiovascular Surgery, German Heart Center Munich at the Technical University, Lazarettstrasse 36, Munich D-80636, Germany. Tel: +49-8912-184111; fax: +49-8912-184123; e-mail: hoerer@dhm.mhn.de (J. Hörer).

Received 19 October 2012; received in revised form 3 January 2013; accepted 3 February 2013

---

## Abstract

**OBJECTIVES:** Total anomalous pulmonary venous connection (TAPVC) occurs as isolated cases, in combination with single ventricle physiology, and may be complicated by pulmonary venous obstruction. We sought to identify potential risk factors for long-term mortality and reoperations.

**METHODS:** Data from 193 consecutive patients who had undergone repair of TAPVC between 1974 and 2011 were analysed using multivariate Cox regression. Mean follow-up time was  $15.0 \pm 11.0$  years, 95% complete.

**RESULTS:** Survival was  $82.7 \pm 2.9\%$  at 20 years. Single ventricle physiology (5.9% of the patients,  $P < 0.001$ ) emerged as the only significant risk factor for mortality in multivariate analyses. Freedom from cardiac reoperation was  $82.2 \pm 3.3\%$  at 20 years. Single ventricle physiology ( $P < 0.001$ ) was the only risk factor for cardiac reoperations in multivariate analyses. Freedom from reoperations for pulmonary venous obstruction was  $90.4 \pm 2.5\%$  at 20 years. An age at operation of  $\leq 30$  days (52.8% of the patients,  $P = 0.007$ ) was the only risk factor for reoperations for pulmonary venous obstruction in univariate analyses. In patients with isolated TAPVC ( $n = 177$ ), preoperative pulmonary venous obstruction (53.7% of the patients,  $P = 0.030$ ) and deep hypothermic circulatory arrest (78.5% of the patients,  $P = 0.017$ ) emerged as risk factors for mortality in univariate analyses. An age at operation of  $\leq 30$  days (53.7% of the patients,  $P = 0.022$ ) was the only risk factor for reoperations for pulmonary venous obstruction in univariate analyses.

**CONCLUSIONS:** Survival into the third decade without reoperations is excellent in patients with isolated TAPVC without preoperative pulmonary venous obstruction, irrespective of the type of anomalous connection. In contrast, survival of patients with TAPVC and single ventricle physiology is among the poorest of all congenital heart defects. Reoperations for pulmonary venous obstruction are rare and are predominantly required in patients who were operated on as neonates. Survival may be improved by using a strategy of low-flow cardiopulmonary bypass.

**Keywords:** Congenital • Anomalous pulmonary venous return • Surgery • Long-term results • Total anomalous pulmonary venous connection

---

# Total Anomalous Pulmonary Venous Connection: An Analysis of Current Management Strategies in a Single Institution

Camille L. Hancock Friesen, MD, David Zurakowski, PhD, Ravi R. Thiagarajan, MD, Joseph M. Forbess, MD, Pedro J. del Nido, MD, John E. Mayer, MD, and Richard A. Jonas, MD

Departments of Cardiac Surgery, Cardiovascular Surgery, Cardiology, and Biostatistics, Children's Hospital Boston, Harvard Medical School, Boston, Massachusetts

**Background.** Repair of total anomalous pulmonary venous connection (TAPVC) continues to be associated with significant mortality. We reviewed patients undergoing consecutive TAPVC repairs over a 10-year period at Children's Hospital Boston. The impact of current surgical and perioperative management strategies on short-term outcomes (postrepair pulmonary venous obstruction and mortality) is evaluated.

**Methods.** All patients with surgically corrected TAPVC from November 1989 to December 2000 were included. Charts were reviewed for patient demographics, operation variables, and postoperative course.

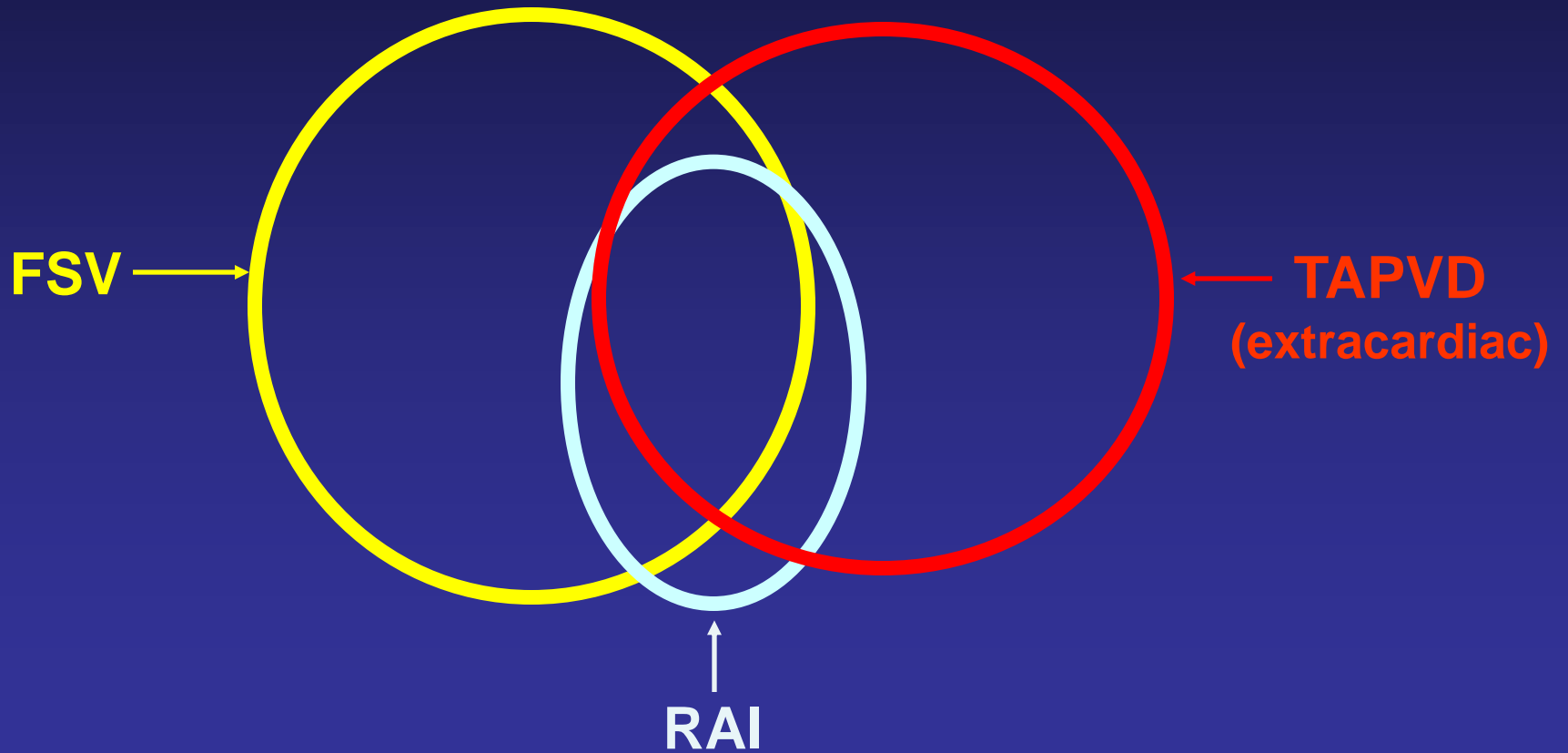
**Results.** There were 123 patients in the cohort, of which 72 (59%) were male. The median age and weight at operation were 10 days and 3.6 kg, respectively. Sixty-eight (55%) patients presented with pulmonary venous obstruction, and 65 (53%) underwent emergent TAPVC repair. Thirty-nine (32%) had single-ventricle anatomy, and 84 (68%) had two-ventricle anatomy. Thirty patients

(24%) died. Kaplan-Meier survival at 1 month was 65% (95% confidence interval [CI], 55% to 75%) for single-ventricle patients versus 90% (95% CI, 90% to 100%) for two-ventricle patients; at 36 months it was 47% (95% CI, 35% to 59%) versus 87% (95% CI, 81% to 93%), respectively. By Cox multivariable regression analysis, a single ventricle ( $p < 0.001$ , hazard ratio, 4.8; 95% CI, 2.5 to 9.2) was an independent mortality risk factor. Prerepair pulmonary venous obstruction was a multivariate risk factor for death among single-ventricle patients. Postrepair pulmonary venous obstruction occurred in 11%. If year of operation is used as a predictor, two-ventricle patient survival has significantly improved ( $p < 0.05$ ).

**Conclusions.** Despite current interventions, single-ventricle patients continue to have a worse prognosis than two-ventricle patients.



# Functional SV, TAPVD and RAI

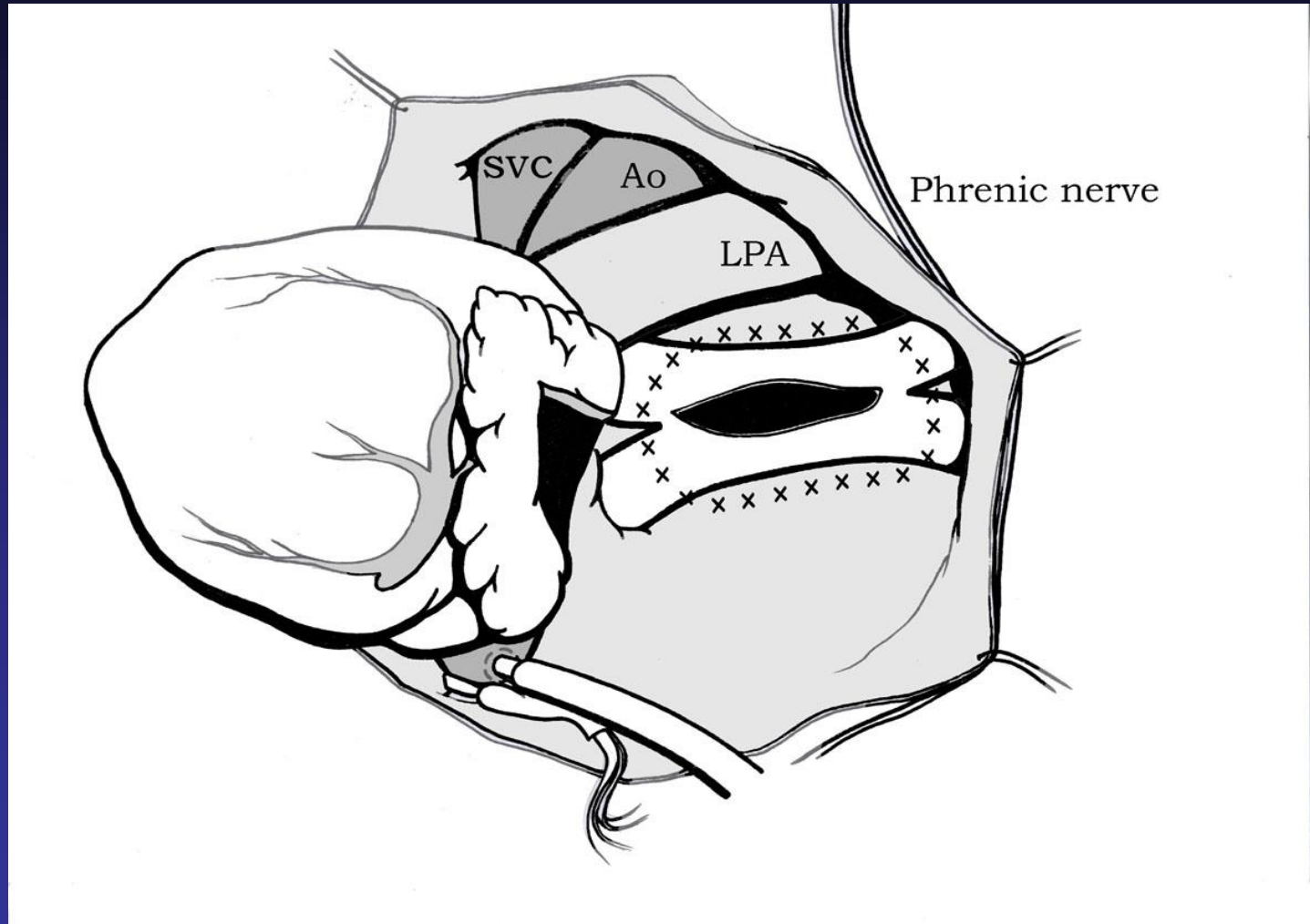


# **Sutureless repair for RAI / TAPVD**

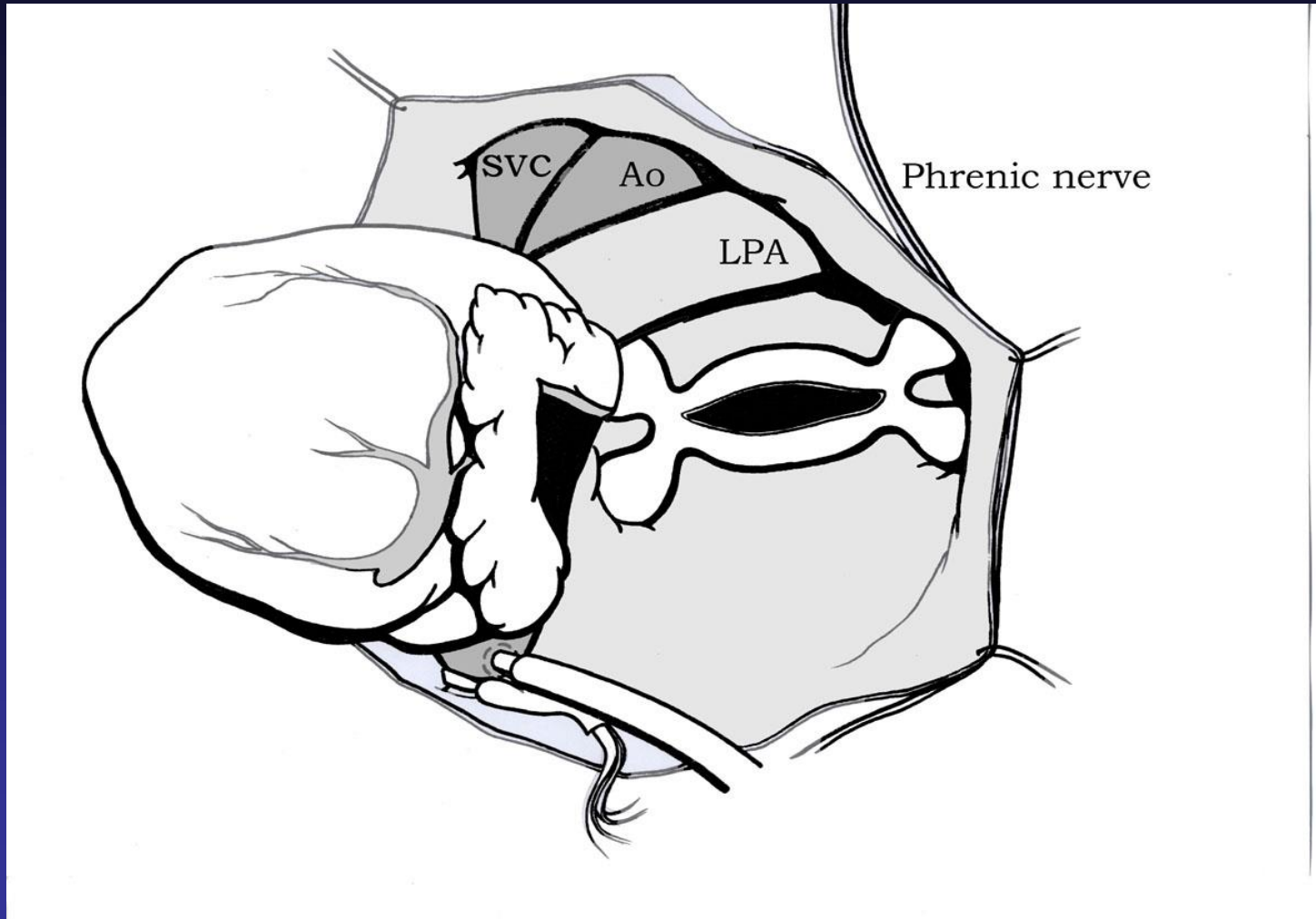
- potential benefits-

- **Inherently small confluence and PVS**
- **Unfavorable PV morphology**
- **CPVC / PVs buried in post. mediastinum**

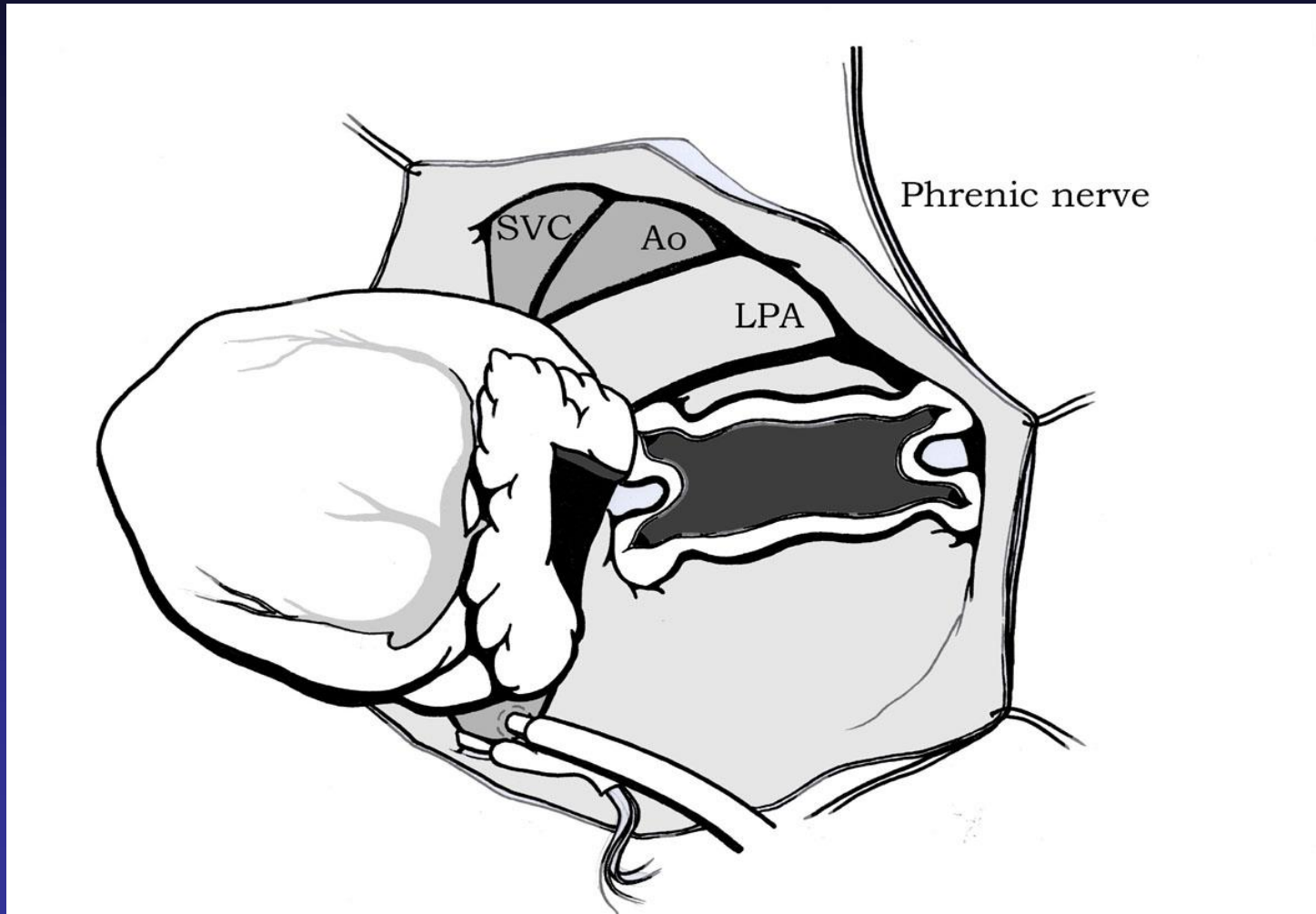
# 1<sup>st</sup> sutureless repair



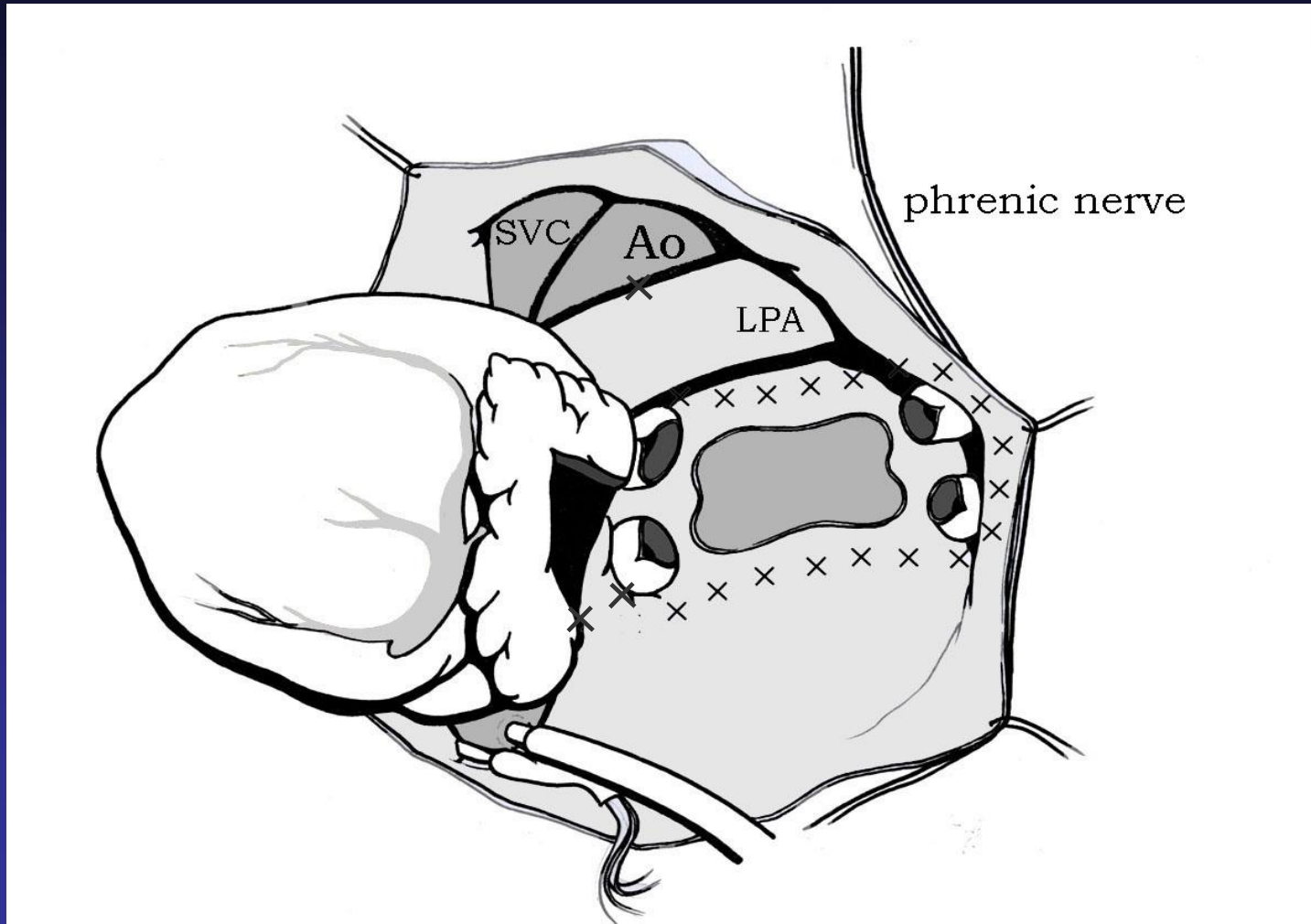
# 2<sup>nd</sup> sutureless repair



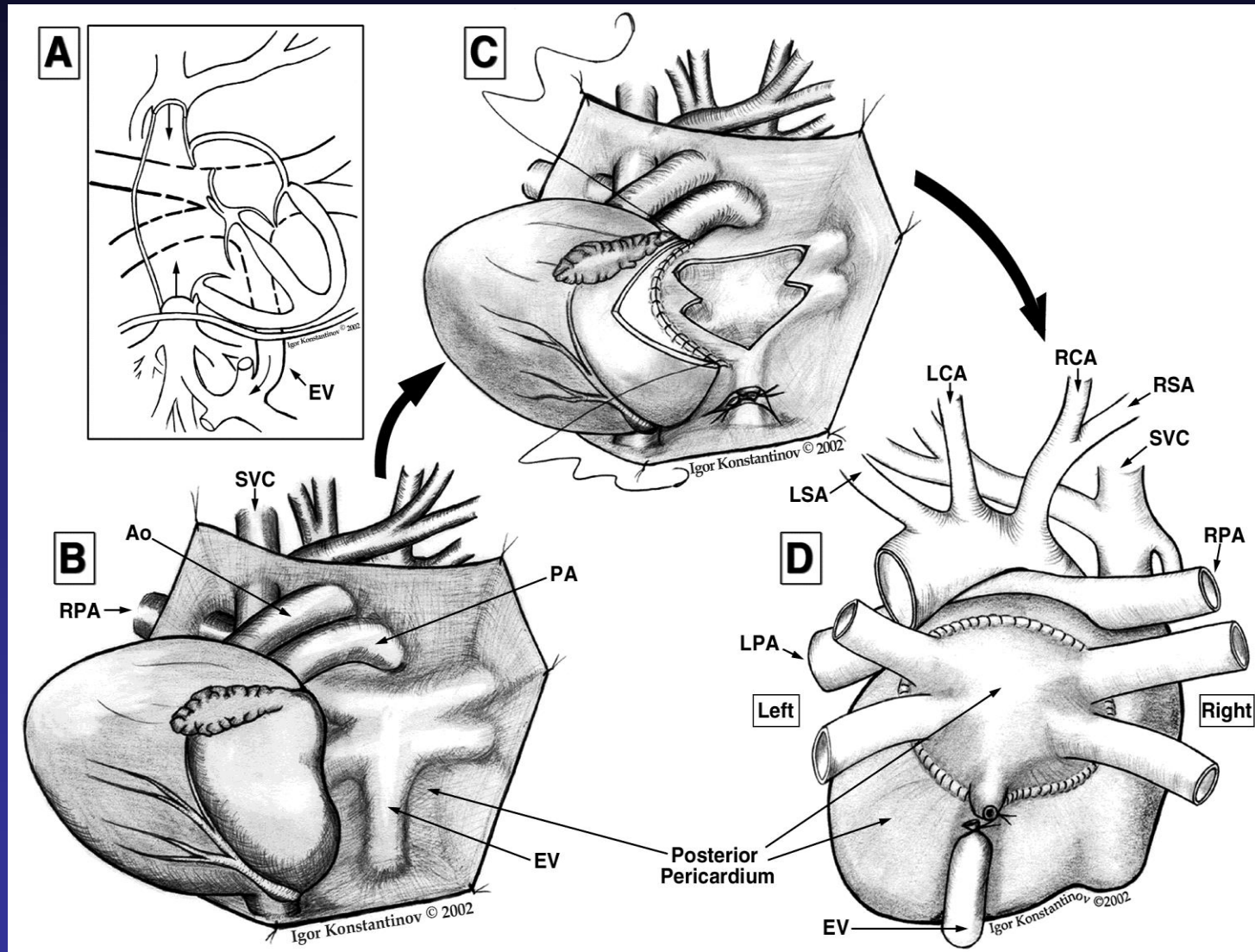
# 2<sup>nd</sup> sutureless repair



# 2<sup>nd</sup> sutureless repair



# Posteriorly located PVs in RAI



# Retrobronchial Vertical Vein in RAI

## Retrobronchial Vertical Vein in Totally Anomalous Pulmonary Venous Connection to the Innominate Vein and Its Specific Occurrence in Right Isomerism

Shi-Joon Yoo, MD, David G. Nykanen, MD, Robert M. Freedom, MD, Leland N. Benson, MD, C. A. Frederic Moes, MD, and Patricia E. Burrows, MD

Recently, a case of right isomerism with totally anomalous pulmonary venous connection (TAPVC) to the innominate vein through a vertical vein that ascended in the mediastinum posterior to the left-sided main bronchus was encountered. This retrobronchial vertical vein that has not been described previously in patients with TAPVC to the innominate vein prompted the performance of a retrospective analysis of 44 cases with TAPVC to the innominate vein in which angiography had been performed. The 44 cases consisted of 36 patients with situs solitus, 7 with right isomerism, and 1 with left isomerism. The spatial relation of the vertical vein to the adjacent pulmonary artery and main bronchus could be defined in 41 cases. The vertical vein was retrobronchial in 4 of 5 cases with right isomerism in which the location of the vertical vein could be defined with certainty. No case with situs solitus or left isomerism was associated with a retrobronchial vertical vein. In all 4 patients with a retrobronchial vertical vein, angiographic evidence of obstruction of pulmonary venous drainage was present, and was due to an extrinsic bronchial compression in 2 and to an intrinsic narrowing of the vertical vein in 2.

(Am J Cardiol 1993;71:1198-1203)

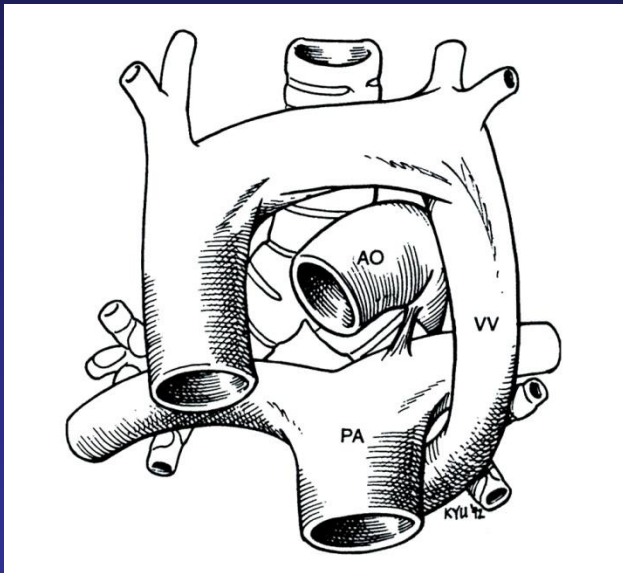
In patients with totally anomalous pulmonary venous connection (TAPVC) to the innominate vein, the pulmonary venous confluence is formed behind the left atrium and is connected to the innominate vein through an ascending channel that is called a "vertical vein."<sup>1-8</sup> In patients with situs solitus, the vertical vein usually ascends through an anterolateral angle formed as the left pulmonary artery crosses over the left main stem bronchus (Figure 1). In some cases, the vertical vein passes through a narrow triangular space that is bounded by the left pulmonary artery anterolaterally, the ligamentous or patent ductus arteriosus medially and the left main bronchus posteroinferiorly (Figure 2). This spatial arrangement results in extrinsic compression of the vertical vein and has been referred to as a "hemodynamic vise."<sup>7</sup> In patients with situs inversus, there is a mirror-image bronchovascular spatial relation. In patients with right isomerism, neither the right- nor the left-sided pulmonary artery crosses over the main bronchus,<sup>9,10</sup> and a different spatial relation of the vertical vein to the adjacent pulmonary artery and main stem bronchus may be expected.

Recently, we encountered a case of right isomerism with TAPVC to the innominate vein in which the left vertical vein was retrobronchial (i.e., it ascended in the mediastinum posterior to the left-sided main bronchus) (Figure 3). The vertical vein was displaced and appeared externally compressed by the left-sided main stem

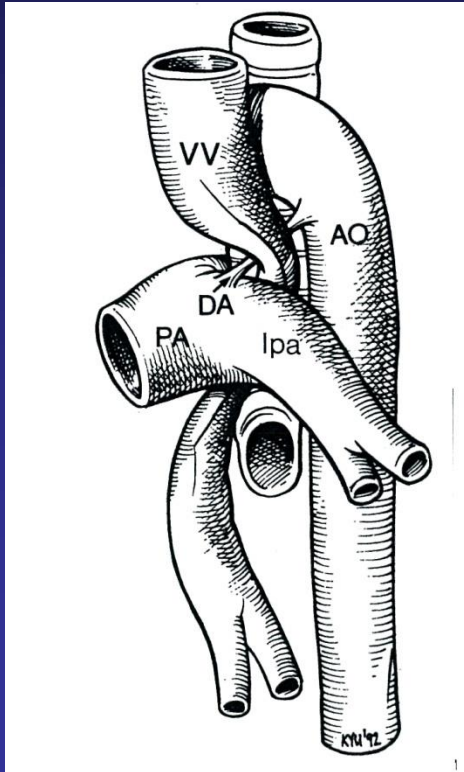


# Retrobronchial Vertical Vein in RAI

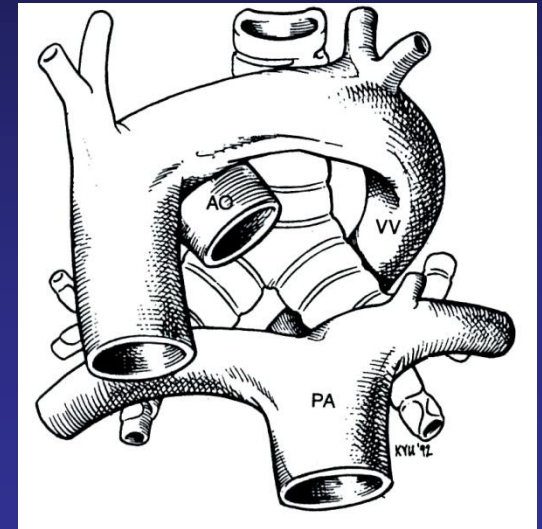
**Pre-arterial**



**Retro-arterial  
Pre-bronchial**

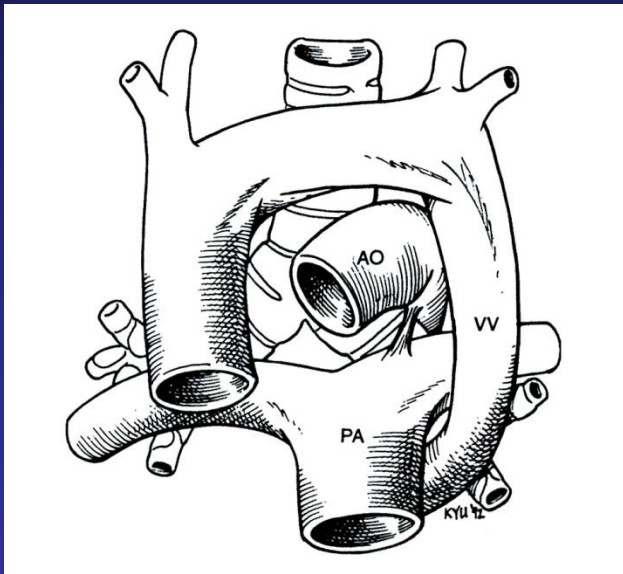


**Retrobronchial**



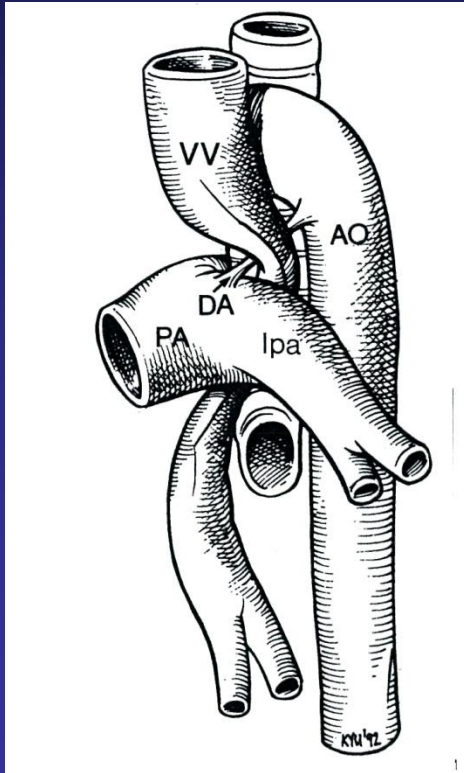
# Retrobronchial Vertical Vein in RAI (AMC experience)

**Pre-arterial**



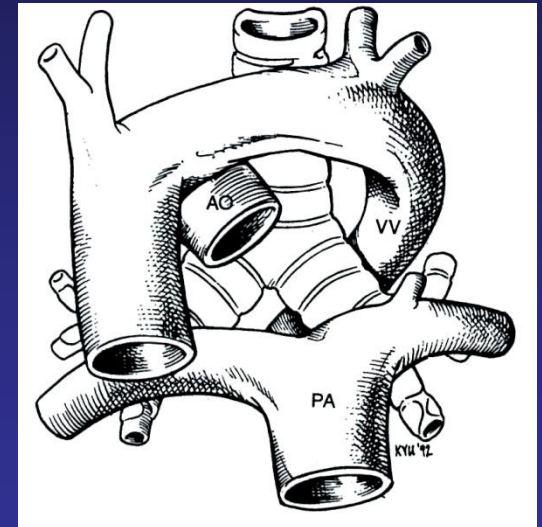
**N=2 (2/9)**

**Retro-arterial  
Pre-bronchial**



**N=2 (2/9)**

**Retrobronchial**



**N=5 (5/9)**

## Work in progress report - Congenital Sutureless pericardial repair of total anomalous pulmonary venous connection in patients with right atrial isomerism<sup>☆</sup>

Naoki Yoshimura<sup>a,\*</sup>, Yoshihiro Oshima<sup>b</sup>, Roland Henaine<sup>c</sup>, Hironori Matsuhisa<sup>b</sup>

<sup>a</sup>First Department of Surgery, University of Toyama, Graduate School of Medicine, 2630 Sugitani, 930-0194, Toyama, Japan

<sup>b</sup>Department of Cardiovascular Surgery, Kobe Children's Hospital, Kobe, Japan

<sup>c</sup>Department of Cardiovascular Surgery and Cardiac Transplantation, Hôpital Cardiovasculaire et pneumologique Louis Pradel, Lyon, France

Received 10 September 2009; received in revised form 1 February 2010; accepted 3 February 2010

---

### Abstract

Surgical repair of total anomalous pulmonary venous connection (TAPVC) in patients with right atrial isomerism is associated with a significant risk of recurrent pulmonary venous obstruction (PVO). We evaluate the effect of sutureless repair to reduce the risk of recurrent PVO. Since November 2007, five patients, including three neonates, with right atrial isomerism underwent sutureless repair of TAPVC. The sutureless repair was used in three neonates as an initial procedure and in two infants as a procedure for postrepair PVO. Under deep hypothermic circulatory arrest or low flow cardiopulmonary bypass, pulmonary vein (PV) was incised as long as possible. The atrial wall was partially resected and anastomosed to the pericardial wall around the incised PV. There were no early deaths. No patients showed recurrence of PVO. There was one late death. Two patients underwent a bidirectional Glenn shunt after the sutureless repair. The pulmonary venous confluence was confirmed to be left open at the time of the Glenn surgery. The sutureless technique may be useful not only for postrepair PVO but also for non-operated TAPVC in neonates with right atrial isomerism.

© 2010 Published by European Association for Cardio-Thoracic Surgery. All rights reserved.

**Keywords:** Right atrial isomerism; Total anomalous pulmonary venous connection; Sutureless pericardial repair

---

### 1. Introduction

Despite improvements in the treatment of complex congenital heart disease, right atrial isomerism associated with

reless pericardial repair of TAPVC at Toyama University Hospital (Table 1). The parents of the patients gave written informed consent before the operation. The anatomical

# Early Outcomes of Primary Sutureless Repair of the Pulmonary Veins

Anthony Azakie, MD, Michael J. Lavrsen, MD, Natalie C. Johnson, BS, and Anil Sapru, MD

UCSF Benioff Children's Hospital, Department of Surgery and Department of Pediatrics, University of California-San Francisco, San Francisco, California; and Department of Surgery, Oregon Health Sciences University, Portland, Oregon

*Background.* The "sutureless" repair technique has improved outcomes for post-repair pulmonary vein (PV) stenosis. The purpose of this study is to determine the early outcomes of primary sutureless repair of pulmonary venoocclusive disease in infants with congenital PV stenosis-hypoplasia or PVs at high risk for progressive stenosis.

*Methods.* This is a retrospective review of infants who had primary sutureless repair of the PVs from October 2002 to April 2010.

*Results.* Twenty-five infants had primary sutureless repair of the PVs. Eighteen infants had total anomalous pulmonary venous return; 14 with obstruction, 10 with heterotaxy syndrome, and 9 with univentricular anatomy. Seven infants had congenital PV stenosis. There were 24 perioperative survivors (96%; 95% confidence interval [CI], 75% to 99%) and 2 late deaths from extracardiac causes. Follow-up was available on 21 out of 22 survivors at a median duration of 34 months (range, 9 to 100 months). Persistence-recurrence of PV stenosis occurred

in 3 veins (3%) of 2 infants (8%). On follow-up echocardiography, right ventricular systolic pressure was normal in 13 out of 14 infants with a biventricular heart and 60% of systemic blood pressure in 1 infant. Kaplan-Meier 1-year cumulative survival was 88% (95% CI, 66% to 96%). Kaplan-Meier cumulative disease-free survival was 96% (95% CI, 75% to 99%) at 30 days and 84% (95% CI, 58% to 95%) at 1 year. By Cox proportional hazards, age, univentricular anatomy, and atrial isomerism-heterotaxy syndrome were not associated with an increased risk of death or persistence-recurrence. One-year disease-free survival was lower in infants with prematurity ( $p = 0.0055$ ) and low birth weight ( $p = 0.0011$ ).

*Conclusions.* Primary sutureless repair is a feasible, safe, and relatively effective method of addressing congenital PV stenosis and (or) high-risk PVs, particularly in infants with single ventricle anatomy and (or) heterotaxy syndrome.

(Ann Thorac Surg 2011;92:666-72)

© 2011 by The Society of Thoracic Surgeons

# Primary correction of total anomalous pulmonary venous return with a modified sutureless technique

Christoph Mueller, Hitendu Dave\* and René Prêtre

Department of Congenital Cardiovascular Surgery, University Children's Hospital Zurich, Zurich, Switzerland

\* Corresponding author. Department of Congenital Cardiovascular Surgery, University Children's Hospital Zurich, Steinwiesstrasse 75, 8032 Zurich, Switzerland.  
Tel: +41-44-2668002; fax: +41-44-2668021; e-mail: hitendudave@kispi.uzh.ch, hitendu@hotmail.com (H. Dave).

Received 12 April 2012; received in revised form 17 May 2012; accepted 22 May 2012

## Abstract

**OBJECTIVES:** The objective was to evaluate primary sutureless repair of total anomalous pulmonary venous return (TAPVR) in neonates using a modified technique that minimizes hypothermia and circulatory arrest times.

**METHODS:** From 2009 to 2011, seven consecutive patients underwent primary sutureless repair for the treatment of TAPVR, by which the prepared posterior pericardium was sutured to an opening in the left atrium. Three patients had the obstructed infracardiac type, and four patients had the unobstructed supracardiac type of TAPVR. Moderate hypothermia was used in all patients with a median temperature of 28°C (26–32). Circulatory arrest was not used except for the opening of the collector, which lasted between 3 and 5 min. The connecting vein was ligated in all seven patients (five during repair and two early postoperatively). The follow-up was 100% complete, with a median duration of 652 (range 370–1023) days.

**RESULTS:** There was no operative mortality and no late death. No patient required reoperation. Postoperative echocardiography showed unobstructed pulmonary venous flow in all patients. Recurrent pulmonary venous stenosis was not seen during the follow-up in any patient.

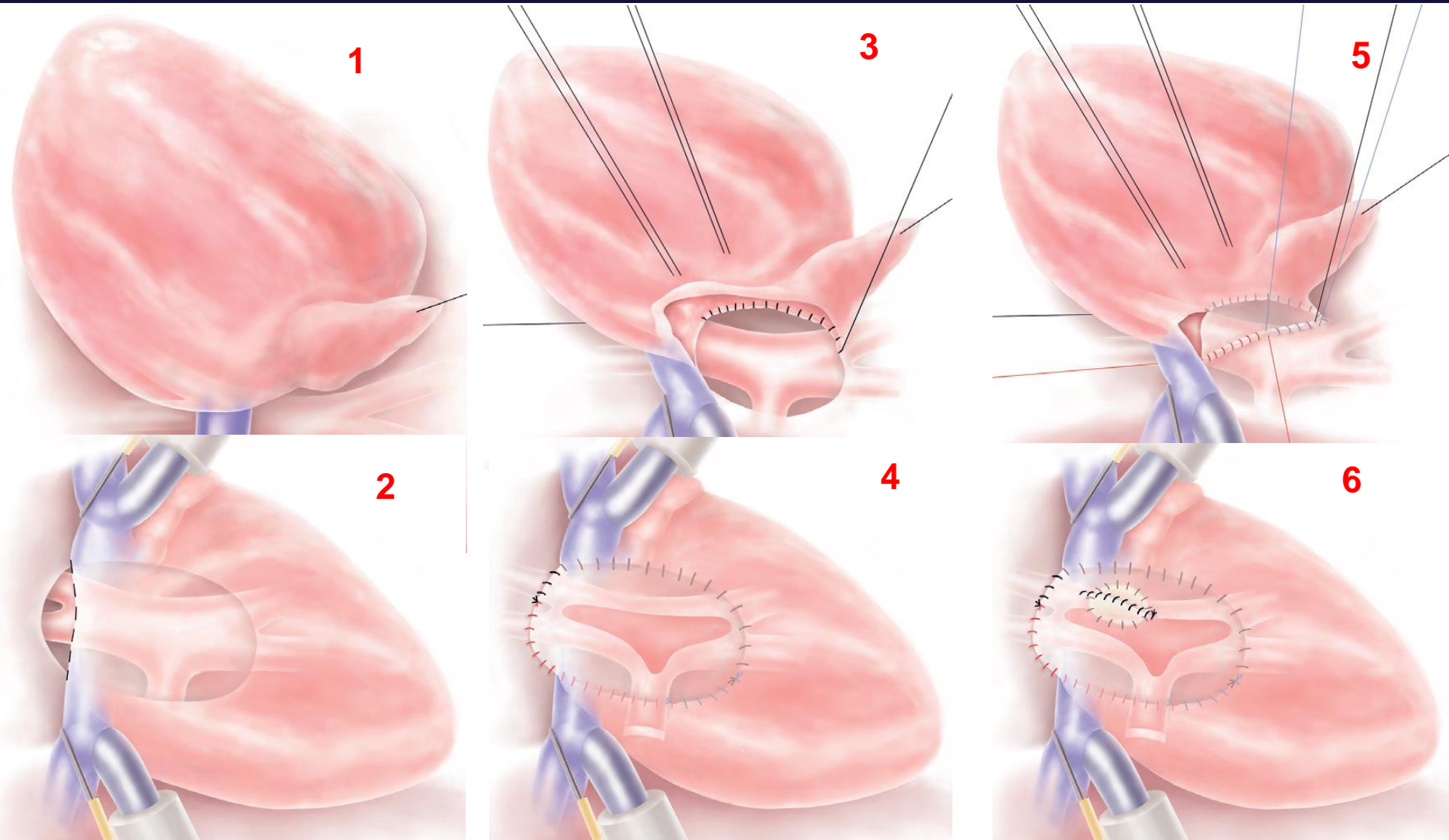
**CONCLUSIONS:** The sutureless technique is an effective technique with potential advantages even for the primary correction of TAPVR. With the described technique, the need for circulatory arrest is substantially reduced. Not handling the pulmonary venous collector by avoiding a direct anastomosis may contribute to better compliance, better growth and the absence of subsequent stenosis.

**Keywords:** Congenital cyanotic heart disease • Pulmonary venous obstruction • Total anomalous pulmonary venous return • Total anomalous pulmonary venous connection • Sutureless repair • Pulmonary hypertension

# Primary correction of total anomalous pulmonary venous return with a modified sutureless technique

Christoph Mueller, Hitendu Dave\* and René Prêtre

Department of Congenital Cardiovascular Surgery, University Children's Hospital Zurich, Zurich, Switzerland



# What to expect after repair of total anomalous pulmonary venous connection: data from 193 patients and 2902 patient years<sup>†</sup>

Jürgen Hörer<sup>a,\*</sup>, Caroline Neuray<sup>a</sup>, Manfred Vogt<sup>b</sup>, Julie Cleuziou<sup>a</sup>, Jelena Kasnar-Samprec<sup>c</sup>,  
Rüdiger Lange<sup>a</sup> and Christian Schreiber<sup>a</sup>

<sup>a</sup> Department of Cardiovascular Surgery, German Heart Center Munich at the Technical University, Munich, Germany

<sup>b</sup> Department of Pediatric Cardiology and Congenital Heart Disease, German Heart Center Munich at the Technical University, Munich, Germany

\* Corresponding author. Department of Cardiovascular Surgery, German Heart Center Munich at the Technical University, Lazarettstrasse 36, Munich D-80636, Germany. Tel: +49-8912-184111; fax: +49-8912-184123; e-mail: hoerer@dhm.mhn.de (J. Hörer).

Received 19 October 2012; received in revised form 3 January 2013; accepted 3 February 2013

---

## Abstract

**OBJECTIVES:** Total anomalous pulmonary venous connection (TAPVC) occurs as isolated cases, in combination with single ventricle physiology, and may be complicated by pulmonary venous obstruction. We sought to identify potential risk factors for long-term mortality and reoperations.

**METHODS:** Data from 193 consecutive patients who had undergone repair of TAPVC between 1974 and 2011 were analysed using multivariate Cox regression. Mean follow-up time was  $15.0 \pm 11.0$  years, 95% complete.

**RESULTS:** Survival was  $82.7 \pm 2.9\%$  at 20 years. Single ventricle physiology (5.9% of the patients,  $P < 0.001$ ) emerged as the only significant risk factor for mortality in multivariate analyses. Freedom from cardiac reoperation was  $82.2 \pm 3.3\%$  at 20 years. Single ventricle physiology ( $P < 0.001$ ) was the only risk factor for cardiac reoperations in multivariate analyses. Freedom from reoperations for pulmonary venous obstruction was  $90.4 \pm 2.5\%$  at 20 years. An age at operation of  $\leq 30$  days (52.8% of the patients,  $P = 0.007$ ) was the only risk factor for reoperations for pulmonary venous obstruction in univariate analyses. In patients with isolated TAPVC ( $n = 177$ ), preoperative pulmonary venous obstruction (53.7% of the patients,  $P = 0.030$ ) and deep hypothermic circulatory arrest (78.5% of the patients,  $P = 0.017$ ) emerged as risk factors for mortality in univariate analyses. An age at operation of  $\leq 30$  days (53.7% of the patients,  $P = 0.022$ ) was the only risk factor for reoperations for pulmonary venous obstruction in univariate analyses.

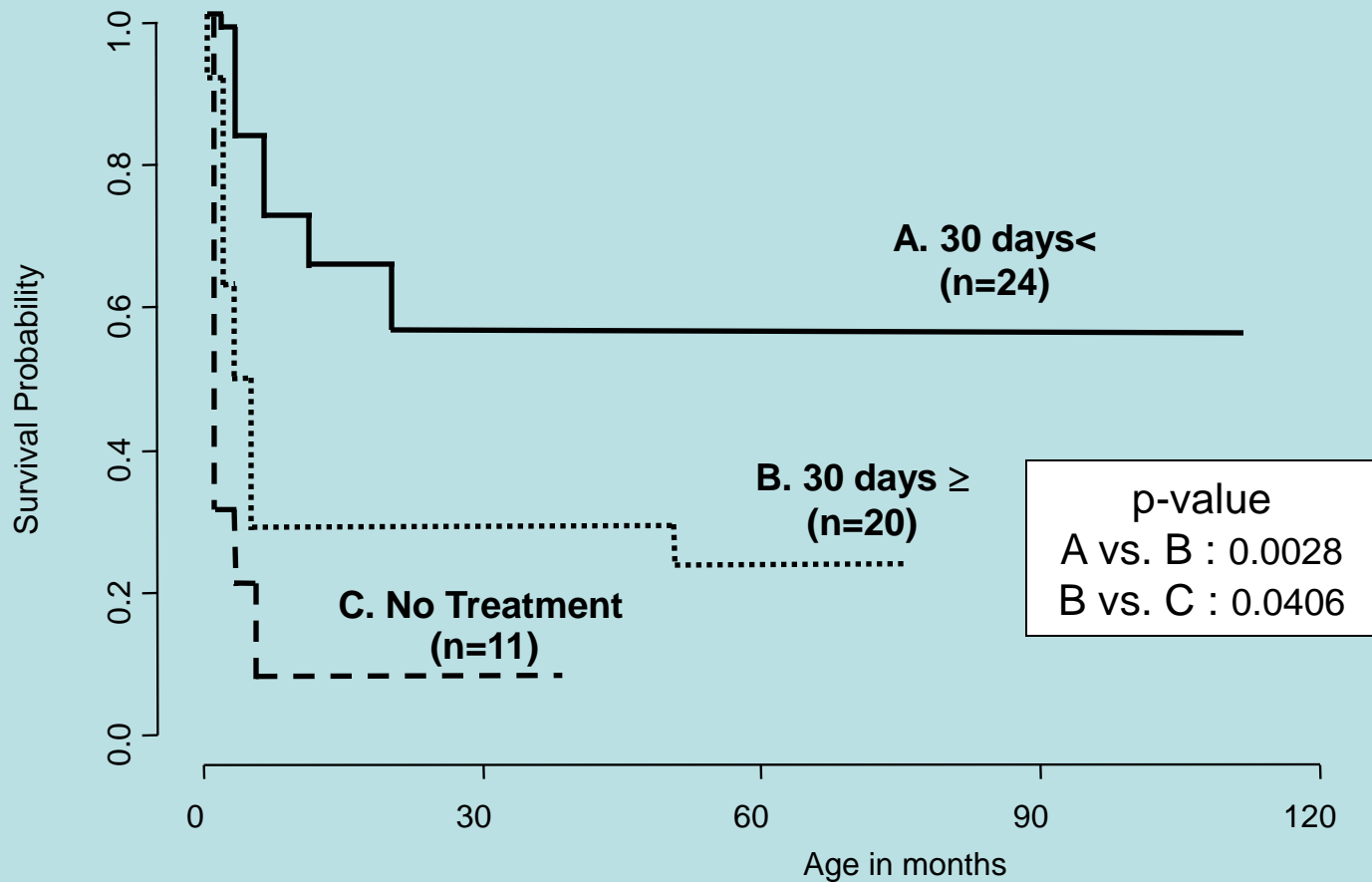
**CONCLUSIONS:** Survival into the third decade without reoperations is excellent in patients with isolated TAPVC without preoperative pulmonary venous obstruction, irrespective of the type of anomalous connection. In contrast, survival of patients with TAPVC and single ventricle physiology is among the poorest of all congenital heart defects. Reoperations for pulmonary venous obstruction are rare and are predominantly required in patients who were operated on as neonates. Survival may be improved by using a strategy of low-flow cardiopulmonary bypass.

**Keywords:** Congenital • Anomalous pulmonary venous return • Surgery • Long-term results • Total anomalous pulmonary venous connection

---

# Contemporary management of RAI

(Yun et al, JTCVS 2006)





## Long-term results of treatments for functional single ventricle associated with extracardiac type total anomalous pulmonary venous connection

Takaya Hoashi<sup>a\*</sup>, Koji Kagisaki<sup>a</sup>, Tatsuya Oda<sup>a</sup>, Masataka Kitano<sup>b</sup>, Kenichi Kurosaki<sup>b</sup>, Isao Shiraishi<sup>b</sup>,  
Toshikatsu Yagihara<sup>a</sup> and Hajime Ichikawa<sup>a</sup>

<sup>a</sup> Department of Pediatric Cardiovascular Surgery, National Cerebral and Cardiovascular Center, Suita, Osaka, Japan

<sup>b</sup> Department of Pediatric Cardiology, National Cerebral and Cardiovascular Center, Suita, Osaka, Japan

\* Corresponding author. Department of Pediatric Cardiovascular Surgery, National Cerebral and Cardiovascular Center, 5-7-1, Fujishirodai, Suita, Osaka 565-8565, Japan. Tel: +81-6-68335012; fax: +81-6-68727486; e-mail: thoashi@surg1.med.osaka-u.ac.jp (T. Hoashi)

Received 14 July 2012; received in revised form 7 September 2012; accepted 16 September 2012

### Abstract

**OBJECTIVES:** Surgical outcomes of patients with functional single ventricle have improved, though those for patients whose condition is complicated by extracardiac type total anomalous pulmonary venous connection (TAPVC) remain poor. We retrospectively reviewed our 21 years of surgical experiences with this challenging group.

**METHODS:** From 1990 to 2010, 48 consecutive patients with functional single ventricle complicated by extracardiac TAPVC (26 males, 46 with right atrial isomerism) underwent initial surgical palliation at our centre. The median age and body weight at surgery were 69 days and 3.5 kg, respectively. The type of TAPVC was supracardiac in 31 patients, infracardiac in 14 and mixed type in 3. TAPVC was repaired in 25 patients before bidirectional Glenn (BDG) and 18 at BDG, while it remained in 3 patients. Since 2007, stent implantation for obstructive drainage veins for patients with preoperative pulmonary venous obstruction and sutureless marsupialization for relief of postoperative pulmonary venous stenosis (PVS) have been initiated. The mean follow-up period was  $4.2 \pm 5.1$  years.

**RESULTS:** The overall survival rates at 1, 3 and 5 years after the initial surgical intervention were 58.3, 41.1 and 31.3%, respectively. Sixteen patients achieved the Fontan operation (33.3%). The freedom from postoperative PVS rates at 1 and 3 years after repair was 68.7 and 63.4%, respectively. Univariate analysis detected that infracardiac TAPVC ( $P=0.036$ ), coexisting major aortopulmonary collaterals ( $P=0.017$ ), and TAPVC repair before BDG ( $P=0.036$ ) all reduced survival, and multivariable analysis indicated the repair of TAPVC before BDG as the only risk factor ( $P=0.032$ ). Whereas the occurrence of postoperative PVS did not reduce survival, which had a significant negative impact on achieving the Fontan operation ( $P=0.008$ ). The cumulative survival rate did not improve by surgical era.

**CONCLUSIONS:** Surgical outcomes of patients with functional single ventricle undergoing the repair of extracardiac TAPVC in the neonatal period due to obstruction of the venous drainage pathway remain poor. Stent implantation for obstructive drainage veins to delay the timing of surgical correction and sutureless marsupialization as relief of postoperative PVS are expected to improve the late outcomes; however, the effect is still limited.

**Keywords:** Heterotaxy • Total anomalous pulmonary venous connection • Single ventricle • Sutureless technique

## Case Reports

# Preoperative Balloon Dilatation of Obstructed Total Anomalous Pulmonary Venous Connection in a Neonate

Sivasubramanian Ramakrishnan, MD, and Shyam Sunder Kothari,\* MD

Prompt recognition and early surgical correction are mandatory in neonates presenting with obstructed total anomalous pulmonary venous connection (TAPVC). Preoperative balloon angioplasty of obstructed TAPVC in a sick neonate is rarely reported. We describe successful short-term palliation with balloon angioplasty of a critically ill neonate with obstructed supracardiac TAPVC. *Catheter Cardiovasc Interv* 2004;61:128–130.

© 2004 Wiley-Liss, Inc.

**Key words:** angioplasty; pulmonary vein stenosis

### INTRODUCTION

Obstructed total anomalous pulmonary venous connection (TAPVC) commonly presents in the first few days of life. Prompt recognition and early surgical correction are mandatory. The reported early operative mortality of TAPVC repair in the current era is 5–8% [1,2]. However, the operative mortality in a critically ill neonate is likely to be higher. Hence, measures directed at preoperative stabilization, if feasible, may be worthwhile before corrective surgery. Preoperative balloon angioplasty of obstructed TAPVC is rarely reported [3–6]. We describe successful short-term palliation with balloon angioplasty of a critically ill neonate with obstructed supracardiac TAPVC.

### CASE REPORT

A 36-hr-old full-term neonate (2.5 kg) had presented with central cyanosis, severe hypoxia, metabolic acidosis (pH 7.29; PCO<sub>2</sub>, 22.2 mm Hg; HCO<sub>3</sub>, 14.1 mEq/lit) and pulmonary edema. Cyanosis did not improve by ventilation with 100% oxygen (PO<sub>2</sub>, 37.2 mm Hg; SaO<sub>2</sub>, 58%). Peripheral pulses were feeble, and the blood pressure was 46/28 mm Hg on high doses of inotropes, including adrenaline, dopamine, and dobutamine. There was oliguria nonresponsive to fluid challenge. On auscultation, there was split second heart sound and no murmurs. There were diffuse crepitations over both the lung fields and 6 cm hepatomegaly. The chest radiograph showed normal cardiac silhouette with bilateral interstitial pulmonary edema. The electrocardiogram showed right axis

deviation and right ventricular hypertrophy. The echocardiogram revealed a secundum atrial septal defect shunting from right to left and evidence of pulmonary artery hypertension. The pulmonary veins were very small in caliber and were joining an ascending vein of 2.6 mm in size, which was draining into the superior vena cava. There was high-velocity turbulent continuous flow detected at the site of entry into the superior vena cava. The hematological and biochemical investigations were unremarkable except for unconjugated hyperbilirubinemia (serum bilirubin, 9.2 mg/dl). The patient did not improve despite aggressive correction of acidosis, inotropic support, and mechanical ventilation. In view of the poor clinical condition, the patient was perceived to have very high surgical risks that were unacceptable to the parents. Hence, it was planned to catheterize and dilate the obstruction if feasible as a desperate measure.

A written informed consent was obtained for the procedure. The right femoral venous approach (6 Fr) was used. The ascending vein was hooked with a 4 Fr Cobra catheter. Angiography confirmed the diagnosis of supra-

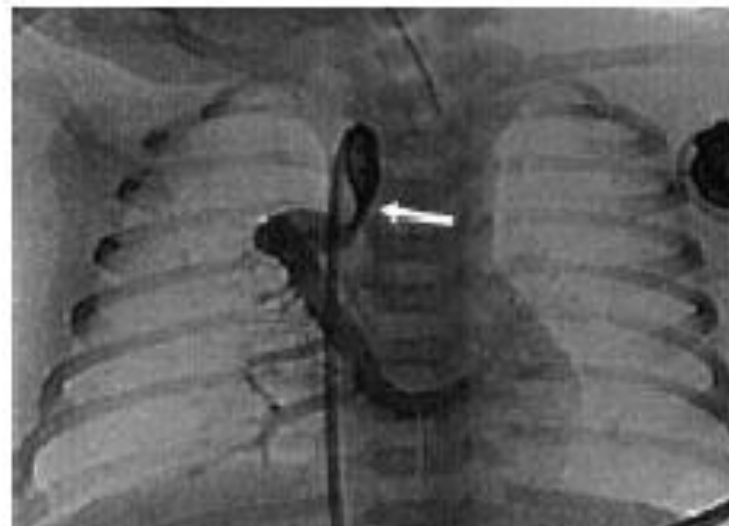Department of Cardiology, All India Institute of Medical Sciences, New Delhi, India

\*Correspondence to: Dr. Shyam Sunder Kothari, Department of Cardiology, All India Institute of Medical Sciences, New Delhi 110029, India. E-mail: kotharis@del2.vsnl.net.in

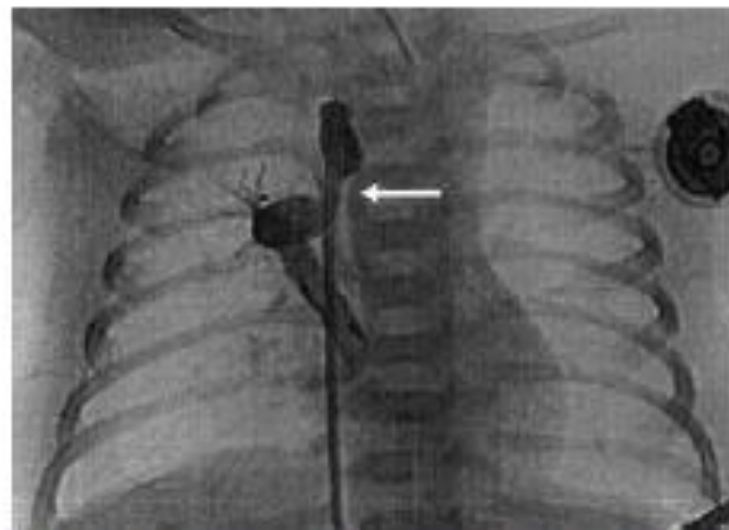Received 27 January 2003; Revision accepted 25 August 2003

DOI 10.1002/ccd.10718

Published online in Wiley InterScience (www.interscience.wiley.com).



**Fig. 1.** Angiogram in anteroposterior view showing all the pulmonary veins joining an ascending vein that is draining into superior vena cava. There is tight stenosis (indicated by the arrowhead) at the site of entry of ascending vein into the superior vena cava.



**Fig. 2.** Angiogram in anteroposterior view following balloon dilatation showing significant relief of obstruction.

TABLE I. Palliative Transcatheter Interventional Procedures for Obstructed Total Anomalous Pulmonary Venous Connection

TAPVC detail	Obstruction site	Other cardiac diagnosis	Present condition	Age	Wt (kg)	GA (wks)	Sheath	SpO2 (%)		Pulmonary venous pressure (mmHg)		Gradient at obstructed TAPVC (mmHg)		Vessel (mm)		Stent	Outcome			Ref	
								Pre	Post	Pre	Post	Pre	Post	Narrow	NL		Complication	TAPVC repair	Last followup		
<b>Stent Supracardiac</b>																					
1	VV to RSVC	Superior aspect of VV	DORV, PA, AVSD <sup>a</sup>	Cyanosis	9 d	1.4	32	4Fr RFV	40	95	45	12	33	NA	2.5	4	4 mm x 12 mm Guidant coronary stent (Vision)	CPR	None	Palliative care	Our case
2	VV to innominate V	VV at the level of L mainstem bronchus	None	Intubation, ECMO	18 h	2.8	Full term	5Fr LFV	NA	NA	38	16	28	2	1.7	6	Premounted 6–15 mm Palmaz Genesis stent	None	14 d after stent	Went home 13d after surgery	3
3	VV to innominate V	Midportion of VV	PDA	Intubation, MOF	6 w	NA	NA	6Fr LFV	70	92	44	NA	36	0	1.7	4.3–5.4	6 mm x 18 mm Cordis Genesis stent	None	1 w after stent	9 mo, doing well	4
4	VV to innominate V	VV at the level of LPA	None	CPR	1 w	NA	NA	6Fr RFV	66	88	NA	NA	NA	NA	Pinpoint	4	4 mm x 12 mm coronary stent (Driver)	None	1 d after stent	18 mo, doing well	5
5	VV to innominate V	VV at the level of LPA	None	Resp distress	4 w	NA	NA	NA	85	NA	22	NA	16	4	4	8	Johnson & Johnson P188 stent	None	3 d after stent	Doing well	6
6	VV to innominate V	VV at entry into innominate V	AVSD, TGA, PA, MAPCA, s/p AP shunt <sup>a,b</sup>	Cyanosis	7 y	NA	NA	NA	NA	83	NA	NA	16	11	NA	14	Jo-Stent (Jo-med, Germany)	NA	None	Re-stent at 9 yo	7
7	VV to L SVC	VV at entry into LSVC	AVSD, SV, PS, s/p Central shunt, mLBS <sup>c</sup>	Resp distress	9 m	NA	NA	7Fr LIJ	NA	NA	NA	NA	NA	NA	NA	NA	10 mm long P1006 Cordis stent; 15 mm long P1507 stent	CPR, thrombus	17 mo (+Glen)	23 mo, doing well	8

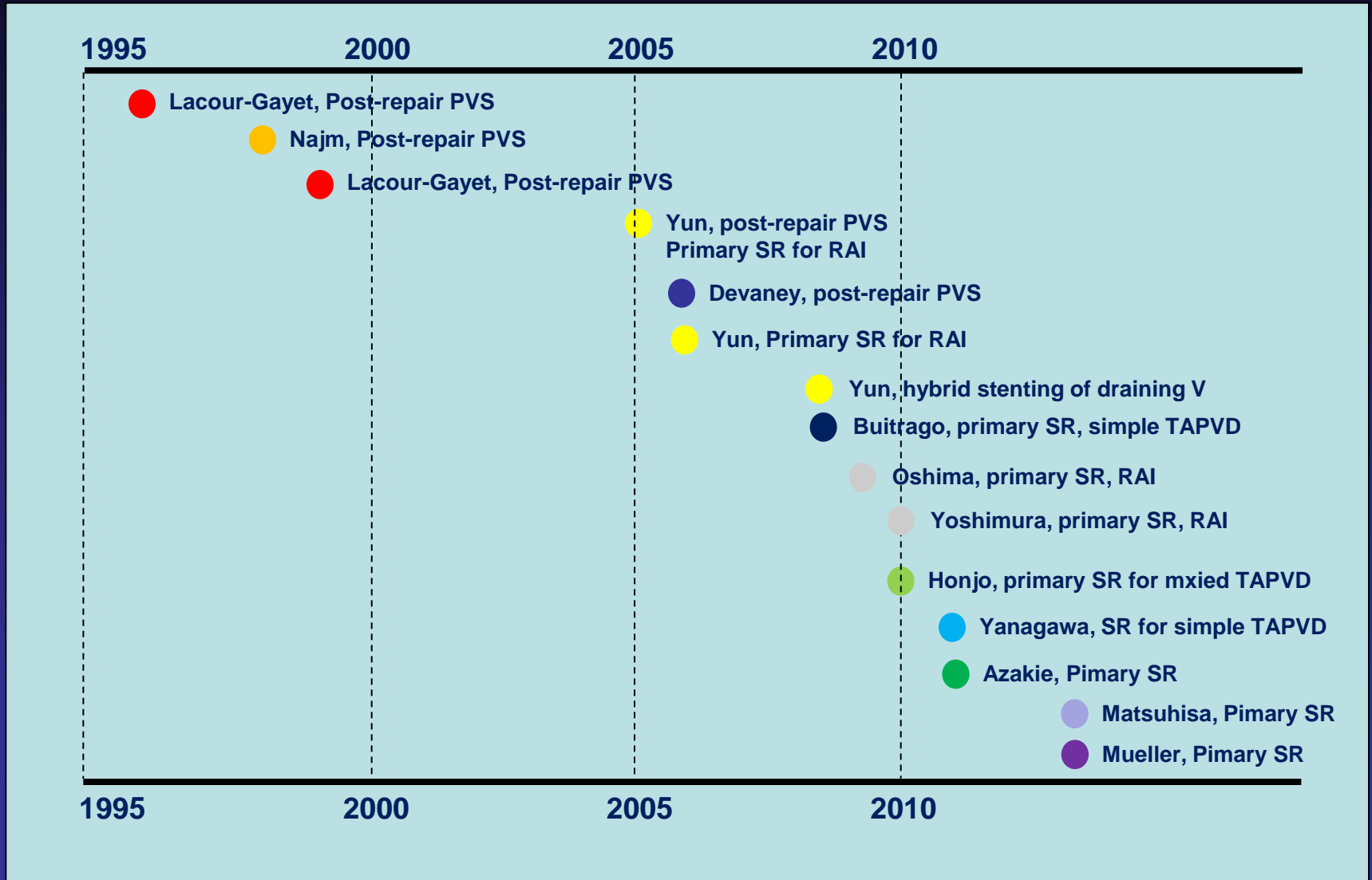
**Table I. Palliative Transcatheter Interventional Procedures for Obstructed Total Anomalous Pulmonary Venous Connection (continued)**

TAPVC detail	Obstruction site	Other cardiac diagnosis	Preexistent condition	Age	Wt (kg)	GA (wks)	Sheath	SpO2 (%)		Pulmonary venous pressure (mmHg)		Gradient at obstructed TAPVC (mmHg)		Vessel (mm)			Complication	TAPVC repair	Last followup	Ref	
								Pre	Post	Pre	Post	Pre	Post	Narrow	NL	Stent					
<b>Infracardiac</b>																					
8	VV to DV	VV at entry into DV	AVSD, PA, MAPCA		22 h	3.9	Full term	4Fr NA	60	80	NA	NA	NA	NA	NA	NA	4.5 mm x 12 mm, 4.5 mm x 16 mm Paclitaxel drug-eluting stents (TAXUS, Boston Scientific)	None	6 mo (+rmBTS)	NA	9
9	VV to DV	VV at the crux of the diaphragm and DV	None	ECMO, MOF	3 d	3.9	Full term	NA UV	44	NA	NA	NA	NA	NA	Pinpoint	NA	Premounted stent x2	None	8 d (after stent)	5mo doing well	10
10	VV to DV	DV	None	NA	13 d	1.5	30	5Fr UV	NA	NA	NA	NA	NA	NA	3.9	3.5 mm x 13 mm Duet coronary stent (Guidant)	None	5 wo	4yo doing well	11	
11	VV to DV	DV	None	NA	2 d	3.2	NA	5Fr UV	NA	NA	NA	NA	8	NA	1.7	4.5	4 mm x 24 mm Liberte coronary stent (Boston Scientific)	None	4 do	9mo doing well	11
<b>Mixed</b>																					
12	LUPV to VV & InnominateV; LL & RPV to des VV & DV	VV at entry into DV	None	NA	2 d	1.7	32	7Fr UV	NA	NA	NA	NA	10	NA	2	NA	4 mm x 20 mm Coronary stent	Cardiac perforation	3 w	2 mo, died of PNA & sepsis	11
13	AscVV to LSVC	Unbalanced AVSD, DORV, PDA, BL SVC <sup>b</sup>	NA	NA	12 d	2.4	38	6Fr LIJ	85-92	NA	NA	NA	7	NA	NA	NA	Palmaz Genesis stent (PG1560BS-S)	None	Serial re-stent, 17 mo (+Glenn)	20 mo, doing well	12
13	DesVV to DV & IVC							6Fr RFV					8		NA	Palmaz Genesis stents (PG1860BSS) x2 in tandem					

**Table I. Palliative Transcatheter Interventional Procedures for Obstructed Total Anomalous Pulmonary Venous Connection (continued)**

TAPVC detail	Obstruction site	Other cardiac diagnosis	Pre-stent condition	Age	Wt (kg)	GA (wks)	Sheath	SpO2 (%)		Pulmonary venous pressure (mmHg)		Gradient at obstructed TAPVC (mmHg)		Vessel (mm)			Outcome			Ref		
								Pre	Post	Pre	Post	Pre	Post	Narrow	NL	Stent	Complication	TAPVC repair	Last followup			
<b>Balloon Angioplasty</b>																						
<b>Supracardiac</b>																						
1	VV to RSVC	At entry of the VV into RSVC	Secundum ASD	Intubation, hypotension	36 h	2.5	Full term	6Fr RFV	NA	NA	NA	NA	NA	NA	NA	2.6	NA	6 mm balloon (SMASH, Boston Scientific)	None	15 d	Died of sepsis POD 20	13
2	VV to innominate V	VV in its lower third	None	Intubation	1 d	Full term	NA UV	35	88	43	NA	33	NA	<2.5	5	7 mm Angioplasty balloon (Meditech)	None	emergent surgery	Died 3hr after surgery	14		
3	VV to LSVC	At entry into left innominate V	ASD	Cyanosis	3 m	NA	NA	7Fr	NA	NA	26	14	20	NA	NA	NA	NA	6 mm x 20 mm polyethylene balloon	None	10d	Died 2hr after surgery	15
<b>Hybrid procedure – Pulmonary artery banding, PDA ligation and Stent placement on VV</b>																						
<b>Supracardiac</b>																						
1	VV to RSVC-RA junction	At entry into RSVC-RA junction	Unbalanced AVSD, DORV, PDA, BL SVC <sup>b</sup>	Suspected NEC	24 d	2.2	36	Hybrid	70	NA	NA	NA	NA	NA	4	NA	4	Balloon expandable drug eluting coronary stent (Endeavor, Medtronic)	None	30 d after stent	7mo (Glenn)	17

# Sutureless repair (SR) for PV anomalies



# Primary SR for TAPVD

## -AMC experience-

**21 Patients over 10 years (2004-2014)**

**12 boys and 9 girls**

**Age at SR: 0 – 269 days (median: 21 days)**

**RAI / FSV: 13 / 21**

**BVR: 8 / 21**

**Early mortality: 5 / 21 (24%)**

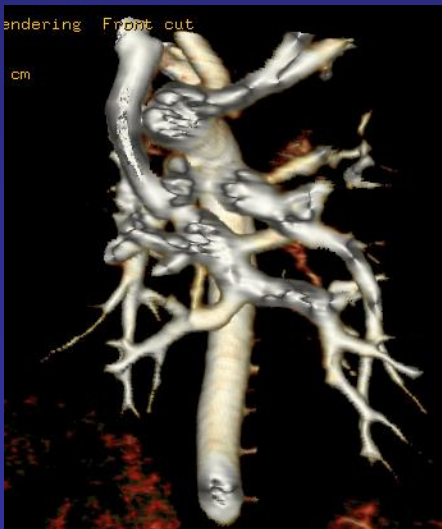
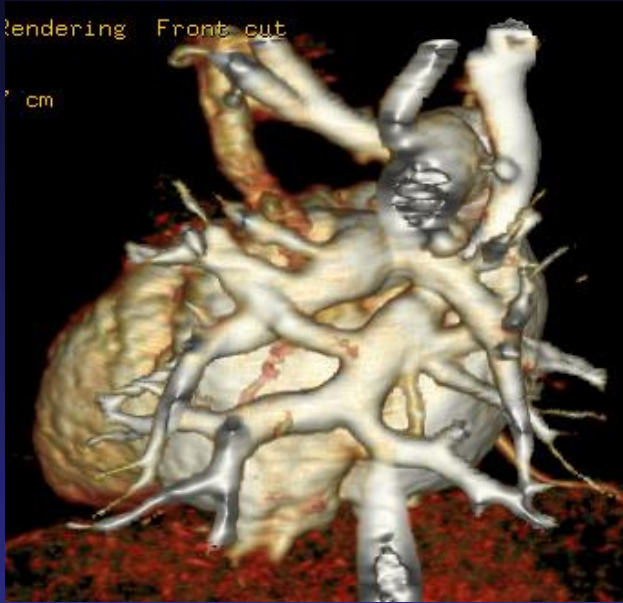
# Primary sutureless repair for TAPVD

-AMC experience (2004-2014) -

No	Sex	SR age (days)	RAI / FSV	TAPVD type	Associated anomalies	Early death
1	M	2	+	Infracardiac	DORV, AVSD, BSVC, PDA	+
2	F	52	+	Supracardiac	DORV, PS, AVSD, BSVC, PDA	-
3	M	31	+	Supracardiac	DORV, PA, AVSD, BSVC, PDA	-
4	M	37	+	Supracardiac	DORV, MA, CoA	-
5	M	21	+	Infracardiac	DORV, AVSD, PDA	-
6	F	9	+	Infracardiac	DORV, PA, AVSD, BSVC, PDA	-
7	F	269	+	Supracardiac	DORV, PS, AVSD, BSVC, PDA	-
8	F	31	+	Infracardiac	DORV, PS, AVSD, BSVC	+
9	F	1	+	Supracardiac	DORV, AVSD, BSVC	-
10	M	52	+	Supracardiac	DORV, PS, AVSD	-
11	F	110	+	Supracardiac	DORV, PS, AVSD	-
12	F	192	+	Supracardiac	DORV, PA, MA, CoA	-
13	M	29	-	mixed	none	-
14	M	8	-	mixed	none	+
15	M	1	-	Infracardiac	none	-
16	F	16	-	Infracardiac	none	-
17	F	8	-	Infracardiac	none	-
18	M	0	-	Infracardiac	none	-
19	M	16	-	Infracardiac	CoA, mVSD	-
20	M	44	+	Supracardiac	DORV, AP window, BSVC	+
21	M	6	-	Infracardiac	TGA with IVS	+



# Case 1



**Dx: DORV, AVSD, no PS, BSVC, PDA,  
RAI, obstructive supracardiac TAPVD**

**Hybrid DV stenting (23 days, 2.2 kg)**

**TAPVD repair (52 days, 2.7 kg)**

**BCS (8 months)**

**Extracardiac Fontan (42 months)**

## Negative results - Congenital Hybrid palliation for right atrial isomerism associated with obstructive total anomalous pulmonary venous drainage

Won-Kyoung Jhang<sup>a</sup>, Yong-Jin Chang<sup>a</sup>, Chun-Soo Park<sup>a</sup>, Yeon-Mi Oh<sup>b</sup>, Young-Hwue Kim<sup>b</sup>, Tae-Jin Yun<sup>a,\*</sup>

<sup>a</sup>Division of Pediatric Cardiac Surgery, Asan Medical Center, College of Medicine, University of Ulsan, 388-1 Poonngnap-dong, Songpa-gu, Seoul, Republic of Korea, 138-736

<sup>b</sup>Pediatric Cardiology, Asan Medical Center, College of Medicine, University of Ulsan, Republic of Korea

Received 1 November 2007; received in revised form 30 December 2007; accepted 1 January 2008

### Abstract

A twenty-four-day-old girl, who was prematurely born at 36 weeks of gestation, and weighed 2.2 kg, and diagnosed with right atrial isomerism, functionally single ventricle, bilateral superior vena cava (SVC) and obstructive supracardiac total anomalous pulmonary venous drainage (TAPVD) draining to the junction between the right SVC and the right atrium, underwent a hybrid procedure in the operating room, which consisted of pulmonary artery banding, ductus ligation and stenting of the draining vein of TAPVD. Obstruction at the drainage site of TAPVD was initially relieved after stenting, but, one month after the procedure, the distal end of the stent became stenotic and she received bilateral sutureless repair of TAPVD. At postoperative seven months, she underwent bidirectional cavopulmonary shunt uneventfully, and she has been followed-up for two months in a stable state without any problem in the pulmonary venous pathway. © 2008 Published by European Association for Cardio-Thoracic Surgery. All rights reserved.

**Keywords:** TAPVD; Right atrial isomerism; Hybrid procedure

### 1. Introduction

Although the prognosis of right atrial isomerism (RAI) associated with obstructive total anomalous pulmonary venous drainage (TAPVD) is very poor even in contemporary series [1, 2], aggressive TAPVD repair upon initial palliation was reported to improve the long-term outcome [2]. Surgical intervention for TAPVD using cardiopulmonary bypass, however, may be too dangerous in small babies with RAI having multiple risk factors. We present a case of hybrid palliation for a baby with RAI and obstructive TAPVD without cardiopulmonary bypass.

### 2. Case

A female baby was born at 36 weeks of gestation with a birth weight of 2.2 kg. On fetal echocardiography, she was found to have RAI, unbalanced atrioventricular septal defect, double outlet right ventricle, large patent ductus arteriosus (PDA), bilateral superior vena cava (SVC), and supra-cardiac total anomalous pulmonary venous drainage (TAPVD) draining to the junction between the right SVC and the right atrium without obstruction. Initial oxygen saturation (SaO<sub>2</sub>) was 94% at room air. The postnatal echocardiography and cardiac computerized tomography (CT) (Fig. 1) confirmed the diagnosis. At the 10th day of life, she showed abdominal distension and elevation of C-reactive protein. On suspicion of neonatal sepsis and

necrotizing enterocolitis, antimicrobial treatment was initiated. From the 15th day of life, she began to show desaturation (70%), tachypnea, and pulmonary venous congestion on chest X-ray. Follow-up echocardiography revealed that the draining site of TAPVD had become obstructive with a peak Doppler velocity of 2.2 m/s. Given her low body weight and suspected necrotizing enterocolitis, we elected to perform hybrid palliation. On the 24th day of life, she was brought to the operating room and underwent a hybrid procedure, consisting of (1) the ligation of PDA, (2) pulmonary artery banding (PAB), and (3) stent insertion into the draining vein of TAPVD (Fig. 2). For the intraoperative stenting, we used a balloon expandable drug eluting coronary stent (Endeavor™, Medtronic Inc., Minneapolis), which was balloon dilated at 10 atmospheres with a final length and diameter of 12 mm and 4 mm, respectively. After the patient arrived in the intensive care unit (ICU), she showed fluctuations in SaO<sub>2</sub> and pulmonary artery pressure, which was deemed to be caused by increased pulmonary vascular reactivity after an abrupt relief of pulmonary venous obstruction. Thus, nitric oxide (NO) inhalation therapy was applied from then on. On postoperative day 4, she began to show a high SaO<sub>2</sub> (>95% at room air) and signs of pulmonary over-circulation, so NO therapy was discontinued and PAB was tightened in the ICU. She was extubated and transferred to the general ward at postoperative day 10 and 13, respectively. Postoperative echocardiography showed mild obstruction at the distal end of the stent with a peak velocity of 1.5 m/s in a continuous flow pattern at the SVC end of the stent, and

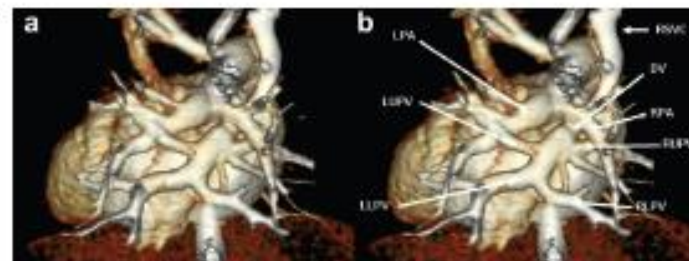


Fig. 1. Preoperative cardiac computerized tomography showing supracardiac total anomalous pulmonary venous drainage which was draining to the junction between the right SVC and the right atrium. LPA, left pulmonary artery; LUPV, left upper pulmonary vein; LLPV, left lower pulmonary vein; RSCV, right superior vena cava; DV, draining vein; RPA, right pulmonary artery; RUPV, right upper pulmonary vein; RLPV, right lower pulmonary vein.

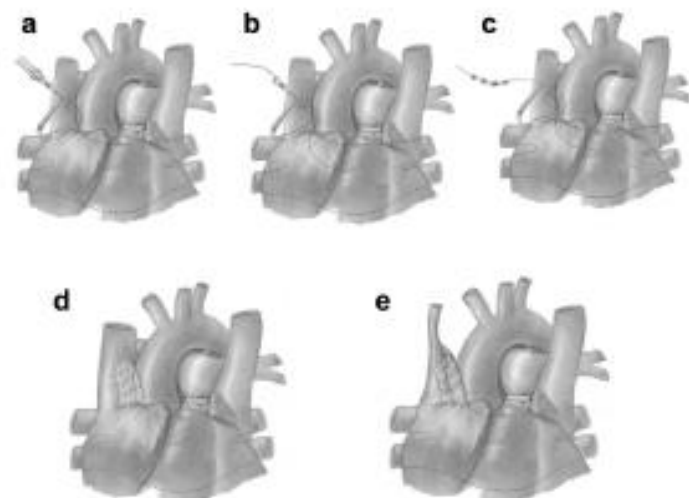
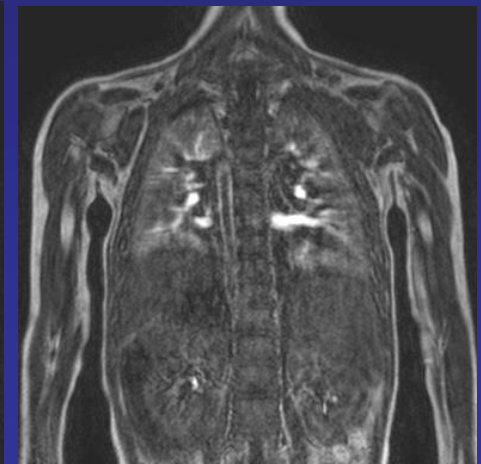
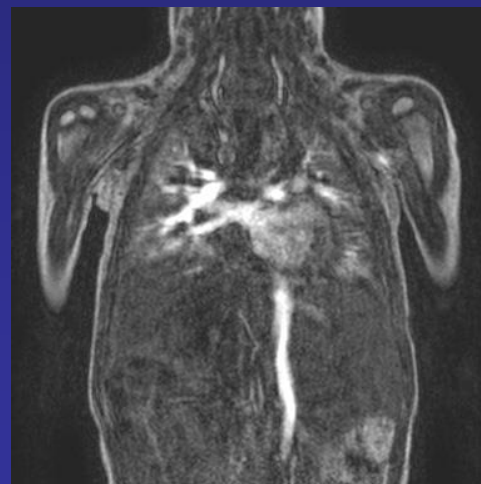
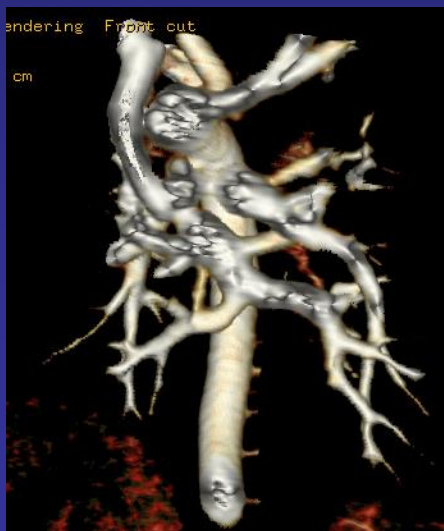
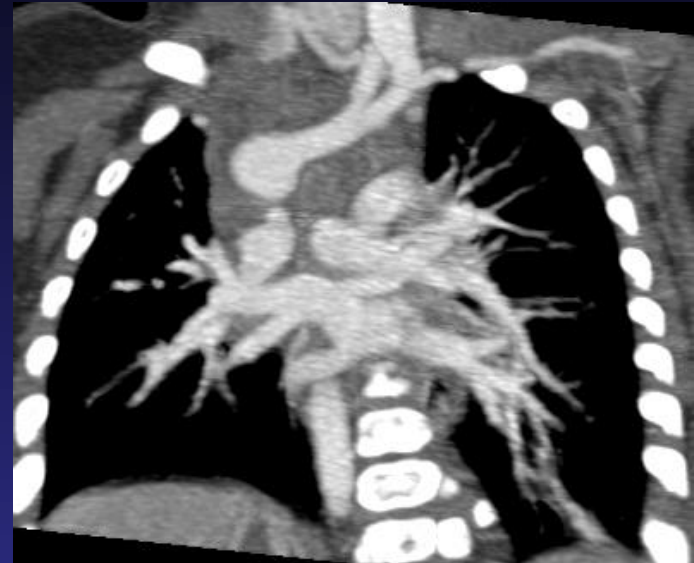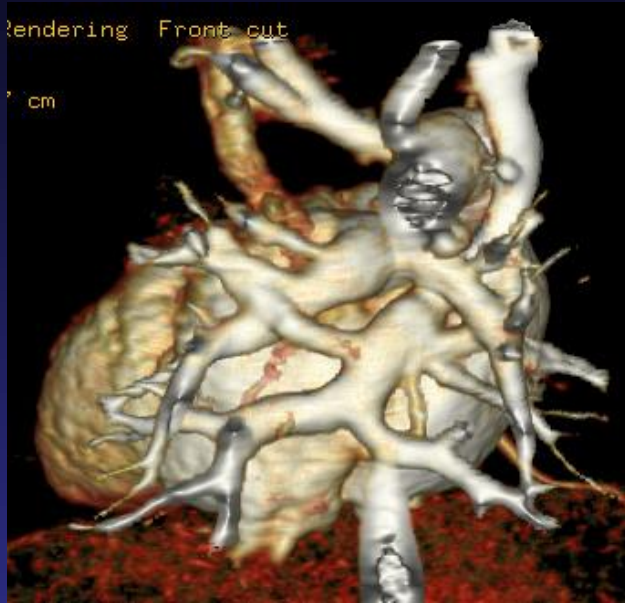


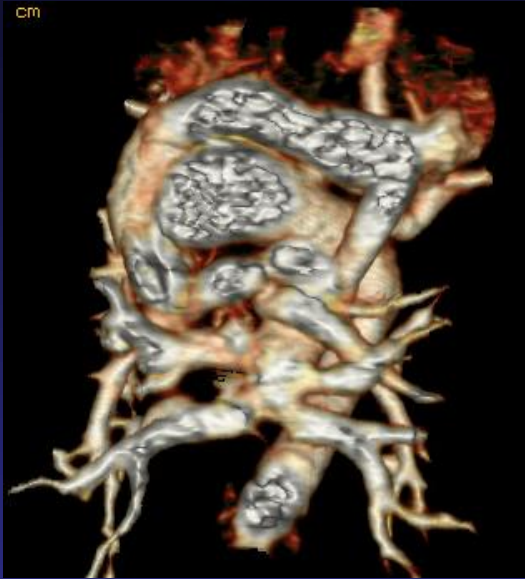Fig. 2. Hybrid procedure for RAI, functionally single ventricle, unrestricted pulmonary blood flow, PDA, and supracardiac TAPVD draining to the junction between the right SVC and RA. a. Angiocath (22 gauge) is introduced into the draining vein of TAPVD after PDA ligation and pulmonary artery banding. Utilization of intra-operative C-arm fluoroscopy and angiographic visualization of the draining vein by injecting contrast media into the common pulmonary venous chamber through the angiocath confirms the exact location of the angiocath in the draining vein. b. A guide wire (5 French) is introduced through the Angiocath. c. A balloon expandable drug eluting coronary stent (Endeavor™, Medtronic Inc., Minneapolis) is advanced following the guide wire. d. The stent is placed in the draining vein of TAPVD, and balloon dilated at 10 atmosphere with a final length and diameter of 12 mm and 4 mm, respectively. e. Distal end of the stent becomes obstructive one month after the hybrid procedure due to the shrinkage of the right SVC. RAI, right atrial isomerism; PDA, patent ductus arteriosus; TAPVD, total anomalous pulmonary venous drainage; SVC, superior vena cava; RA, right atrium.

\*Corresponding author. Tel.: +82-2-3010-3589; fax: +82-2-3010-6966.  
E-mail address: tjyun@amc.seoul.kr (T.-J. Yun).

# Case 1



# Case 2



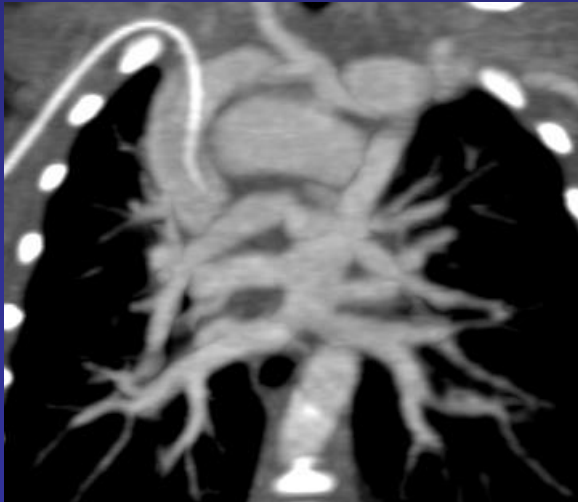**Dx: DORV, AVSD, PA, PDA,  
RAI, non-obstructive supracardiac TAPVD**

**TAPVD repair, RMBT shunt (31 days, 3.5 kg)**

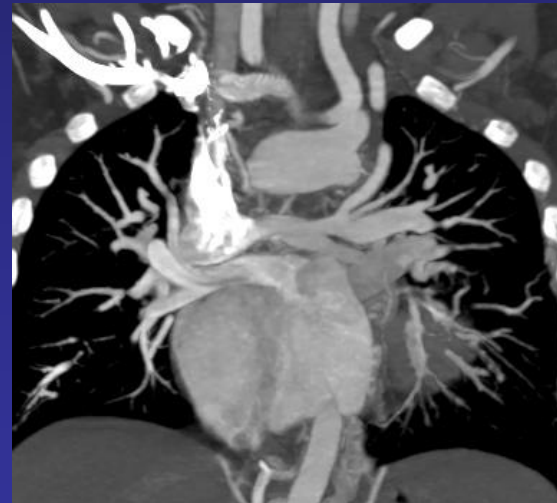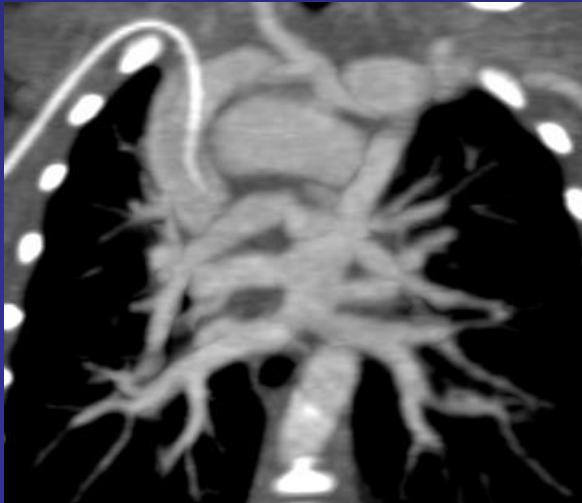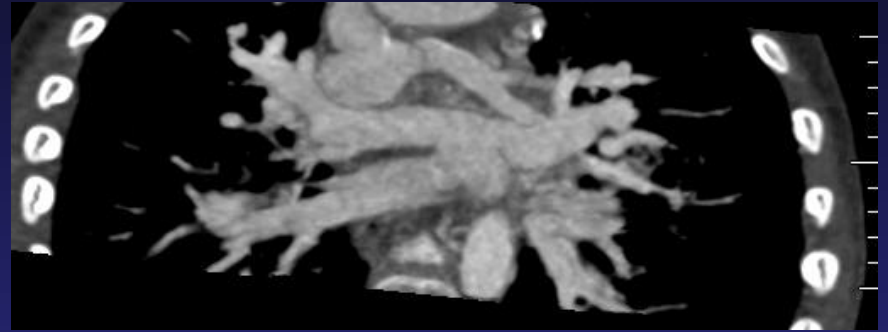
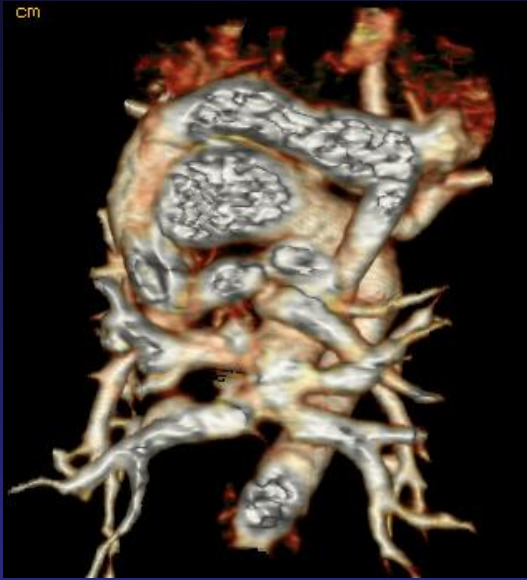**BCS, LPA angioplasty (8 months)**

**LMBT shunt (3 years)**

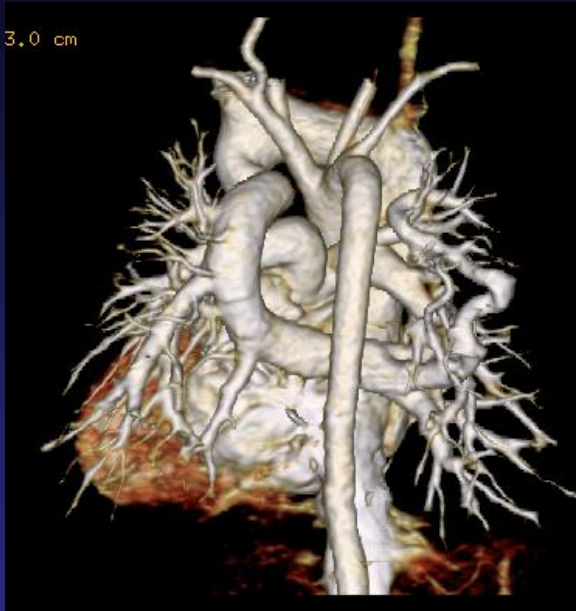
**Extracardiac Fontan (5 years)**



# Case 2



# Case 3

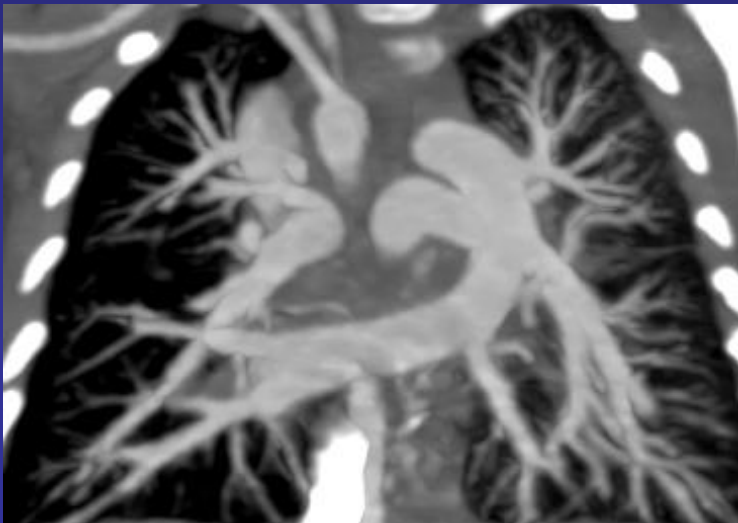


**Dx: DORV, AVSD, no PS, PDA, RAI,  
non-obstructive supracardiac TAPVD**

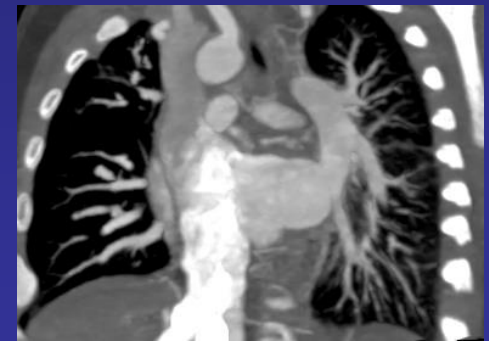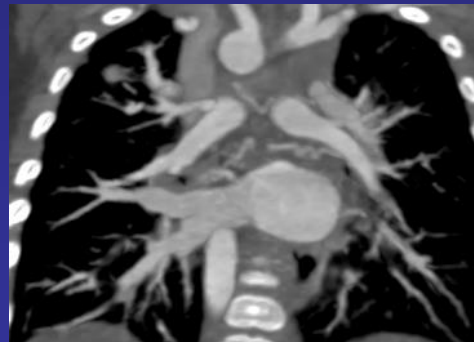
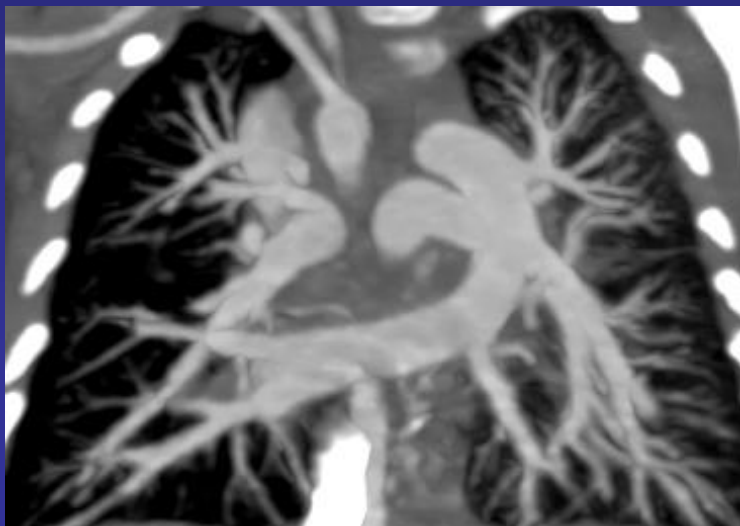
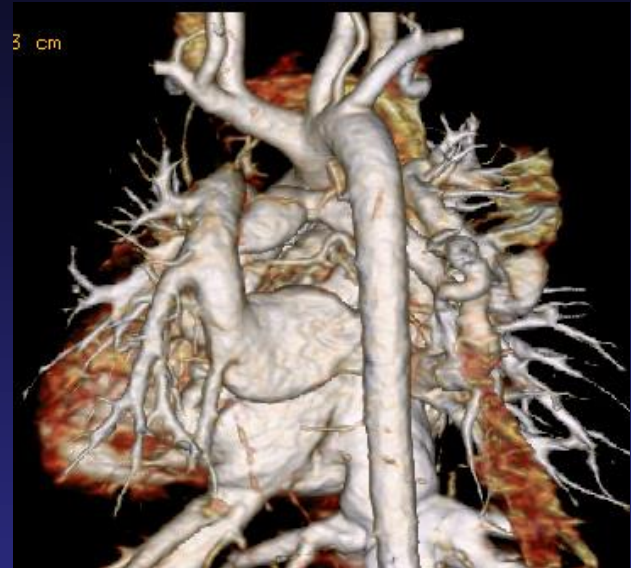
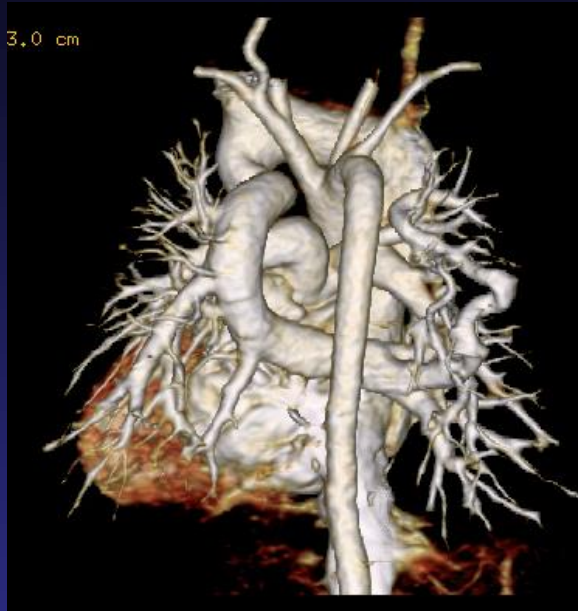
**TAPVD repair, PAB (52 days, 4.5 kg)**

**BCS, LPA angioplasty (7 months)**

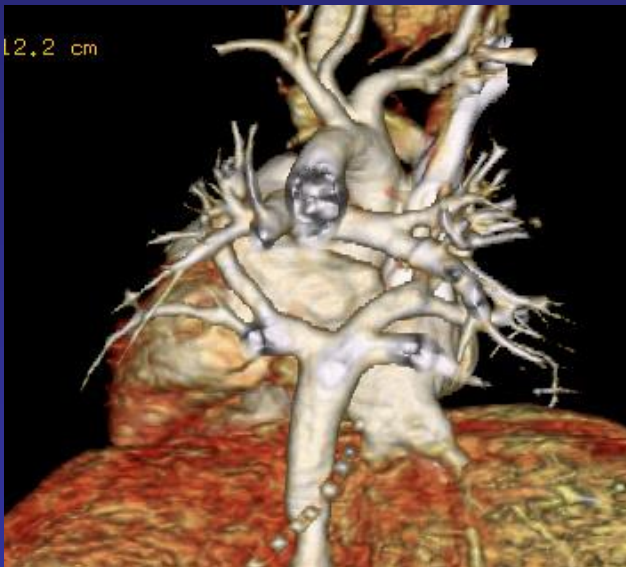
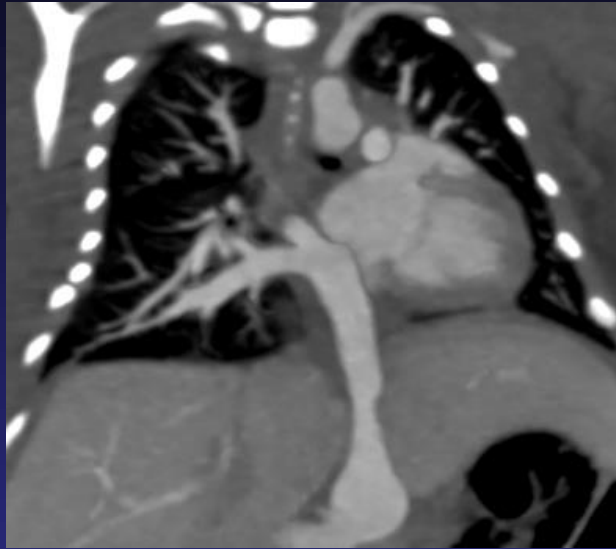**Currently 30 months old, doing well**



# Case 3



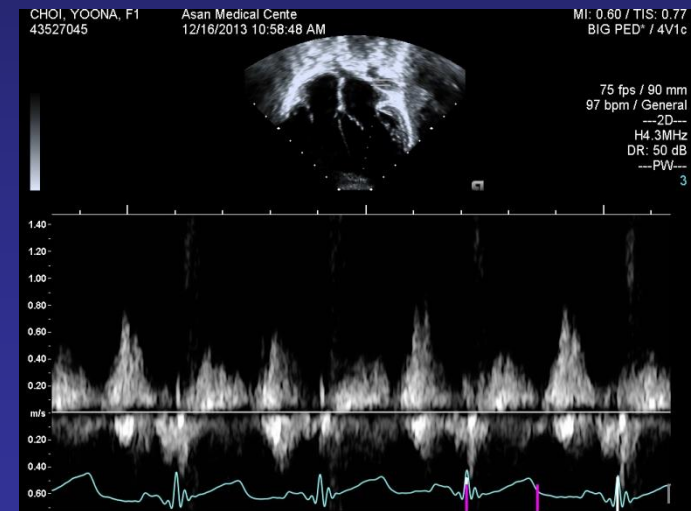
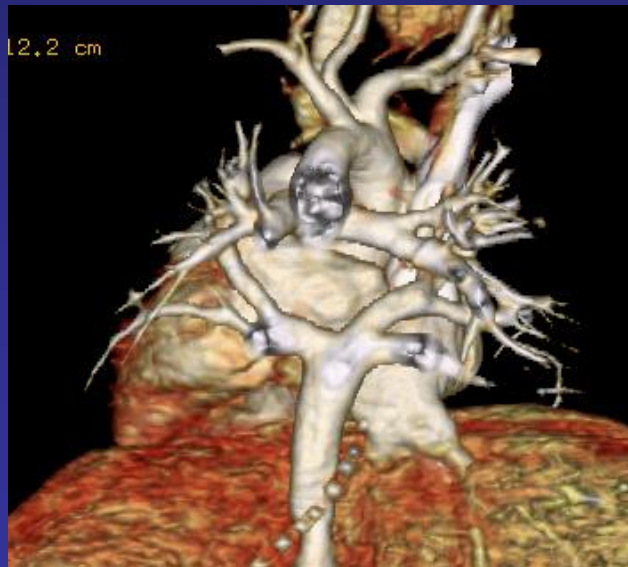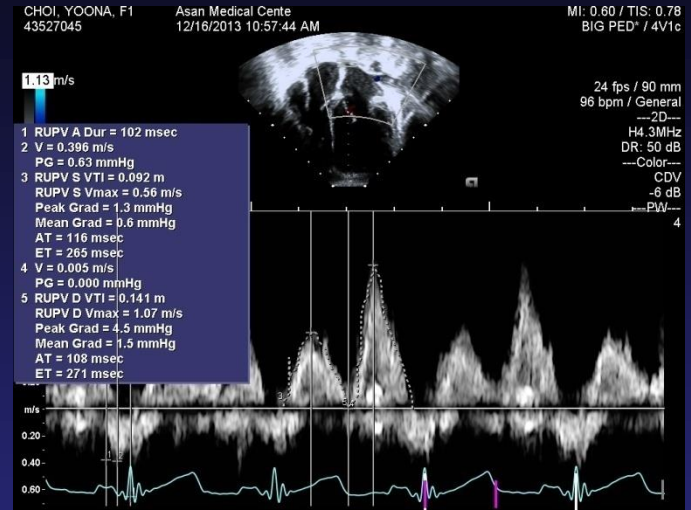
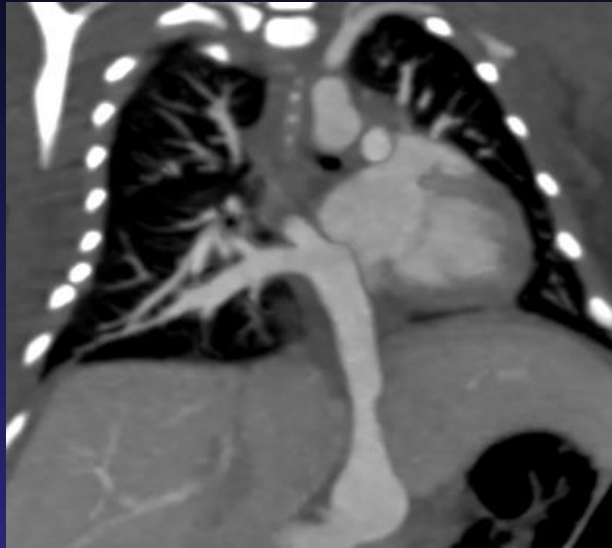# Case 4



**Dx: Infracardiac TAPVD (Isolated)**  
**TAPVD repair (7 days, 2.9 kg)**  
**Uneventful hospital course**

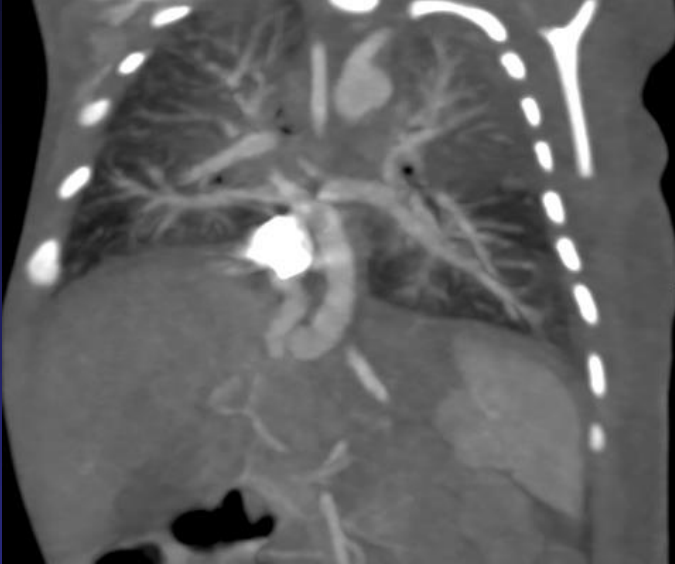

# Case 4



Postop 21 months

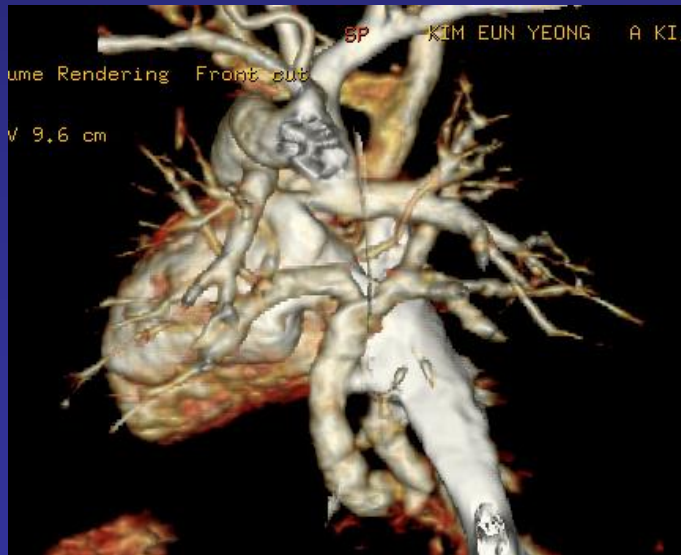
# Case 5



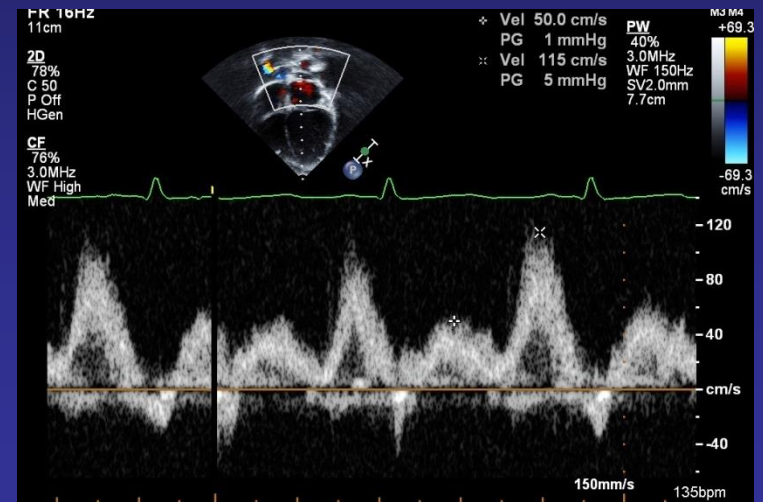
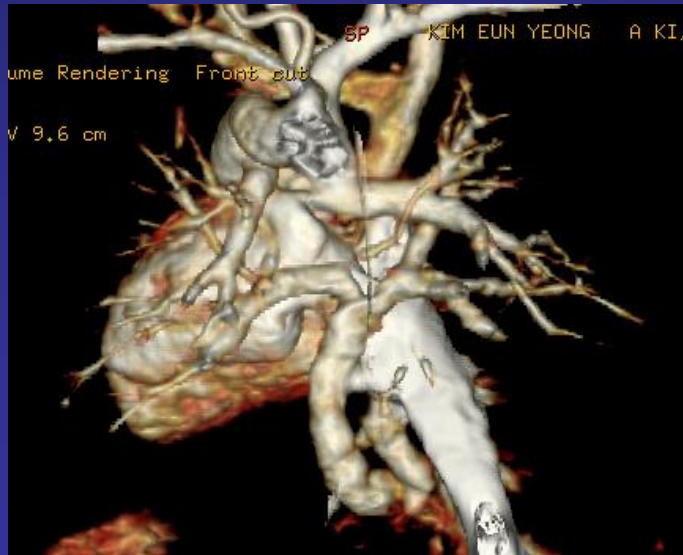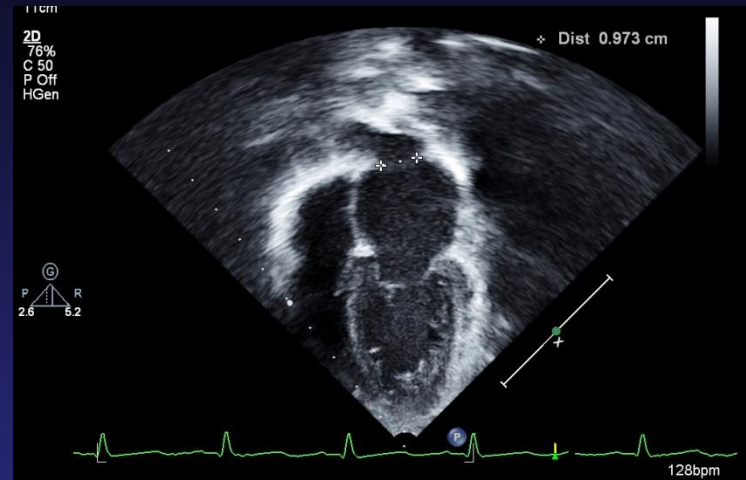
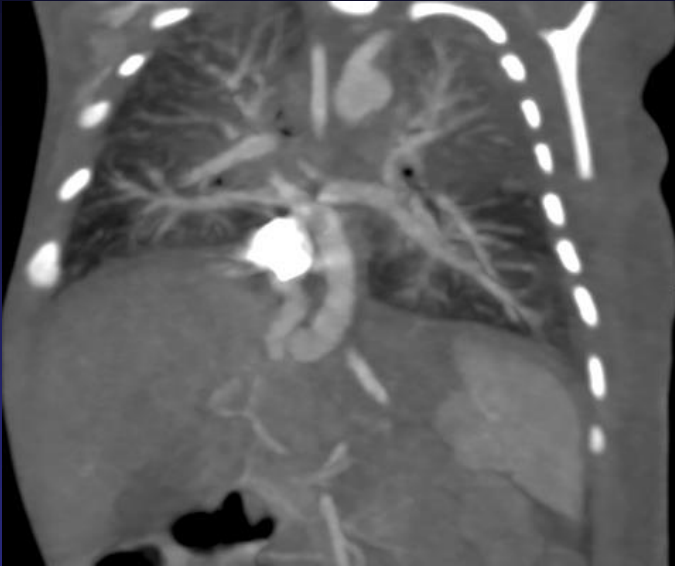**Dx: Infracardiac TAPVD (Isolated)**

**TAPVD sutureless repair (1 day, 2.6 kg)**

**Uneventful hospital course**

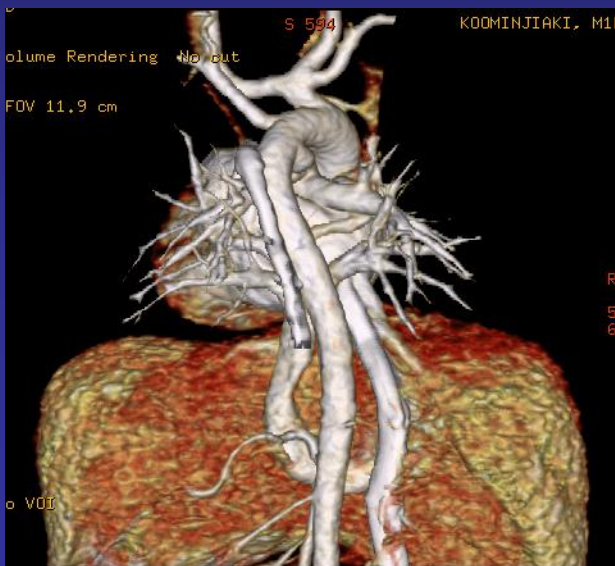
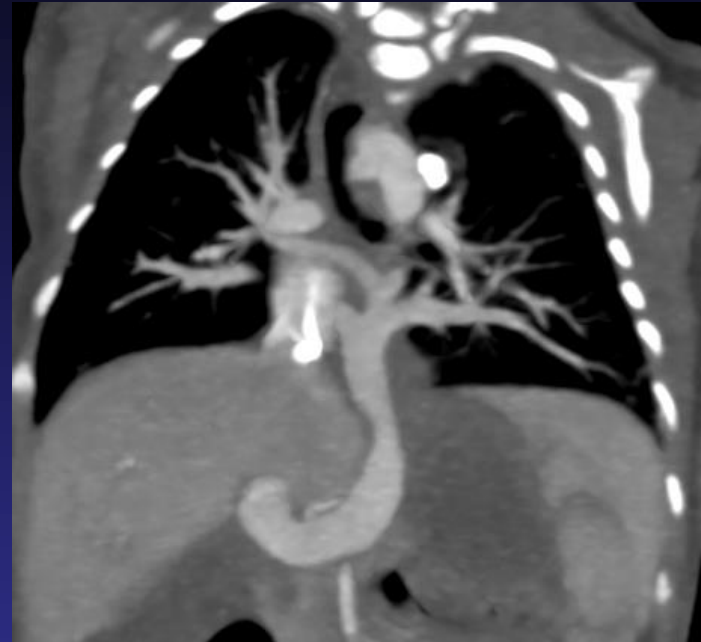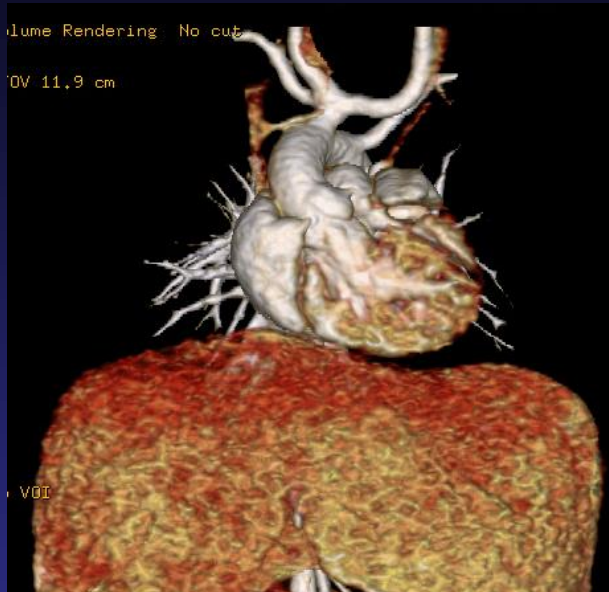


# Case 5



Postop 39 months

# Case 6



**Dx: Infracardiac TAPVD, d-TGA with IVS, VACTER**  
**TAPVD sutureless repair, Arterial switch Op**  
**(6 day, 2.5 kg)**  
**Massive capillary leak, LCP, ARF**  
**Early mortality, POD 21 days)**

# Current indications for SR

- **Post-repair PVS**
- **Congenital PVS**
- **TAPVD associated with FSV, RAI**
- **Isolated TAPVD with unfavorable anatomy**