

:

,

# **Congenital anomalies of the left heart valves: morphology, pathophysiology and diagnosis**

# Congenital anomalies of the left heart valves :

## Mitral / Aortic

- relatively rare (isolated/combined)
- neonate, early infant : severe Sx
- fetal echo.
- diagnosis: difficult

# Mitral Valve & Left Ventricular Inflow

## Mitral Stenosis

1. Congenital Mitral stenosis
2. Others

Cor triatriatum of the left atrium  
Supravalvular mitral ring  
parachute mitral valve  
double-orifice mitral valve

Congenital anomalies of the left heart valves :

## **Mitral Regurgitation**

- **Congenital mitral valve insufficiency**
- **mitral arcade**
- **MVP syndrome**

# Congenital mitral stenosis

valve annulus

leaflet

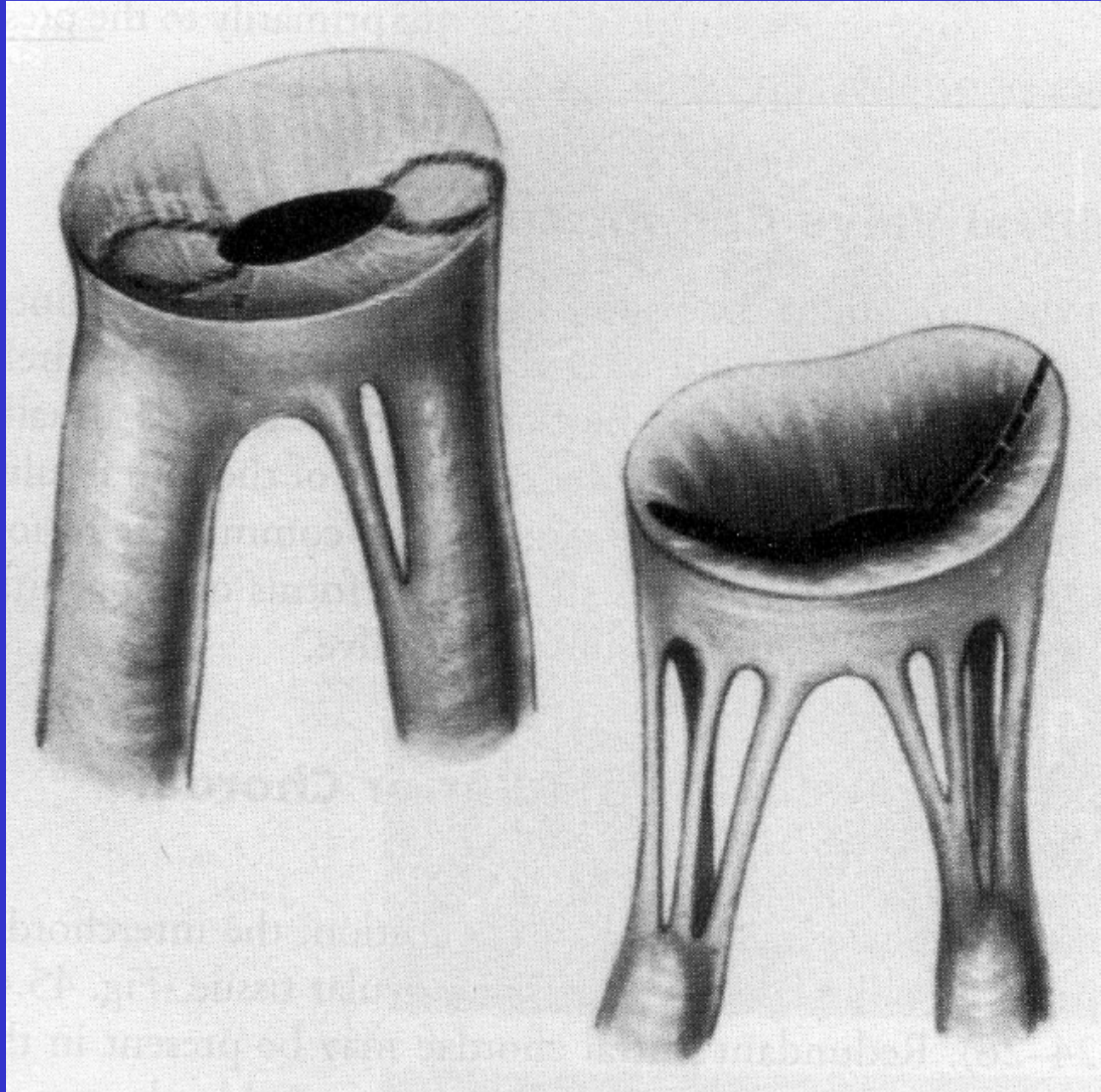
chordae

papillary muscle

**Congenital mitral stenosis**

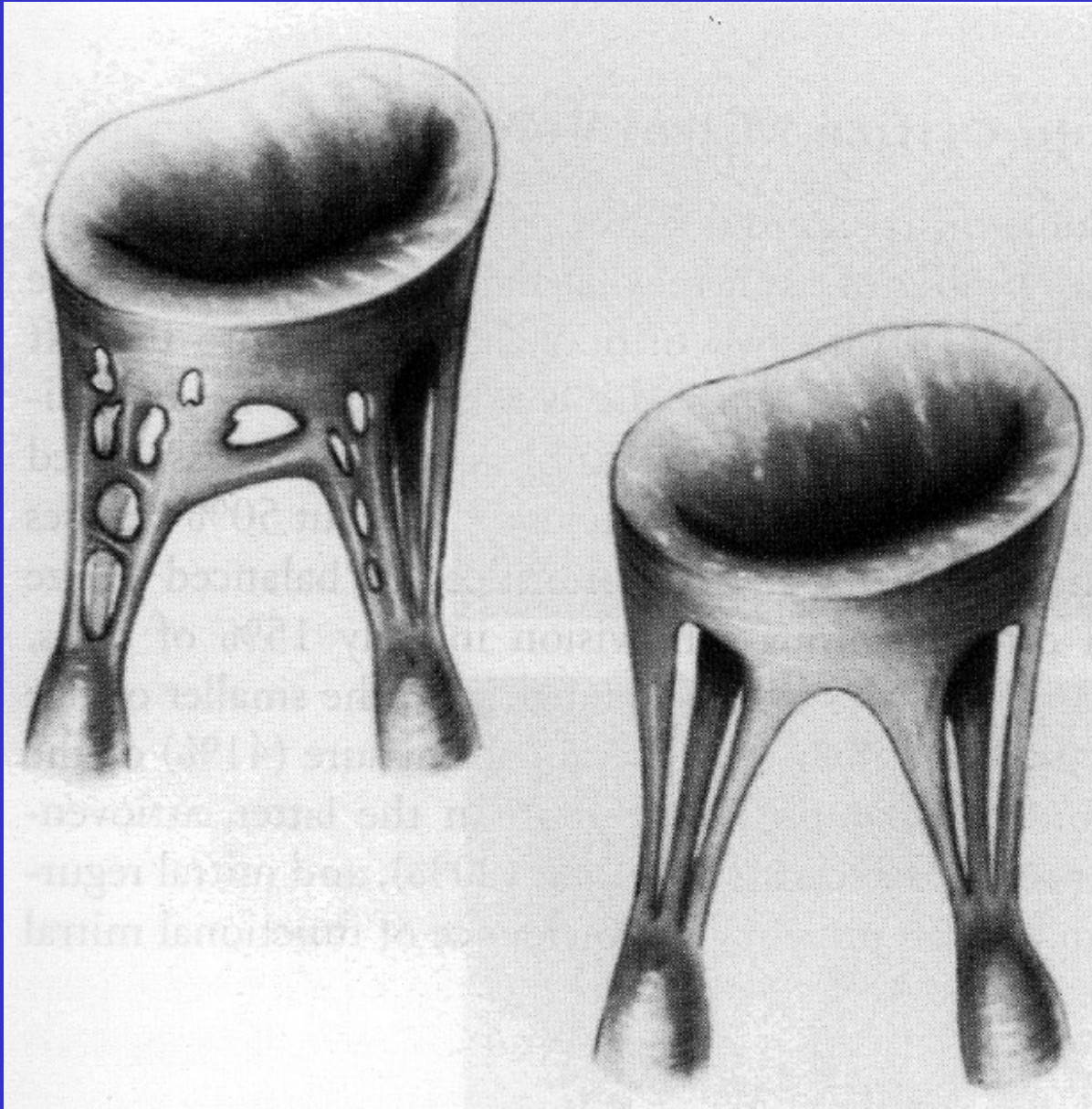
**Commissure**

**fusion**

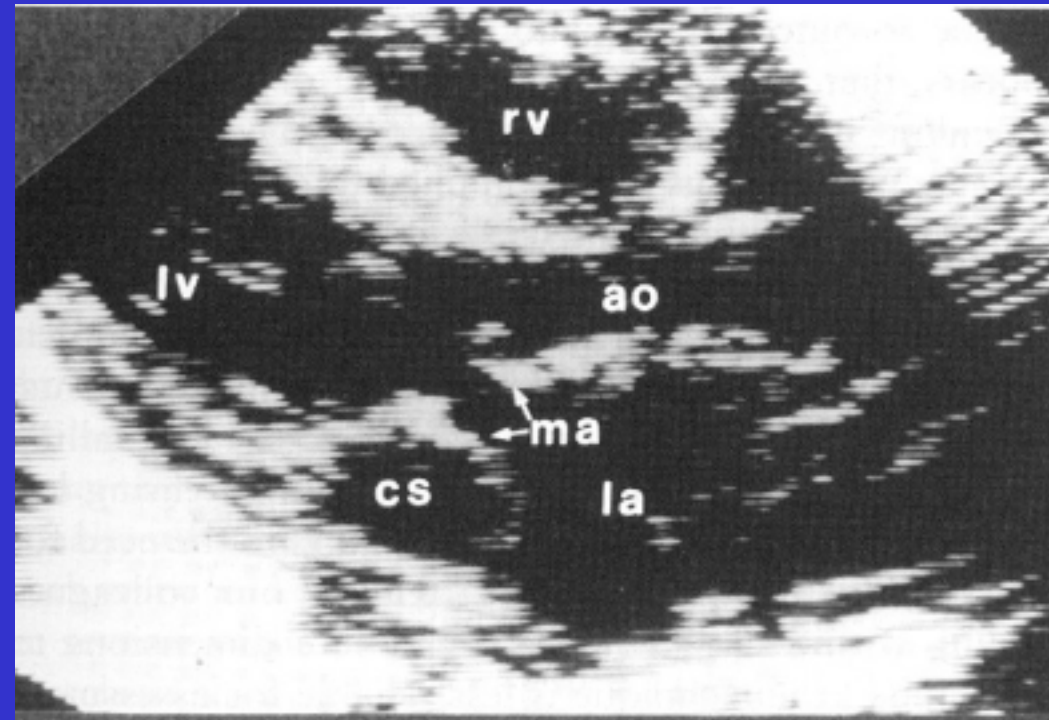
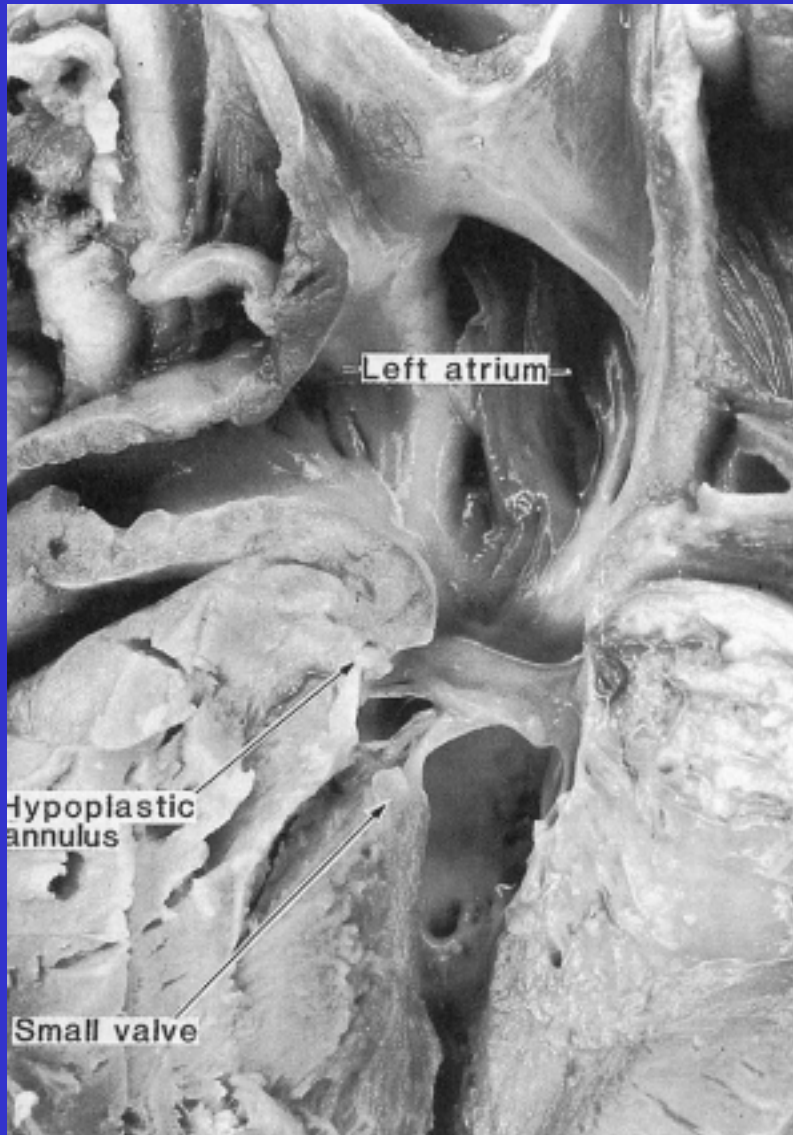


# Congenital mitral stenosis

Excessive valve tissue



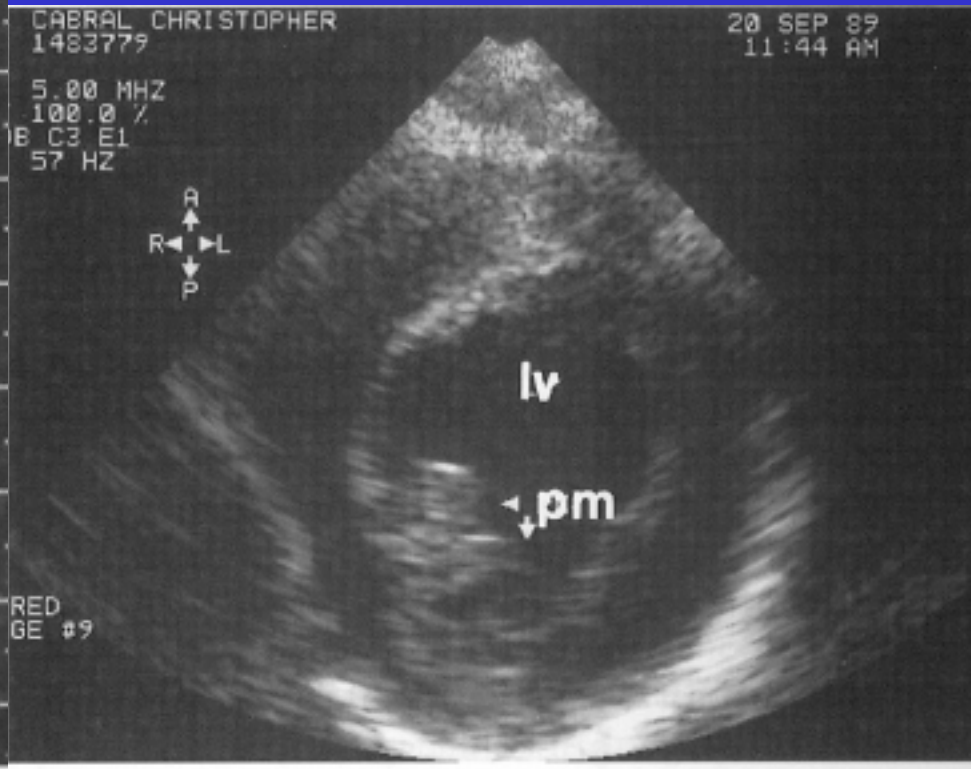
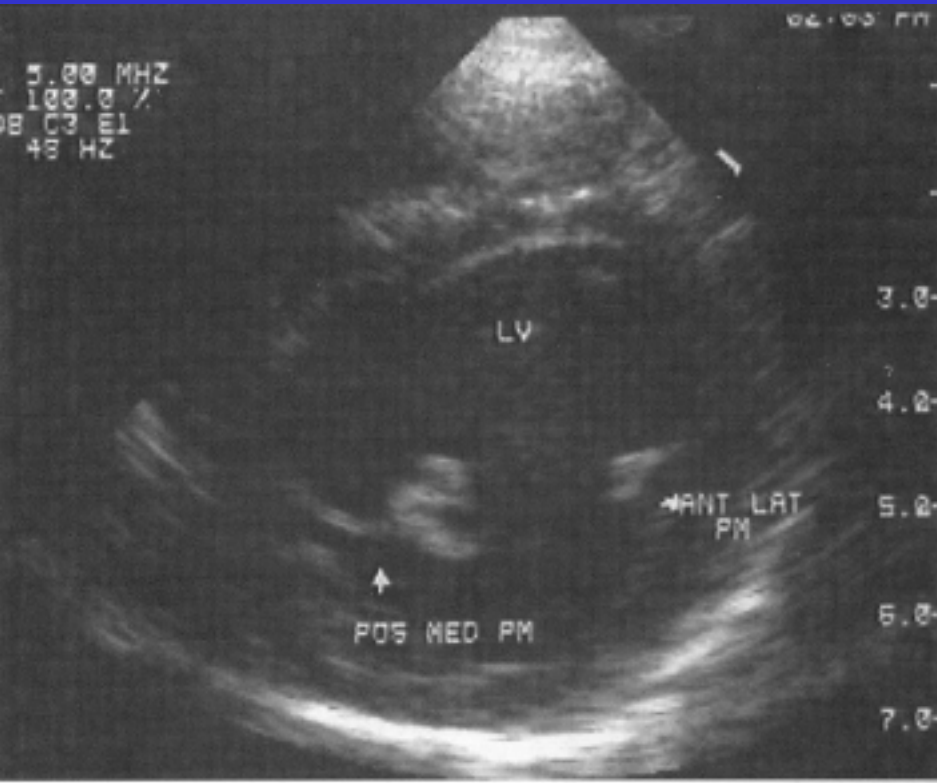# Congenital mitral stenosis



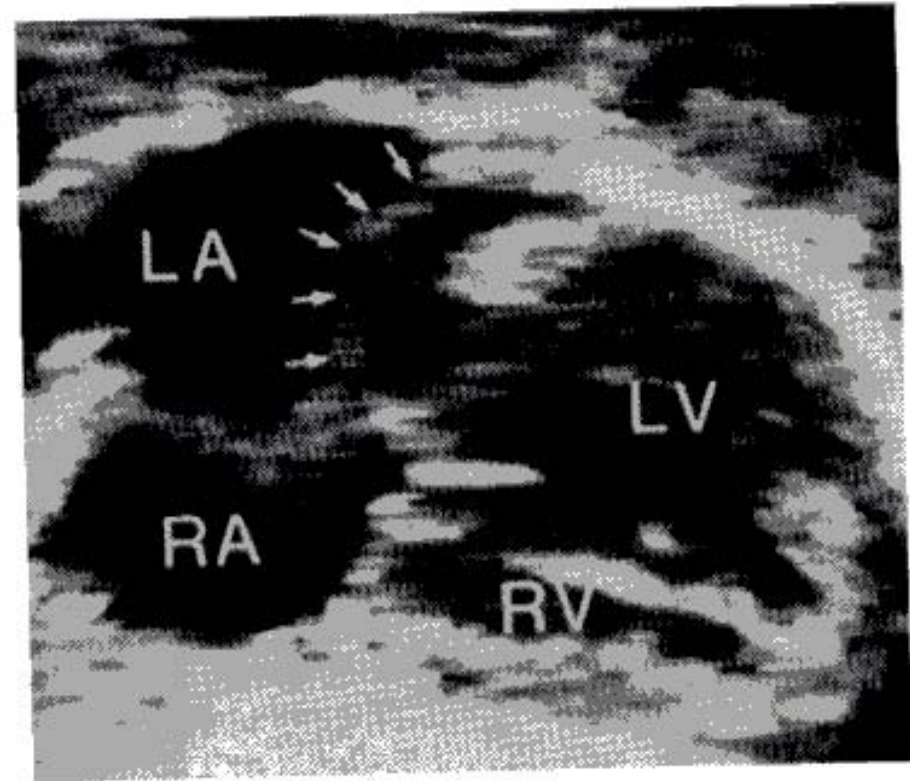
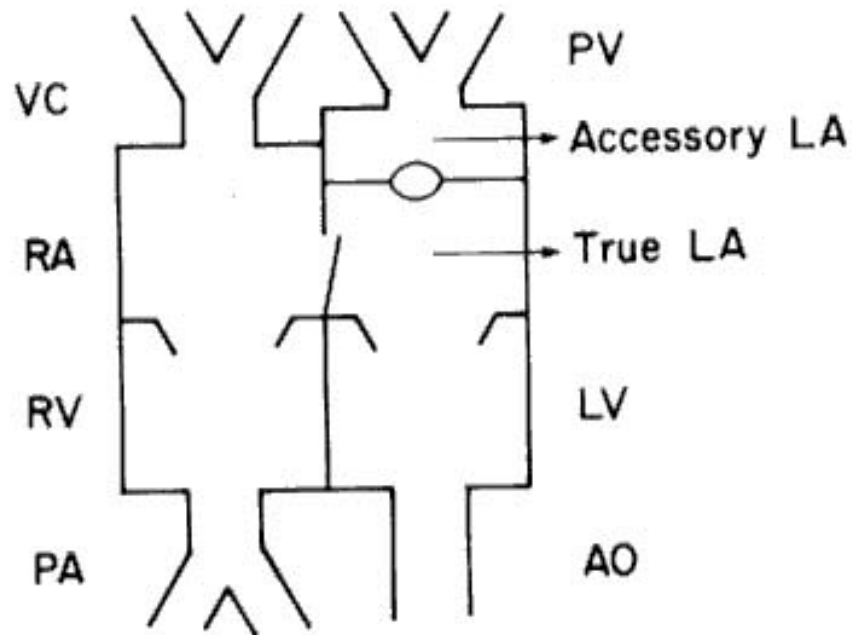
**Annular hypoplasia**

# Congenital mitral stenosis

## Papillary muscle

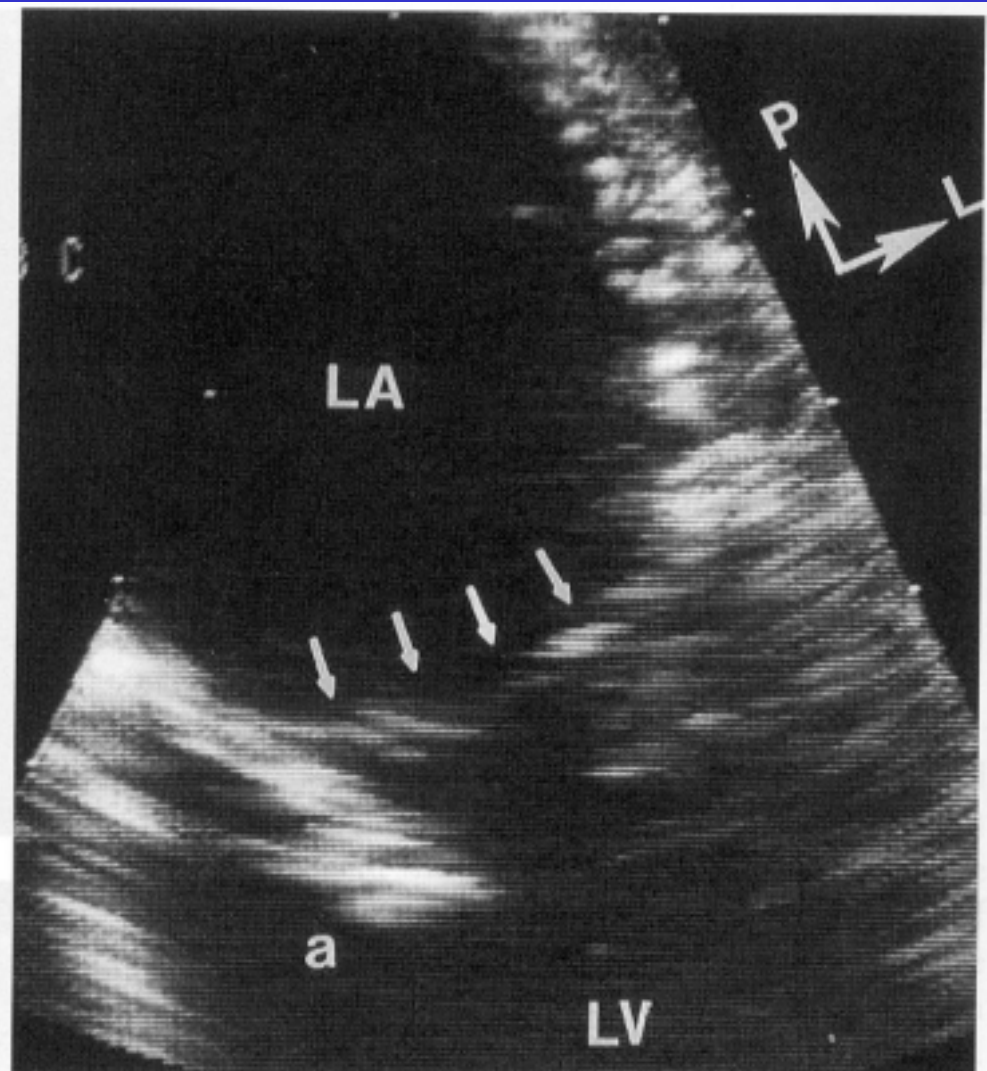
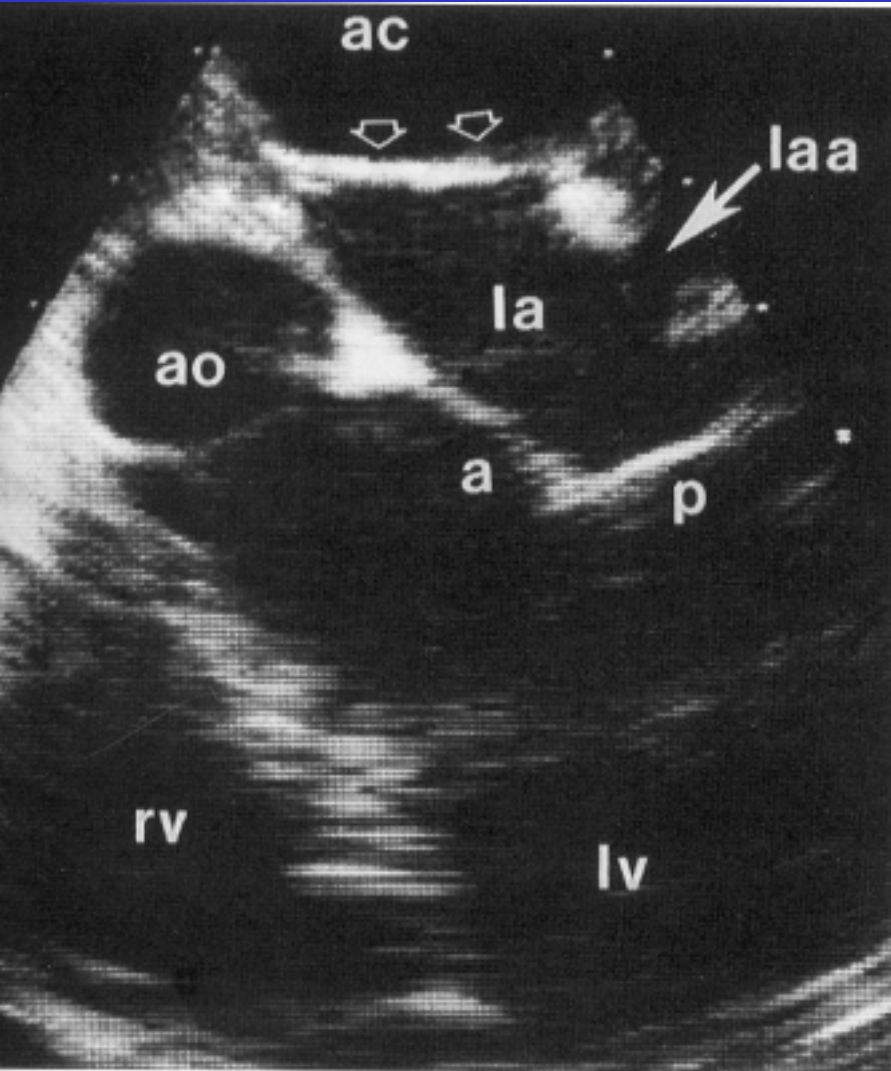


# Cor triatriatum of the left atrium

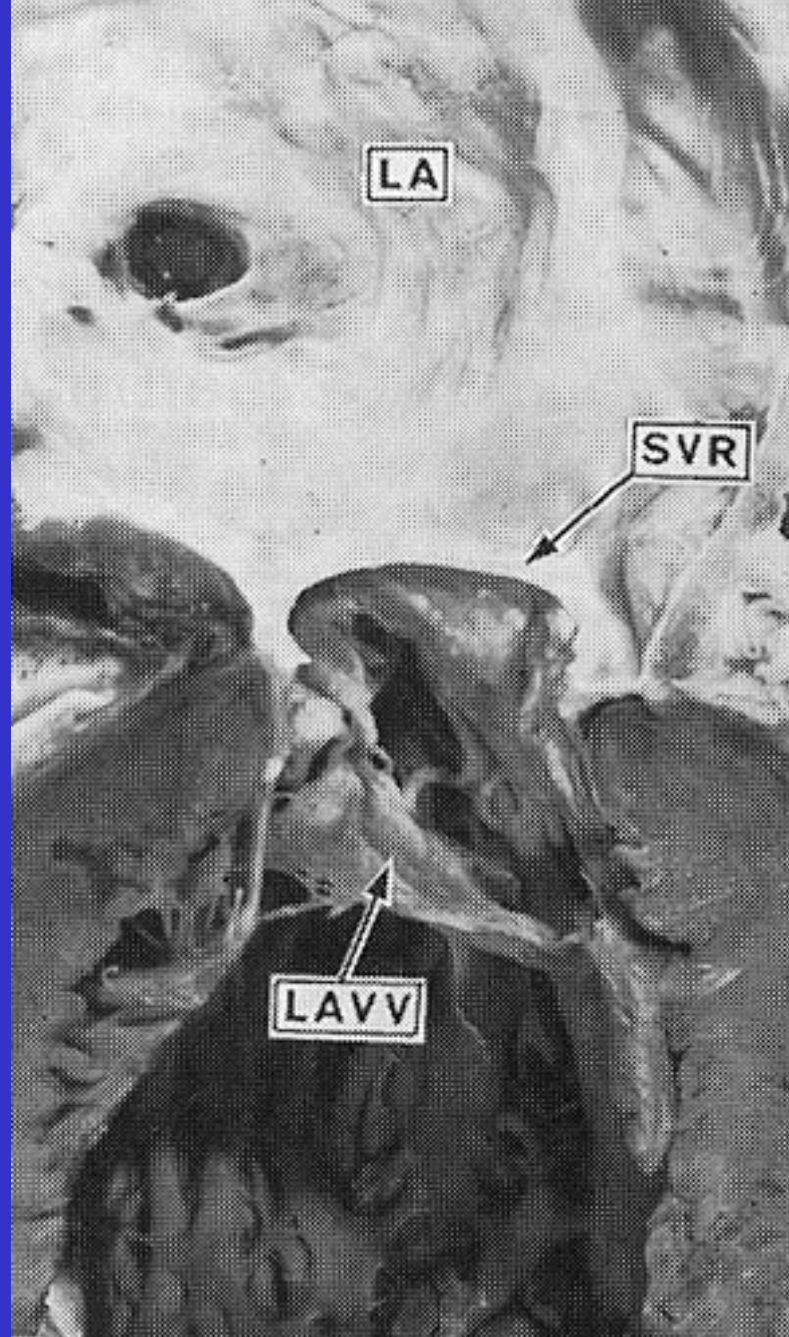


**Subcostal 4-ch**

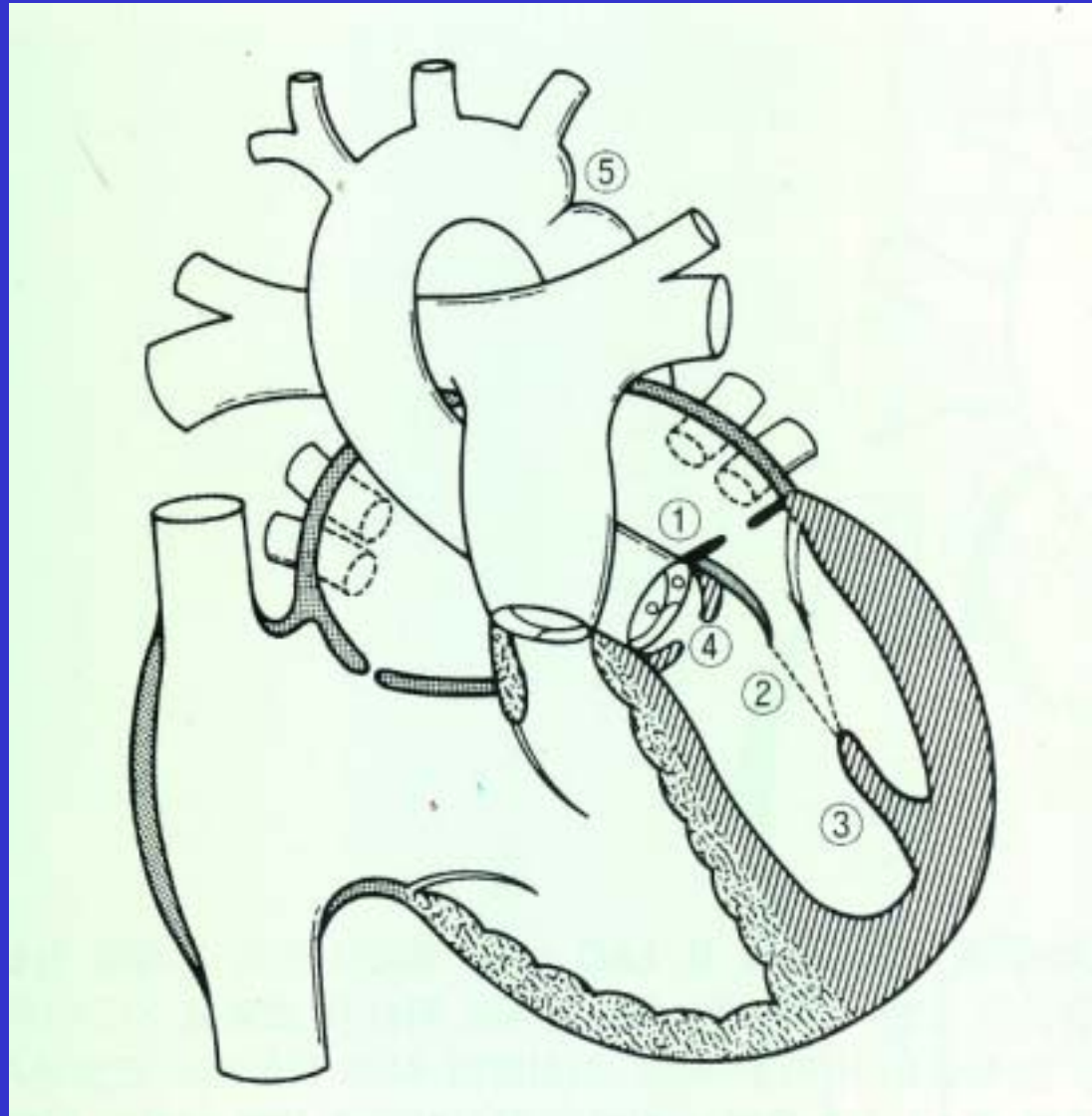
# Cor triatriatum of the left atrium & supra-valvular mitral ring

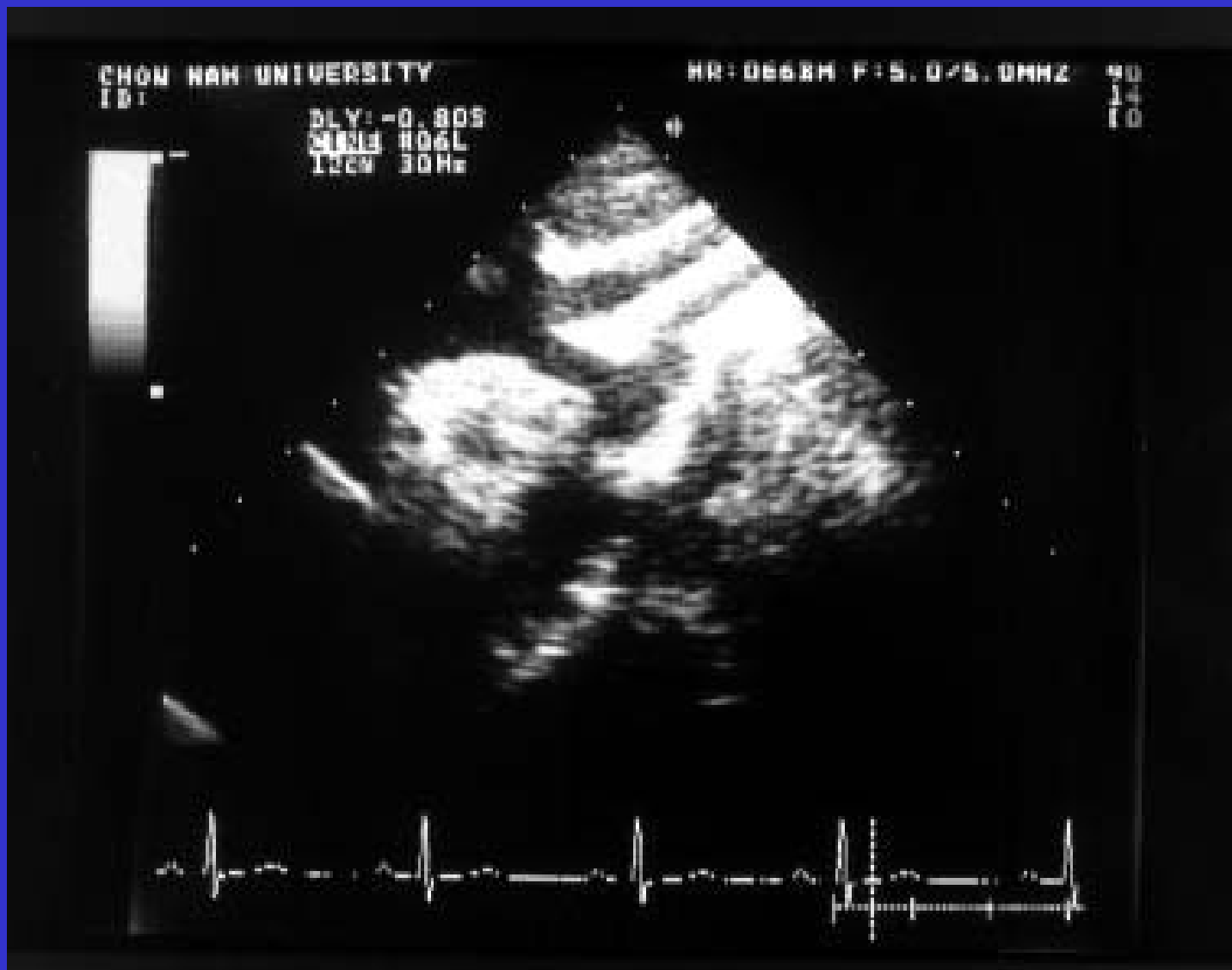


**supravalvular  
mitral ring  
(SVR)**



# Shone complex



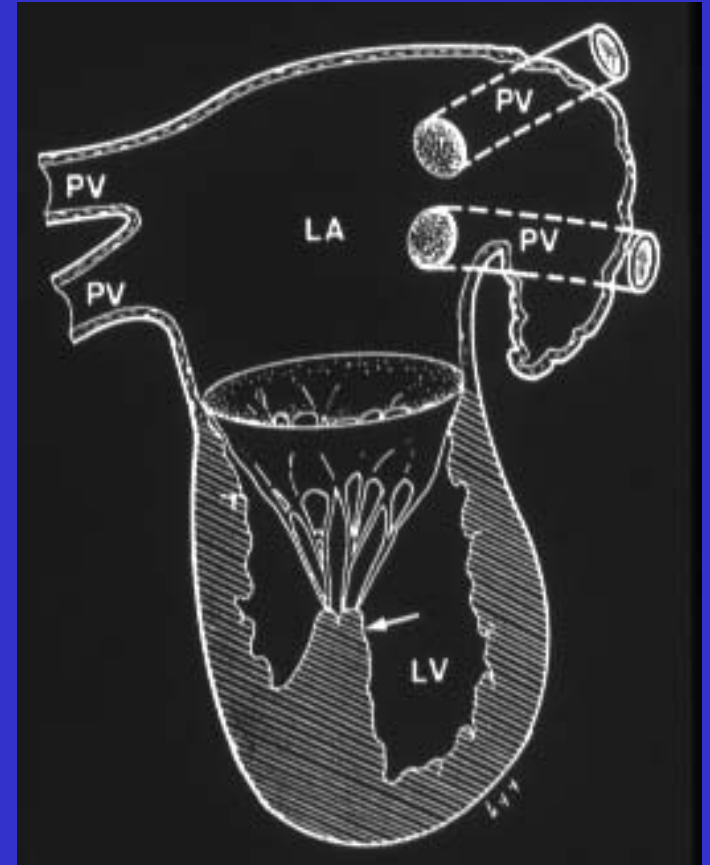
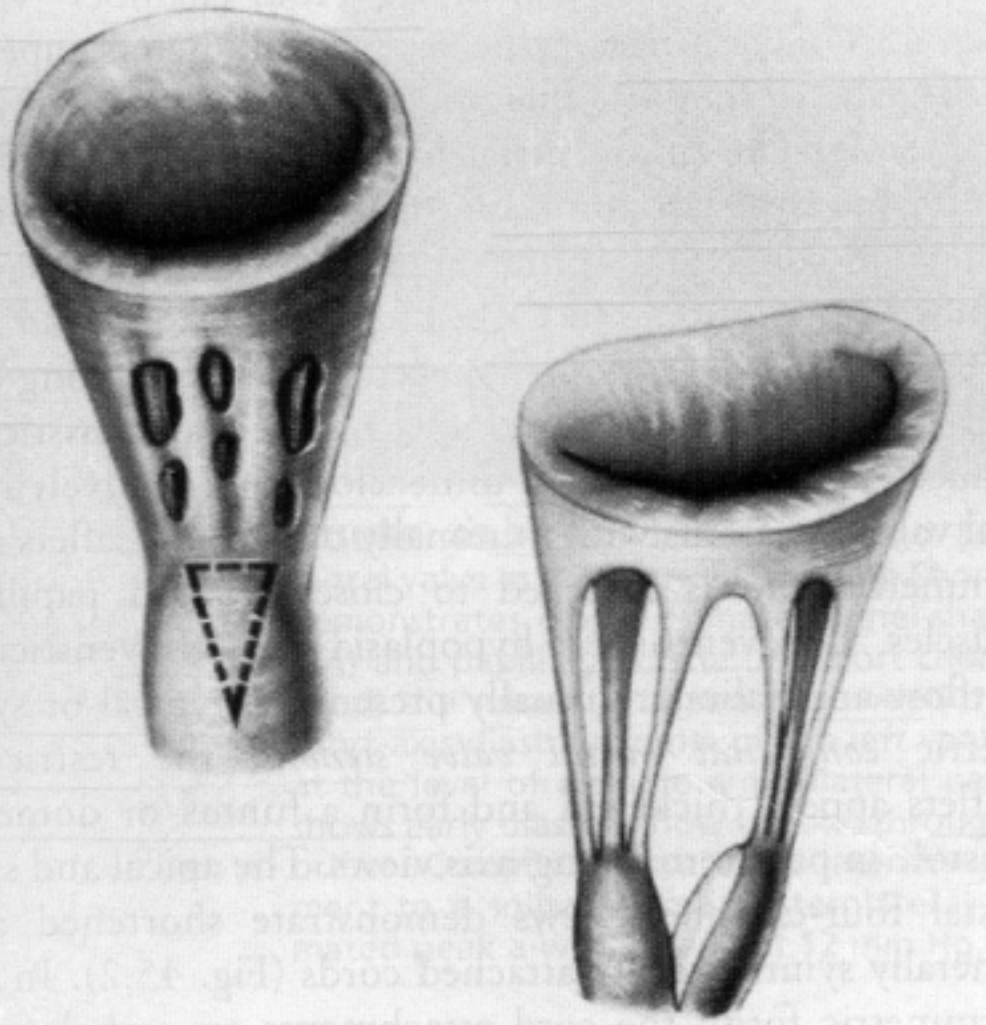


**Shone syndrome with COA**

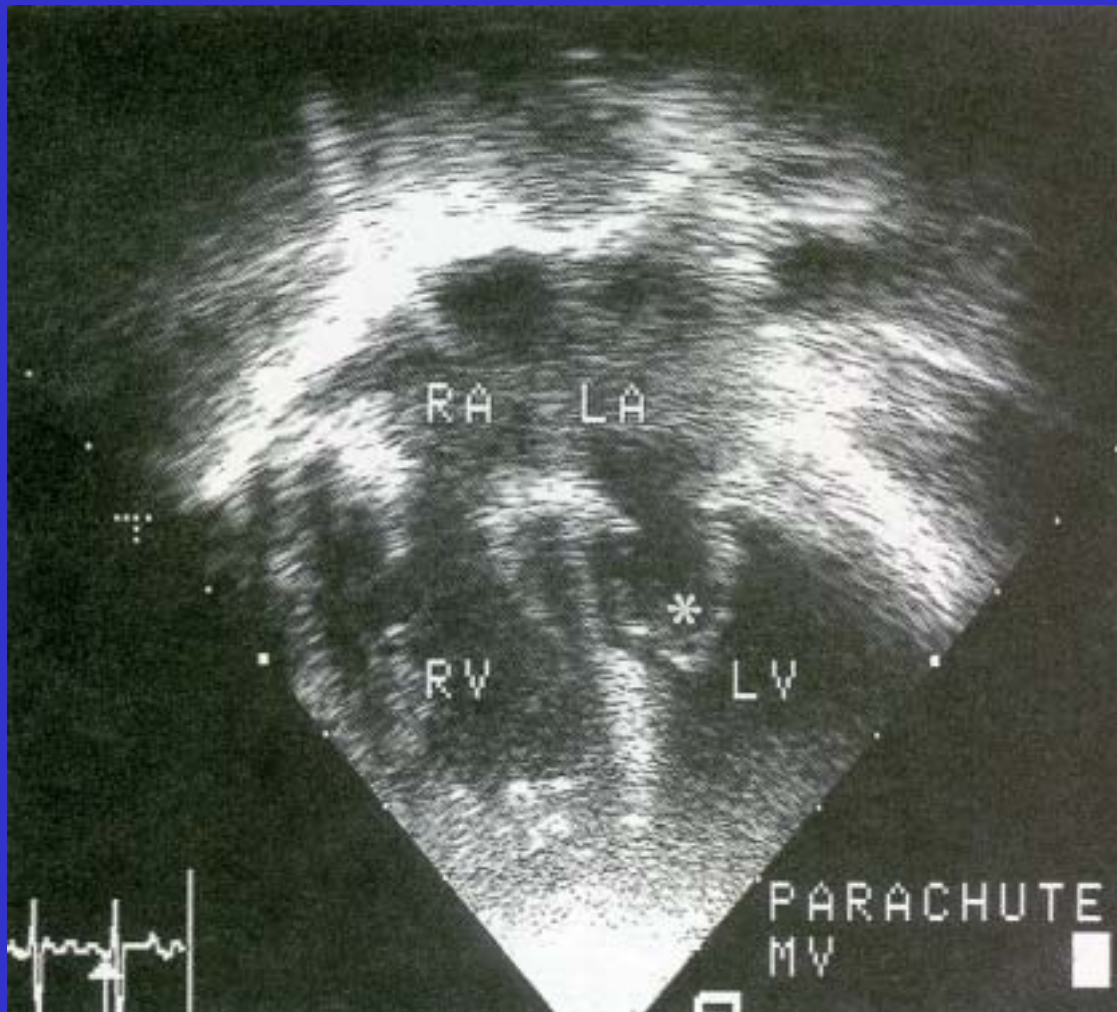


2004 9 19

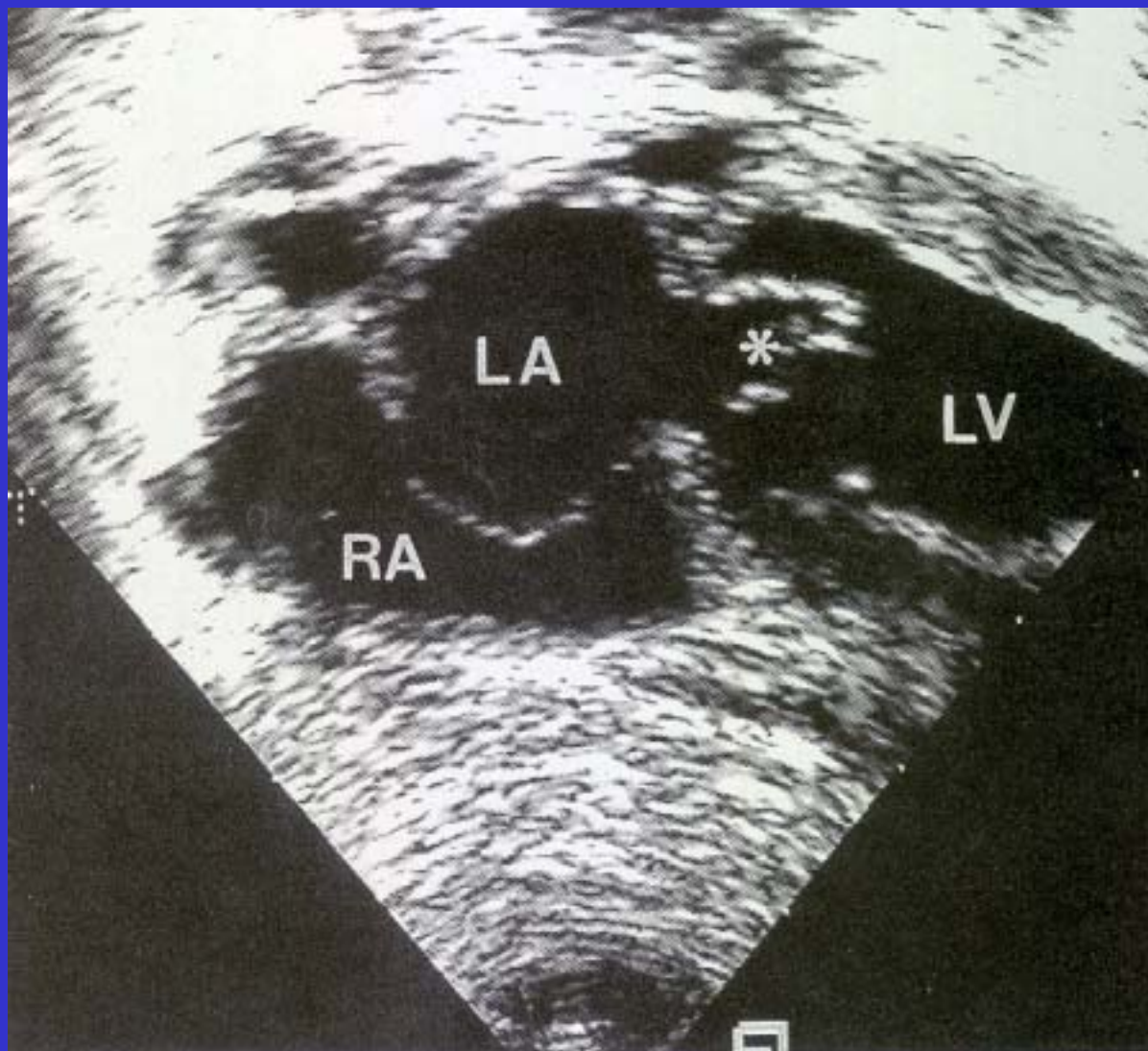
# Parachute Mitral Valve



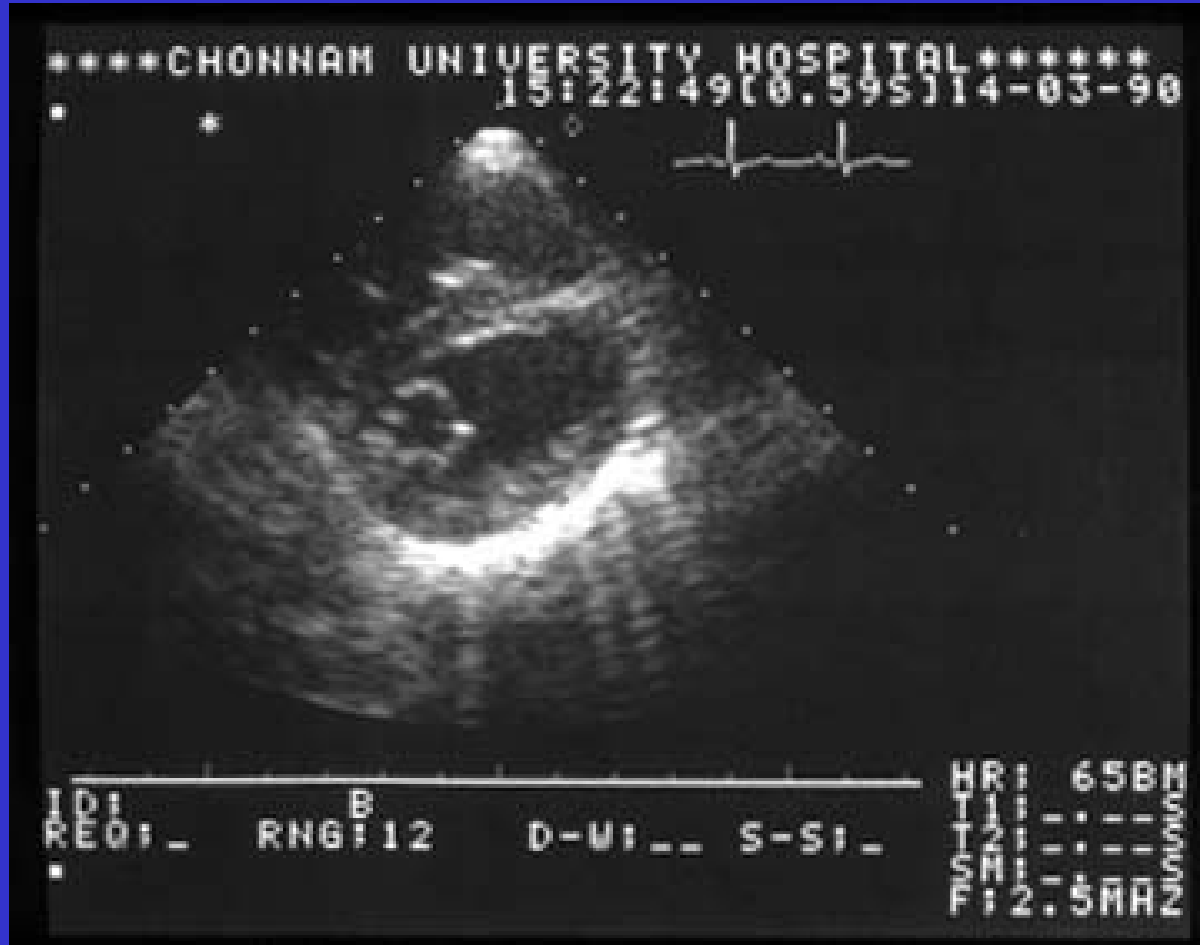# Parachute Mitral Valve



# Parachute Mitral Valve

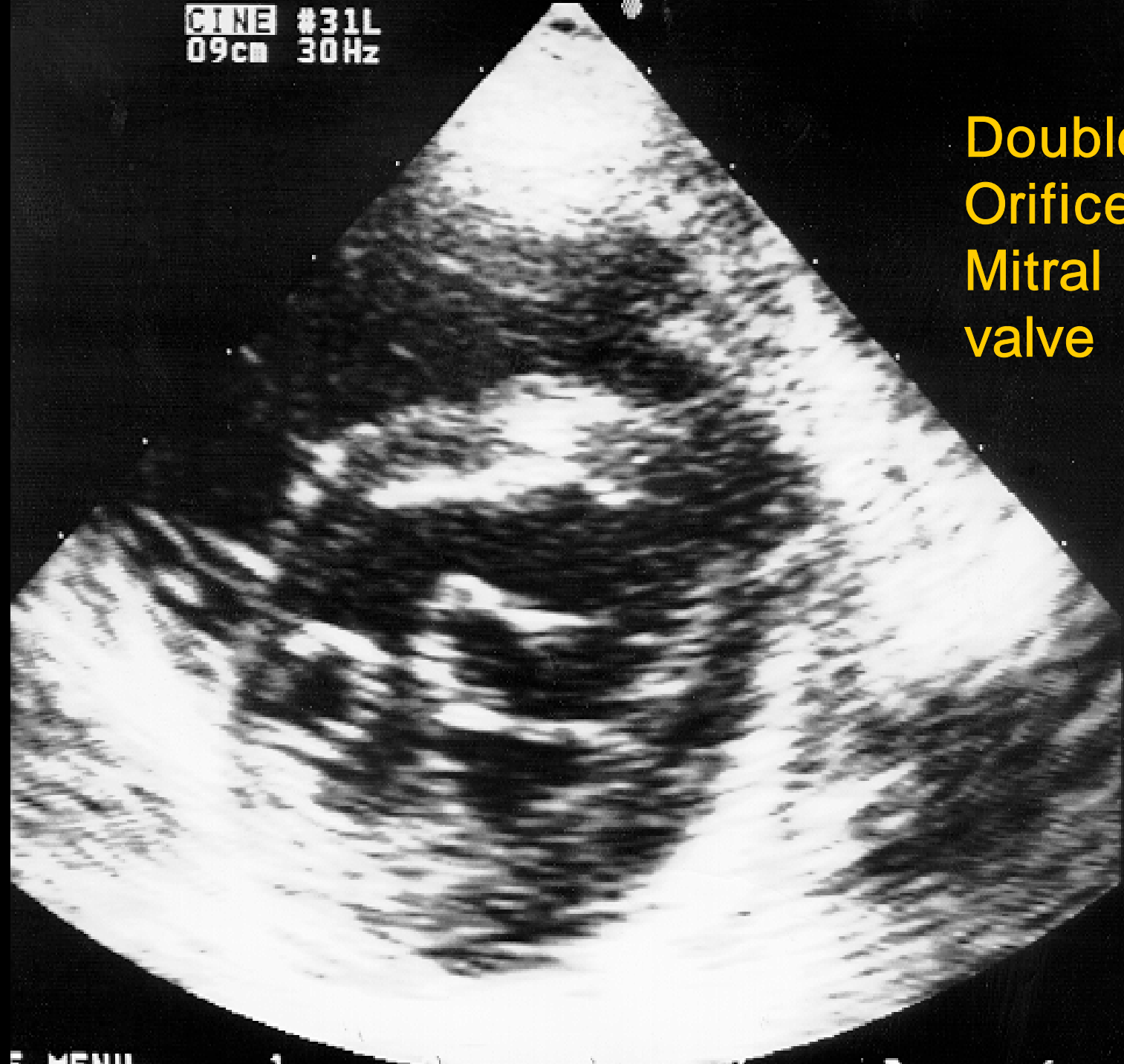


# Parachute Mitral Valve

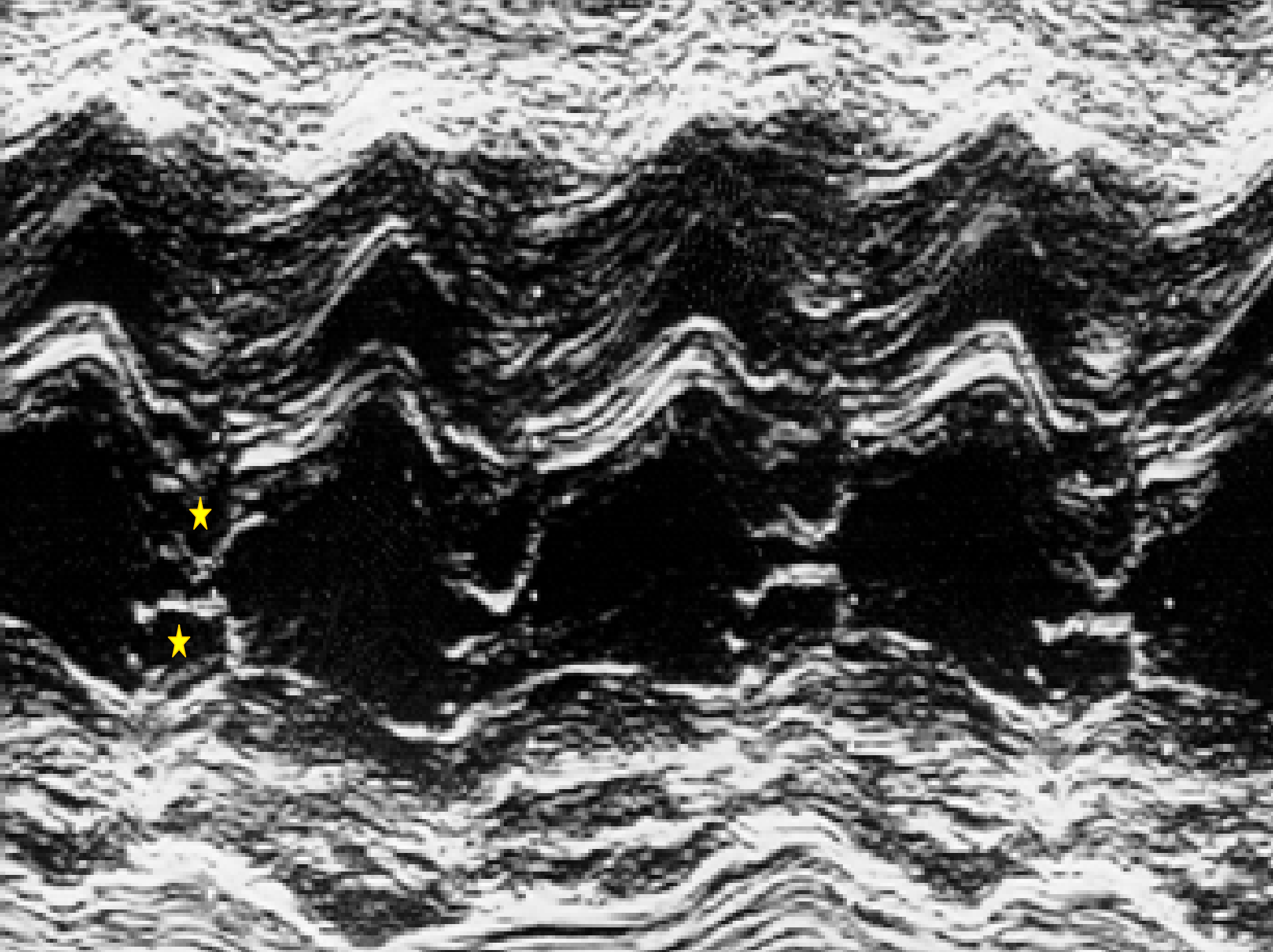


CINE #31L  
09cm 30Hz

Double  
Orifice  
Mitral  
valve

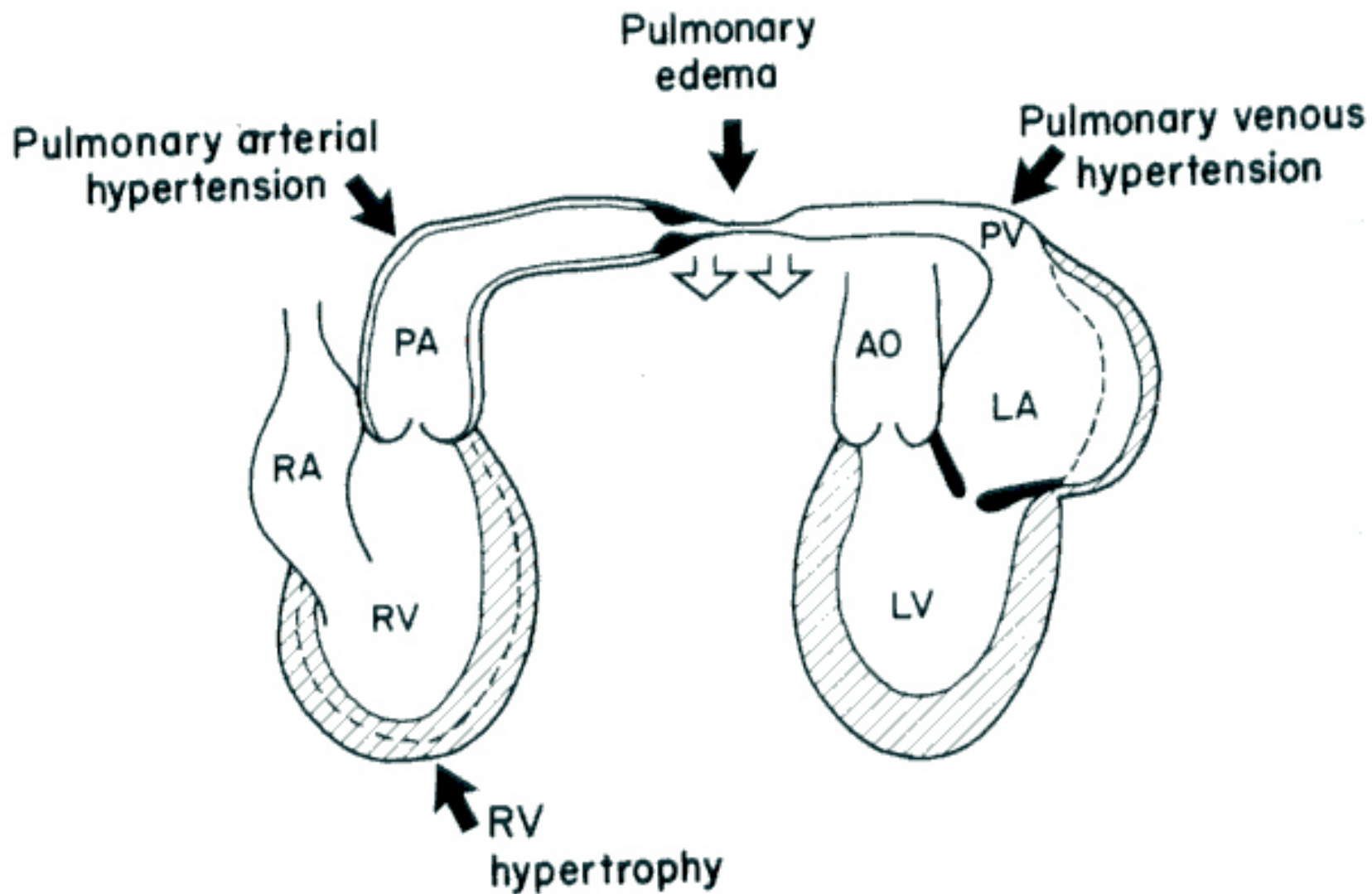


F MENU

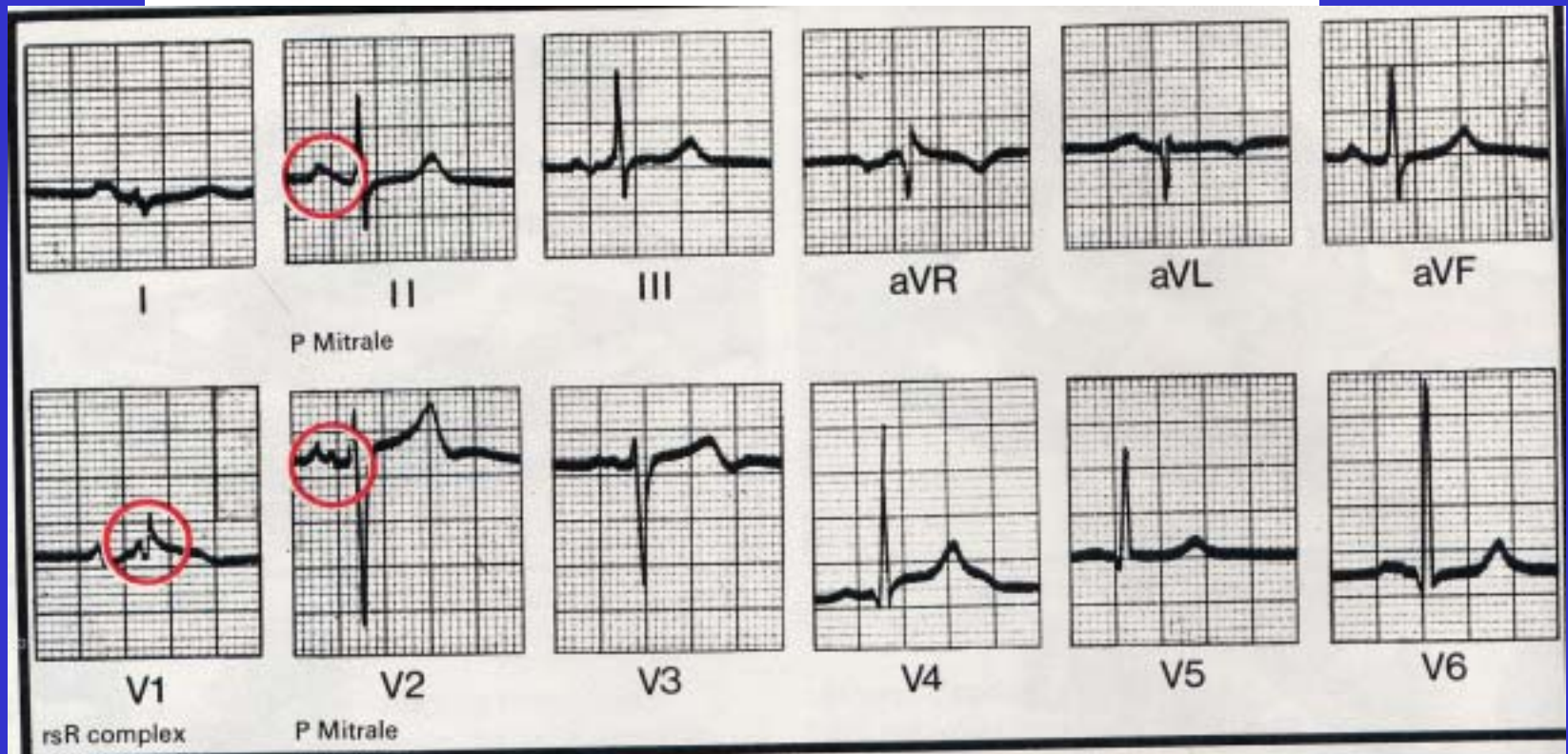
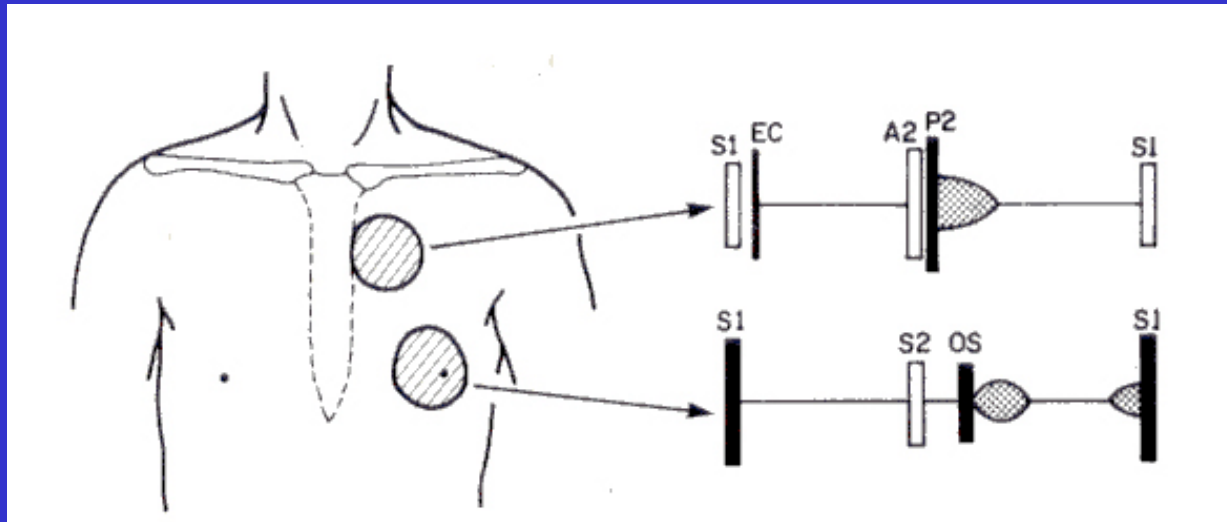


# Clinical Manifestations - Mitral Stenosis

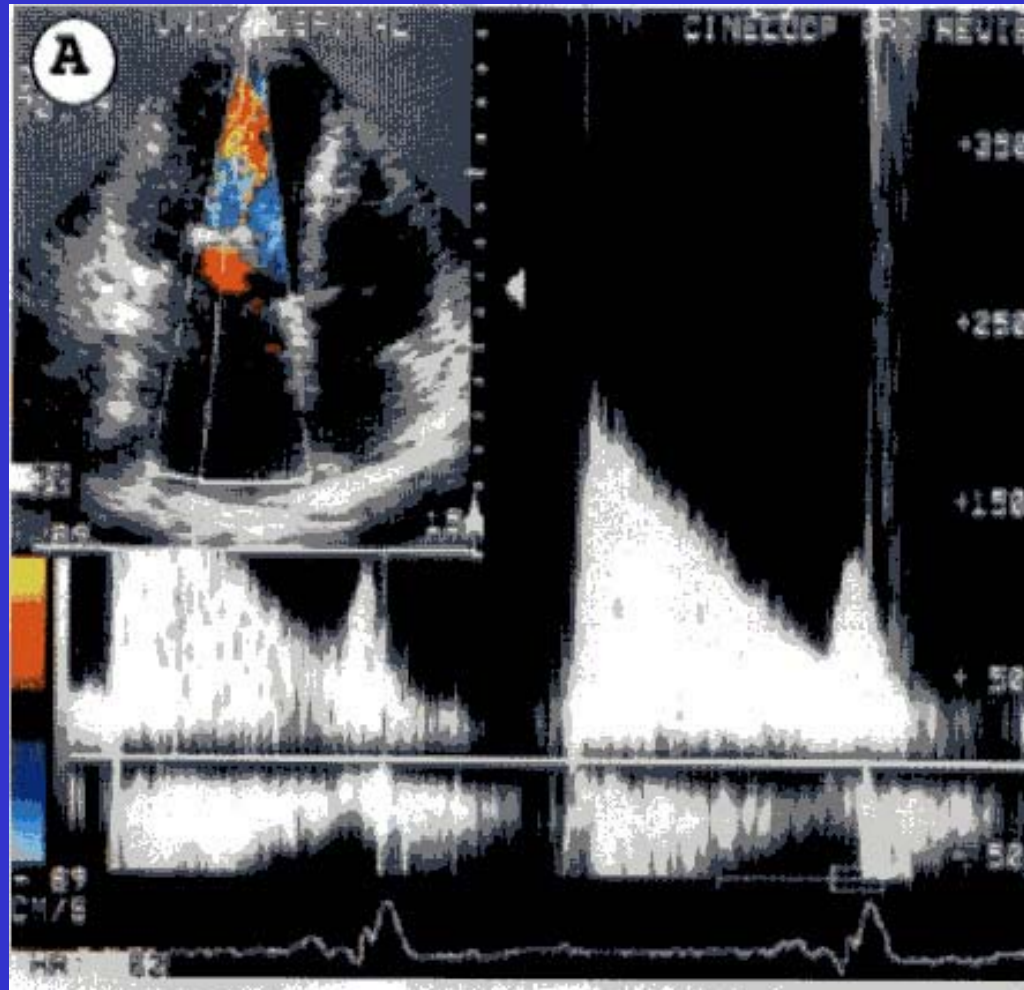
- Congestive heart failure < 2 yr : rare hypoplastic left heart physiology
- Sx < 1 yr
  - pulmonary edema, CHF
  - growth failure, tachypnea,
  - dyspnea, pallor, frequent
  - URI, cyanosis
- Older child:
  - exertional dyspnea, fatigue, intermittent pulmonary edema



# Mitral Stenosis



# Mitral Stenosis



# Mitral Stenosis

## Management, Prognosis

- Balloon valvuloplasty
- Operation

# Mitral regurgitation lesions

- **Congenital mitral valve insufficiency**
  - **Mitral arcade**
  - **MVP syndrome**

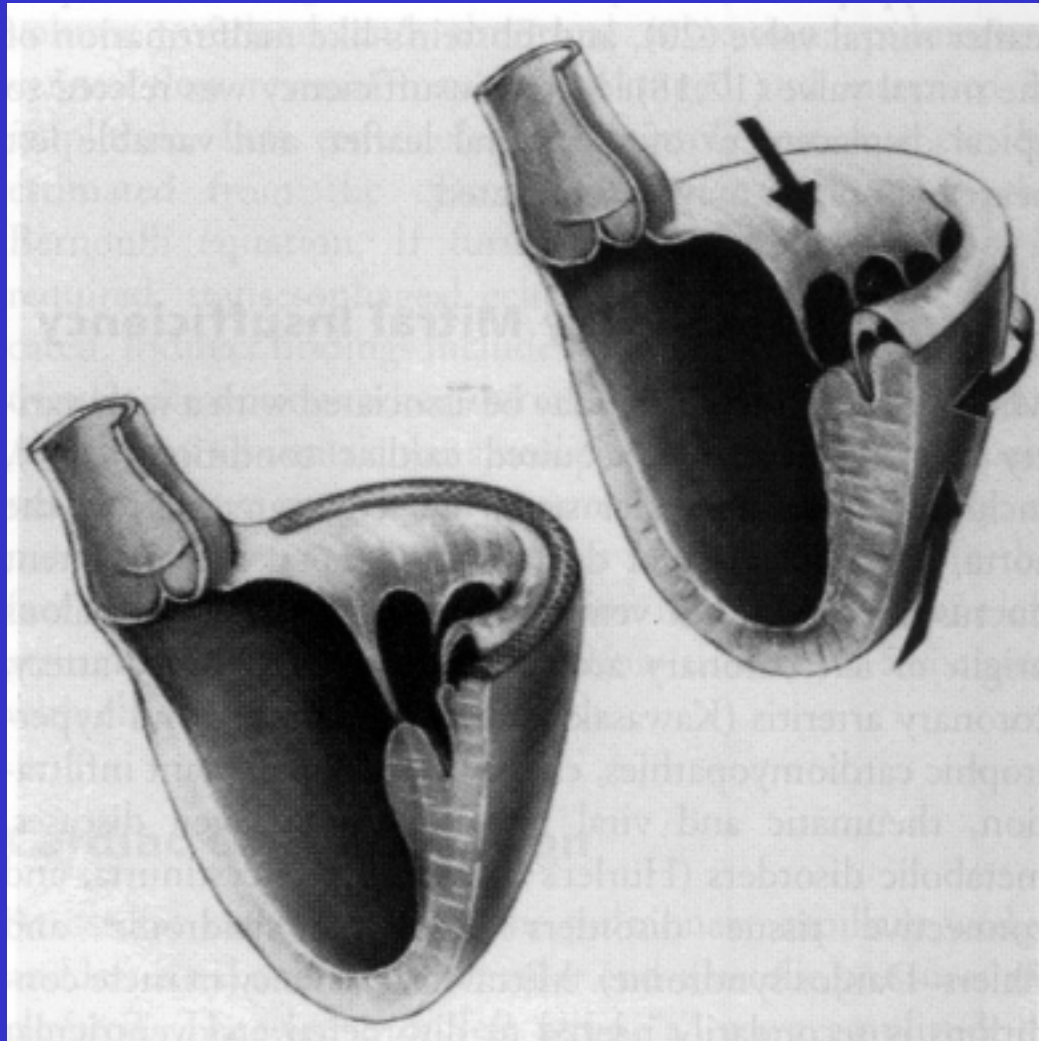
# Congenital mitral valve insufficiency

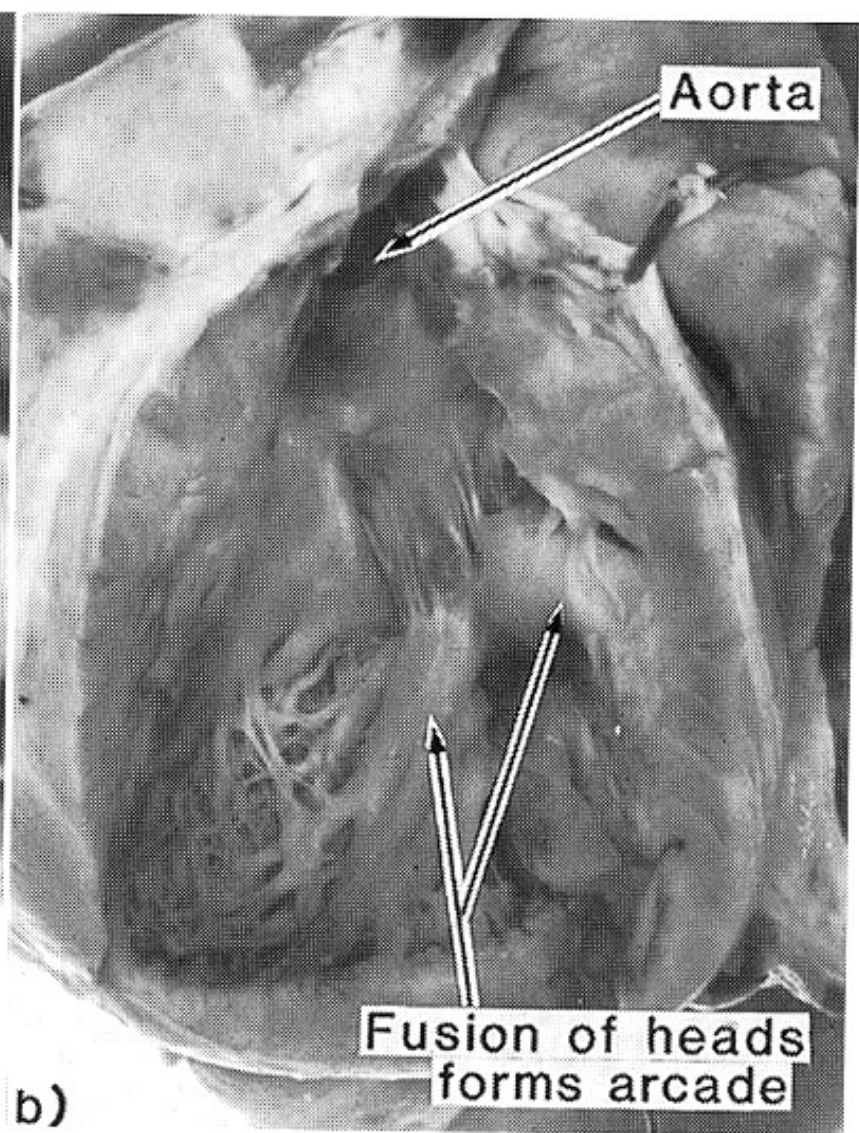
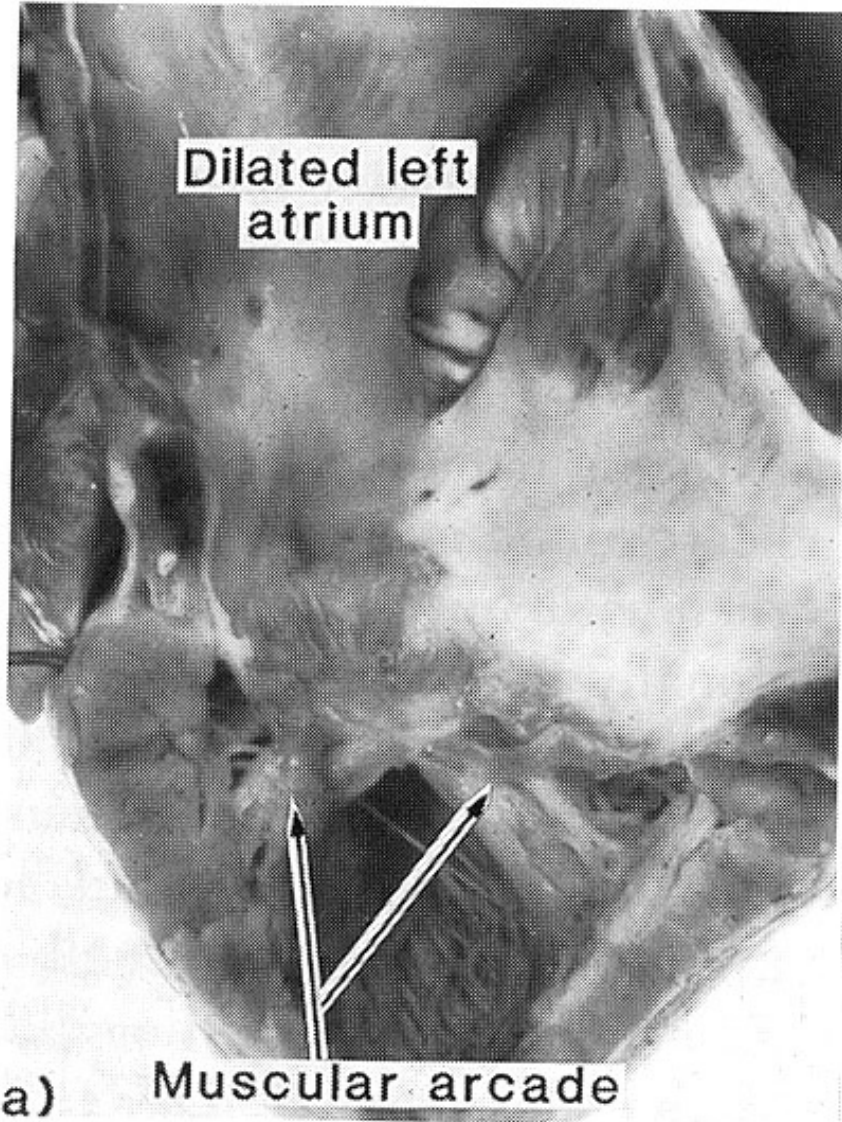
- Isolated
- VSD
- PDA
- Cardiomyopathy
- Coronary artery diseases
- Marfan syndrome

# Congenital mitral valve insufficiency - Pathology

- 
- Mitral valve prolapse
- 
- Mitral cleft
- Mitral arcade
-

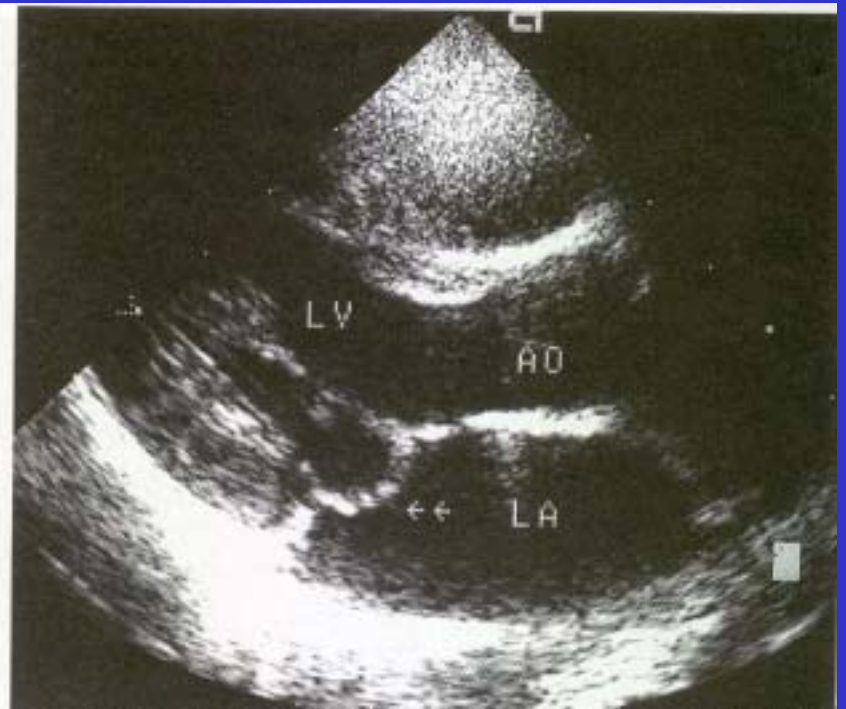
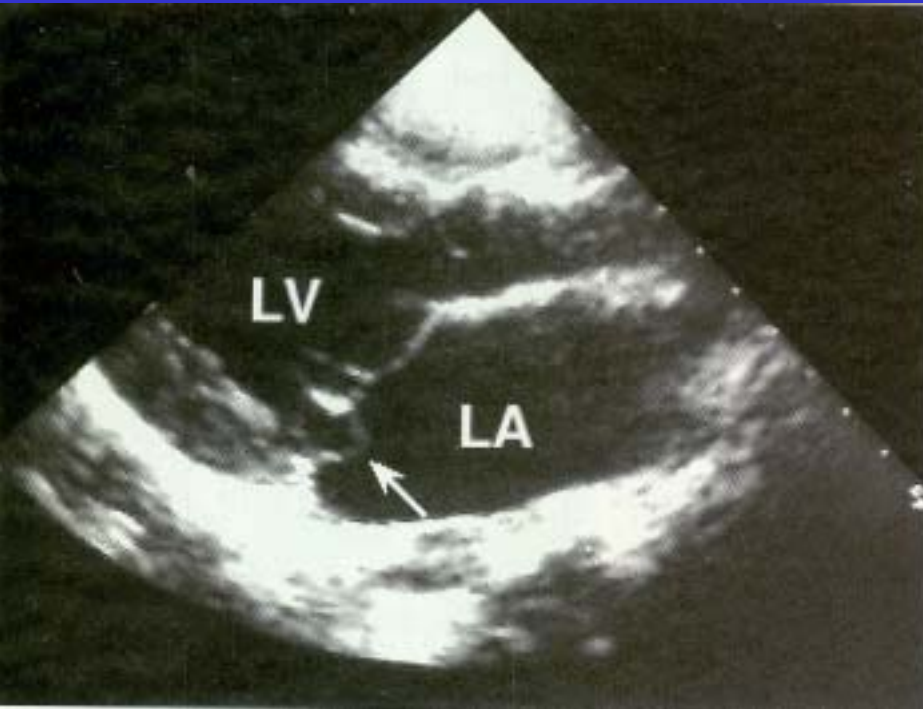
# mitral arcade



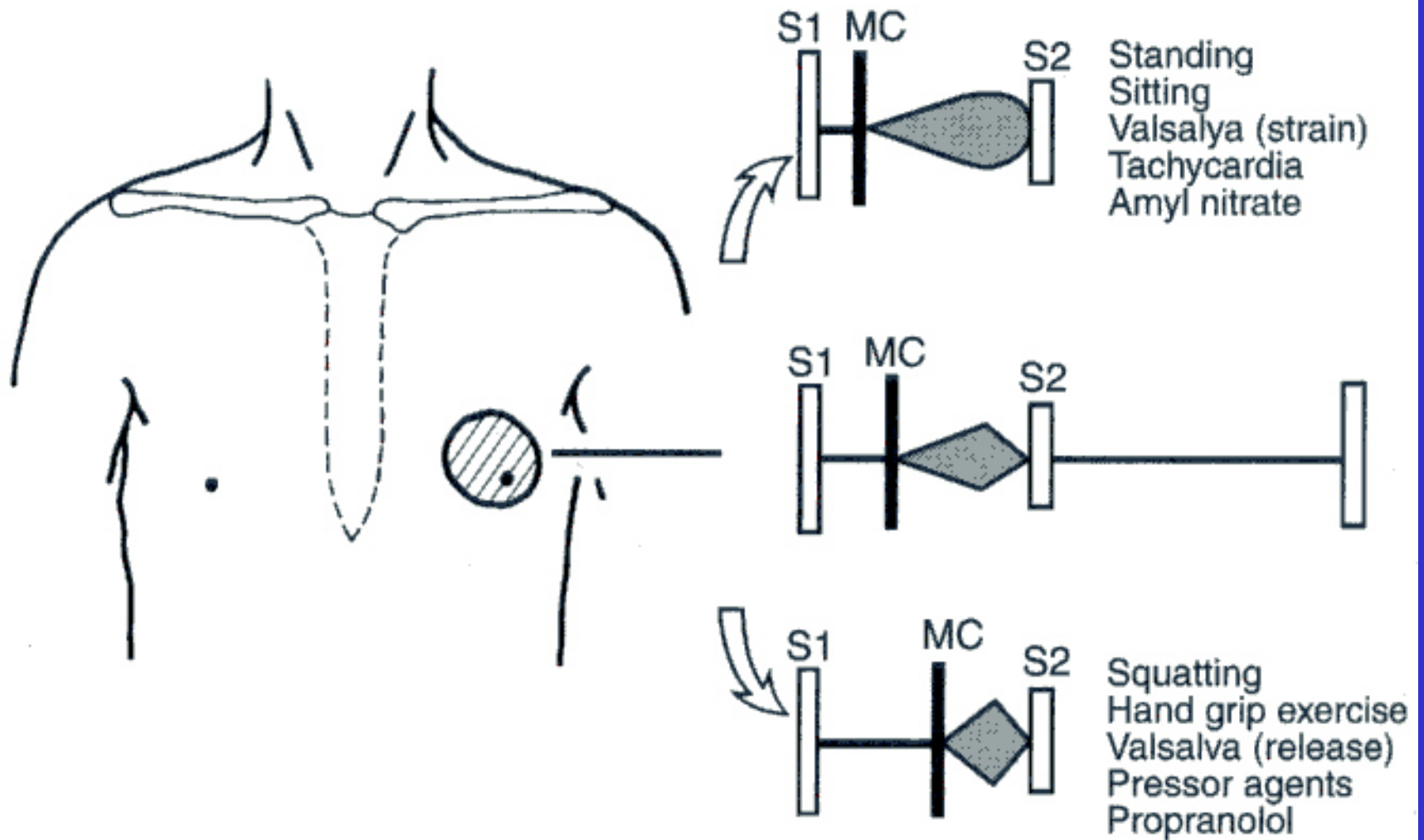


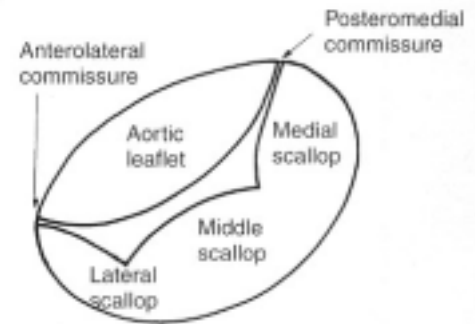
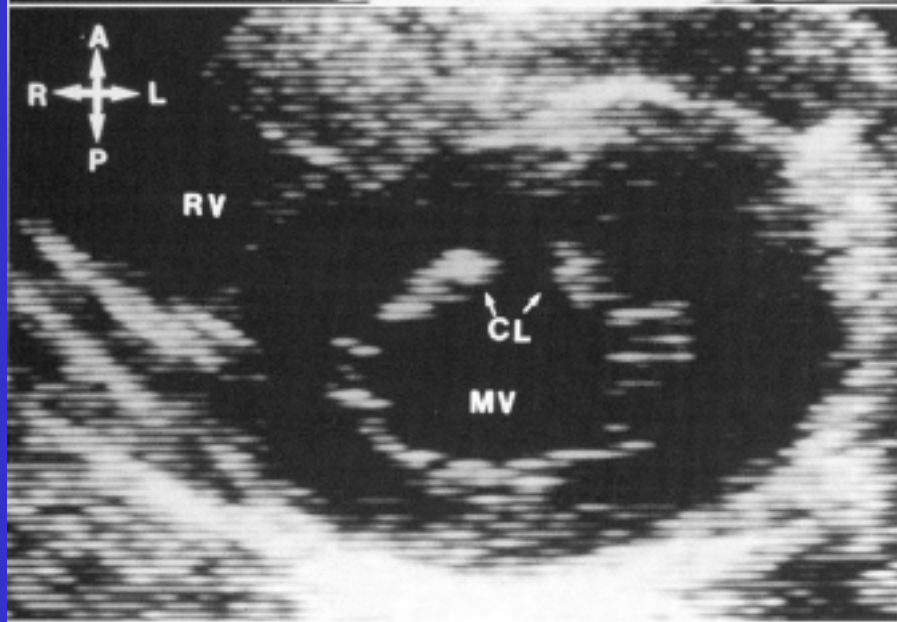
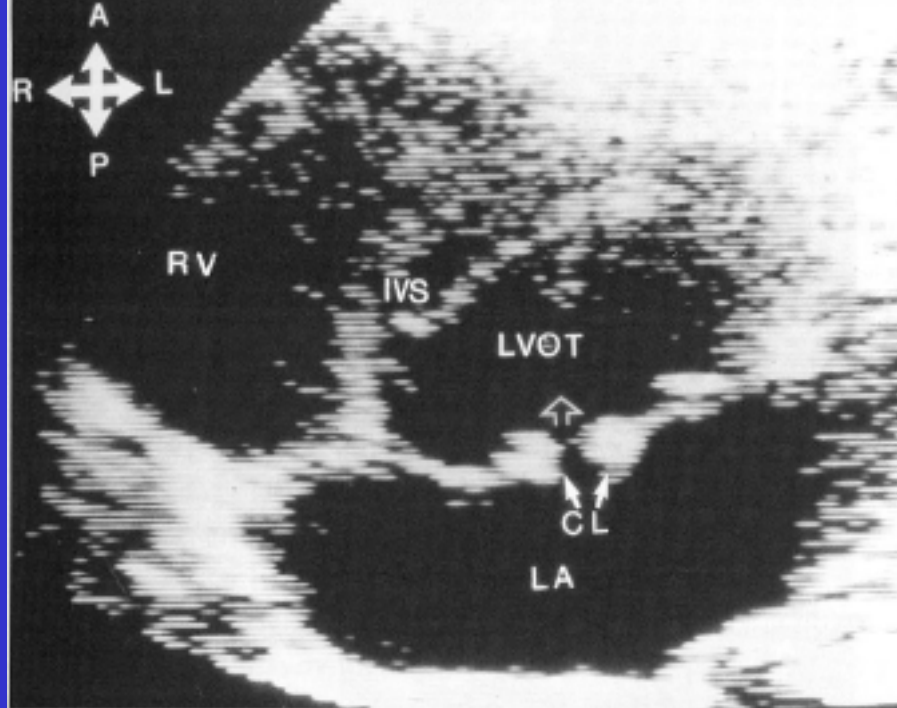
**Mitral valve arcade(Hammock valve)**

# Mitral valve prolapse

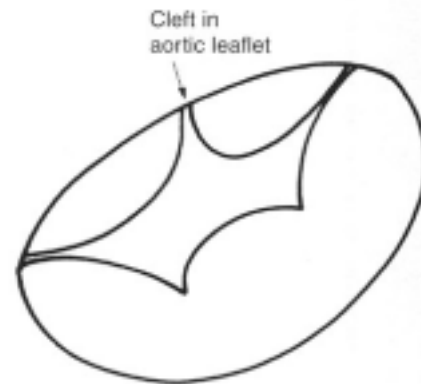

# Mitral valve prolapse

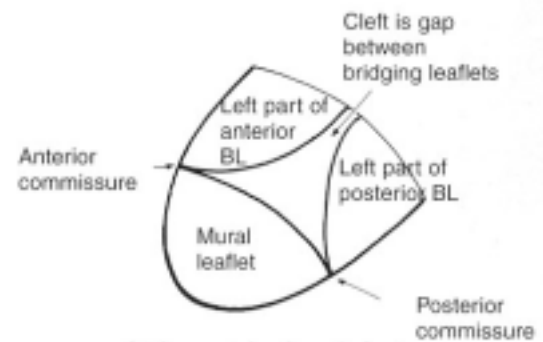




Normal



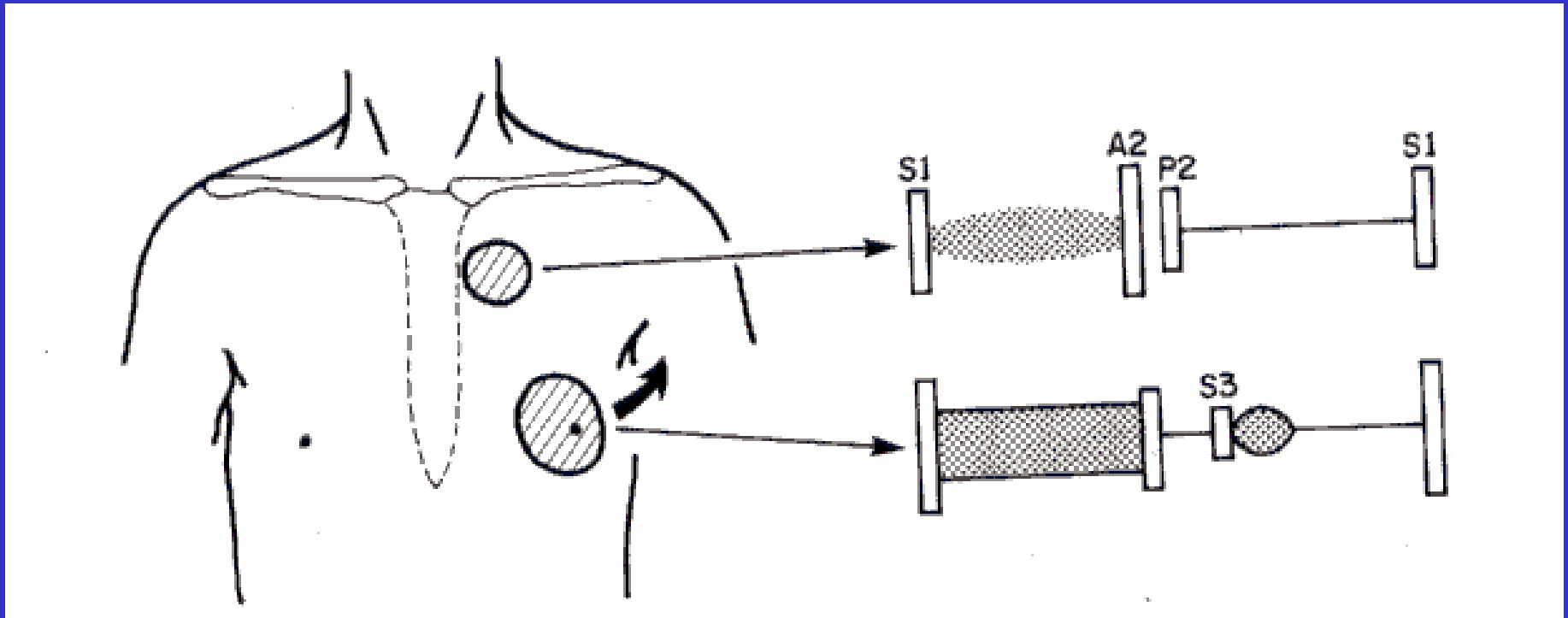
Isolated cleft



Atrioventricular defect

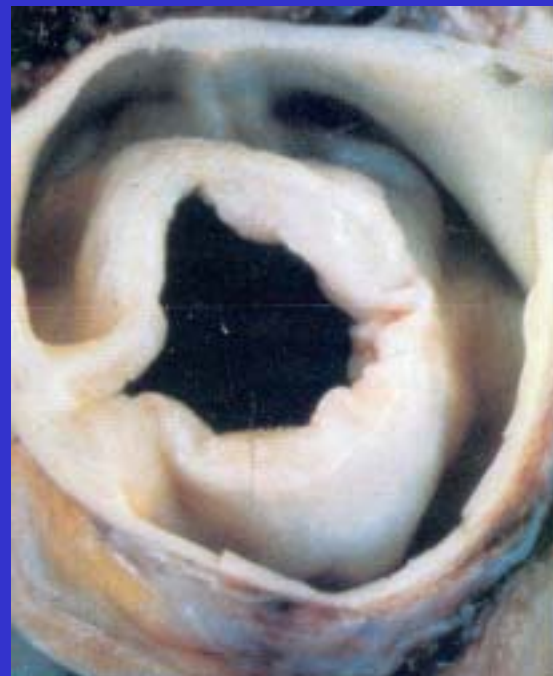
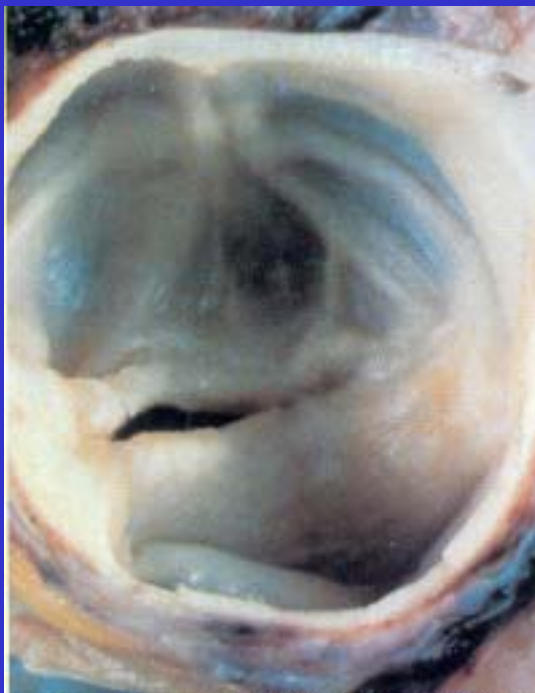
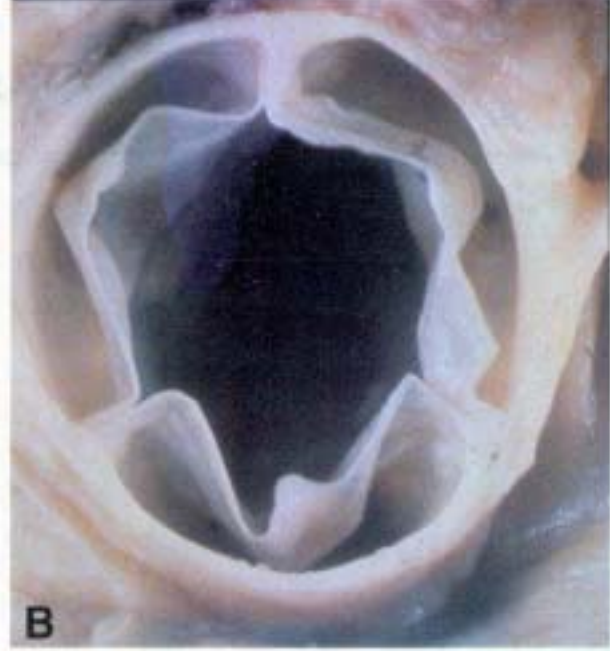
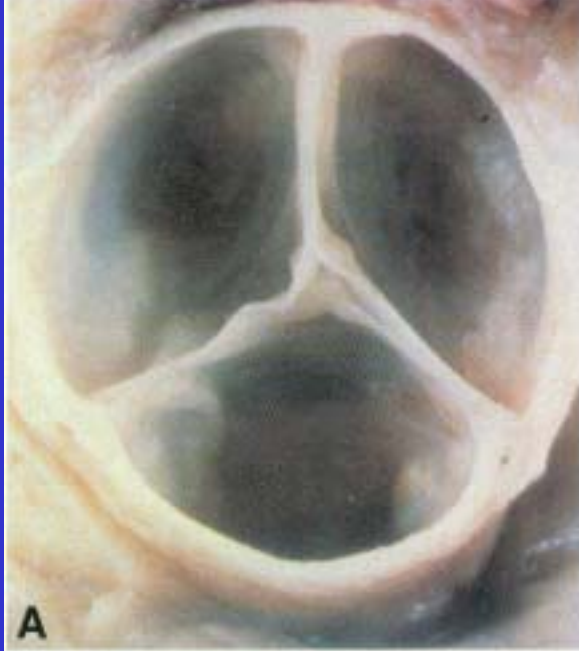# Mitral cleft

# Mitral regurgitation lesions





2003 10 5



# Congenital Aortic Stenosis

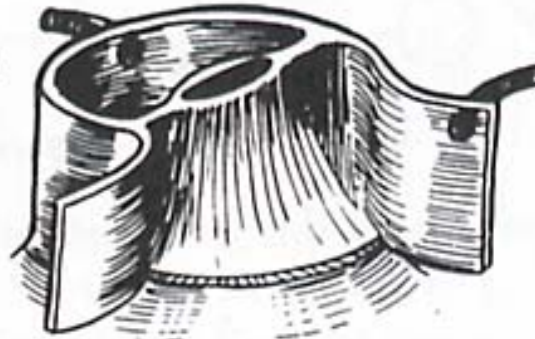
- **Valvular**
- **Subaortic**
  - **Subaortic membrane or ridge**
  - **Fibromuscular stenosis**
- **supravalvular**

# Congenital Aortic Stenosis

A  
UNICUSP



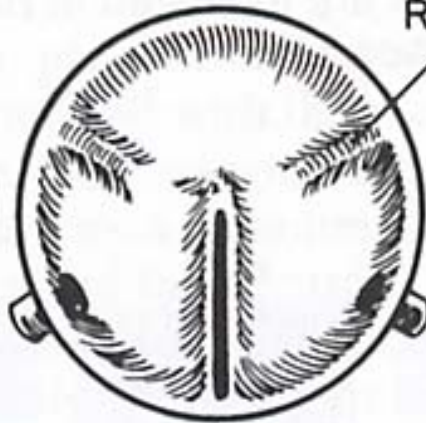
B  
BICUSP



C  
DOME

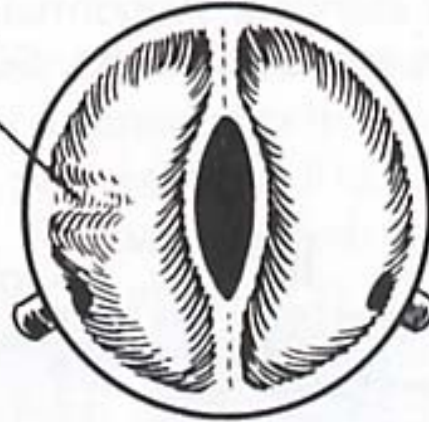


A<sub>1</sub>



RAPHE

B<sub>1</sub>

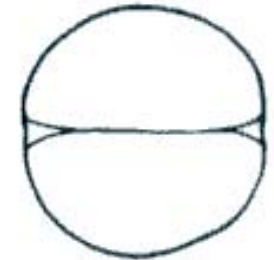
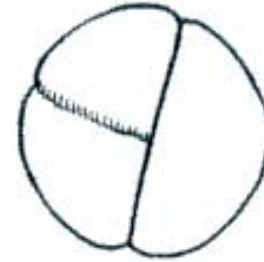
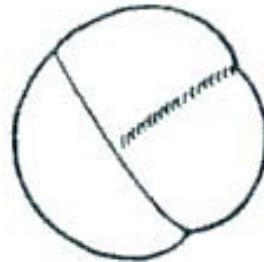
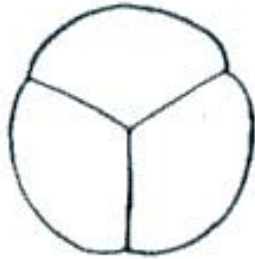
C<sub>1</sub>

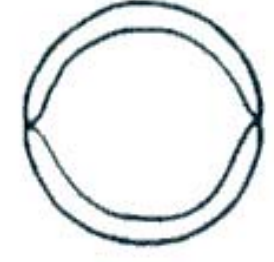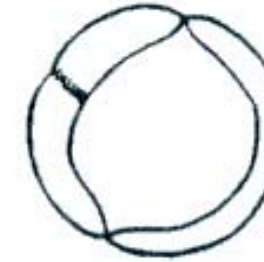
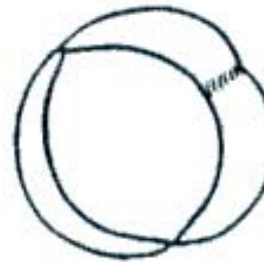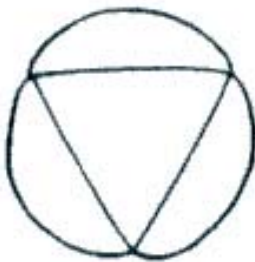


# Congenital Aortic Stenosis

DIASTOLE



SYSTOLE



NORMAL  
TRICUSPID  
AORTIC VALVE

(45%)

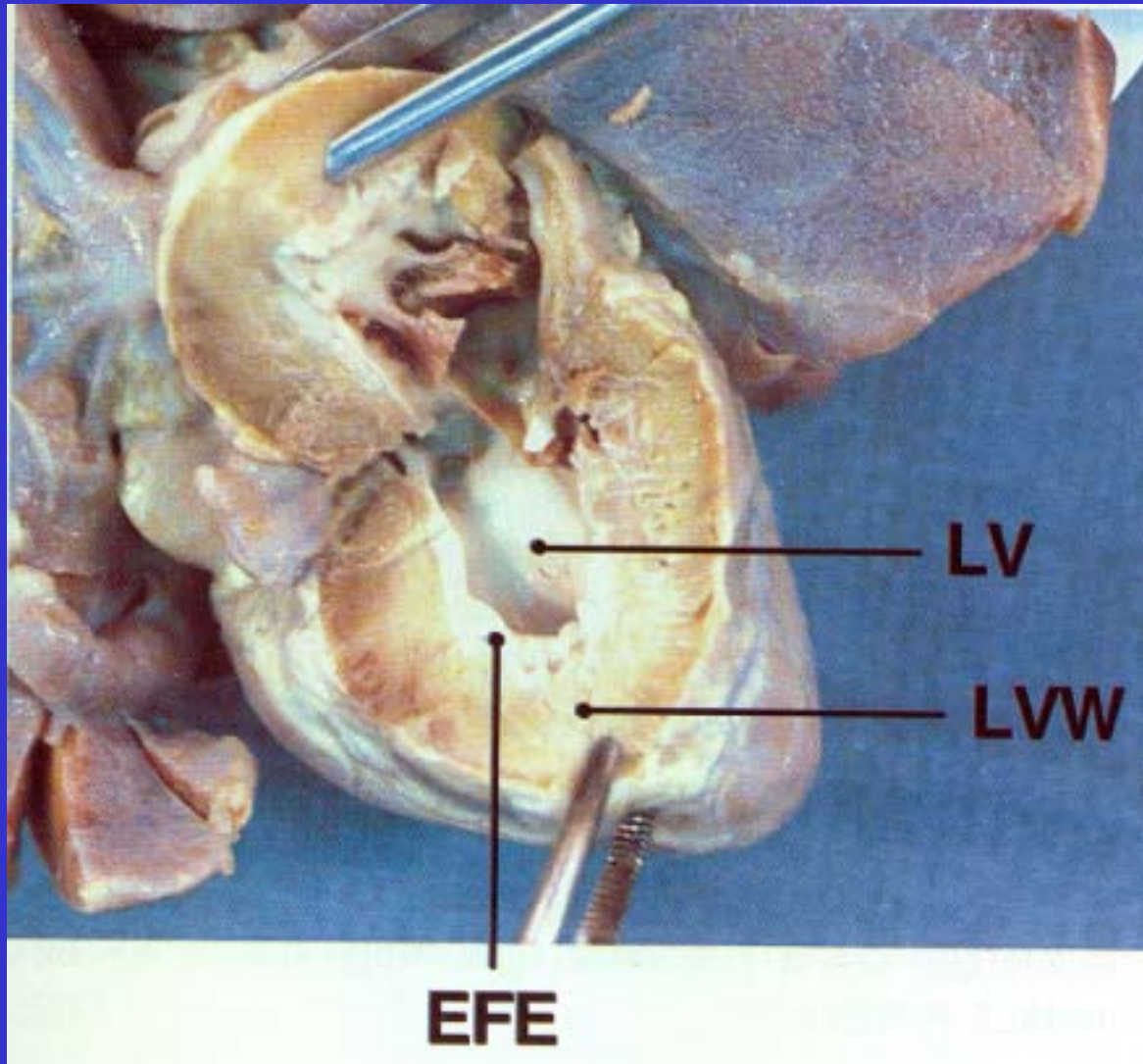
(32%)

(14%)

BICUSPID AORTIC VALVE

# Critical AS

-hypoplastic left heart physiology-



# Congenital Aortic Stenosis

- associated anomalies -

Supravalvular or subvalvular AS

COA

Hypoplastic left heart syndrome

EFE

Congenital MS or MR

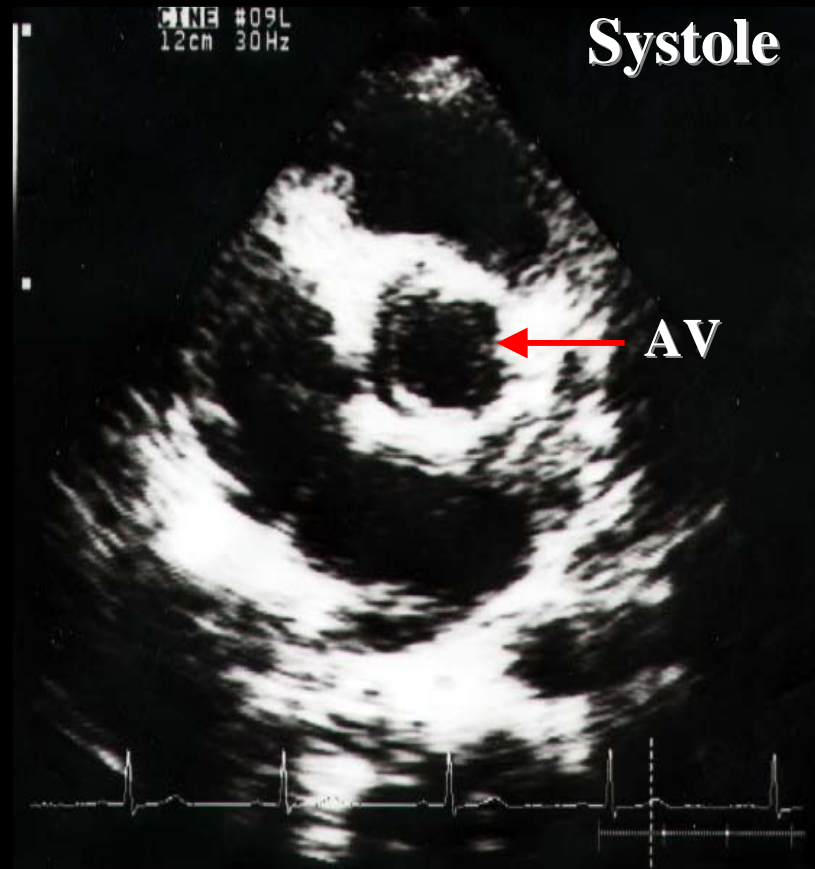
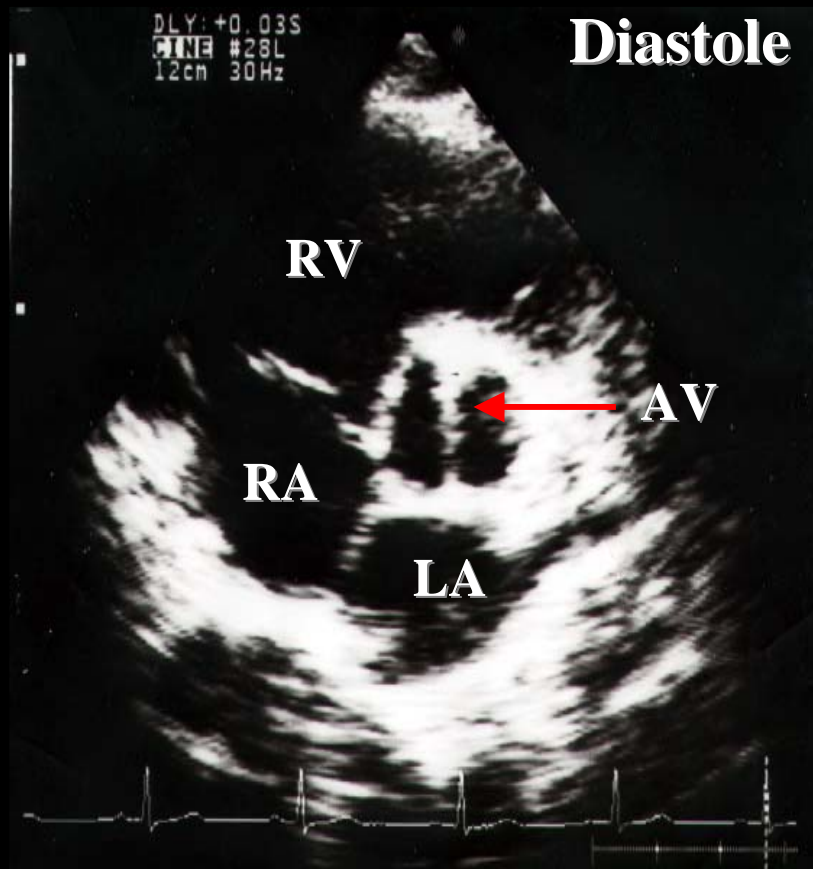
Complex COA

subvalvular AS secondary to mitral anomalies

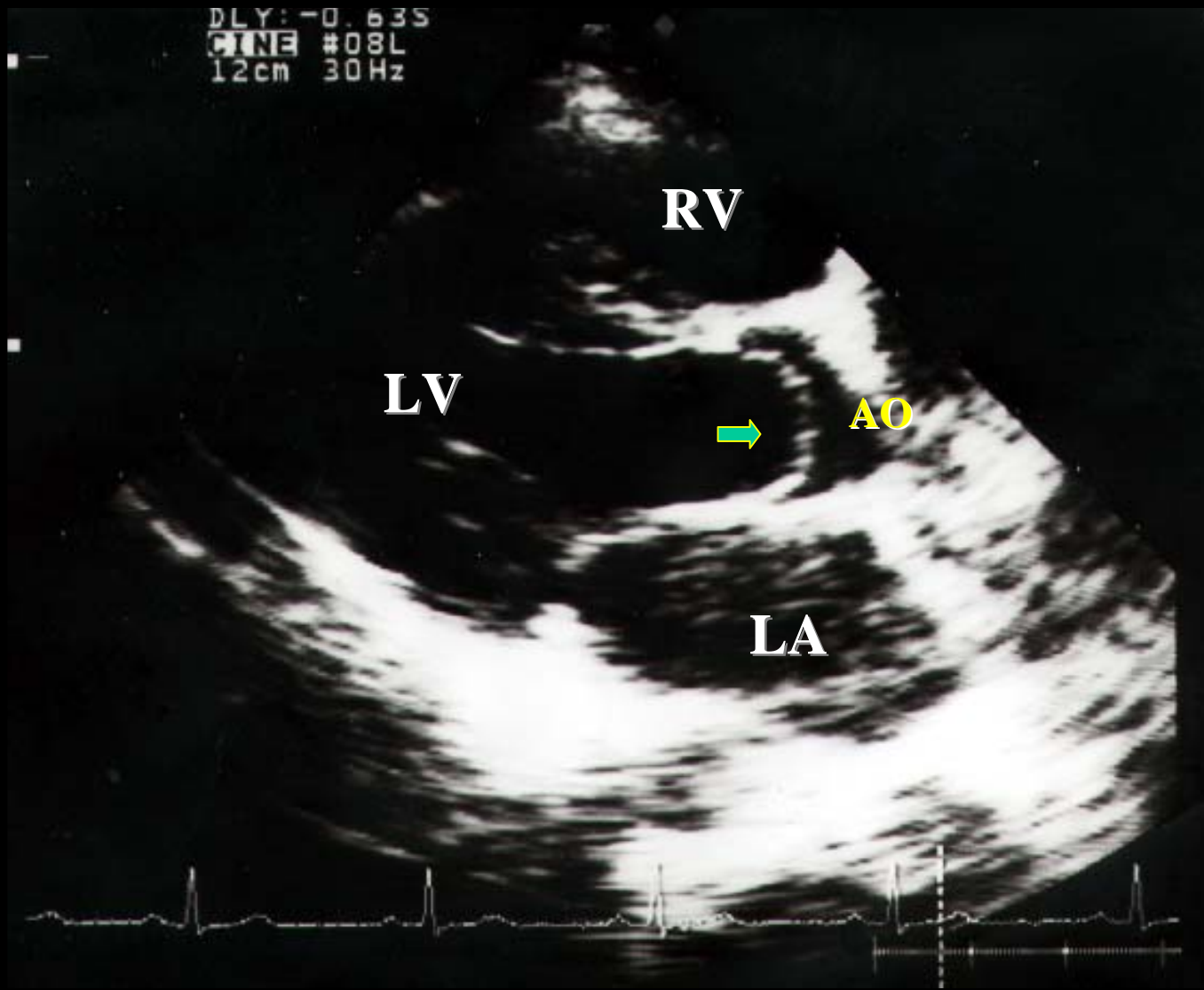
PDA

VSD

Pulmonary atresia

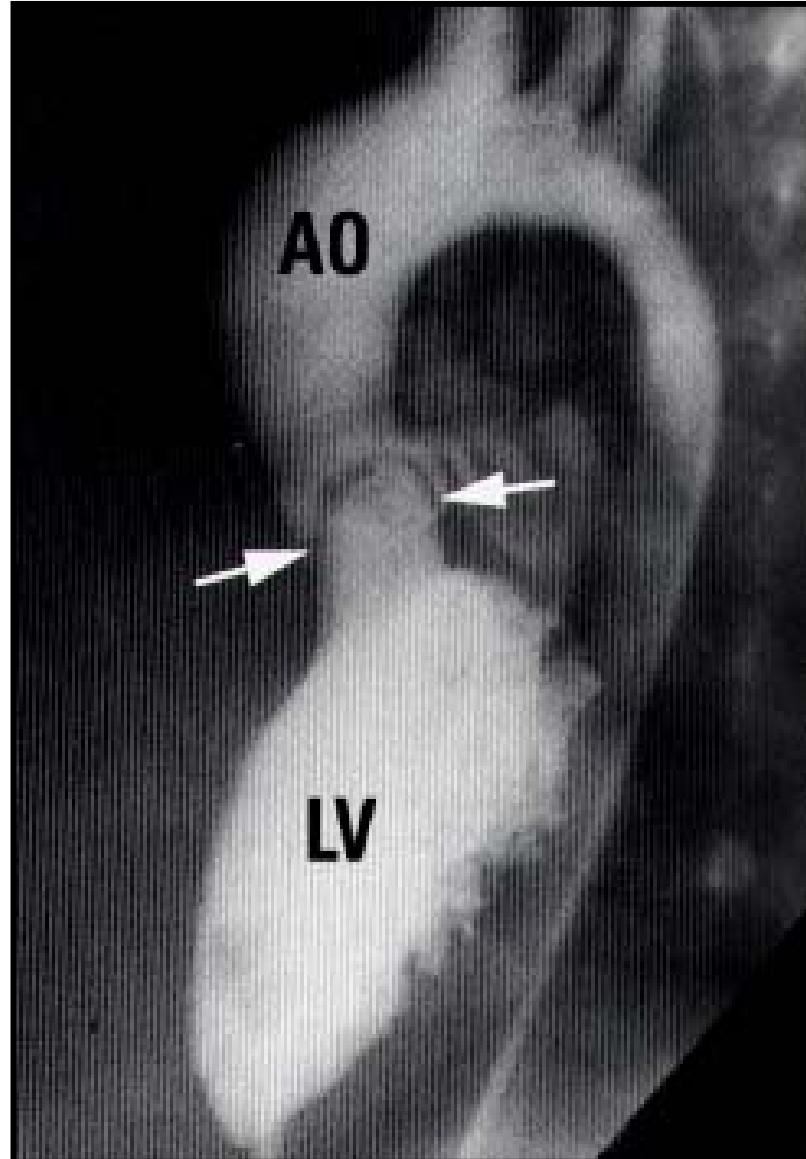
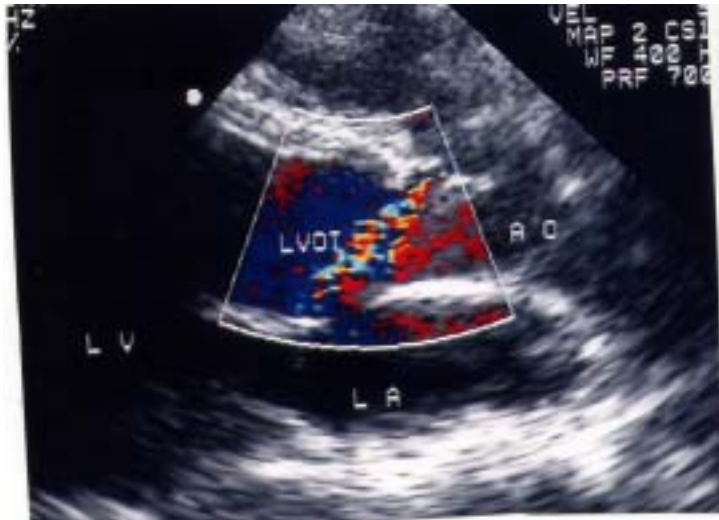
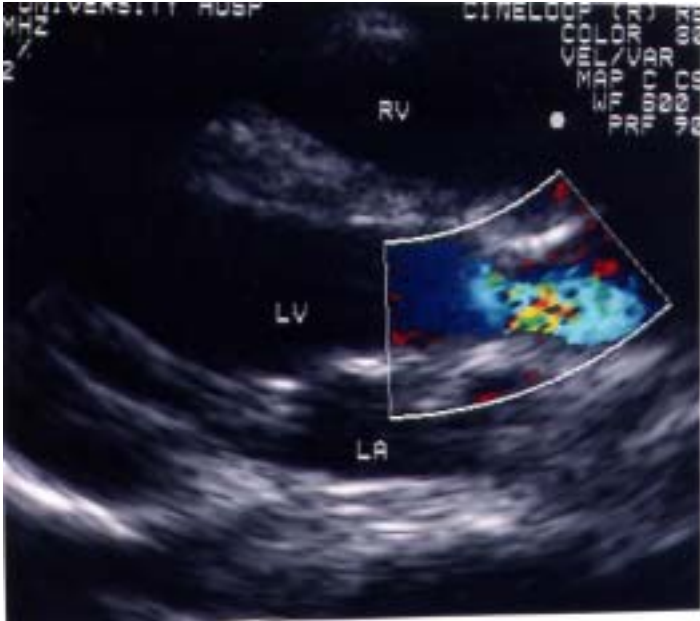
**9** , Congenital AS with bicuspid AV



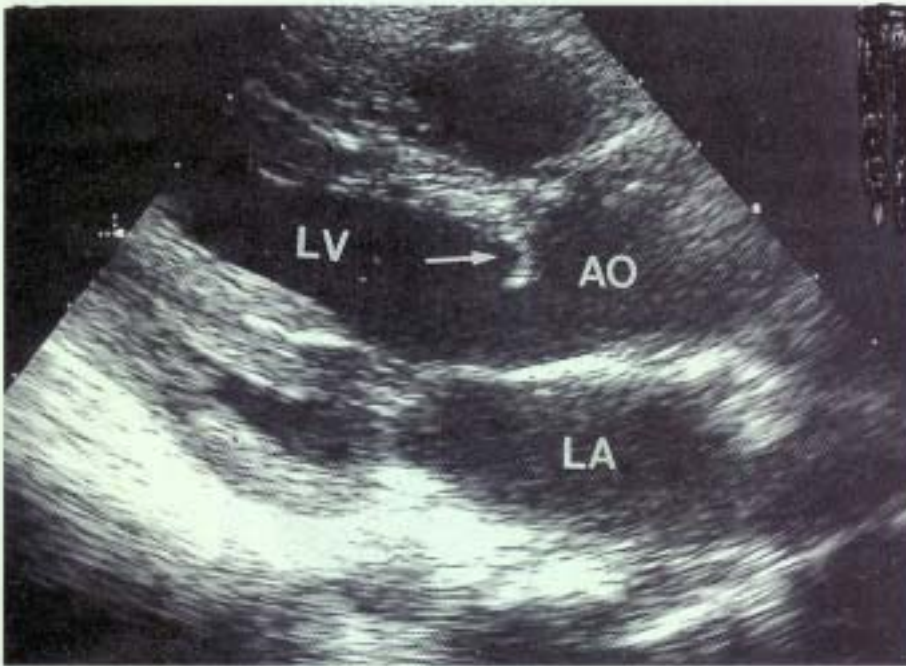**Parasternal long axis view showing doming of AV (arrow) in a 9 year-old boy with congenital AS**

# Congenital Aortic Stenosis

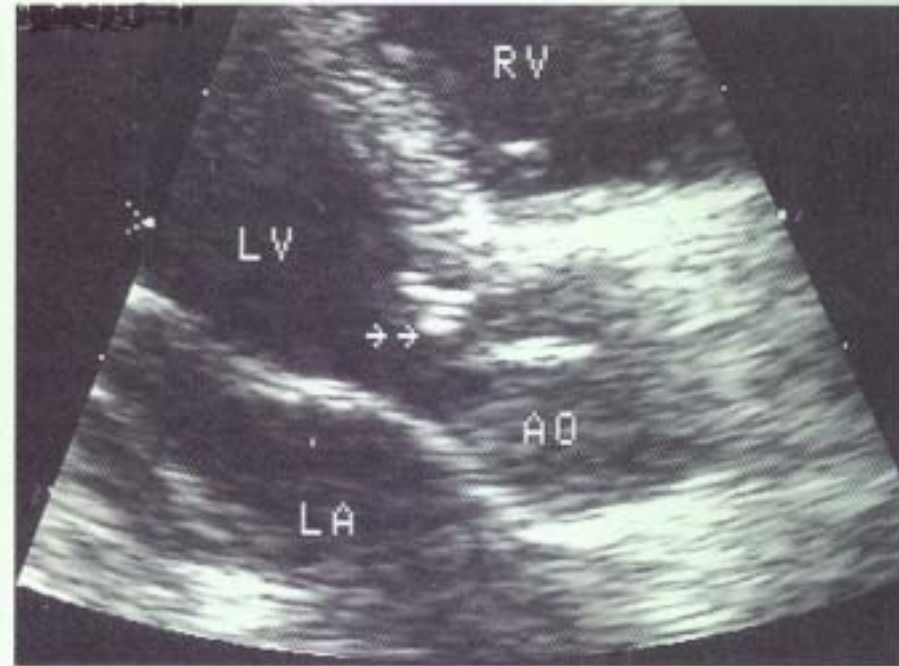

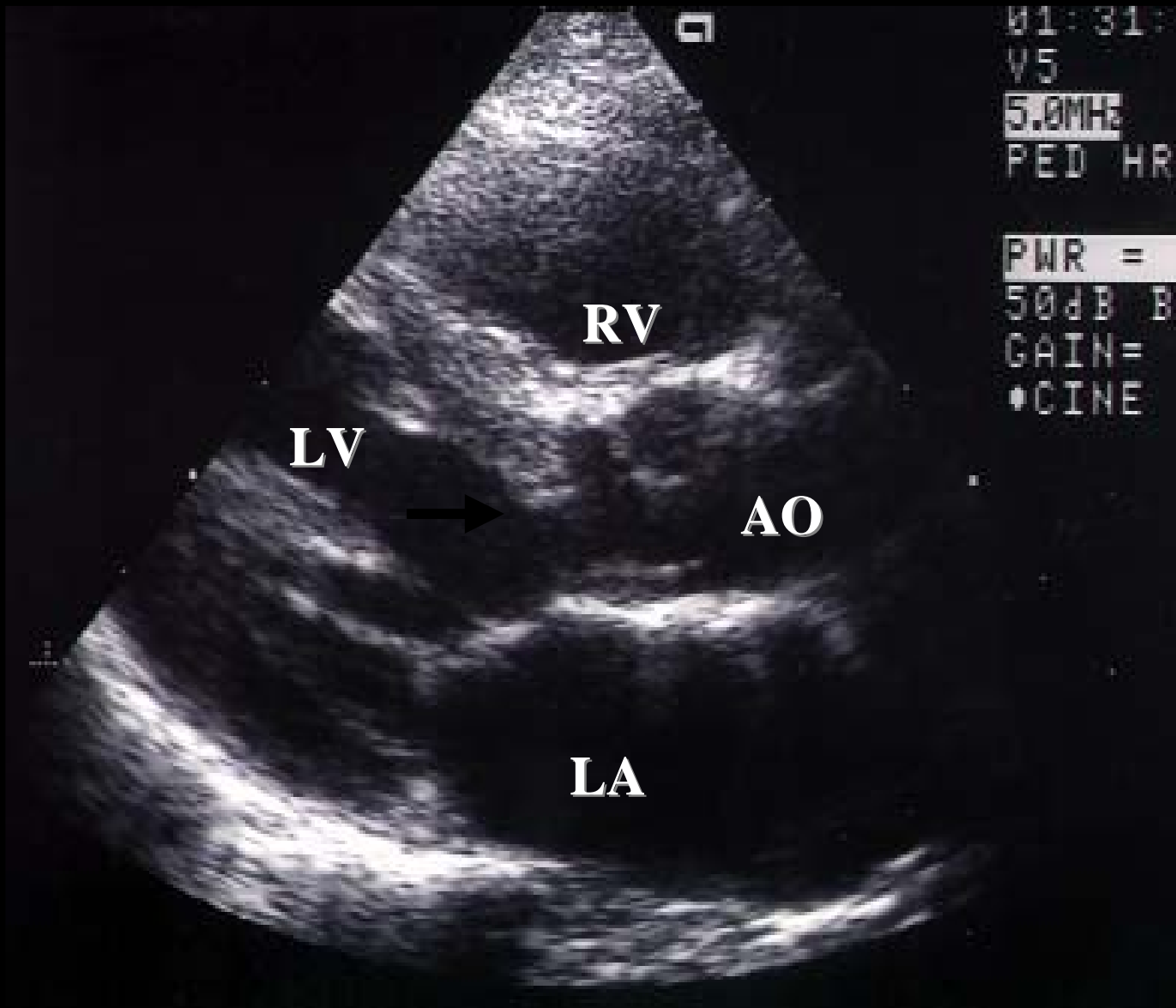
# Subaortic Stenosis

Subaortic membrane



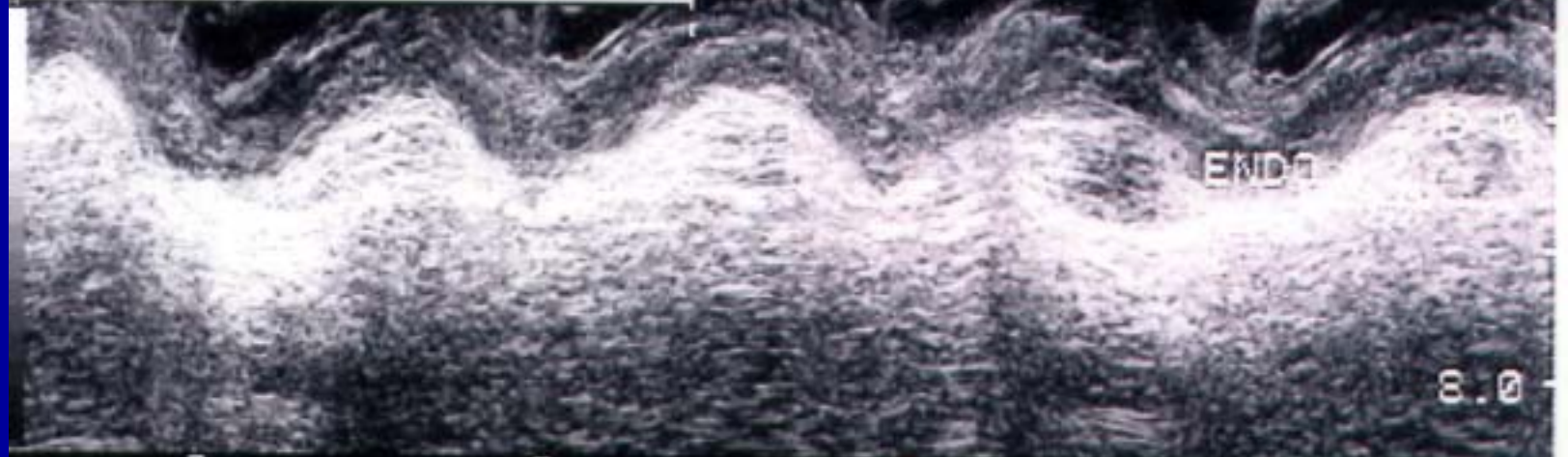
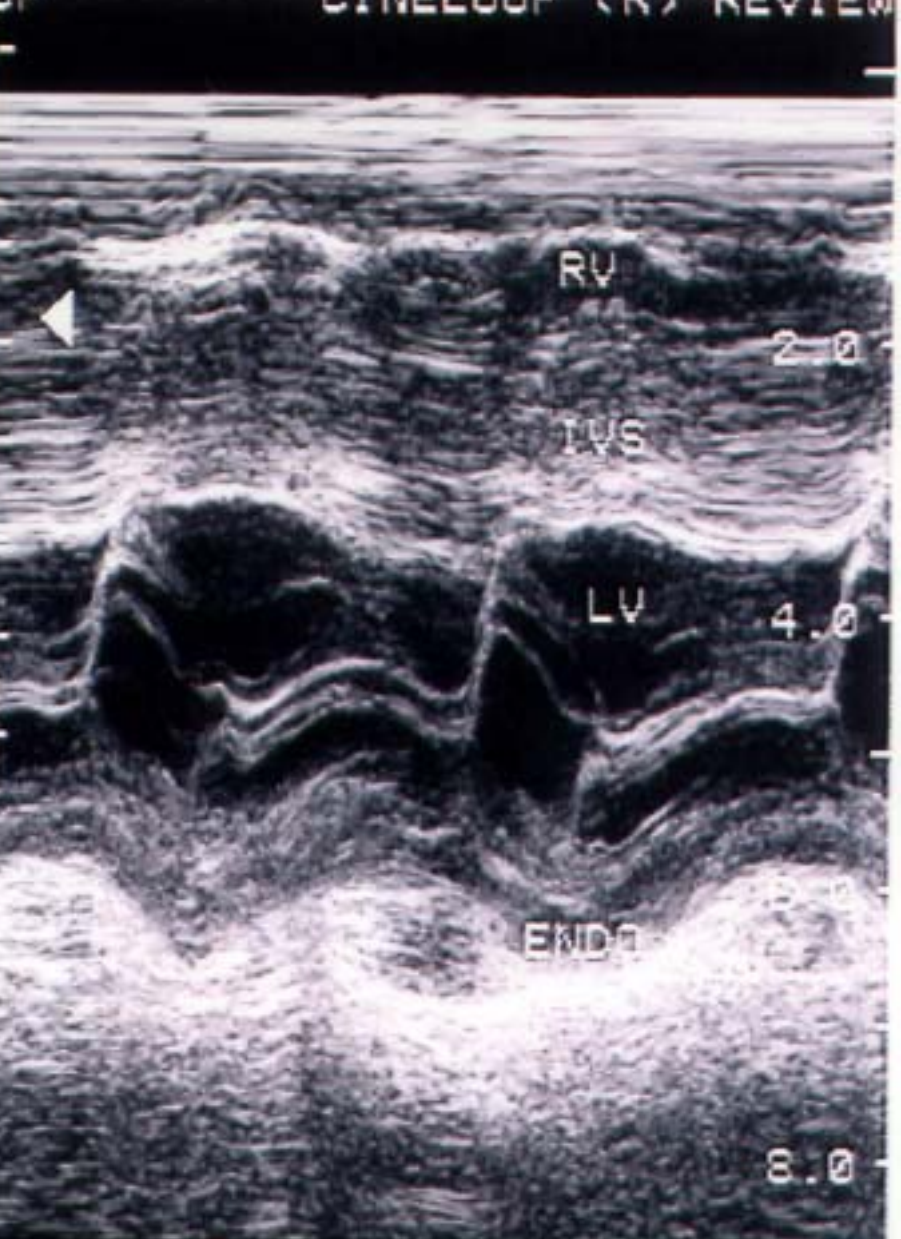
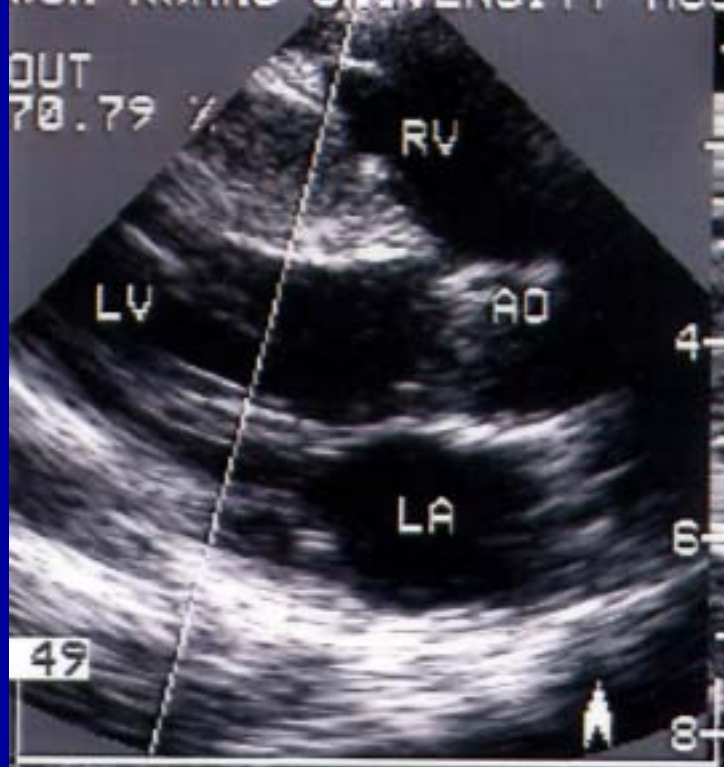Subaortic fibrous ridge

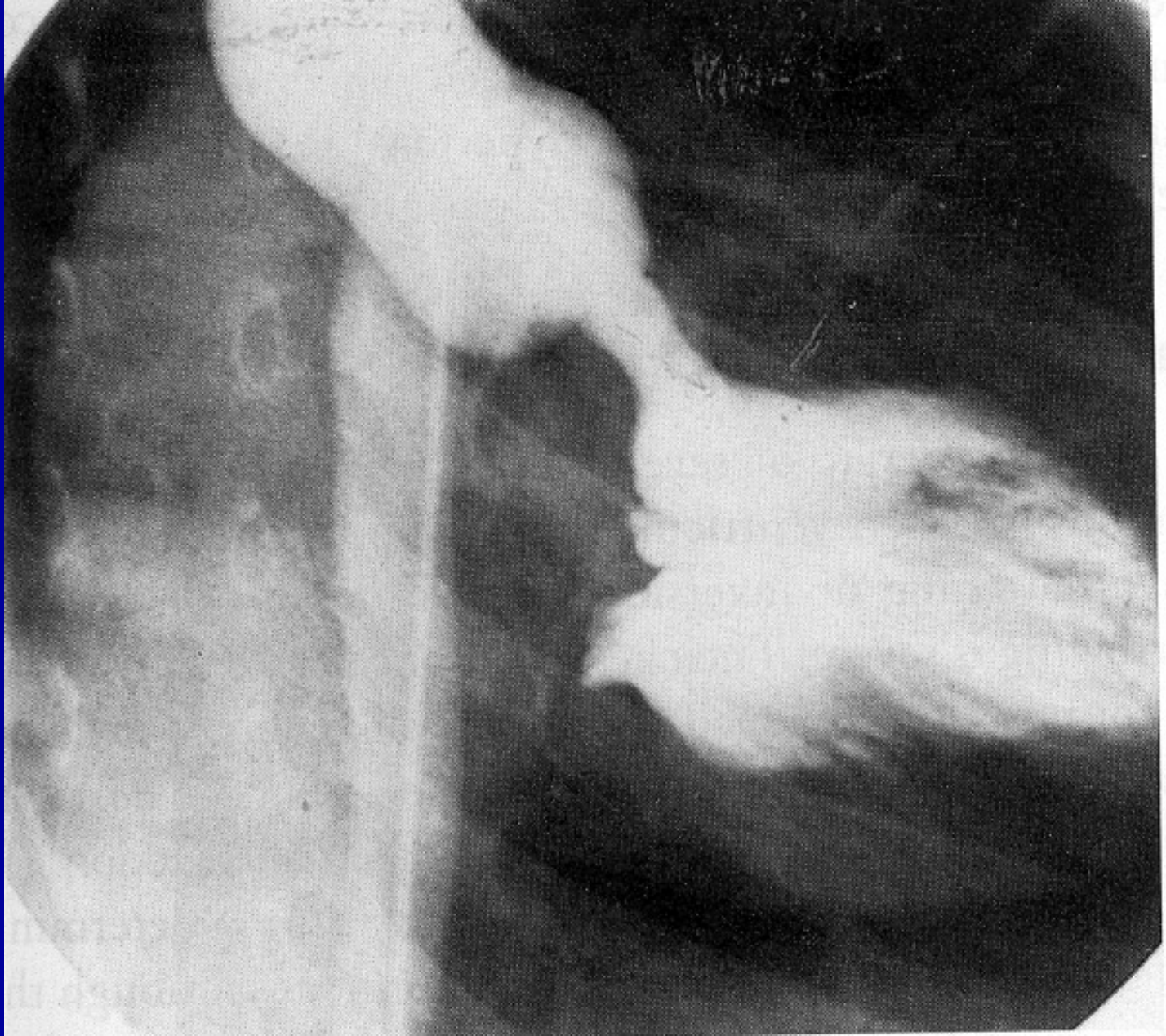




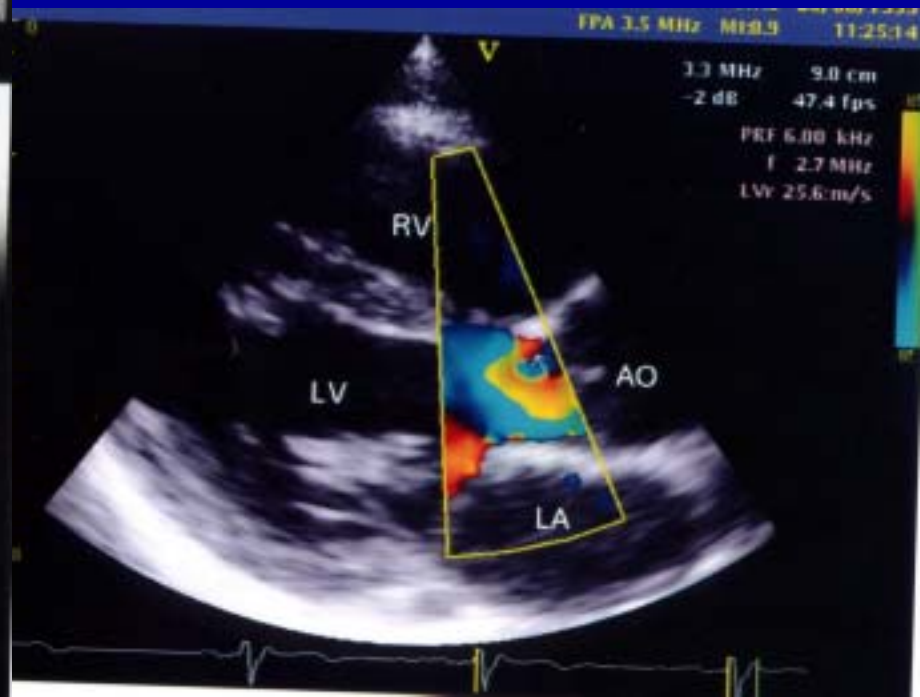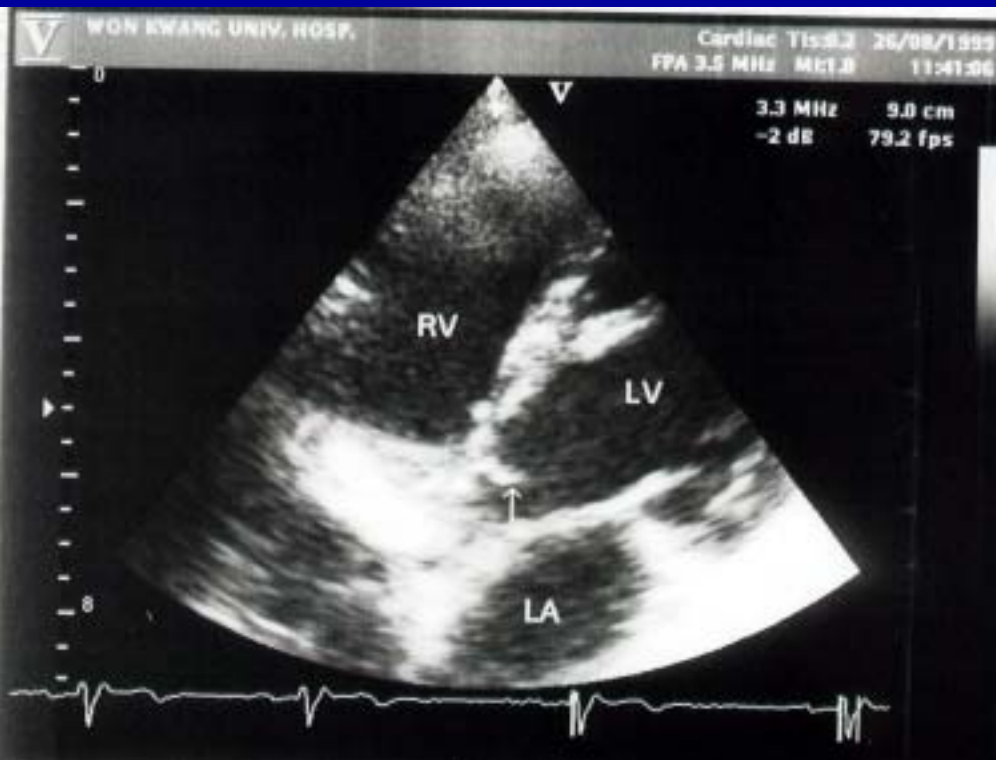
**Subaortic Stenosis ( $\Delta P = 25$  mmHg, 6 )**

OUT  
70.79 %



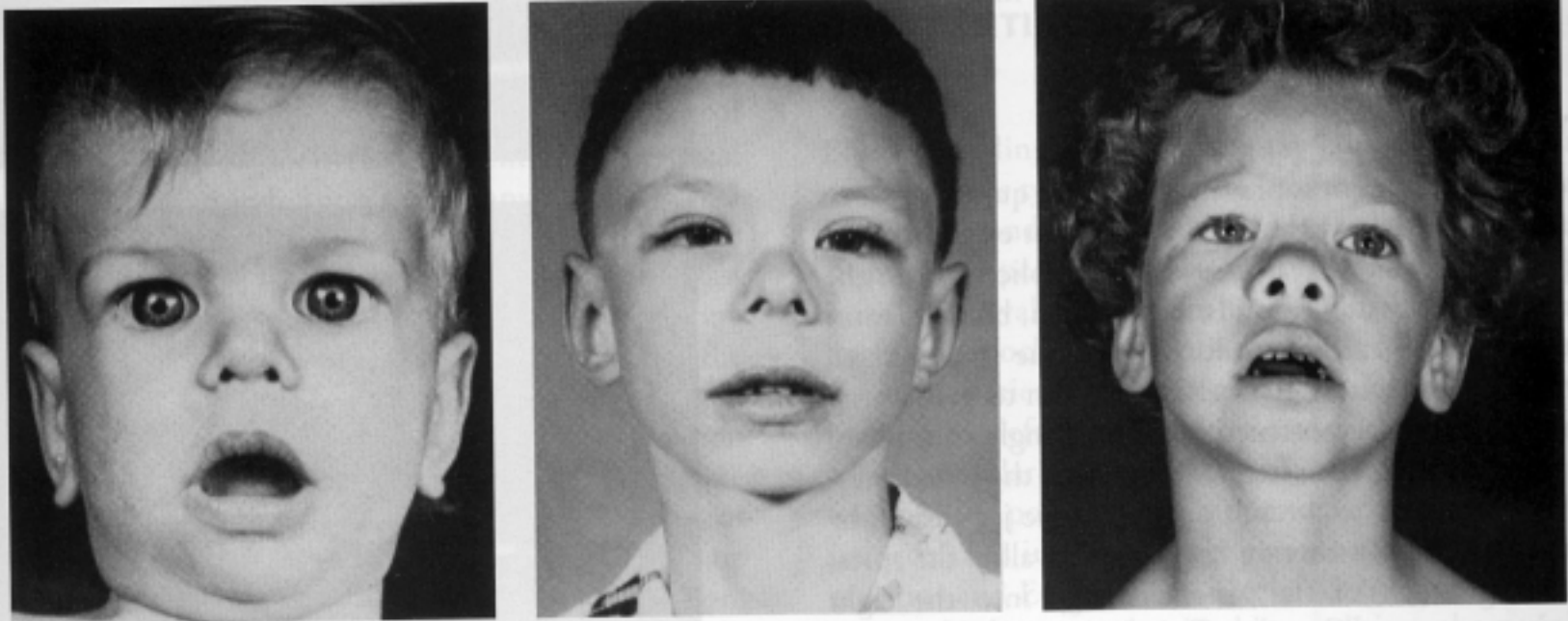


**Long segment tunnel subaortic obstruction in AVSD**



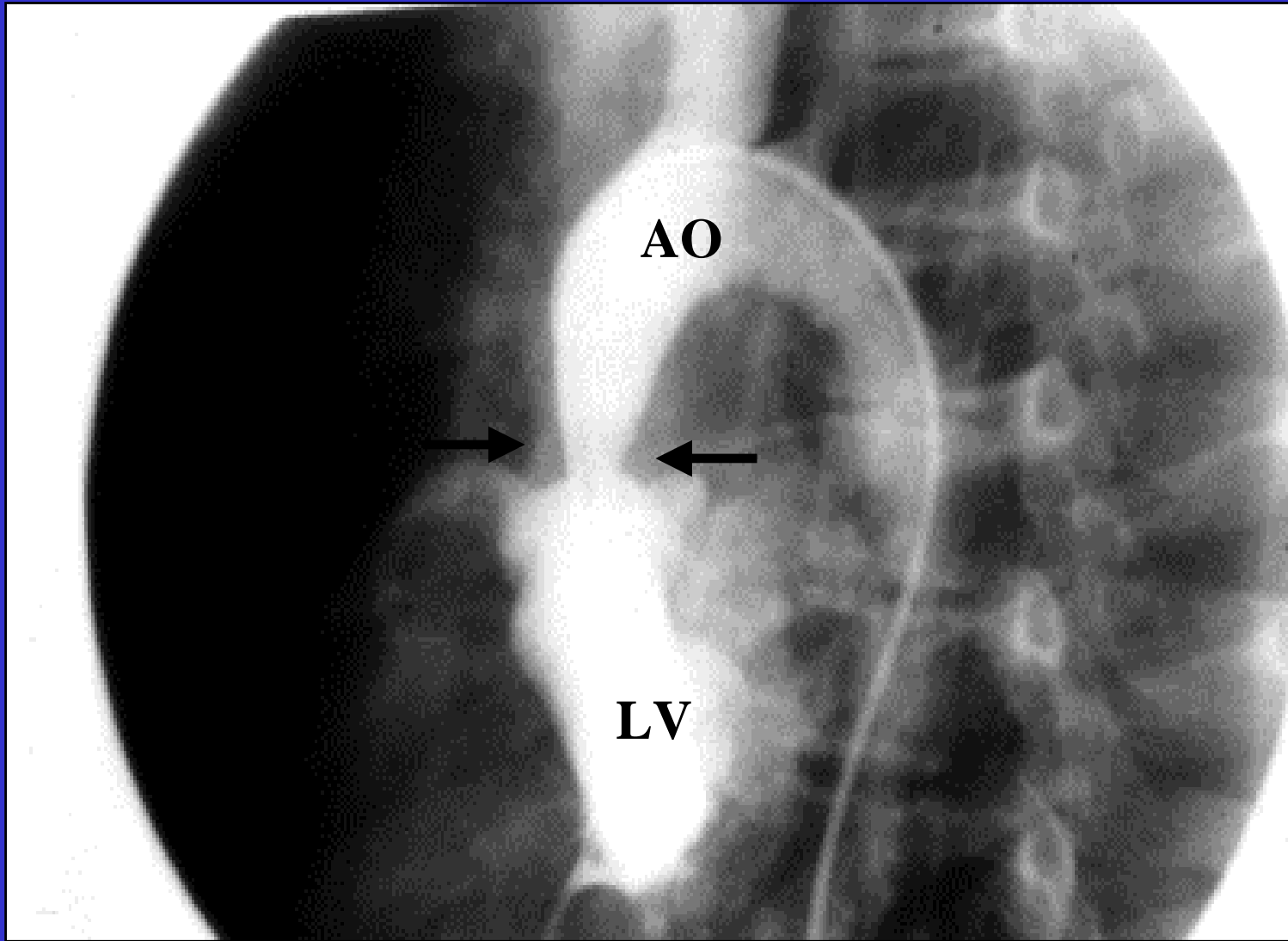
**2 yr male, s/p Partial AVSD**

# Supravalvular AS in Williams syndrome



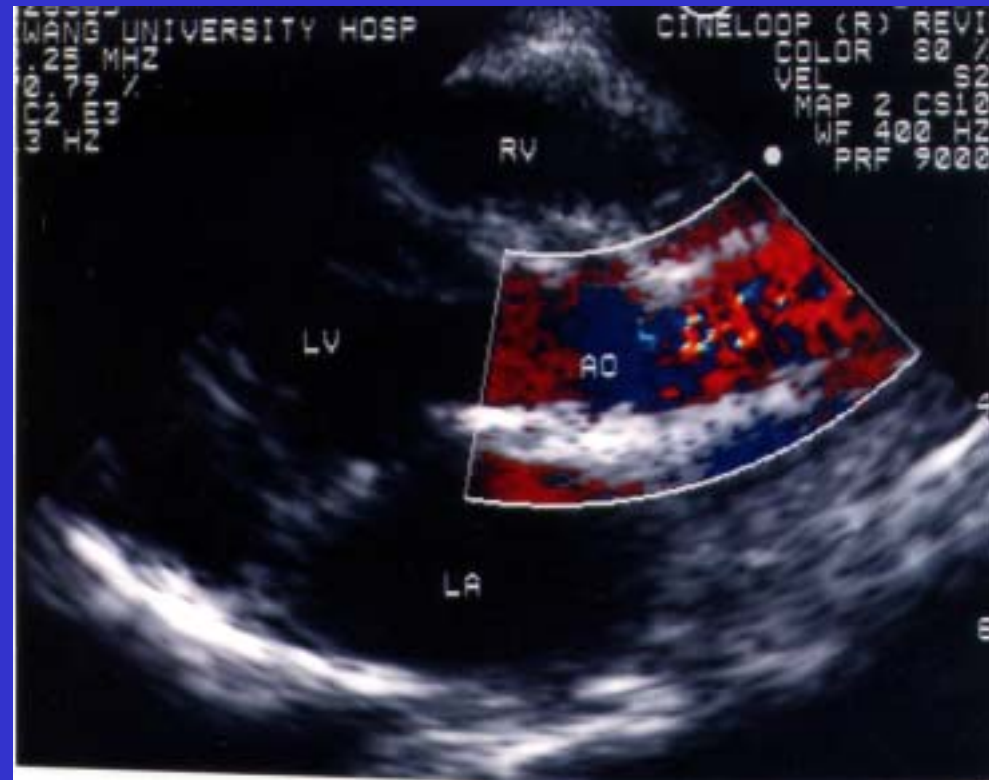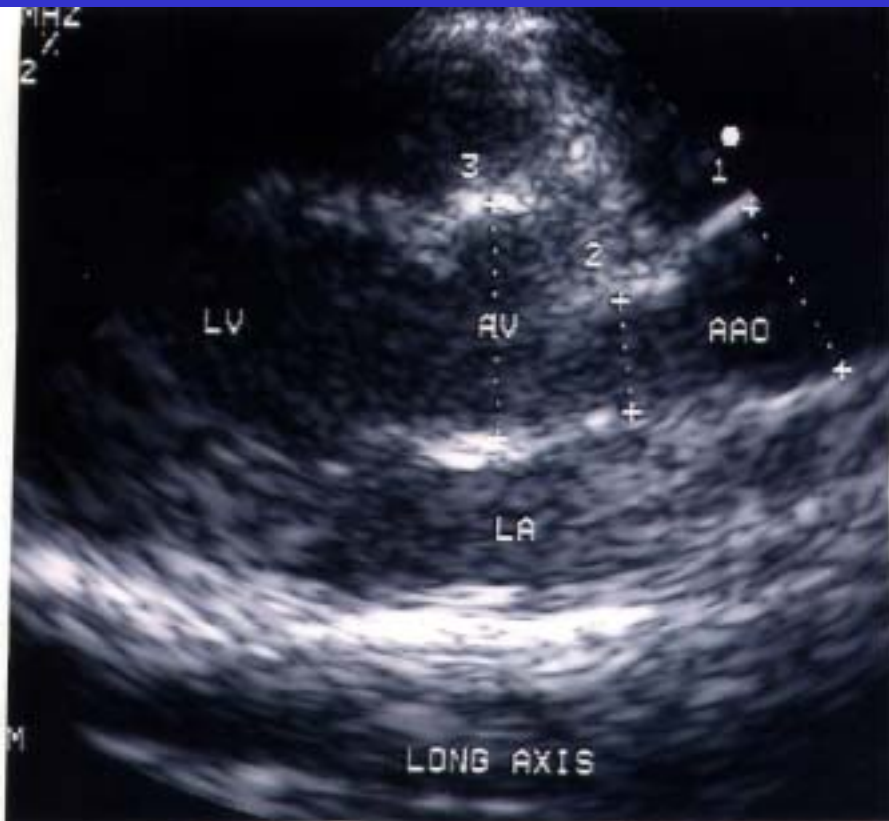**FIGURE 48.18.** Characteristic facial appearance in patients with supravalvular aortic stenosis and mental retardation. Note the high, prominent forehead, epicanthal folds, underdeveloped bridge of the nose and mandible, and overhanging upper lip. Strabismus is noted in the **middle** panel. (Left panel from Garcia RE, Friedman WF, Kaback MM, Rose RD. Idiopathic hypercalcemia and supravalvular aortic stenosis: documentation of a new syndrome. *N Engl J Med* 1964;27:117, with permission.)





**Supravalvular AS in Williams syndrome**

# Supravalvular AS in Williams syndrome

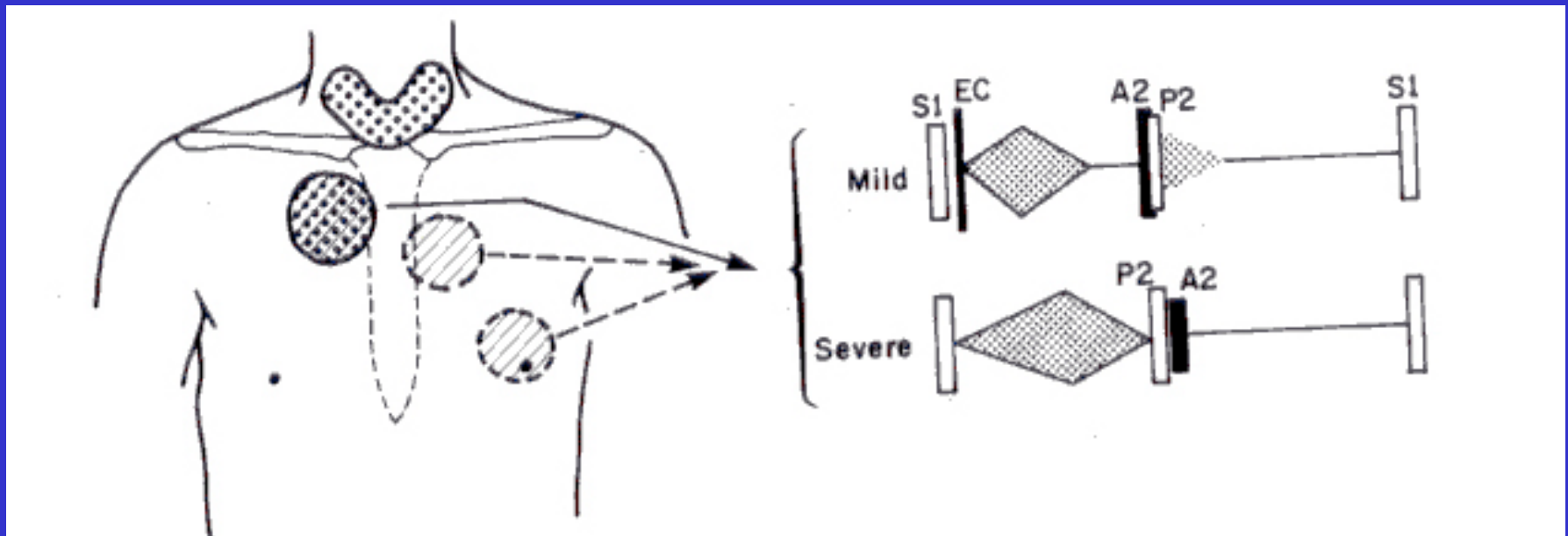


# Clinical Features – Aortic Stenosis

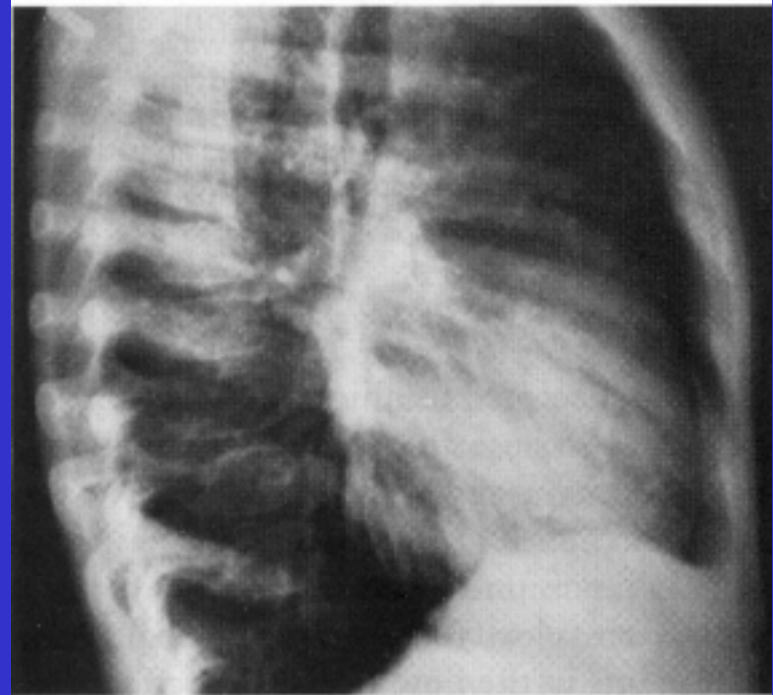
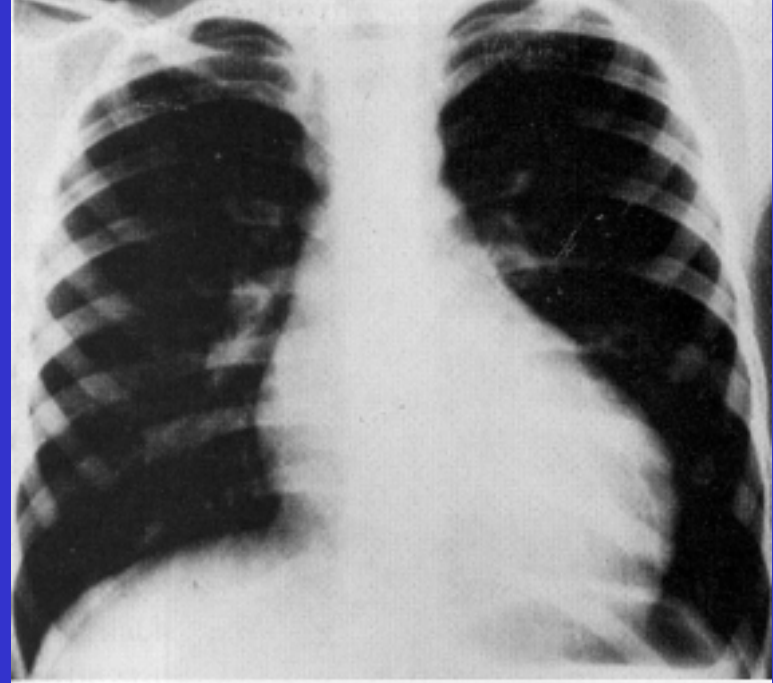
**Mild:** <40 - 50 mmHg(mean 20)

**Moderate:** 50-75 mmHg

**Severe:** >75 mmHg(mean 50)



# Clinical Features – Aortic Stenosis



# Congenital Aortic Stenosis - management

## Assessment of Severity in LVF

- underestimated

regular cardiac echo.

graded exercise testing

## Severe stenosis in neonates:

Cardiac cath.

Therapeutic balloon intervention

> Open heart surgery

- **mortality**

# **Left heart valves anomalies: Summary**

- **Early Diagnosis**

**Fetal Echo.**

- **Neonates or Infants**

- **Proper management**

**Intervention – operation**

- **Assessment of severity**

- **< 4-5 yrs**