



# Comparative Images of TCFA in AMI ; VH-IVUS versus IB-IVUS

Sang-Wook Kim, MD

Associate professor

Director of Cardiac Ultrasound/Core Lab

Chung-Ang University Heart Center

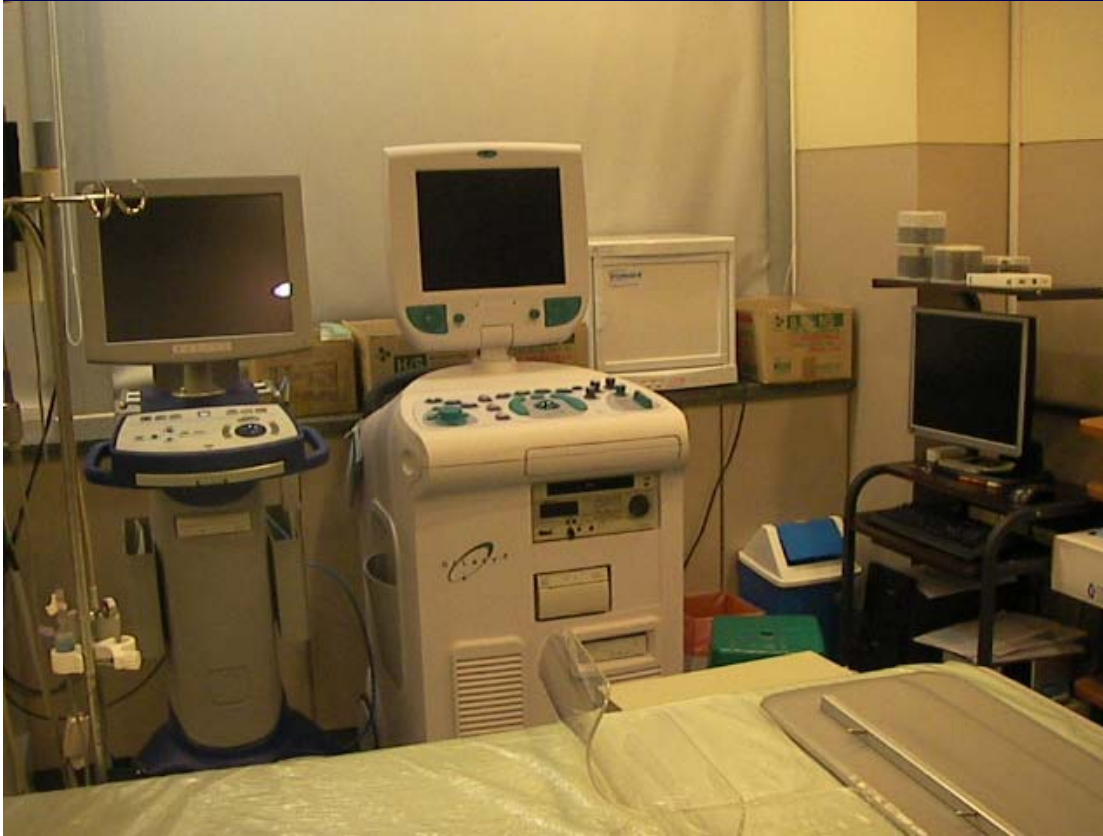


Chung-Ang Univ Medical Center  
Heart Center

Cardiovascular Ultrasound / Core Lab



# Volcano S5 vs Galaxy 2 with IB-IVUS



# VH-IVUS

*eight spectral parameters*

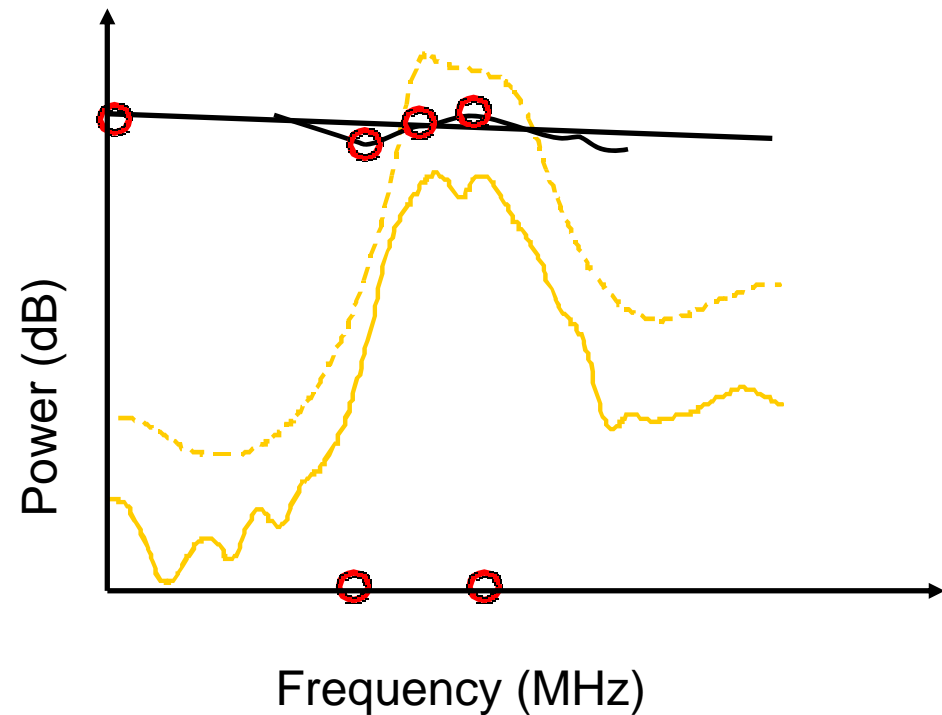
## Spectral Parameters

- Y-intercept
- Minimum Power
- Mid-Band Power
- Maximum Power
- Frequency at Minimum Power
- Frequency at Maximum Power

OTHERS -

Slope

Integrated Backscatter



# Principle of Integrated Backscatter

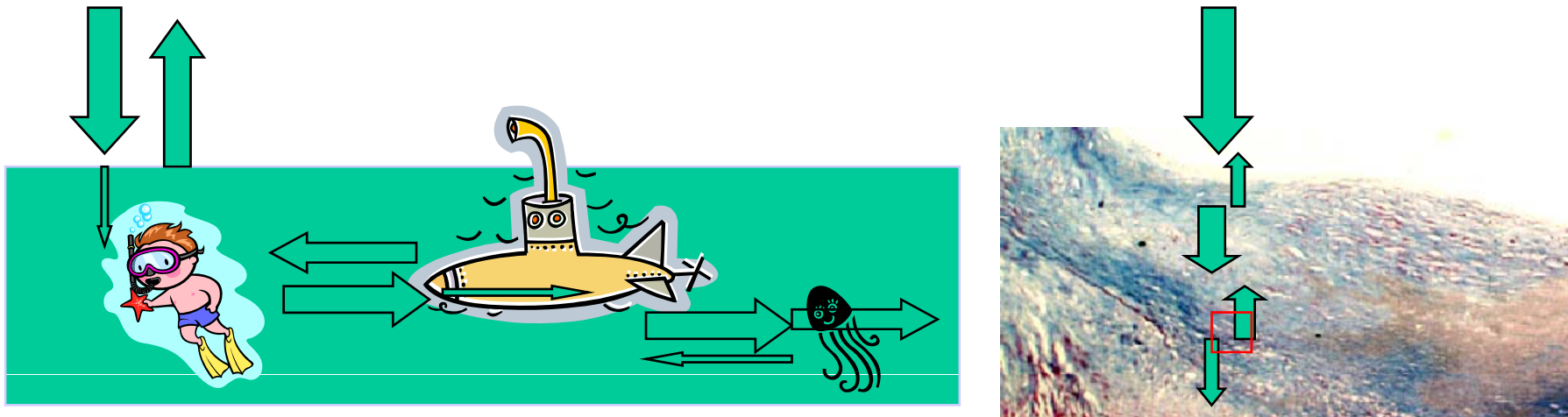
## Acoustic Characteristic Impedance $Z = \rho \cdot C$

( $\rho$  = Density,  $C$  = Speed of sound)

Air	413 Ns/m <sup>3</sup>
Water	1,480,000 Ns/m <sup>3</sup>
Lipid	1,380,000 Ns/m <sup>3</sup>
Fibrosis	1,680,000 Ns/m <sup>3</sup>
Iron	45,600,000 Ns/m <sup>3</sup>

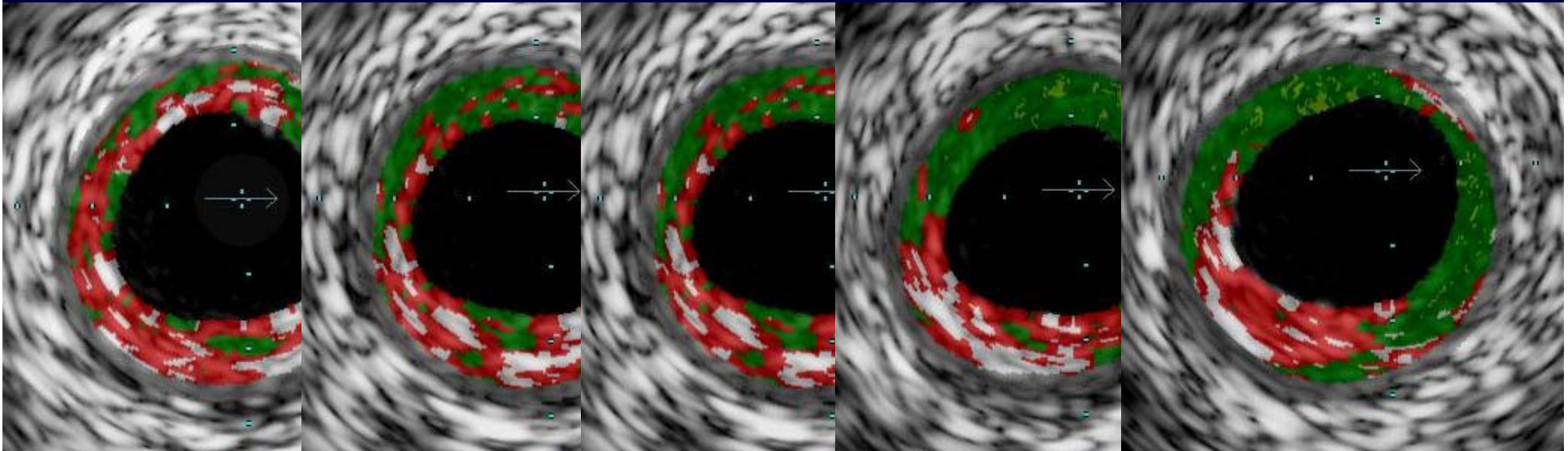
Jelly fish ?

$$\text{Integrated backscatter intensity (dB)} = k \times 10 \log_{10} \frac{(Z_A - Z_B)^2}{(Z_A + Z_B)^2}$$



Slide Courtesy of Dr. Masanori Kawasaki

# Thin-capped Fibroatheroma (VH-IVUS)



Plaque burden  $> 40\%$

Necrotic core  $> 10\%$  of plaque area

Necrotic core contact lumen at least 3 image slices

Thin cap not measurable

*Rodriguez-Granillo, et al JACC 2005;45:2038-42*



# Case

MRN: Y0672511

Name: Lee, JJ

Sex/ Age: male/50

Chief complaint: chest pain, for 2 hours

Risk Factors:

Hypertension(+) 5 years

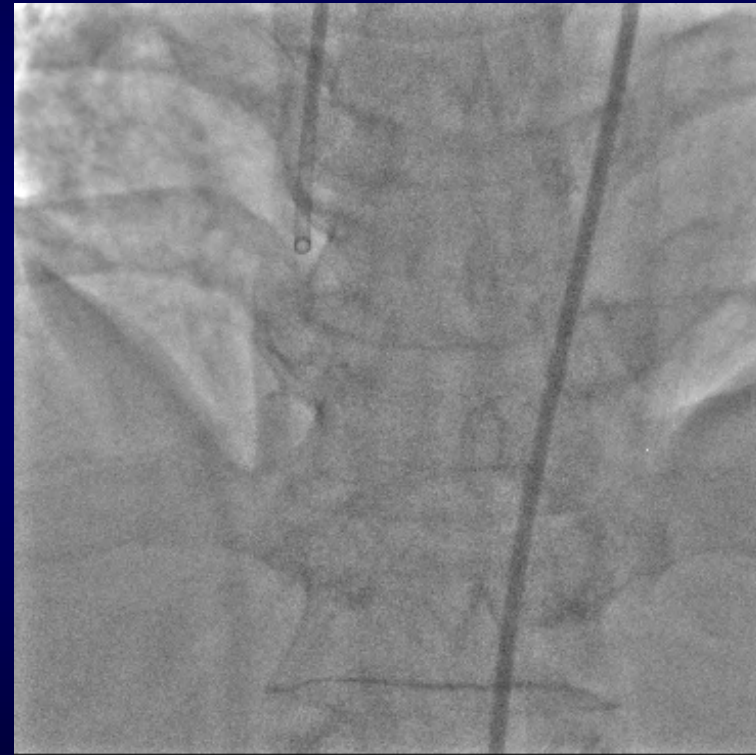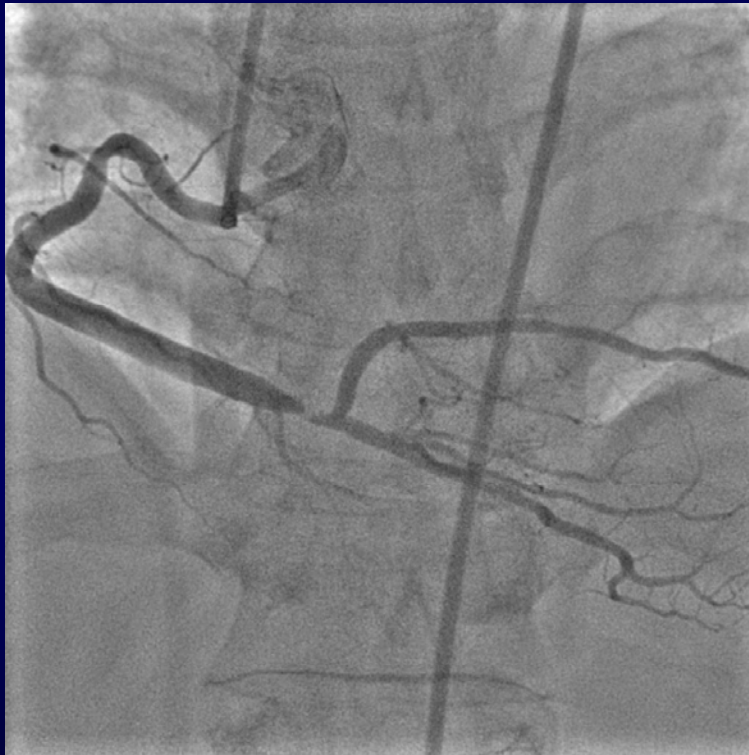DM(+) 3 years

ECG: ST elevation, II, III, aVF

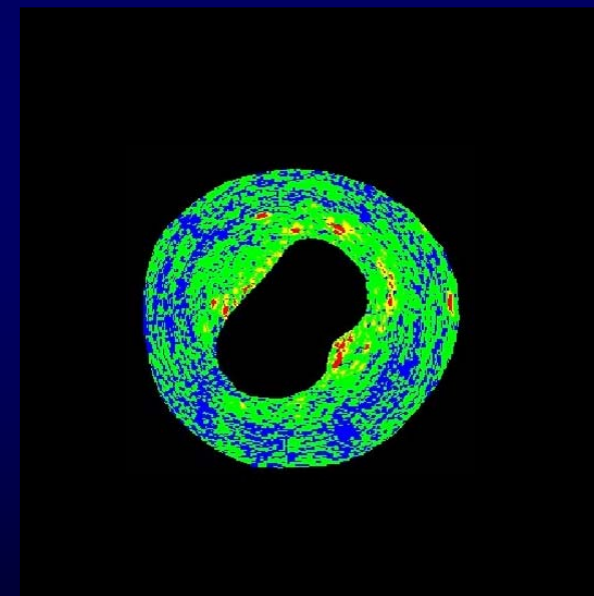
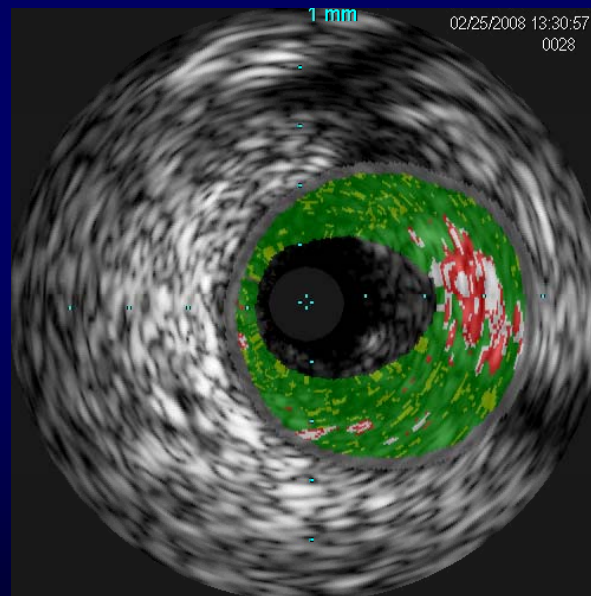
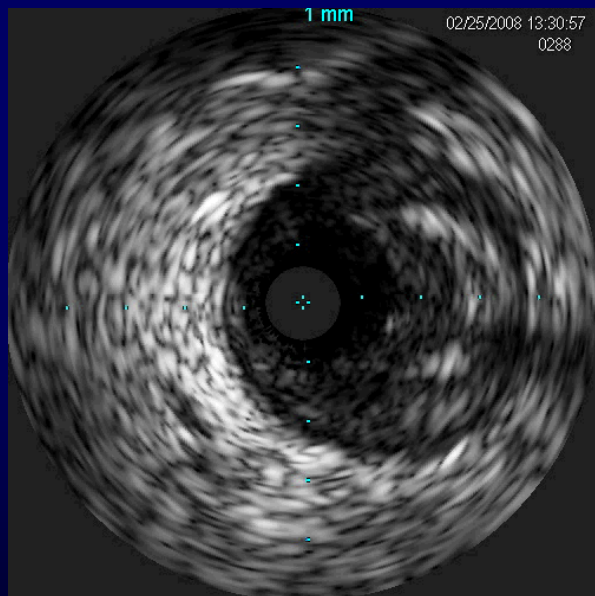
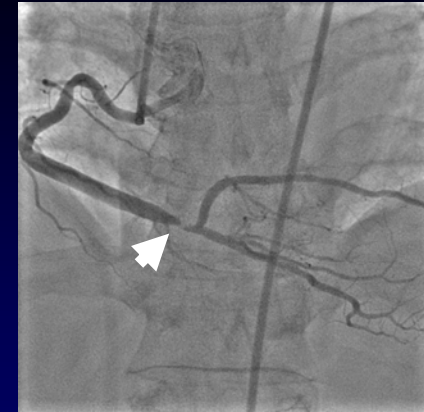Diagnosis: Acute STEMI



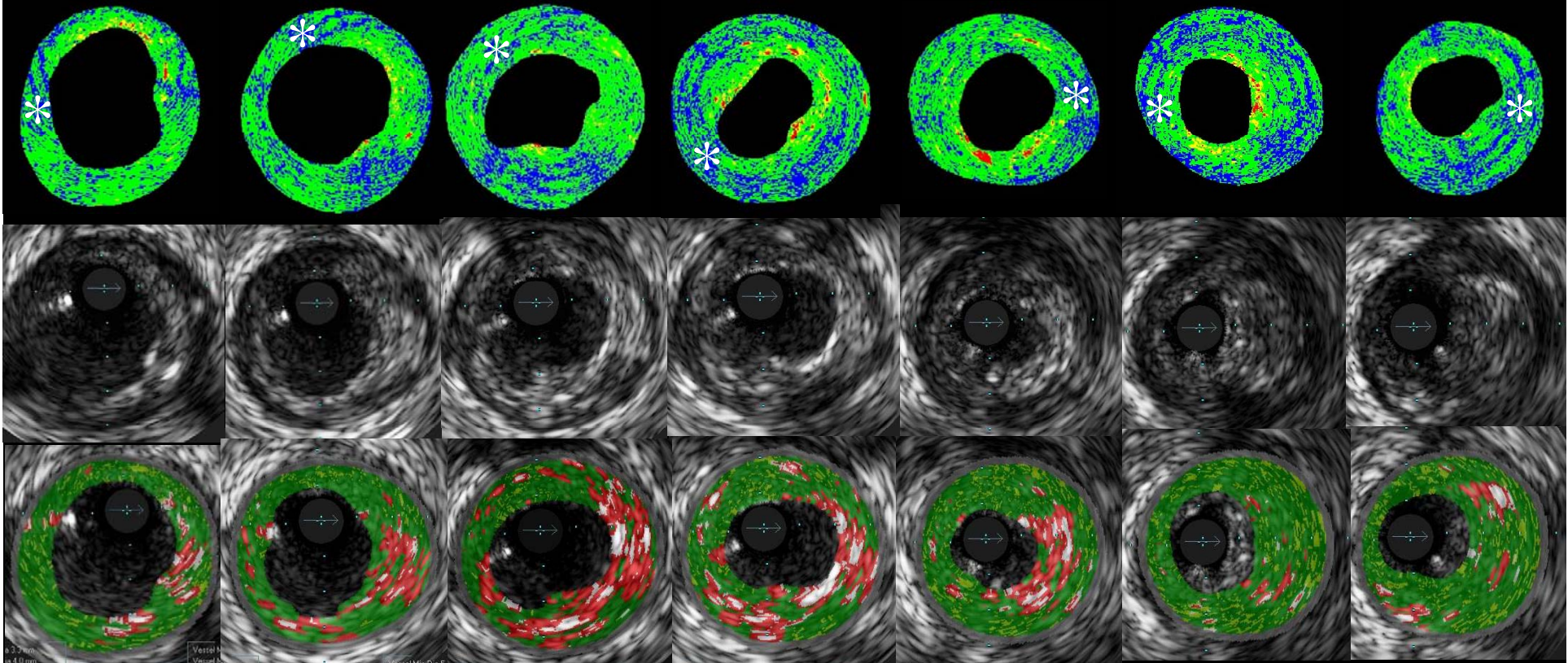
# Coronary angiography



# IVUS



# IB-IVUS vs Greyscale IVUS vs VH-IVUS



Proximal



distal



Chung-Ang Univ Medical Center

Cardiovascular Ultrasound / Core Lab





## Imaging Plaque; *A Gift from Physics*

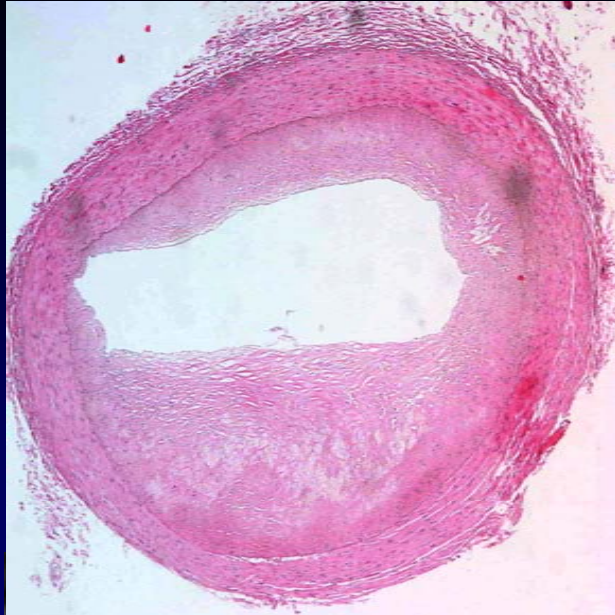	VH-IVUS	IB-IVUS
Plaque component	easy interpretation	not easy
Consensus standard	going on	not yet
Penetration	good	good
Functional information	no	no
Thin fibrous cap	not measurable	not measurable
Behind calcium	Maybe better	less
Guidewire artifact	no	yes
Artifacts	more necrotic core	more lipid pool
Thrombus	not validated	maybe better
Intima hyperplasia	not validated	maybe better

*“ If we knew what it was we were doing,  
it would not be called research, would it ? “  
(Albert Einstein)*



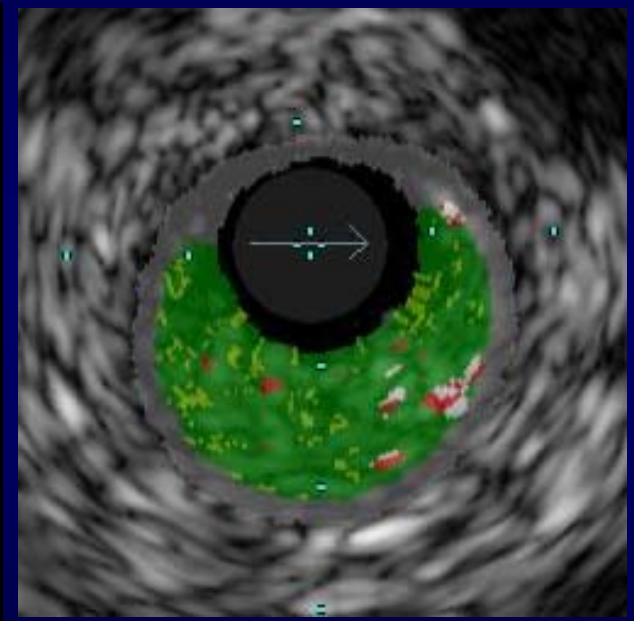
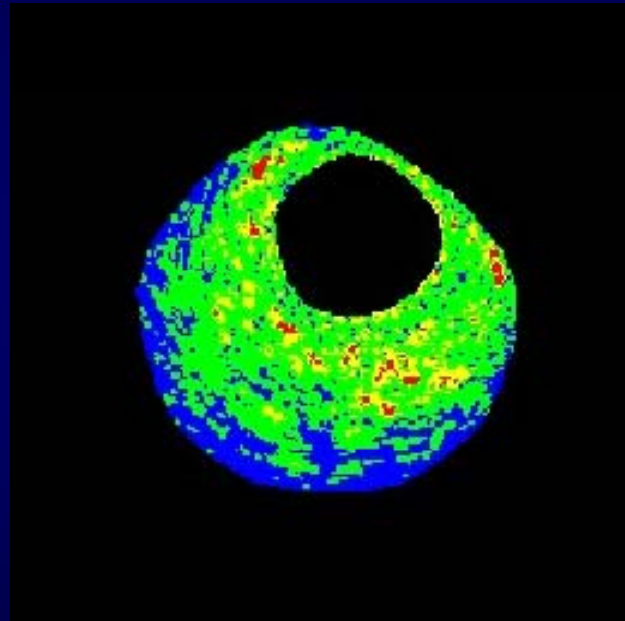
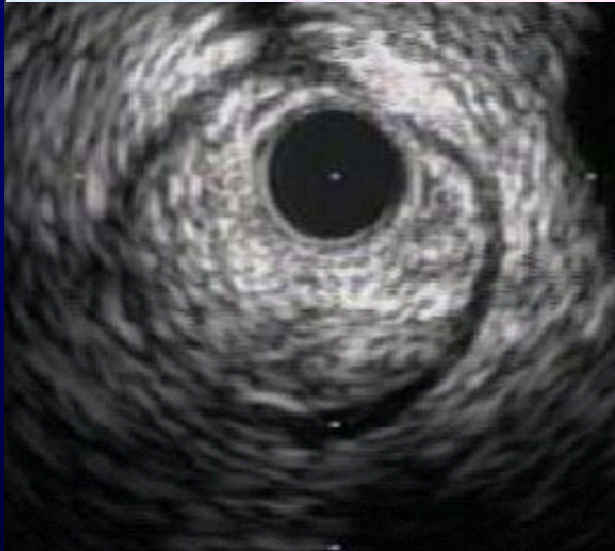
# Non-calcified Plaque

M/41, Sudden cardiac death, 5/15/07



IB-IVUS

VH-IVUS



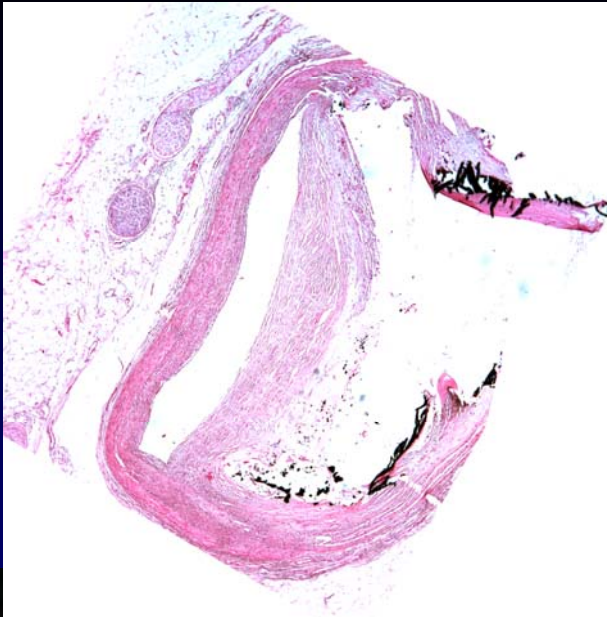
Vessel area 6.86 mm<sup>2</sup>  
Lumen area 1.32 mm<sup>2</sup>  
Plaque area 5.54 mm<sup>2</sup>

■ Dense fibrosis	12.54 %
■ Fibrosis	59.21 %
■ Lipid pool	26.08 %
■ Calcification	2.18 %

■ Fibrous	85.9 %
■ Fibro-fatty	8.3 %
■ Necrotic core	3.0 %
■ Dense calcium	2.8 %

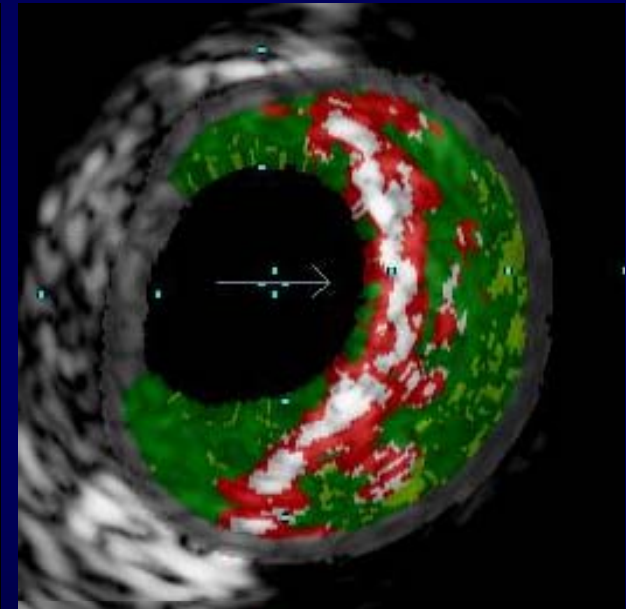
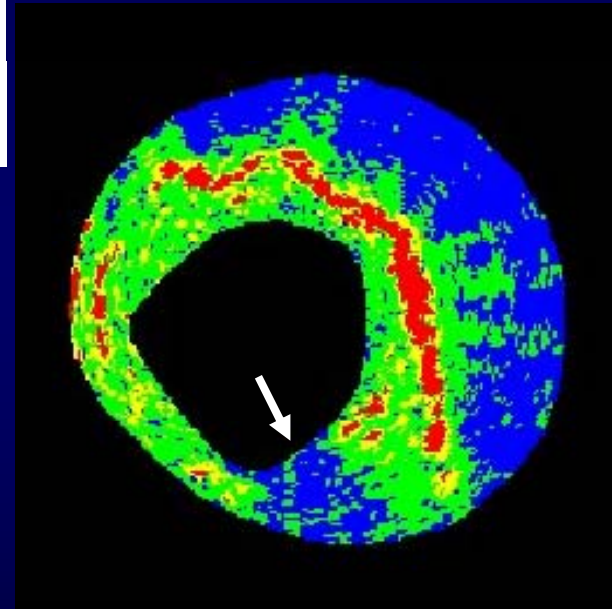
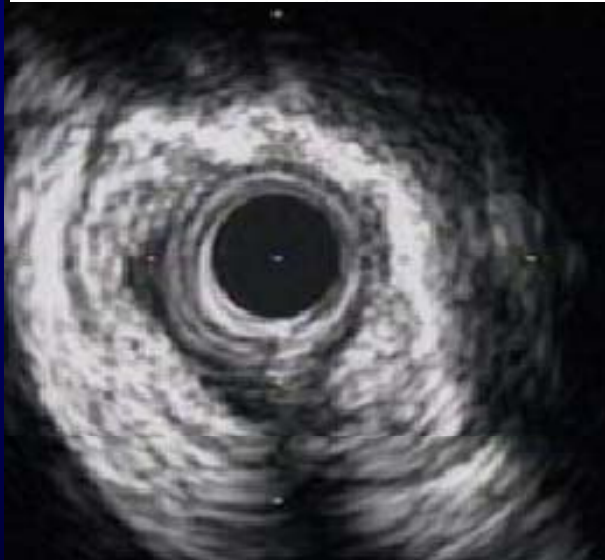# Calcified Plaque

M/52, Non-cardiac death, 5/29/07



IB-IVUS

VH-IVUS

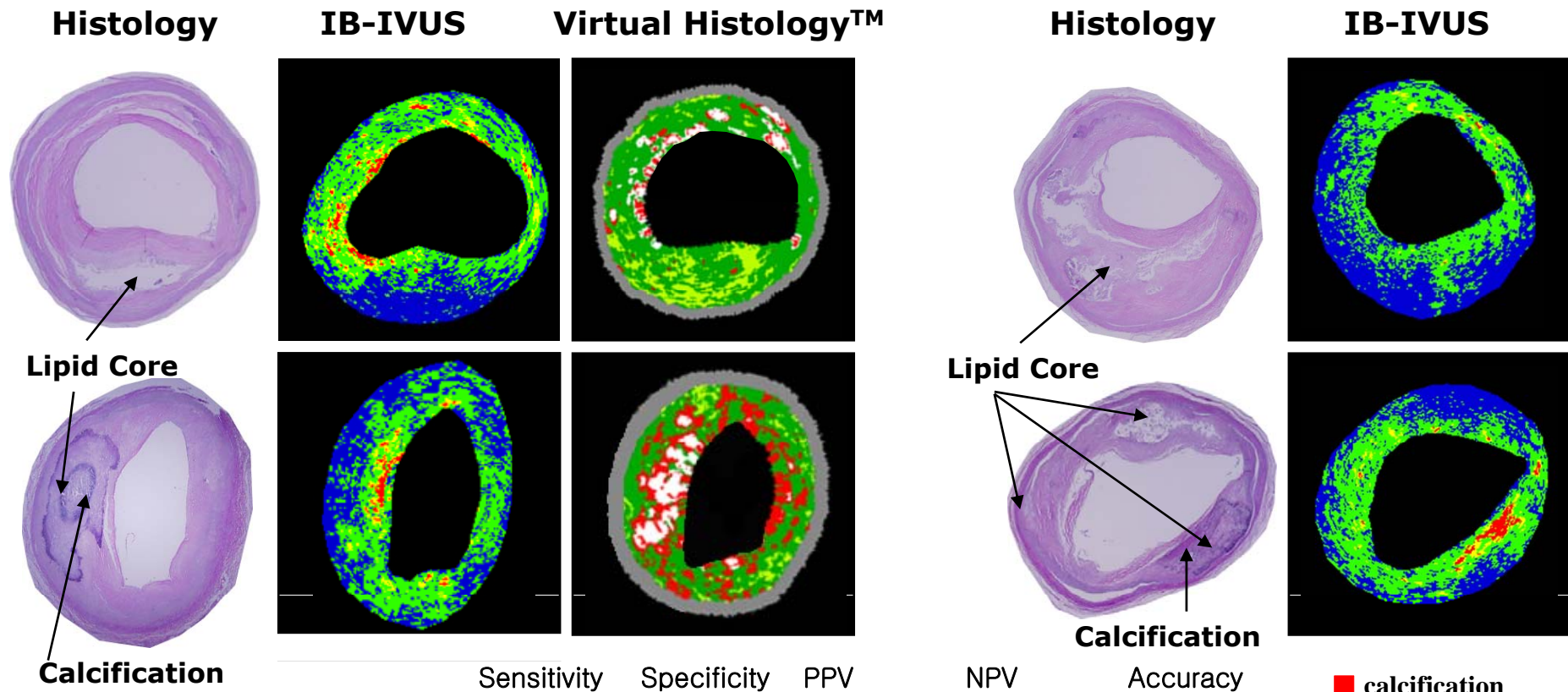


Vessel area 12.4 mm<sup>2</sup>  
Lumen area 2.92 mm<sup>2</sup>  
Plaque area 9.46 mm<sup>2</sup>

■ Dense fibrosis	11.56 %
■ Fibrosis	44.32 %
■ Lipid pool	36.46 %
■ Calcification	7.66 %

■ Fibrous	51.0 %
■ Fibro-fatty	7.7 %
■ Necrotic core	24.4 %
■ Dense calcium	16.8 %

# High Accuracy



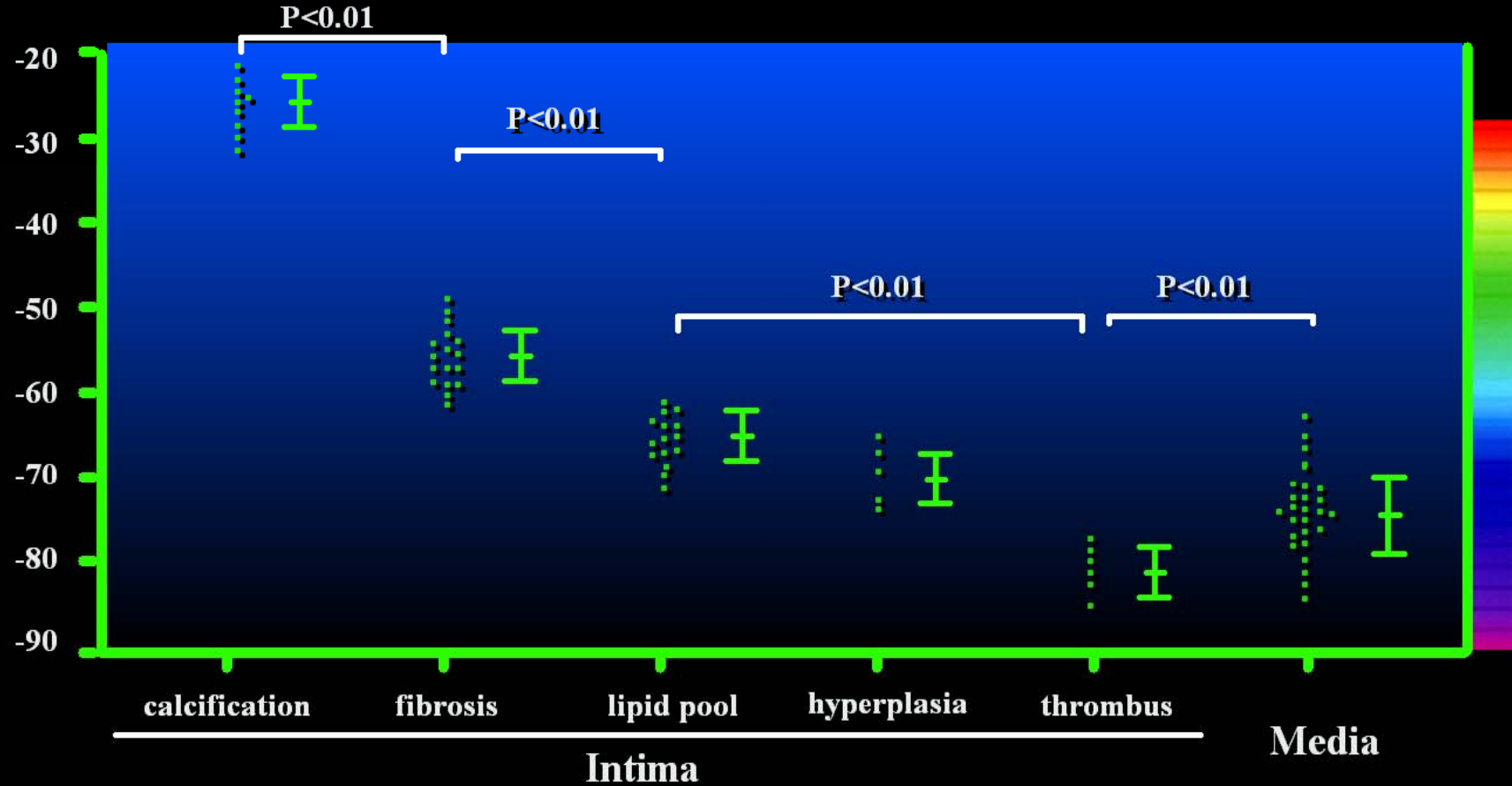
	Sensitivity	Specificity	PPV	NPV	Accuracy
Calcification (n=144)	95 (92–98)	99 (98–100)	93 (89–97)	99 (98–100)	97 (95–99)
Fibrosis (n=335)	94 (92–96)	93 (91–95)	93 (91–95)	94 (92–96)	94 (92–96)
Lipid pool (n=205)	90 (87–93)	92 (89–95)	85 (81–88)	90 (87–93)	91 (88–92)

**PPV: Positive predictive value. NPV: Negative predictive value, Numbers in parenthesis are 95% confidence intervals.**

Okubo M, *et al.* *Ultrasound Med Biol* 2007 (in press)

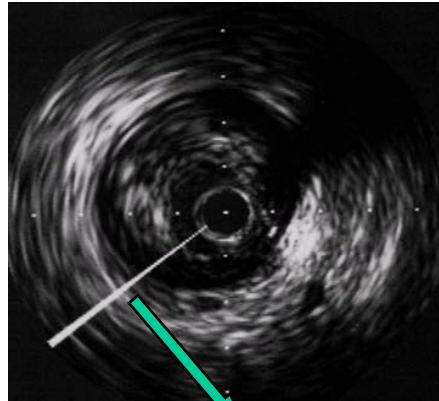
# Integrated Backscatter Intravascular Ultrasound

IB values (dB)

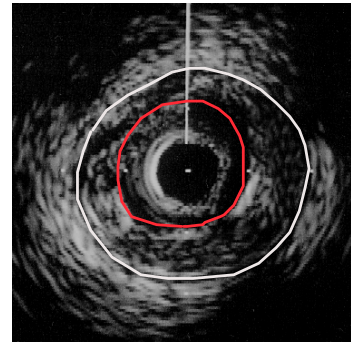


# Integrated Backscatter Intravascular Ultrasound

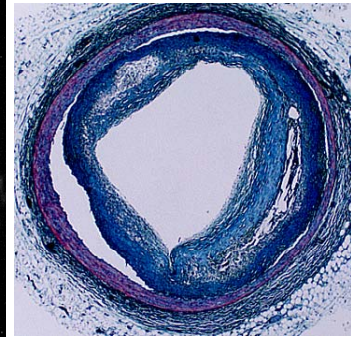
**Conventional IVUS**



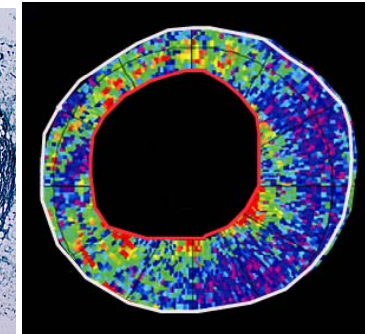
**Conventional IVUS**



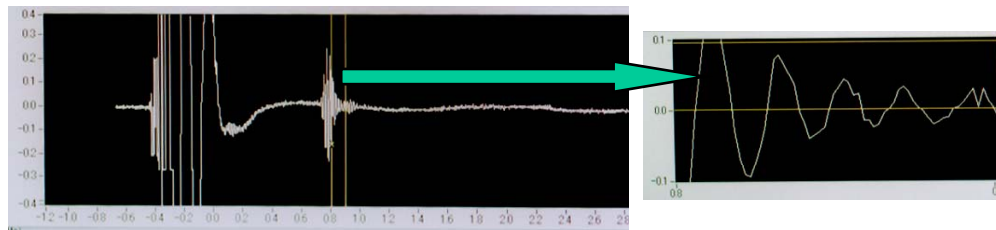
**Histology**



**IB-IVUS**



**Radio Frequency Signal**



**Time domain analysis**

**Frequency domain analysis**

**Fast Fourier Transform**

