

2008년 순환기관련 춘계통합학회 2008.4.18. Busan Bexco.

Tissue Characterization in Echo

정 욱 진

嘉泉醫大 吉病院 心臟內科

GACHON
UNIVERSITY of
MEDICINE and SCIENCE

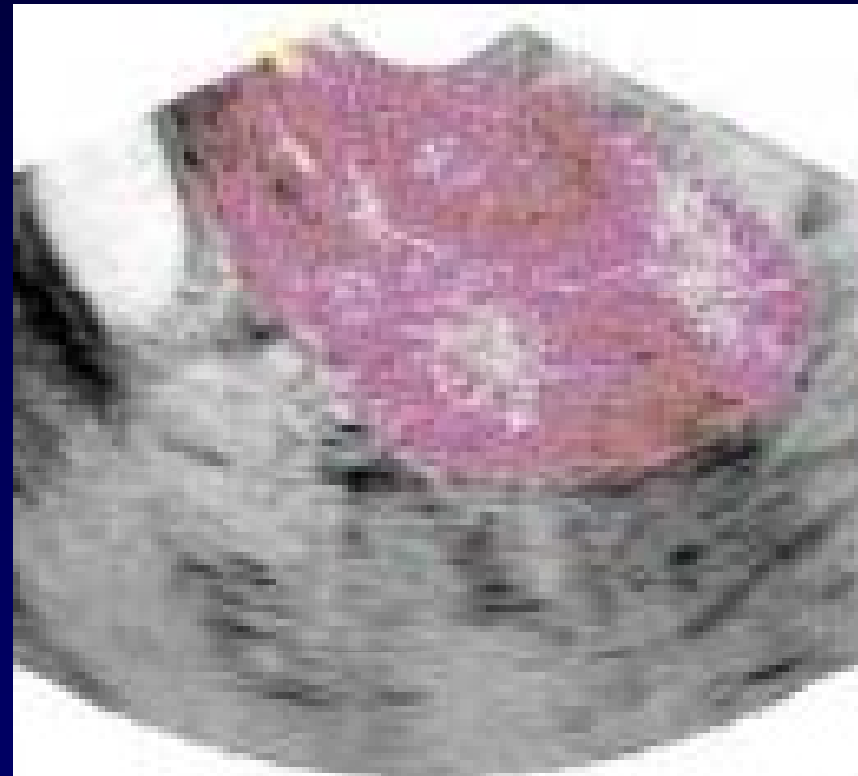
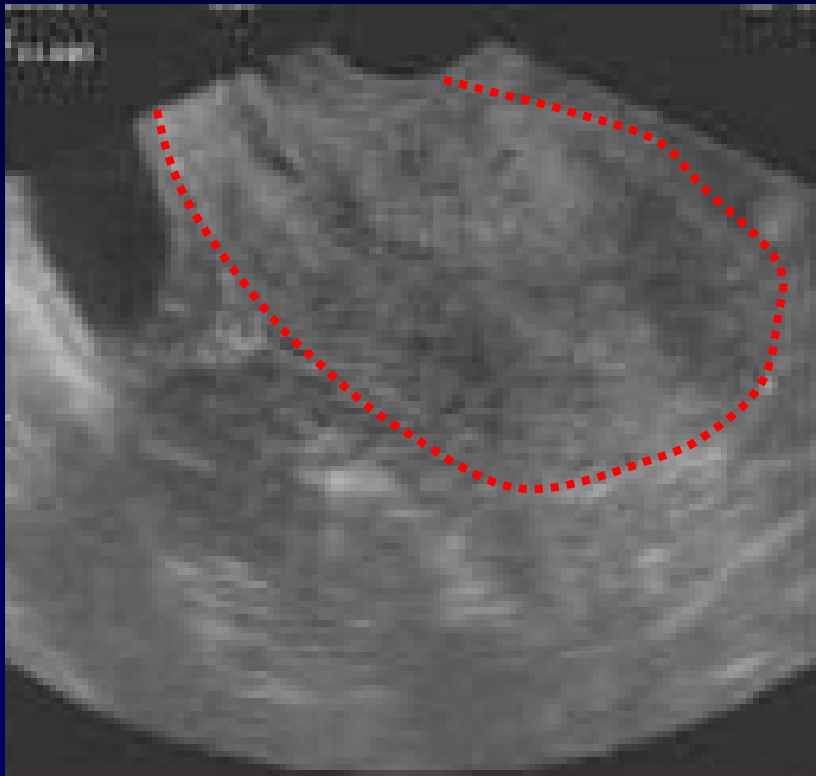
TOC



Tissue Characterization



Tissue Characterization by Ultrasound



Tissue Characterization in Echo

- ✓ History: The characterization of myocardial tissue by ultrasound was **first attempted in 1957**, using excised human hearts to distinguish infarcted from normal myocardium. Basic concept was **quantitative estimates of frequency dependent myocardial attenuation** (*Wild JJ, et al. Am Heart J 1957;54:903-6*)
- ✓ Object: **Cardiomyopathic abnormalities** ; coronary ischemia, myocardial viability, experimental myocardial contusion, amyloid infiltration, HCM, transplant rejection, myocarditis...

Tissue Characterization in Echo

- ✓ Object: **Cardiomyopathic abnormalities** ;
coronary ischemia, myocardial viability,
experimental myocardial contusion,
amyloid infiltration, HCM, transplant rejection,
myocarditis...



Tissue Characterization in Echo

- ✓ Qualitative – M-mode, 2D
- ✓ Integrated Backscatter (IBS)
- ✓ Tissue Doppler Imaging (TDI)
- ✓ Deformation Imaging (SRI)
- ✓ Myocardial Contrast Echo (MCE)

Tissue Characterization in Echo

- ✓ **Qualitative – M-mode, 2D**
- ✓ **Integrated Backscatter (IBS)**
- ✓ **Tissue Doppler Imaging (TDI)**
- ✓ **Deformation Imaging (SRI)**
- ✓ **Myocardial Contrast Echo (MCE)**

M-mode & 2D Echo in Tissue Characterization

- ✓ ***Simplest technique*** used to study the characteristics of myocardial tissue.
- ✓ An ***increased intensity*** of the echocardiographic signal has been reported some weeks **following anteroseptal myocardial infarction**.
- ✓ A strong correlation between ***intensity of the signal*** and **presence of scar tissue** on surgical or post-mortem evaluation by M-mode and 2D echo.

Rasmussen S, et al. Circulation 1978:230-7

Fraker TD, et al. Am J cardiol 1984:1699-702

M-mode & 2D Echo in Tissue Characterization

24 iCMP, DSE before and F/U Echo 6 months after CABG

- ✓ Only **baseline diastolic wall thickness (DWT) measurement** may improve the sensitivity of DSE for the detection of **myocardial viability**.
- ✓ **Akinetic segments with DWT > 0.8 cm have a good chance of recovery** despite the absence of contractile reserve during DSE. Further testing may be required before excluding myocardial viability in these cases.

Tissue Characterization in Echo

- ✓ Qualitative – M-mode, 2D
- ✓ **Integrated Backscatter (IBS)**
- ✓ Tissue Doppler Imaging (TDI)
- ✓ Deformation Imaging (SRI)
- ✓ Myocardial Contrast Echo (MCE)

Importance of Quantification



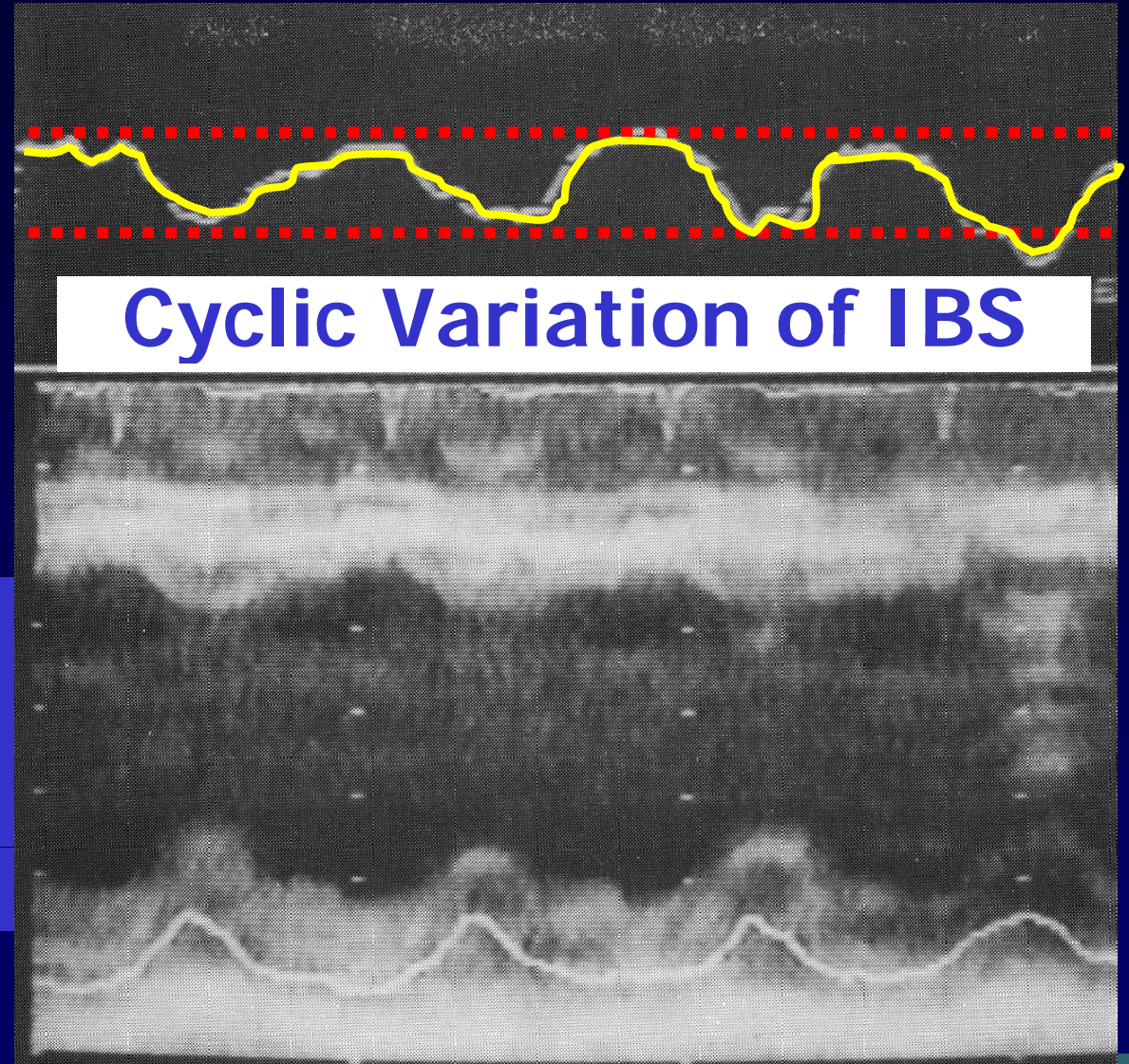
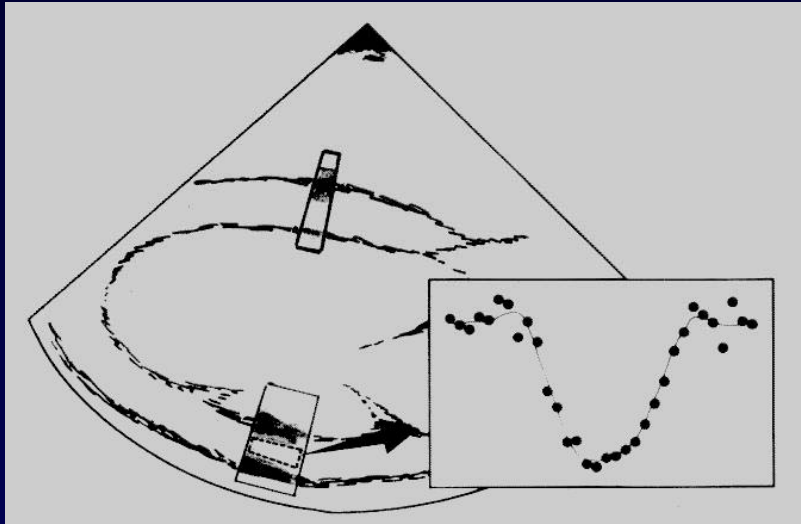
**“ If you can’t measure it,
you can’t manage it.”**

Peter F. Drucker (1909-2005)

Quantitative Tissue Characterization by Ultrasound

- ✓ By the possibility that *individual structural components of the myocardium can influence its acoustic properties* in different physiologic and pathologic conditions.
- ✓ By **radiofrequency (integrated backscatter)** and echocardiographic **gray level (videodensitometry)**
- ✓ In particular, **IBS** analyzes the **unprocessed radiofrequency signal returning from the myocardium**, whilst **VI** bases on the conversion of analogic conventional ultrasonic images into a **digitized form** which allowing quantitative analysis of the ultrasonic myocardial texture.

Integrated Back Scatter (IBS)



IBS

Calibrated IBS (cIBS) ; - blood IBS (circular-shaped ROI (41 41 pixels) in the left ventricular cavity at the mid-level)

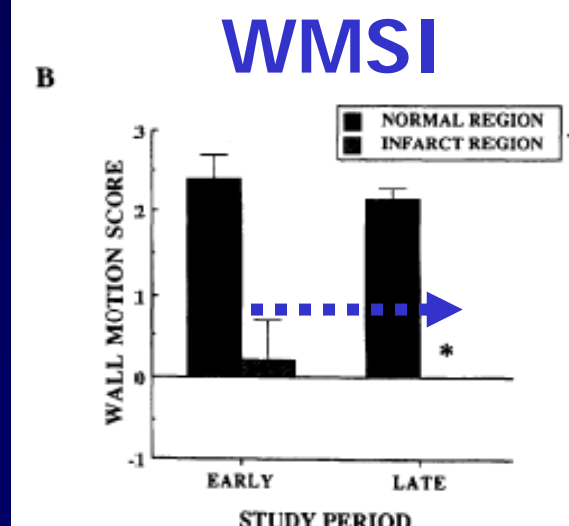
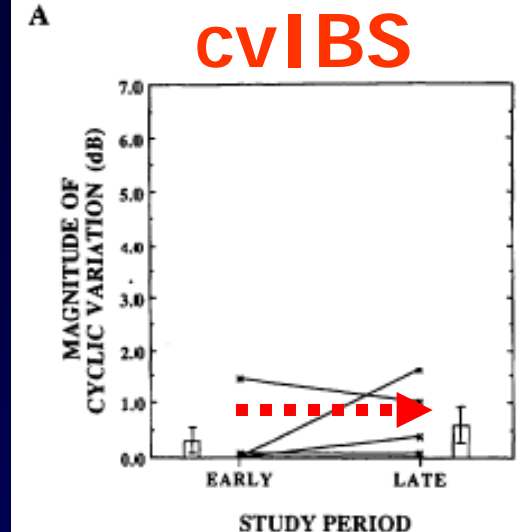
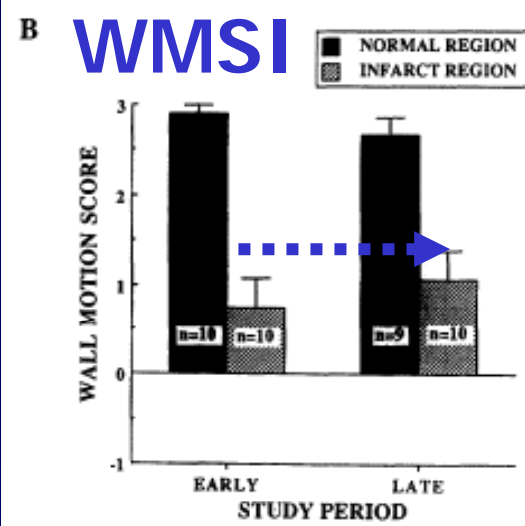
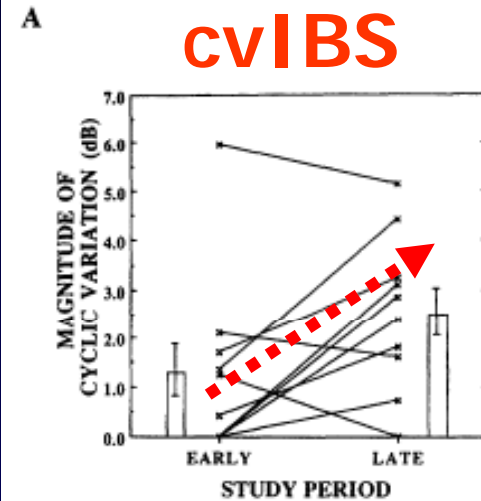
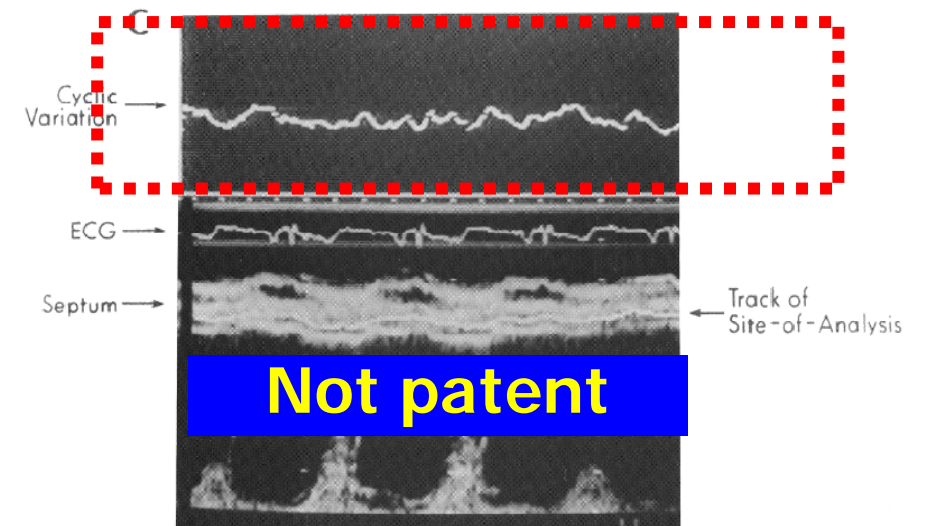

Cyclic variation of IBS (cvIBS)

Naito J et al. UMB 1995;21:33-49

Vitale DF et al. Circulation 1995;92:1452-7

Milunski MR et al. Circulation 1989;80:491-503

Cyclic Variation of IBS in AMI

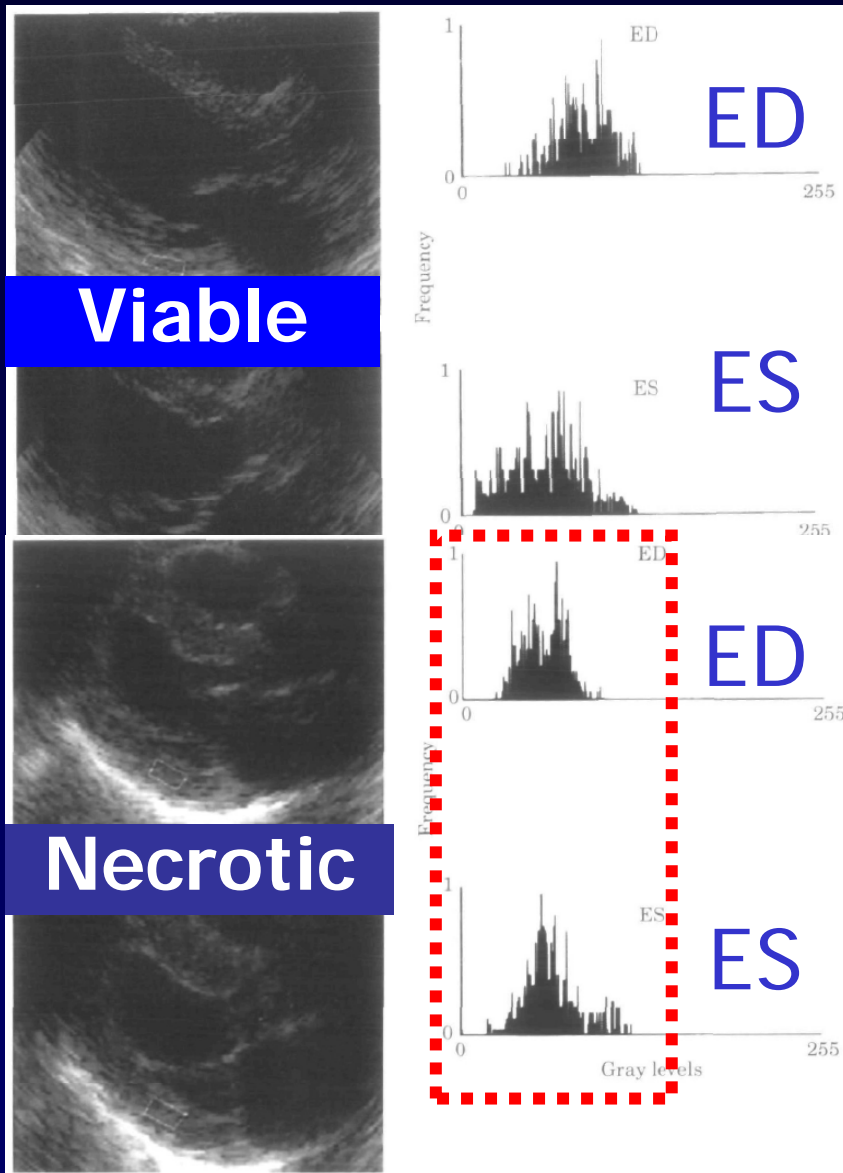


Milunski MR et al. *Circulation* 1989;80:491-503

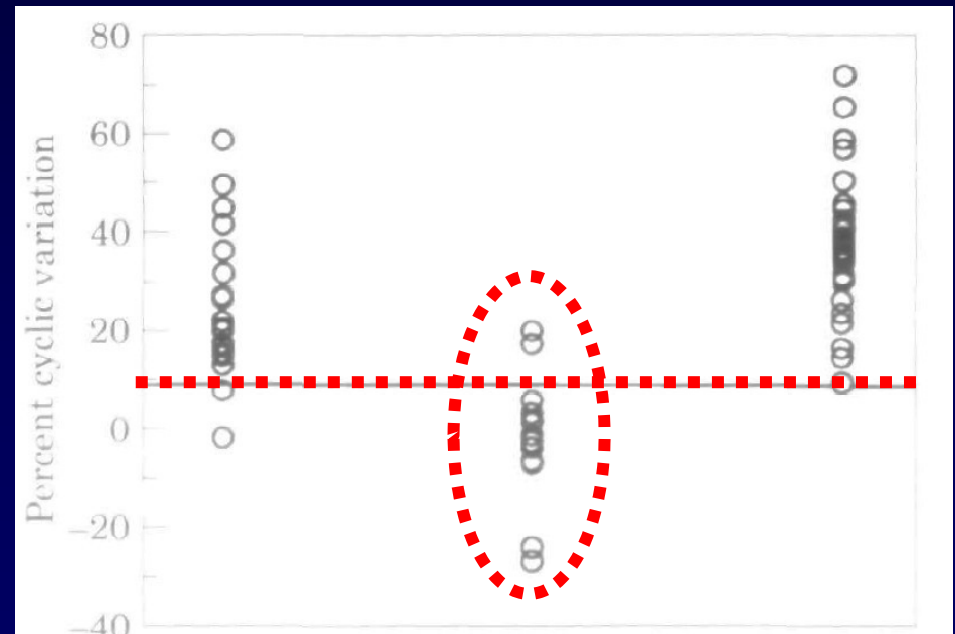
Patent

Not patent

Cyclic Variation of Video Intensity - Viability

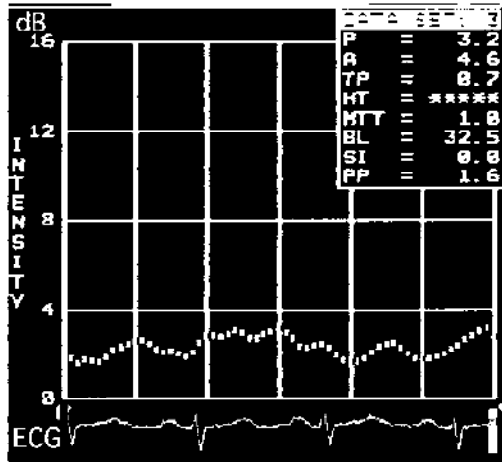


Percent Cyclic Variation

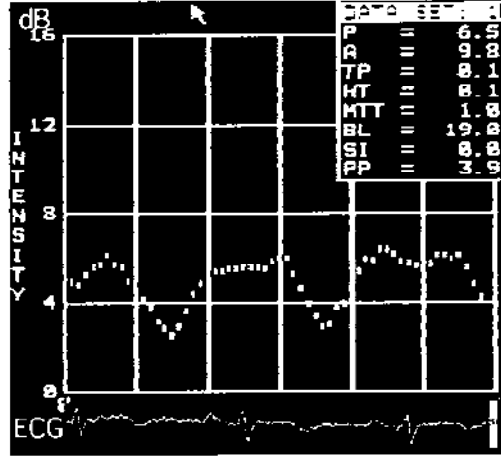


Viable Necrotic Control

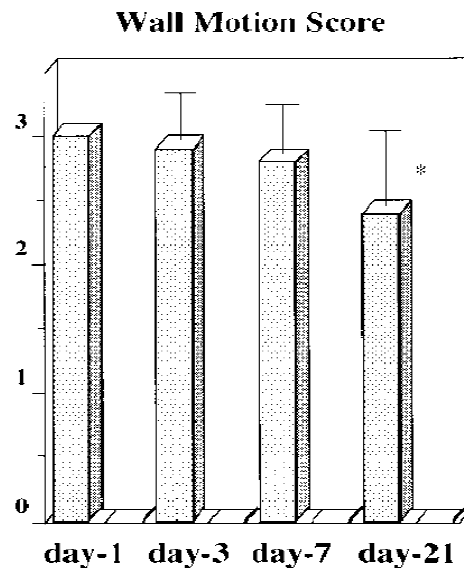
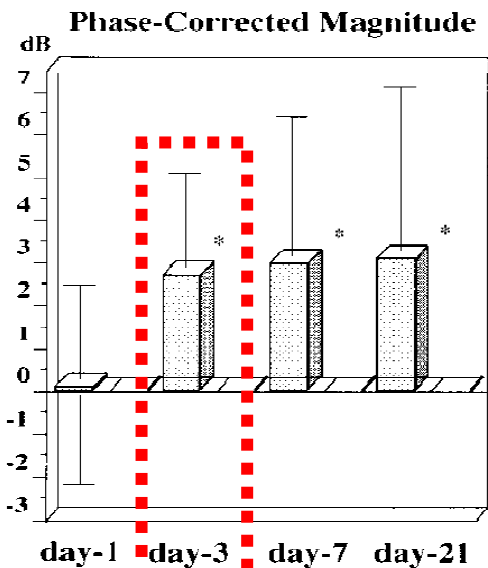
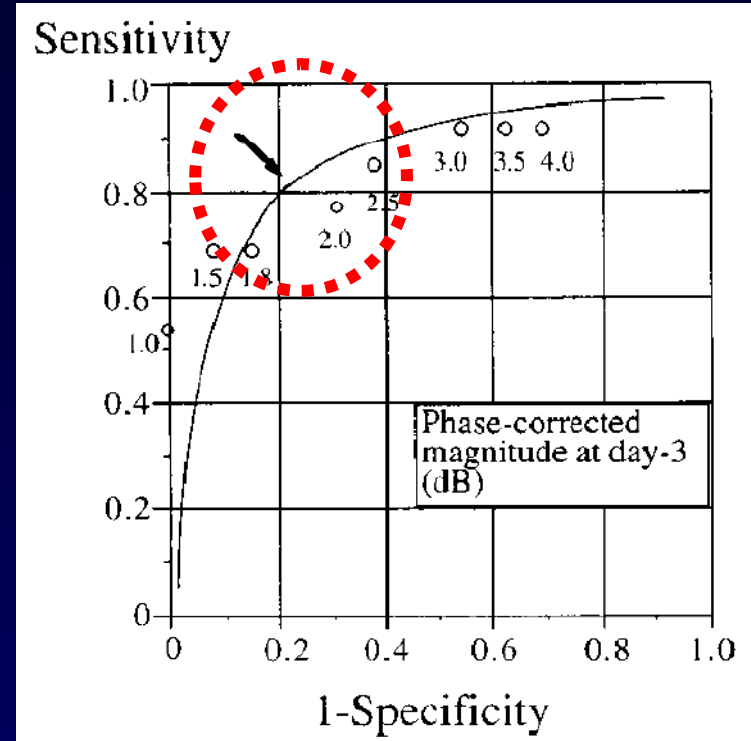
Cyclic Variation of IBS in AMI



Day-1



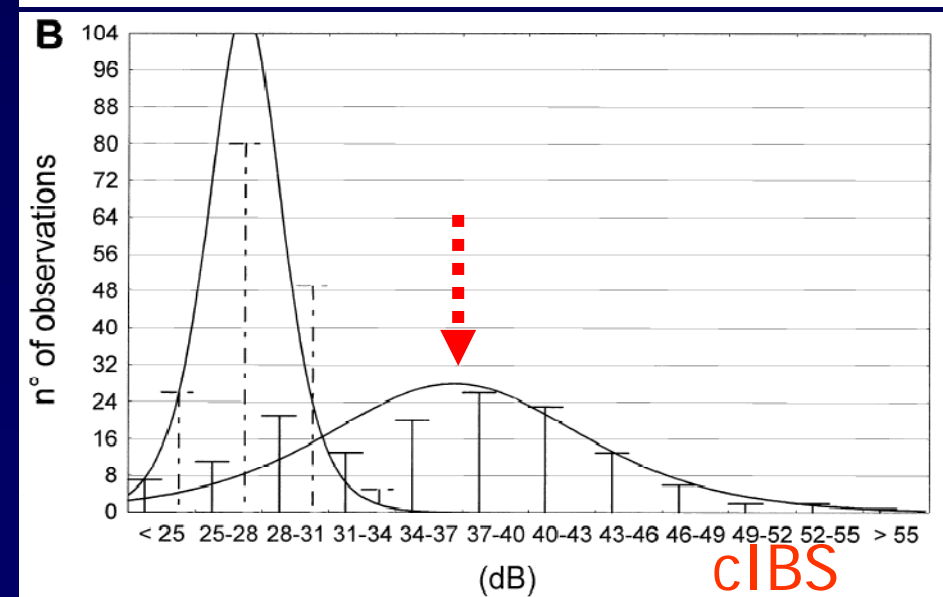
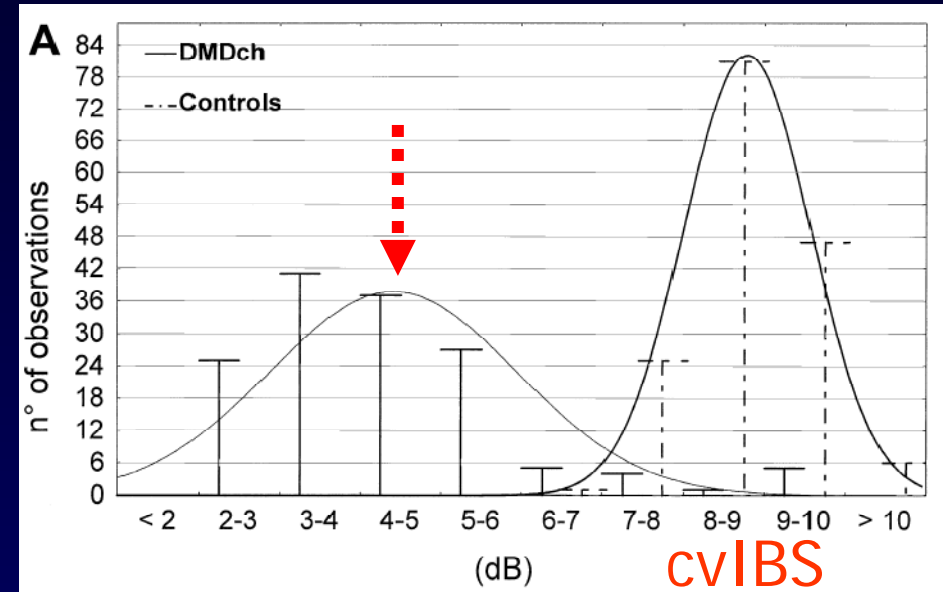
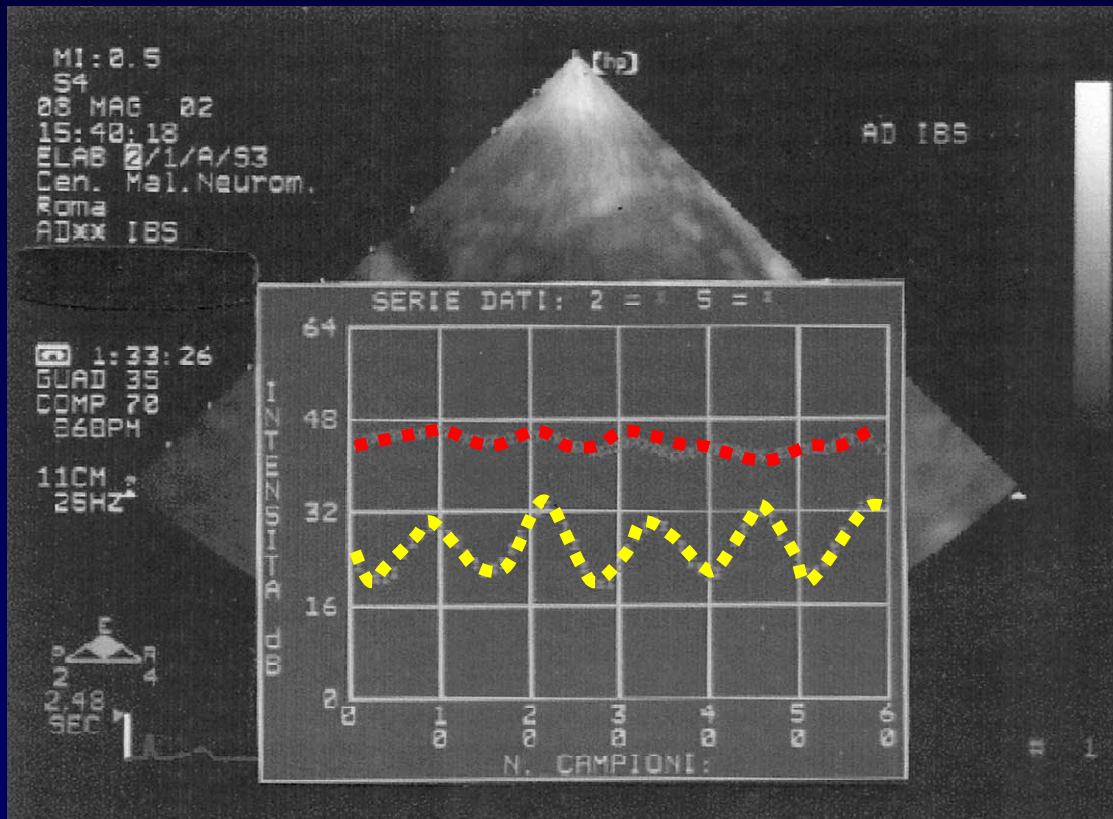
Day-3



Phase Corrected Magnitude of cvIBS > 2.0dB at D3 showed significant lower WMSI at D21

Duchenne Muscular Dystrophy in Preclinical Cardiac Involvement

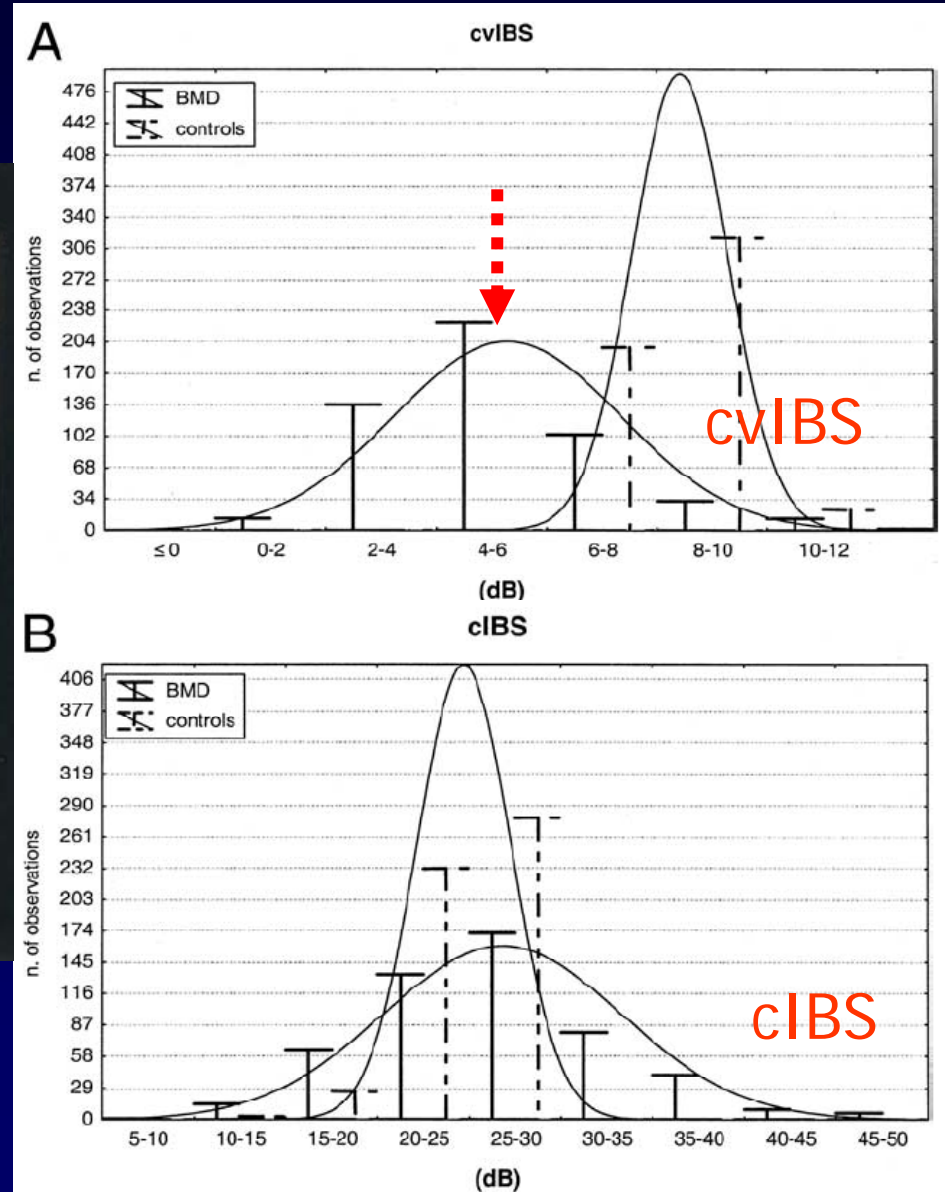
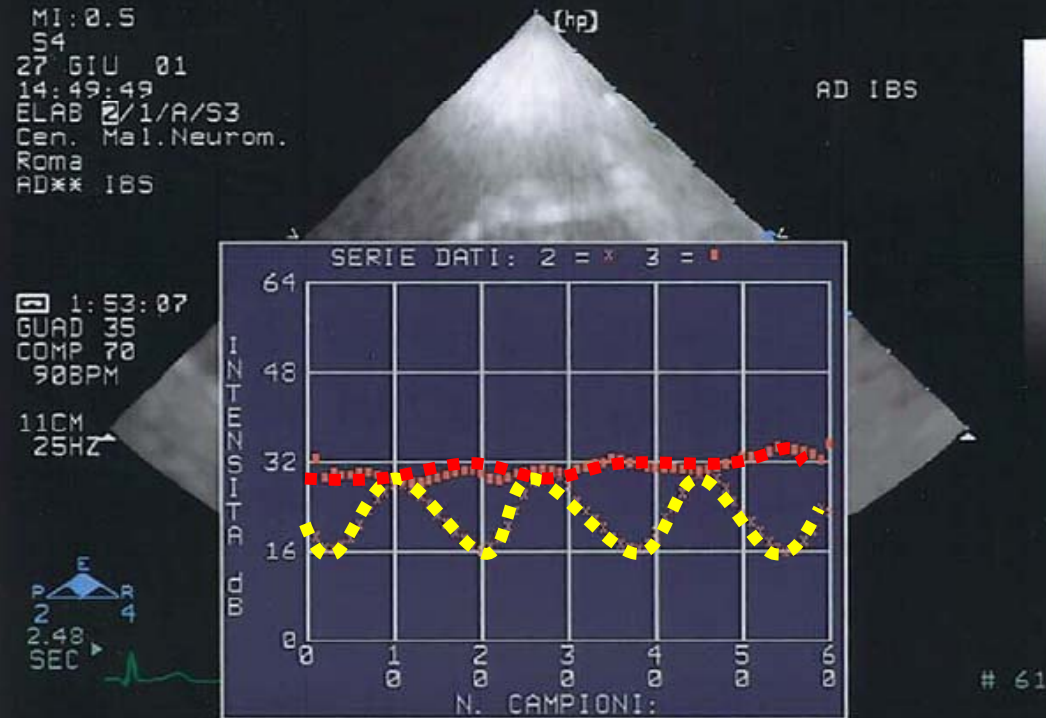
XR, Dystrophin



Giglio V et al. JACC 2003;42:309-16

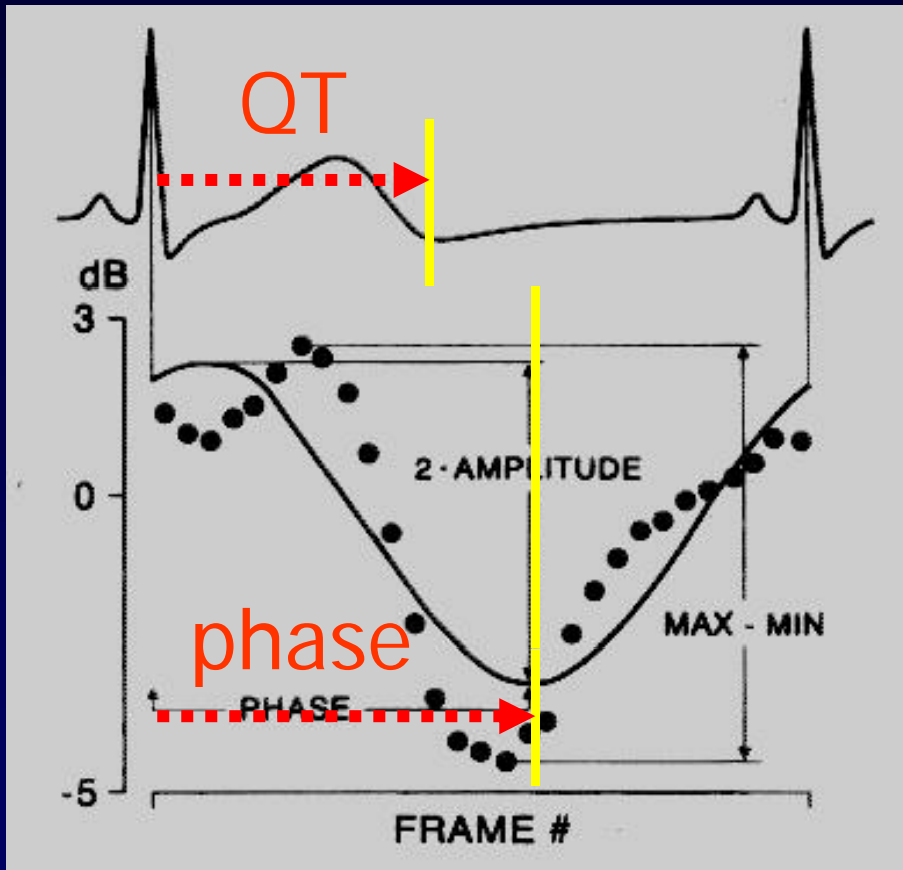
cvIBS in Becker Muscular Dystrophy with Functionally Normal Heart

XR, Dystrophin



Giglio V et al. JACC 2006;47:686-8

Phase Corrected Magnitude (PCM) of cvIBS



Mean of the normalized delay in the normal segment as 1.00 ± 0.1

Normalized delay value in the normal segment was 1.2 (mean 2 SD of normal)

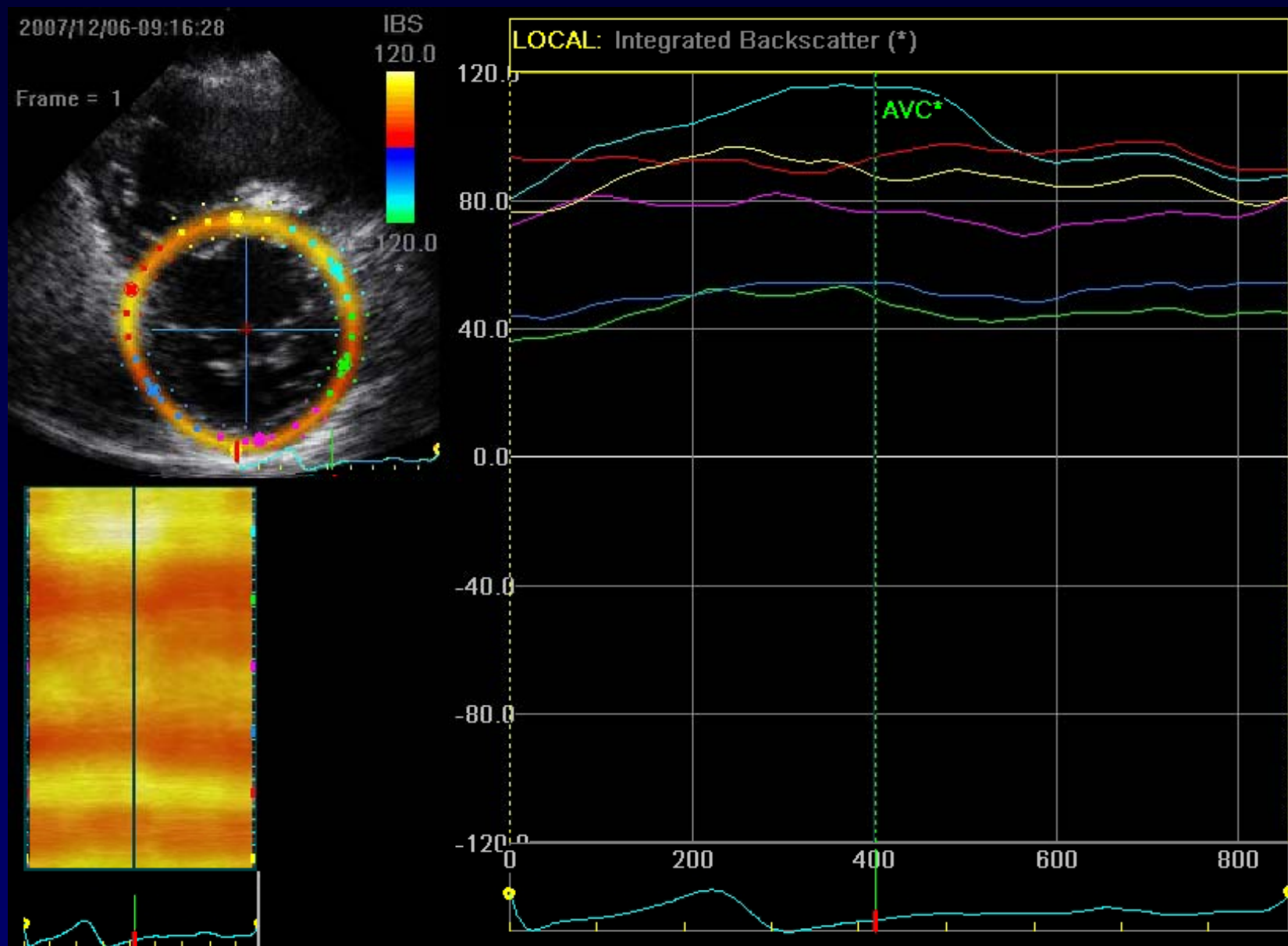
Delayed contraction or Passive stretching (normalized delay > 1.2)
; Multiplied the magnitude by -1.0

Normalized delay = phase/QT

Vitale DF et al. Circulation 1995;92:1452-7

Takiuchi S et al. Circulation 1998;97:356-62

Integrated Backscatter (IBS)




Tissue Characterization in Echo

- ✓ Qualitative – M-mode, 2D
- ✓ Integrated Backscatter (IBS)
- ✓ **Tissue Doppler Imaging (TDI)**
- ✓ Deformation Imaging (SRI)
- ✓ Myocardial Contrast Echo (MCE)


Tissue Doppler Imaging (TDI)

Blood Flow

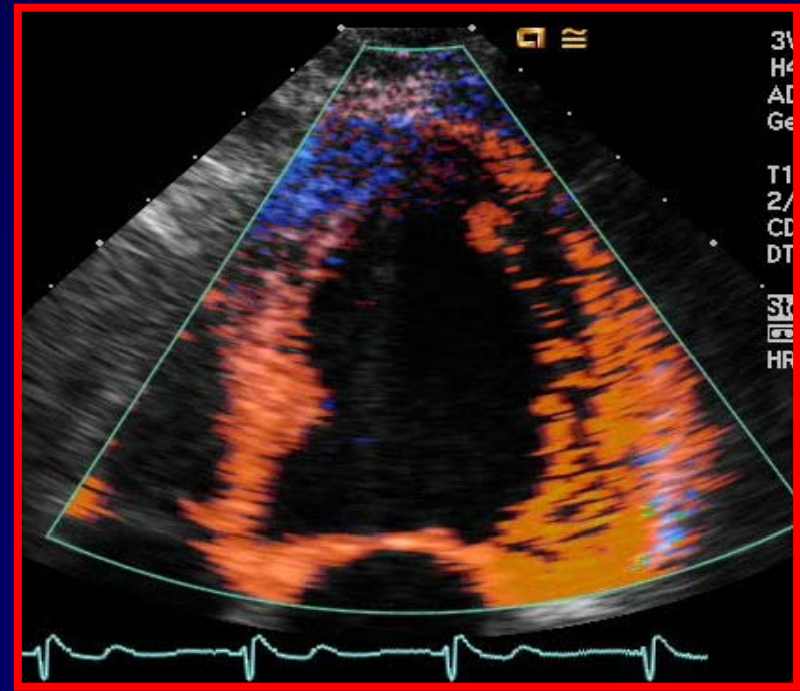
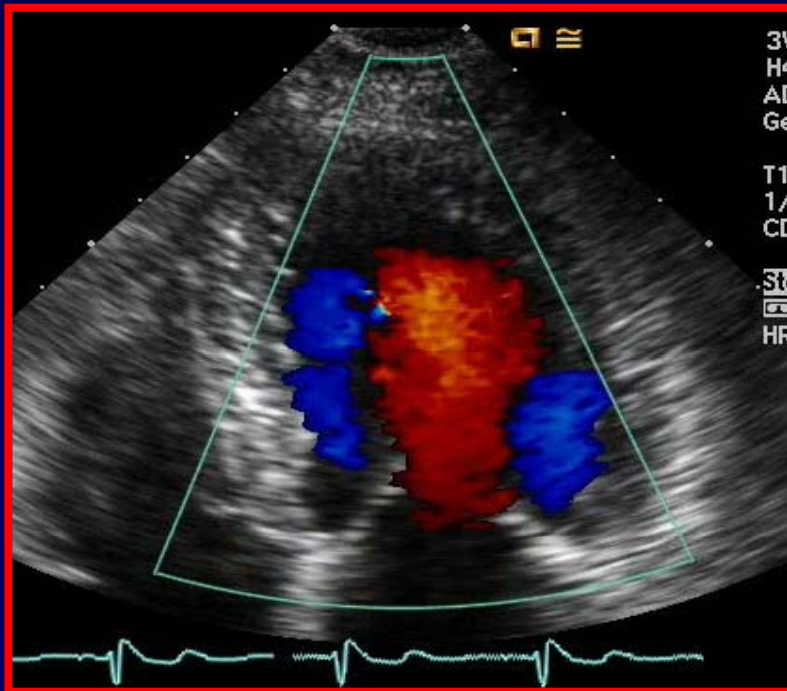


High velocity
Low amplitude

Myocardium

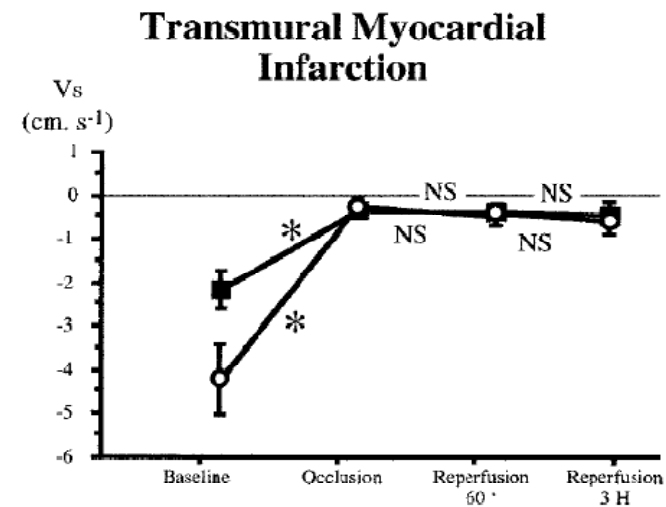
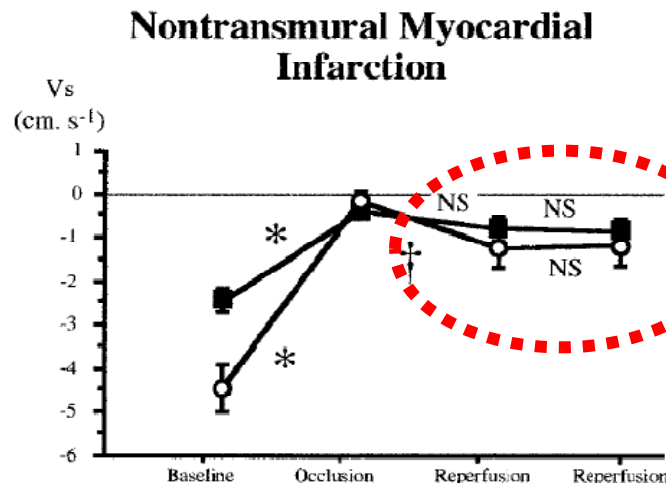


Low velocity;
High amplitude



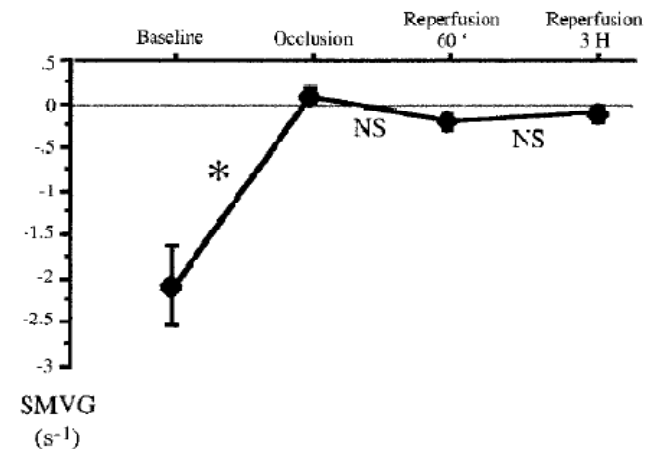
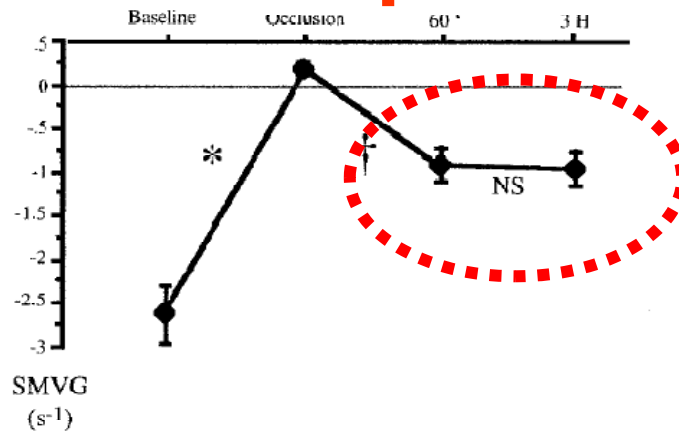
TDI Differentiates Transmurality in AMI After Reperfusion

Systolic Velocity

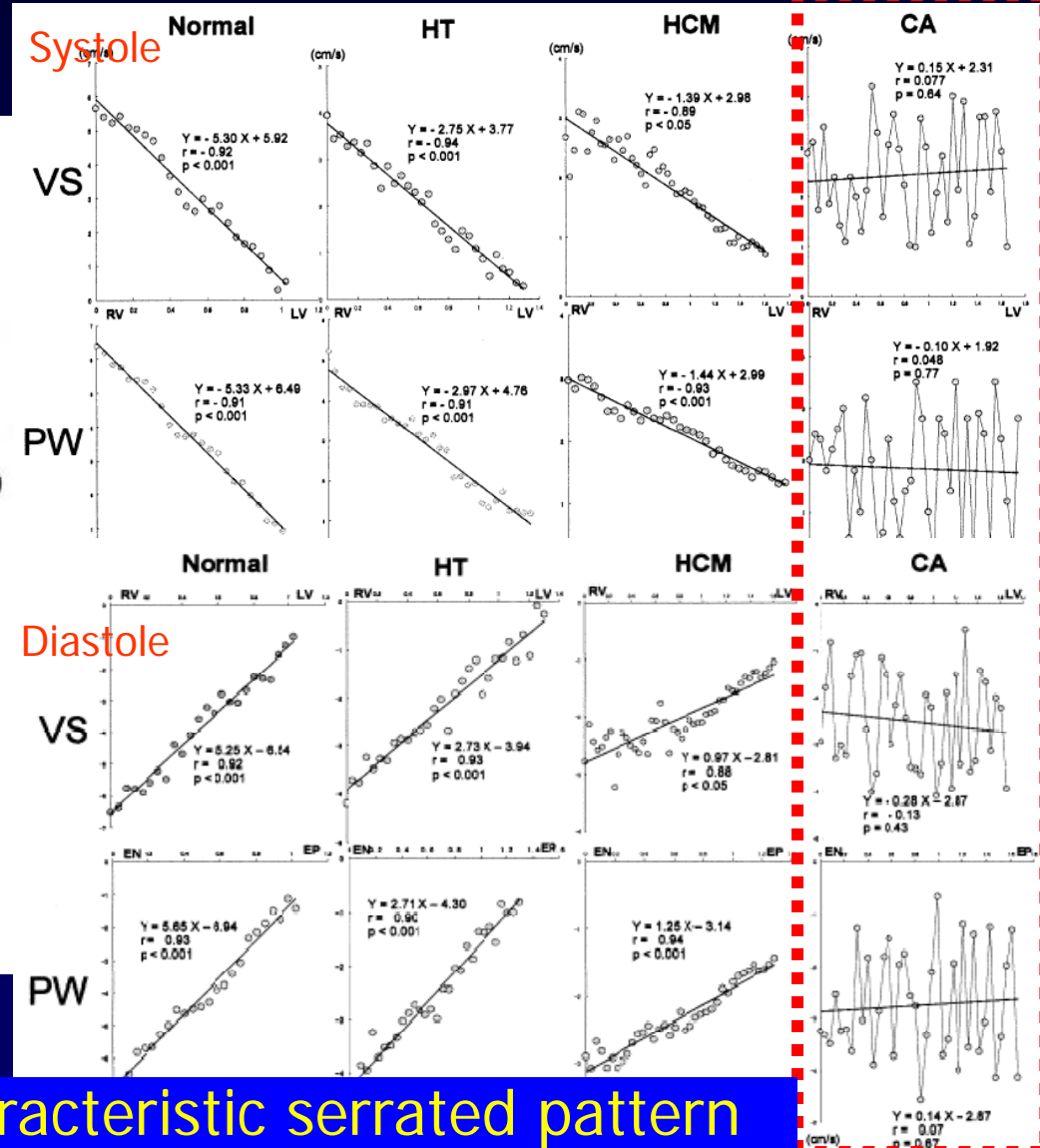
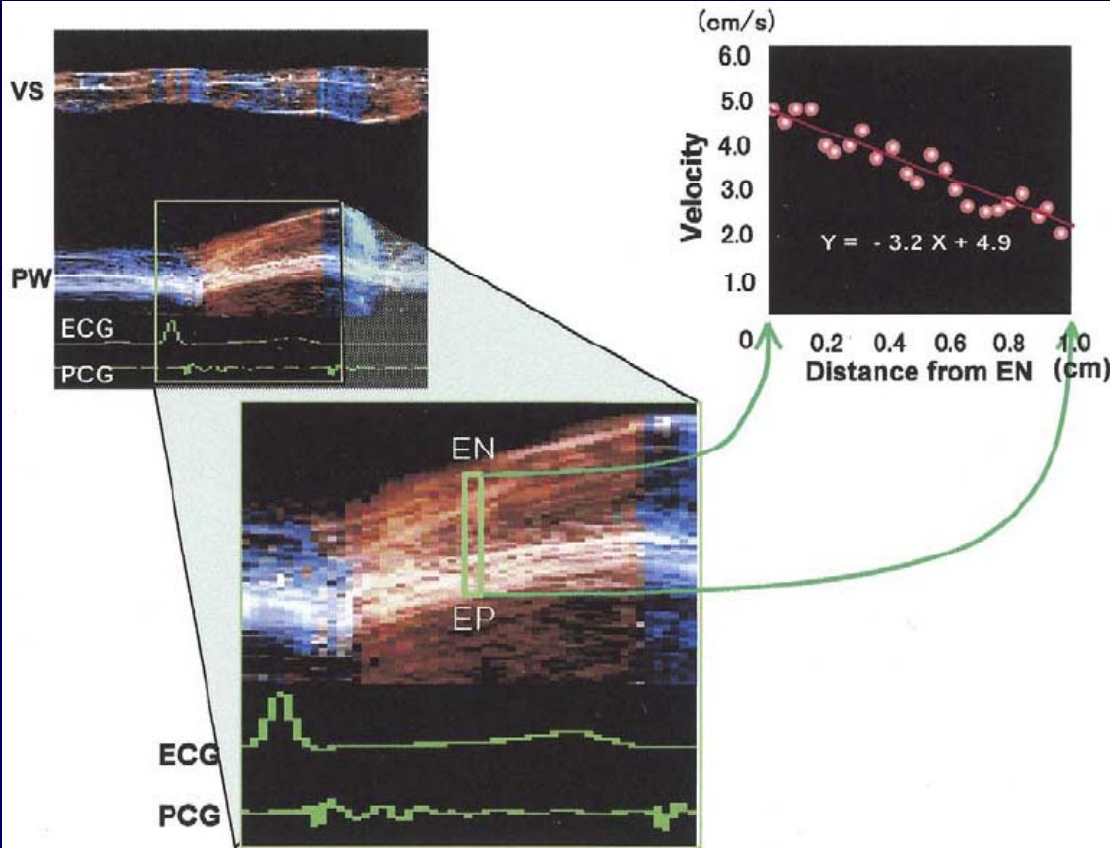


Reperfusion

Systolic Myocardial Velocity Gradient (MVG)



Cardiac Amyloidosis Diagnosed by Color-coded TDI (MVG)



Okita et al. Am J Cardiol 2004;93:864-9

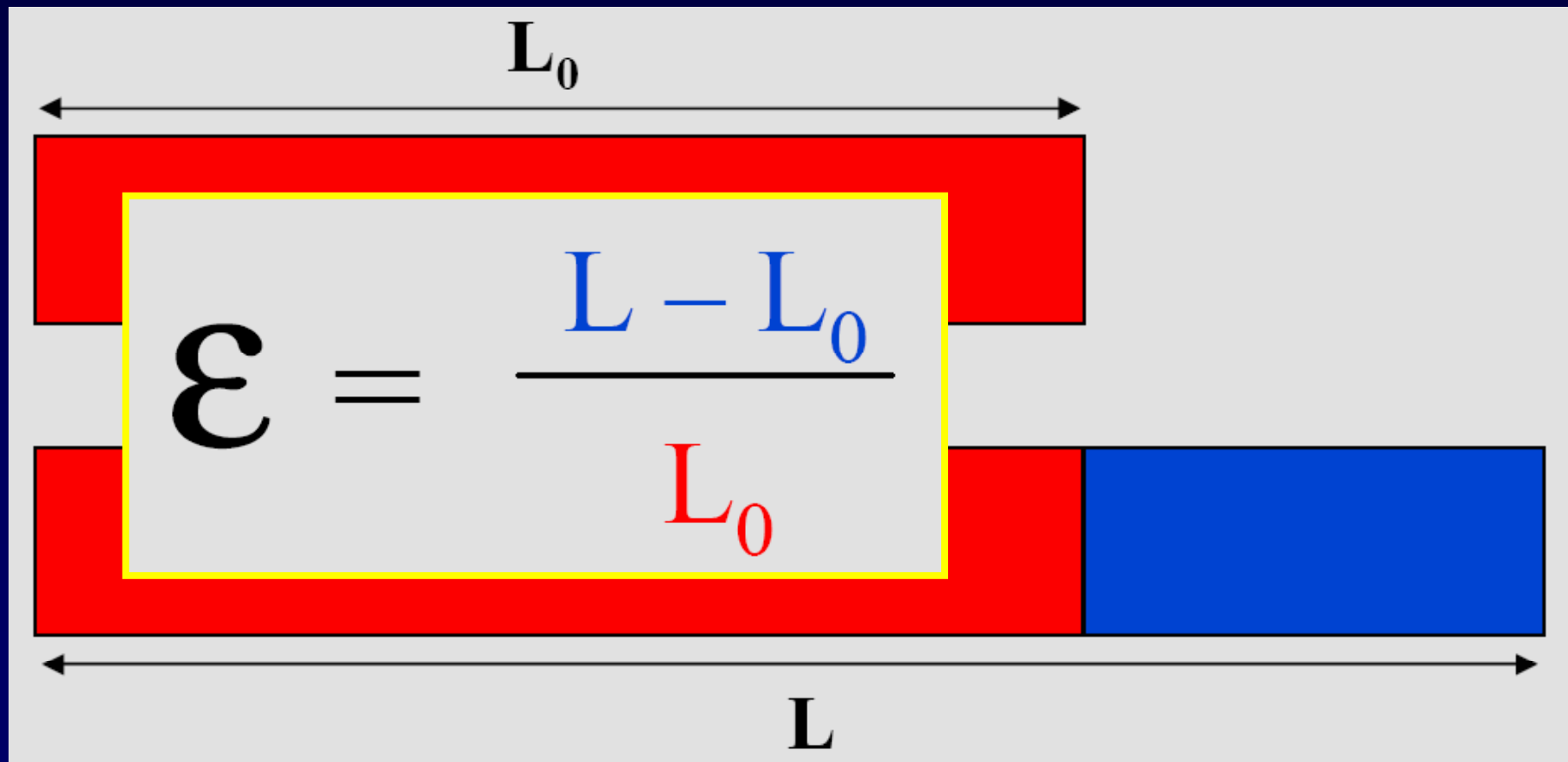
Characteristic serrated pattern

Tissue Characterization in Echo

- ✓ Qualitative – M-mode, 2D
- ✓ Integrated Backscatter (IBS)
- ✓ Tissue Doppler Imaging (TDI)
- ✓ **Deformation Imaging (SRI)**
- ✓ Myocardial Contrast Echo (MCE)

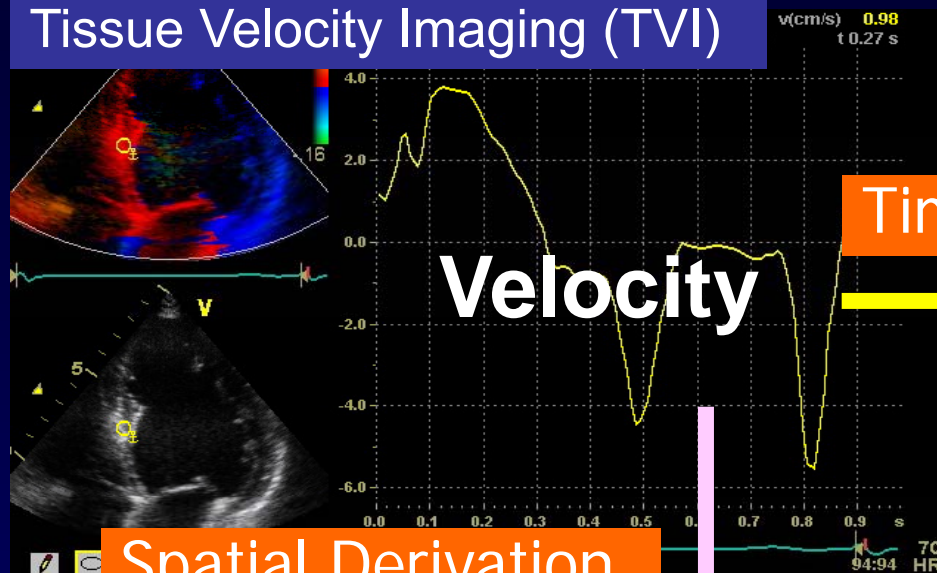
What is *Deformation Imaging*?

Strain (ϵ) - the deformation of an object expressed with respect to its original shape

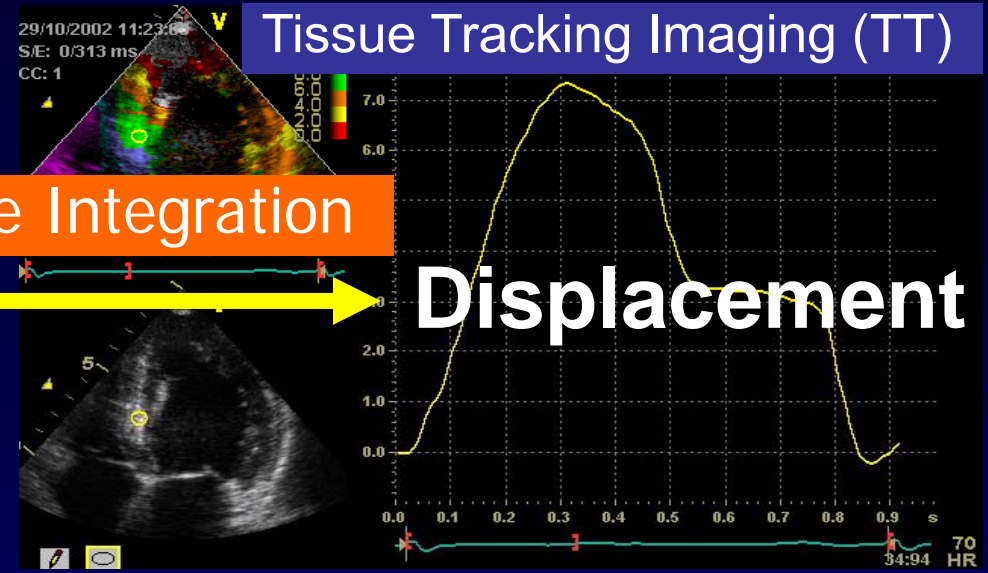


Motion & Deformation

Tissue Velocity Imaging (TVI)



Tissue Tracking Imaging (TT)



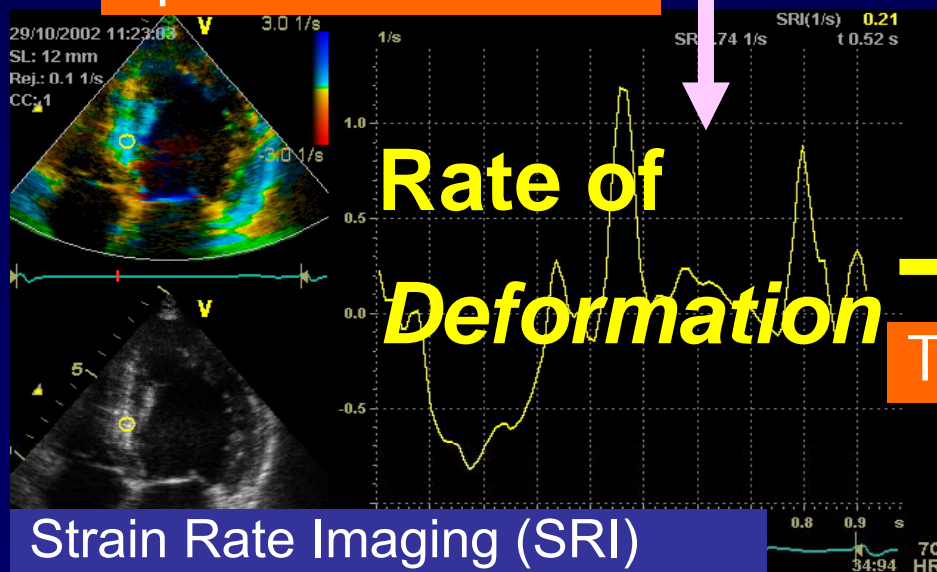
Time Integration



Spatial Derivation

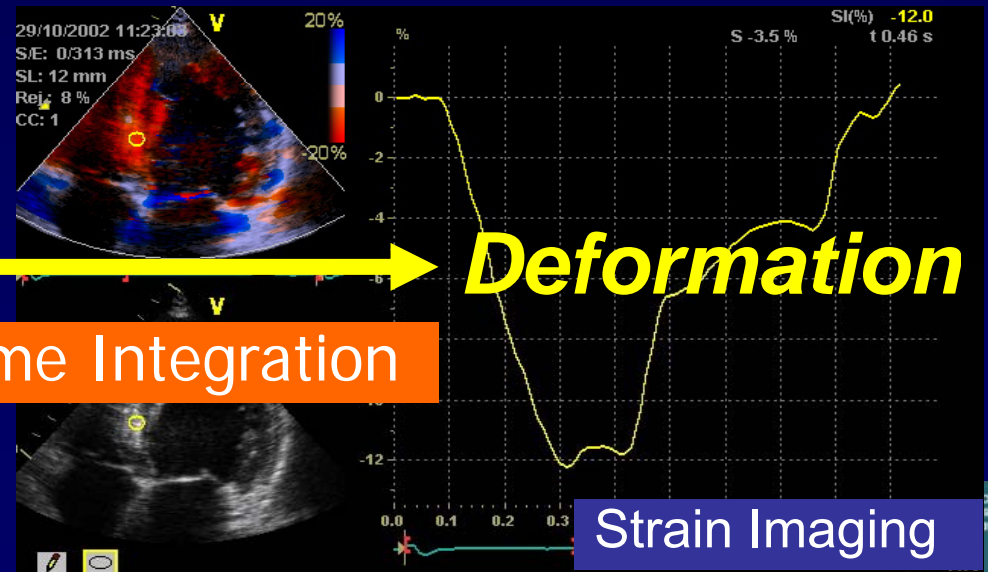


Rate of Deformation

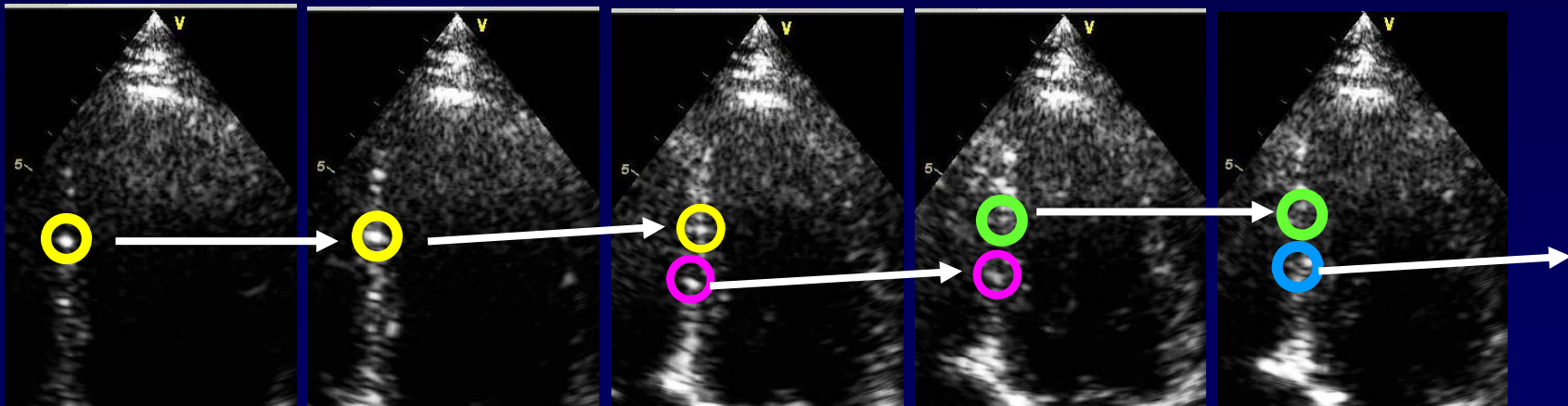
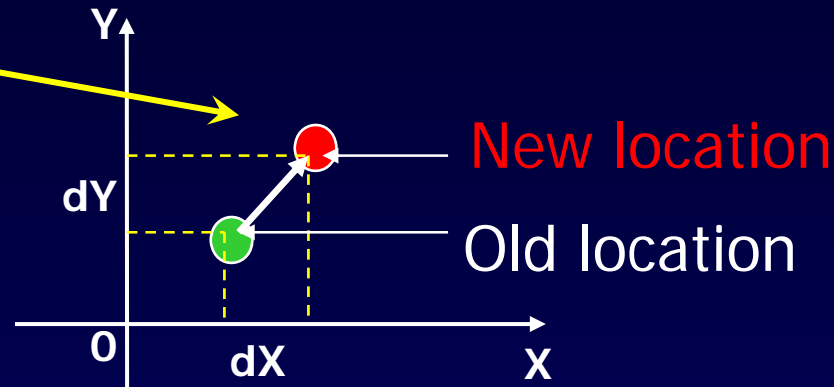
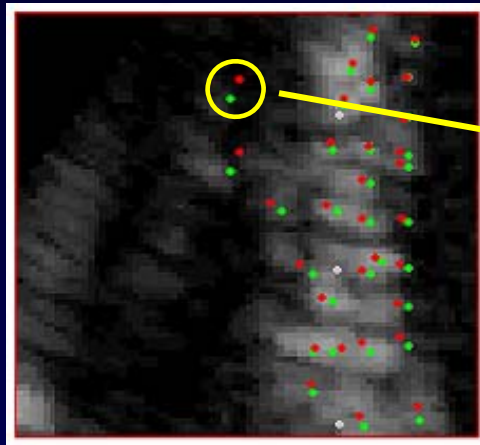


Time Integration

Deformation



What is *Speckle Tracking Imaging*?



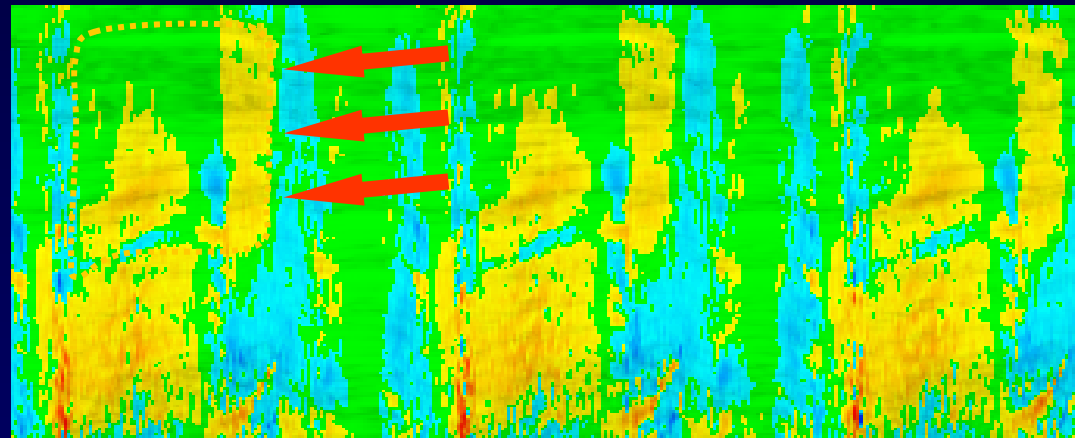
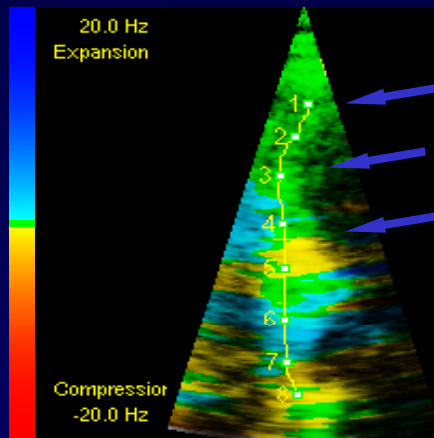
Myocardial Motion Characterization
by *Natural Acoustic "Tagging"*

Doppler Strain vs. 2D Strain

| | <i>Doppler Strain</i> | <i>2D Strain</i> |
|--------------------------|--|--|
| Source | Tissue Doppler | 2D Images |
| Theory | Doppler | 2D Pattern Tracking |
| Measure | Velocity along with acoustic beam line | Direct measurements of 2 dimensional movement |
| Angle dependency | YES | NO |
| Limitation of scan plane | YES Difficult for APEX, SAX | NO |
| Index | Velocity Strain Strain Rate TT, TSI | + Radial Strain, Circumferential Strain, Torsion |

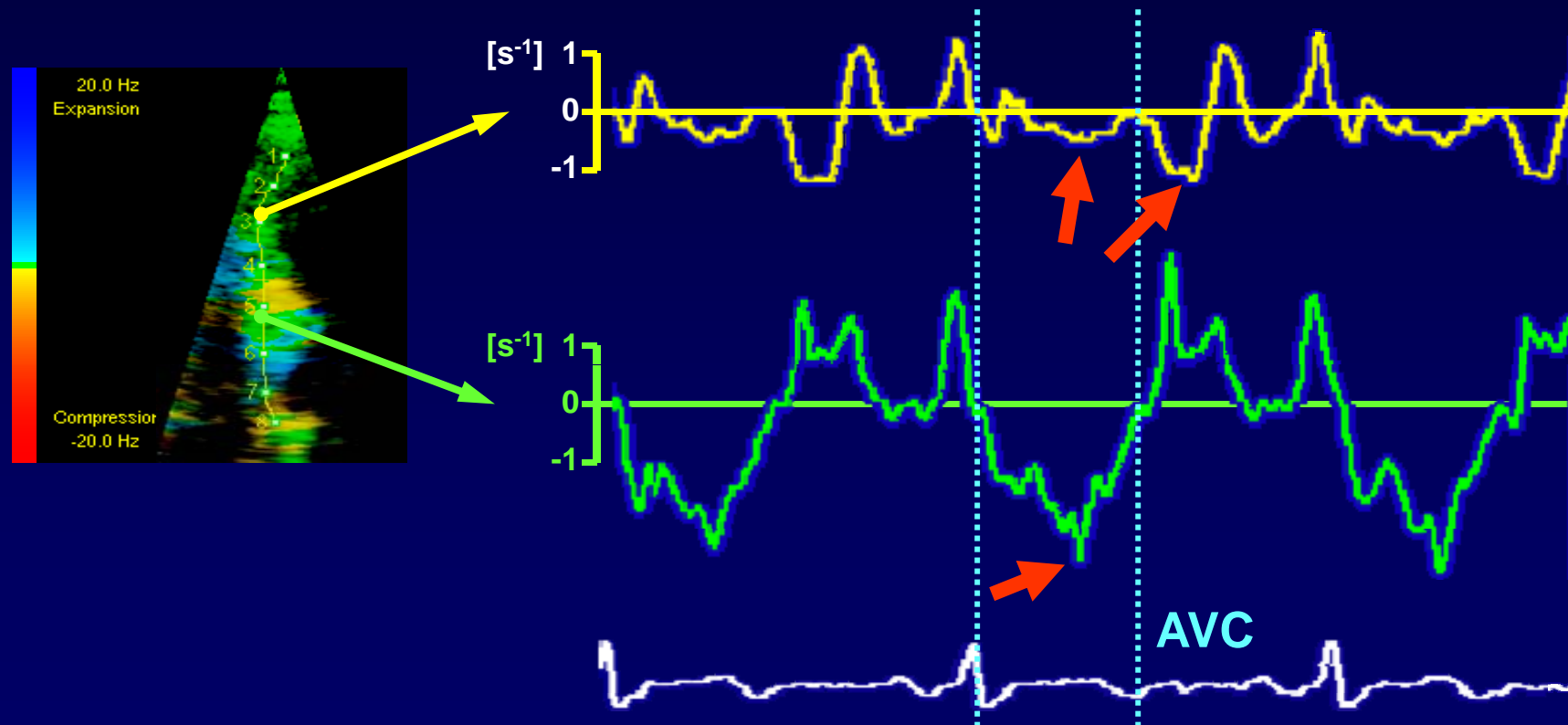
Strain Rate for Assessing Viability

Acute myocardial infarction in man
(LAD occlusion)



Strain Rate for Assessing Viability

Acute myocardial infarction in man
(LAD occlusion)



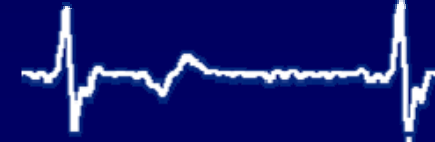
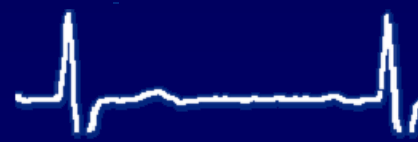
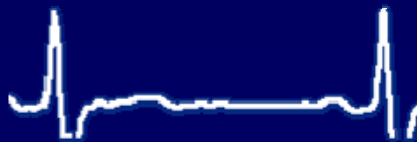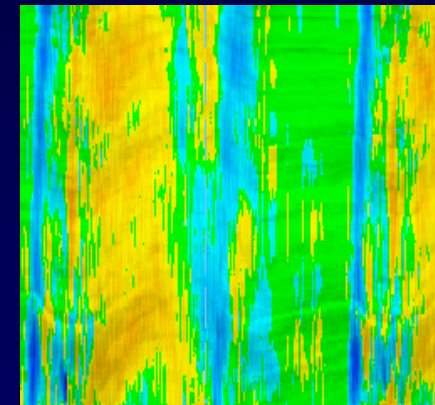
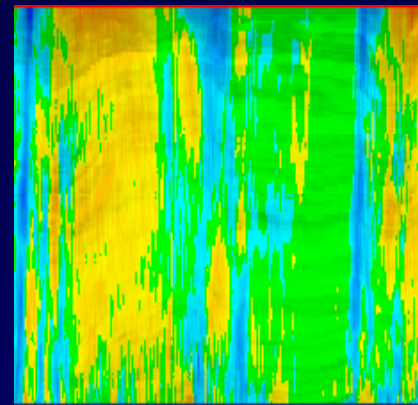
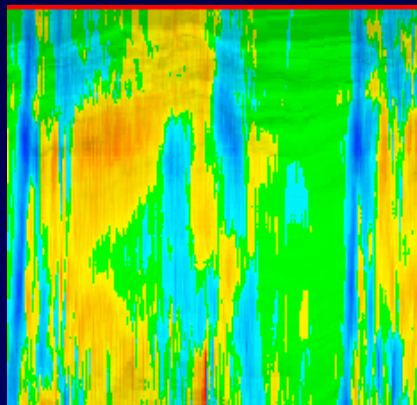
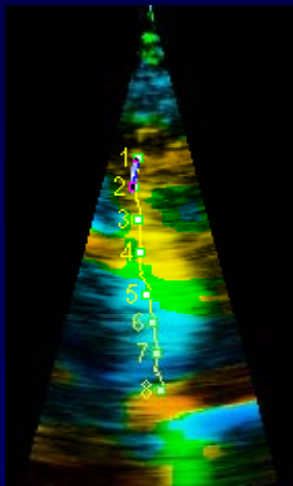
Strain Rate for Assessing Viability

Recovery

acute MI

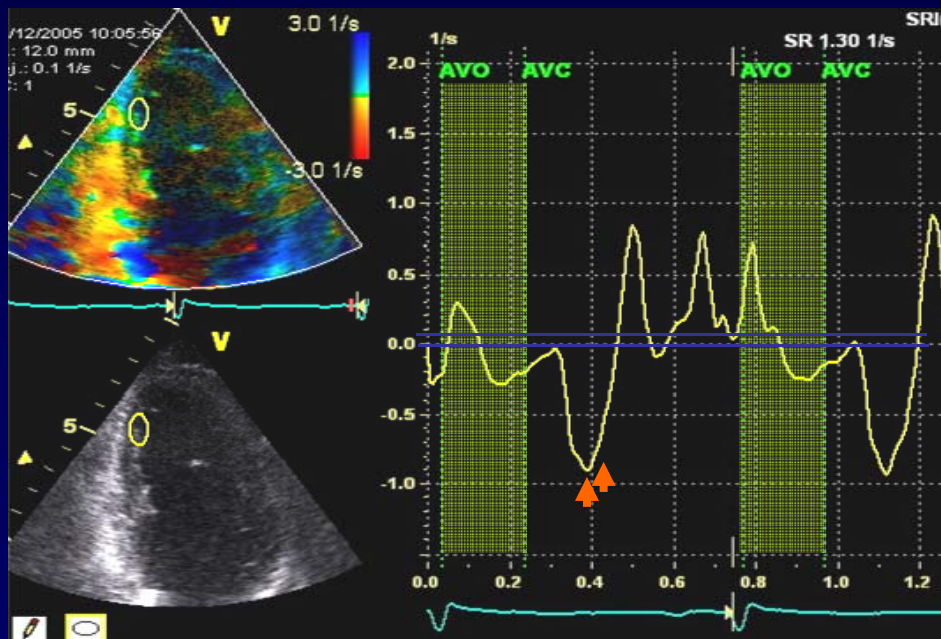
1 day

2 weeks



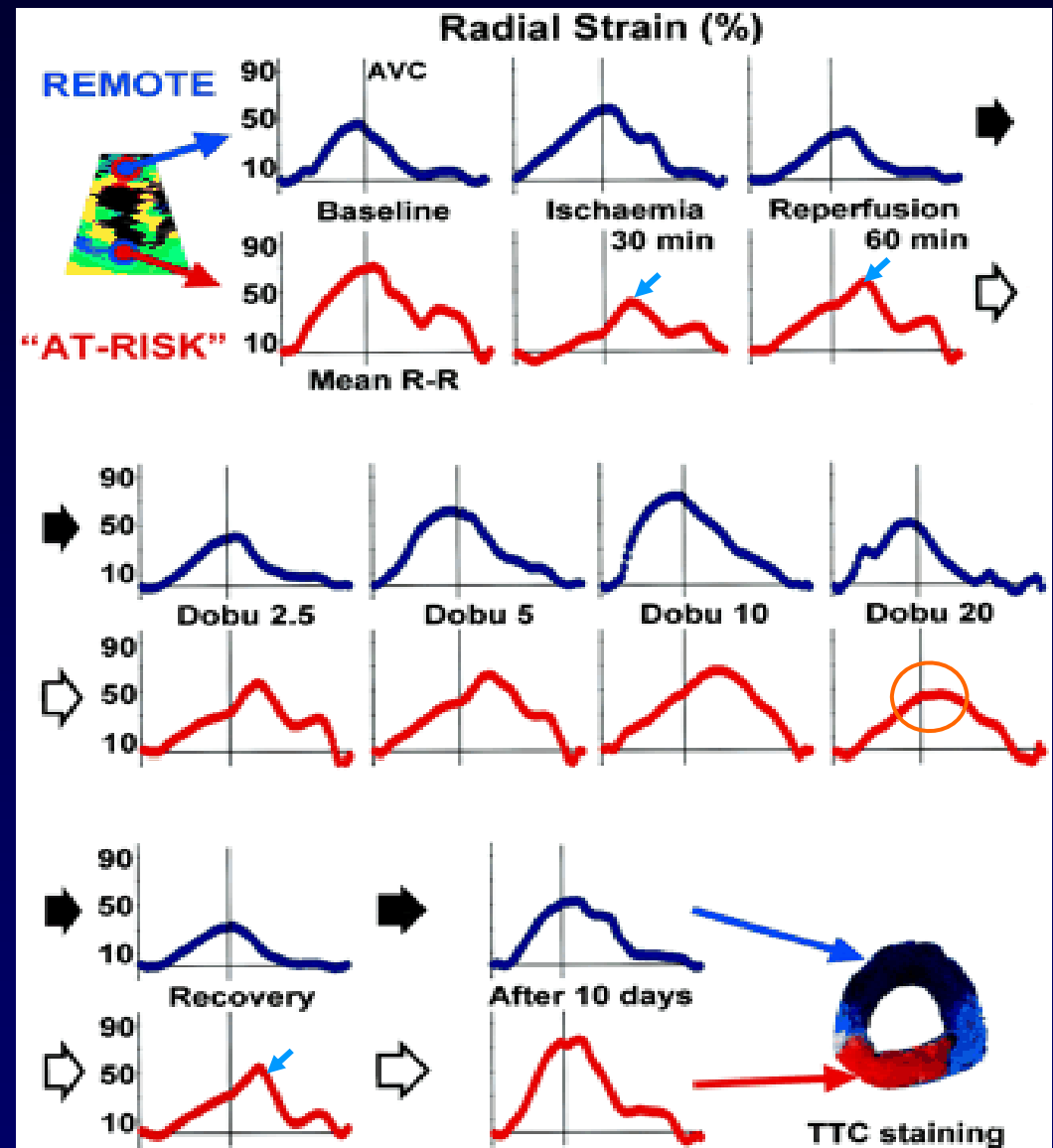
Postsystolic Shortening

- Myocardial ischemia
- Myocardial viability
- Resolved by dobutamine in stunned myocardium

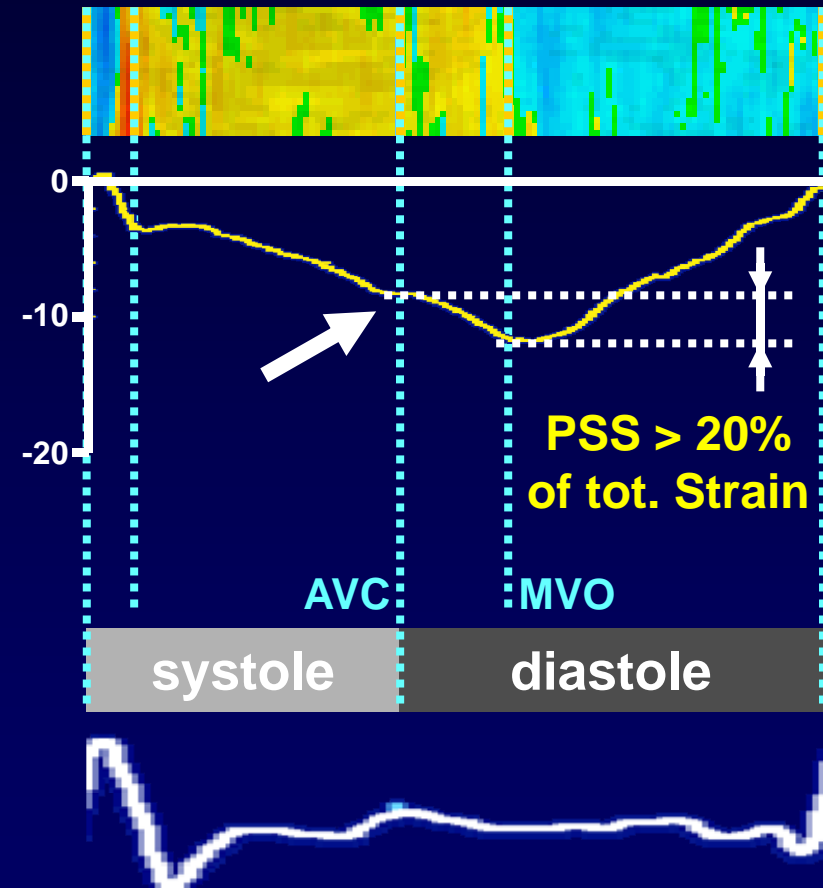
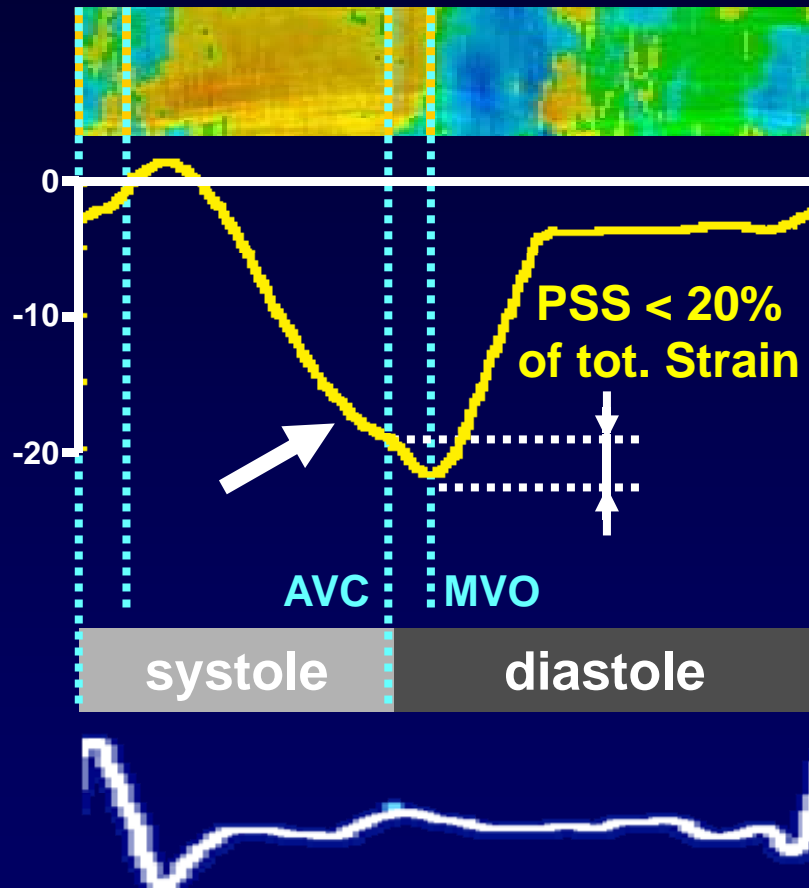


Infarction

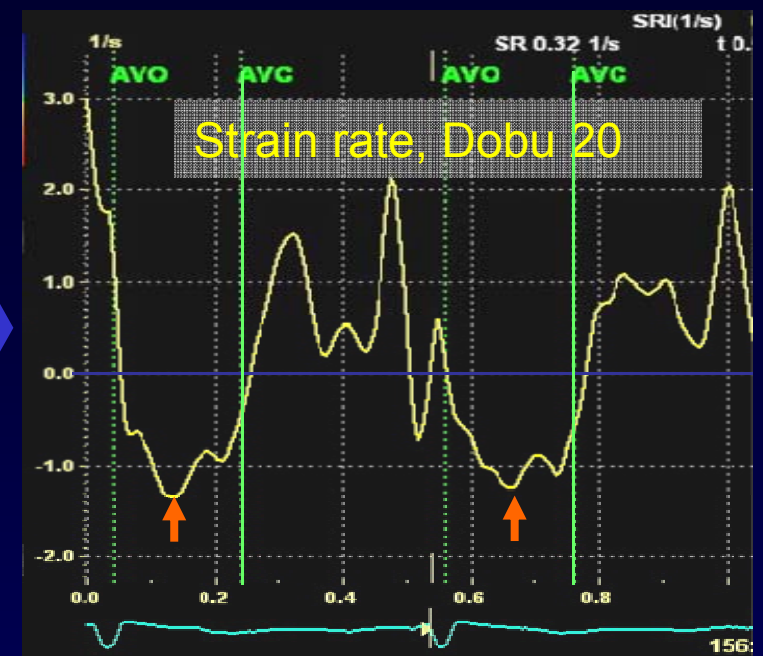
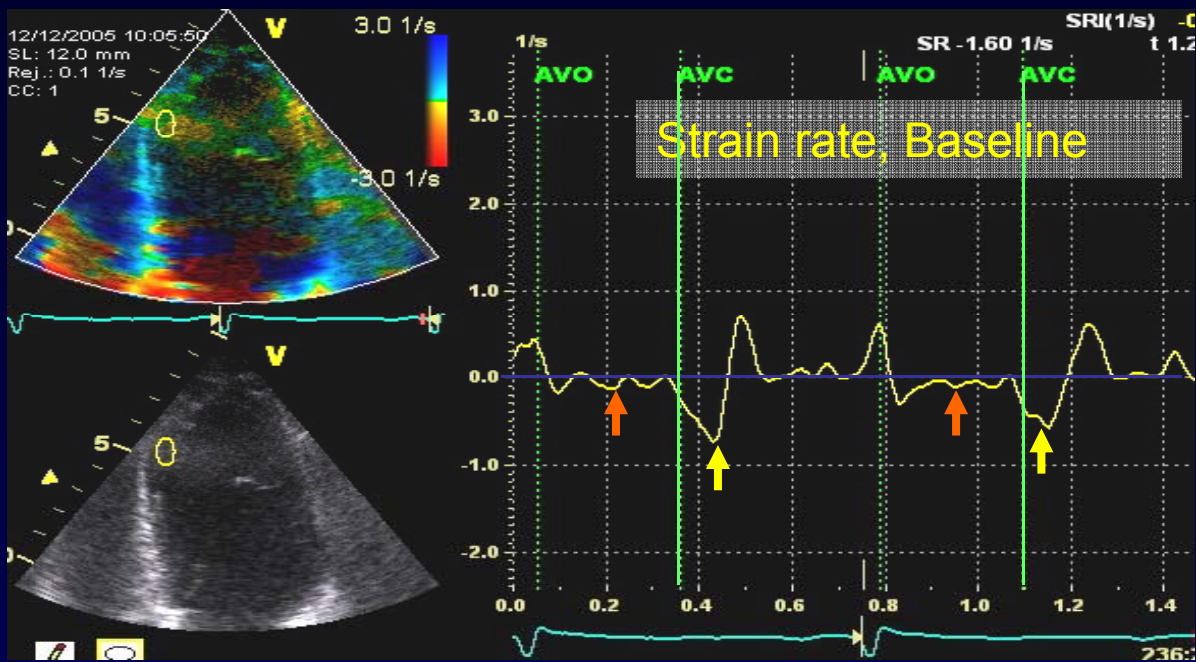
Jamal et al. *Circulation* 2001;104(9):1059-65



Post Systolic Shortening



**PSS defined as predominantly negative SR
between AVC and E-wave**



| | Rest | | | Dobutamine Stress | | |
|------------------|-------------------|------------------|-----|-------------------|------------------|-----|
| | SR _{SYS} | ε _{SYS} | PSI | SR _{SYS} | ε _{SYS} | PSI |
| Control | 5/s | 60 % | 2 % | ↗ | ↘ | → |
| Stunning | ↓ | ↓ | ↑ | ↗ | ↗ | ↘ |
| Acute ischemia | ↓ | ↓ | ↑ | ↘ | ↘ | ↗ |
| Nontransmural MI | ↓ | ↓ | ↑ | ↘ | → | ↗ |
| Transmural MI | ↓ ↓ | ↓ ↓ | ↑ ↑ | → | → | → |

Weidemann et al. Circulation 2003;107(6):883-8

MD Study Design

134 consecutive AMI patients Enrolled & Complete Baseline Studies (LDDSE, NT-proBNP and Cath data)

29 with incomplete information

- 15 alive at last visit
- 3 withdrawn consent
- 11 lost to follow-up

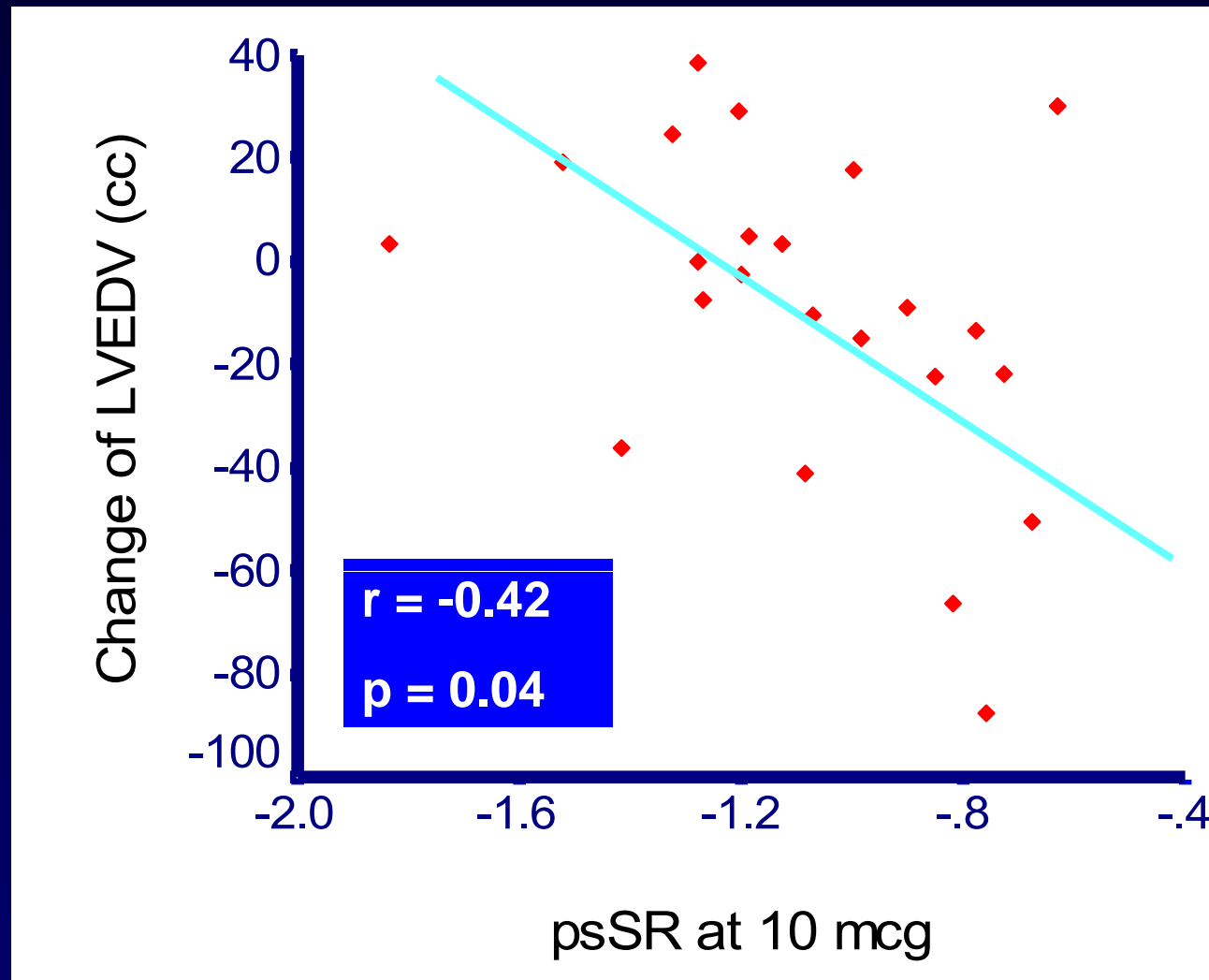
- 105 with complete information (95 alive and 10 dead)
- 95 patients completed 6M f/u echocardiography and NT-proBNP
- 35 patients completed TI^{99m} with delayed image

33 with incomplete strain analysis

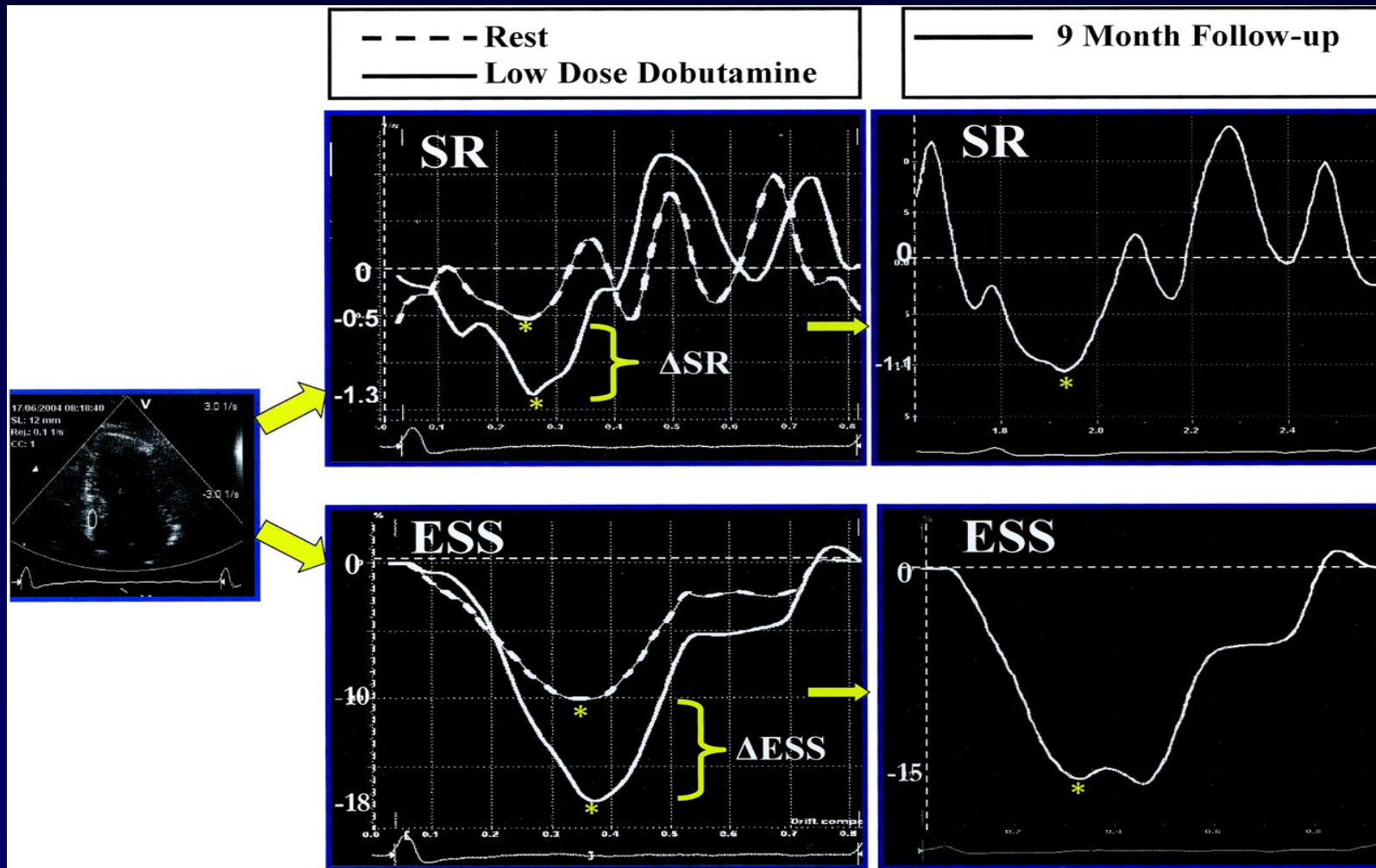
- poor image quality
- inadequate acquisition technique
- incomplete data...

62 patients with complete strain data & 744 segments assessed for psSR, time to peak psSR and PST by 2 independent experts

Correlation Between Global psSR at 10mcg of LDDSE and Change of LVEDV



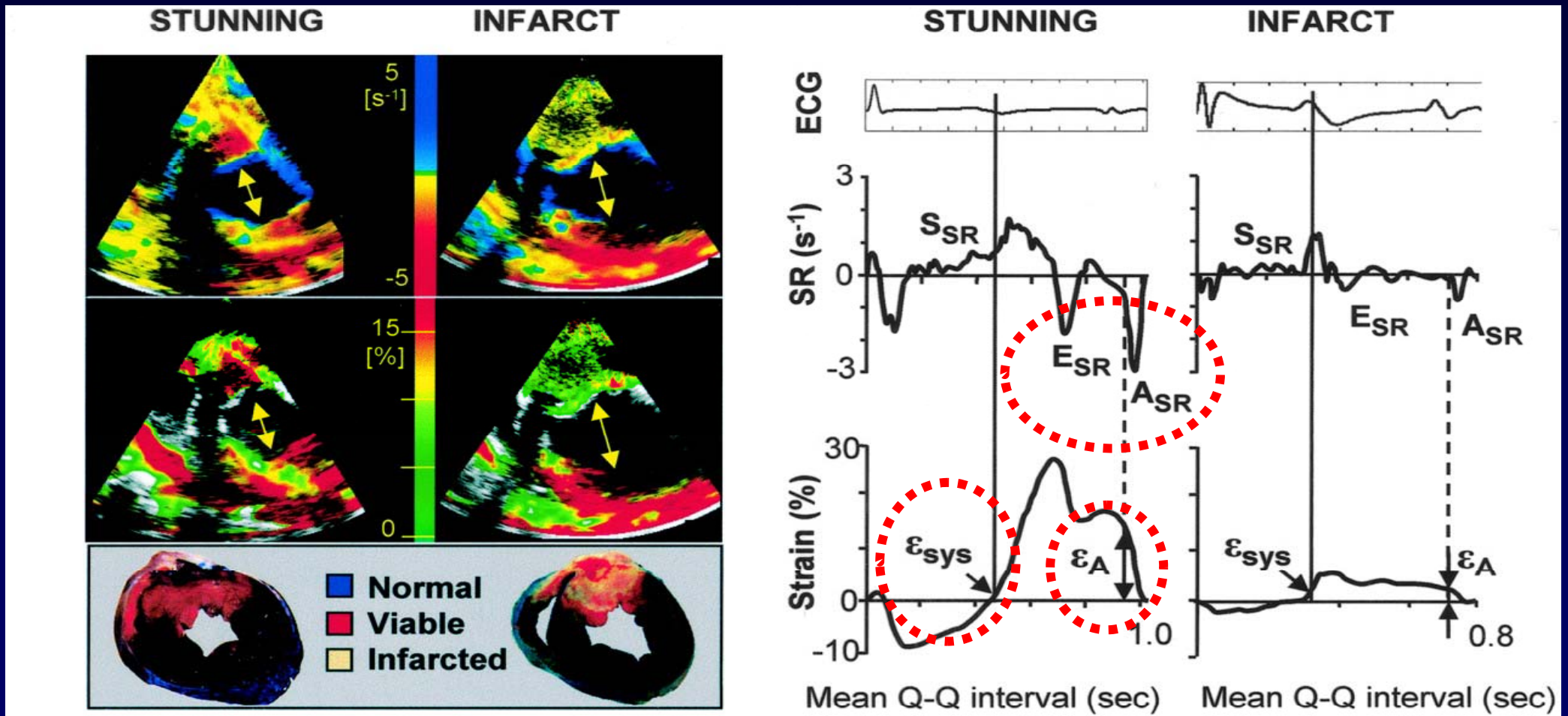
Incremental Value of SRI Assessment of Myocardial Viability after Revascularization



Hanecom et al. *Circulation* 2005;20;112(25):3892-900

Altered Myocardial Stiffness

Stunned Vs. Transmural Infarct

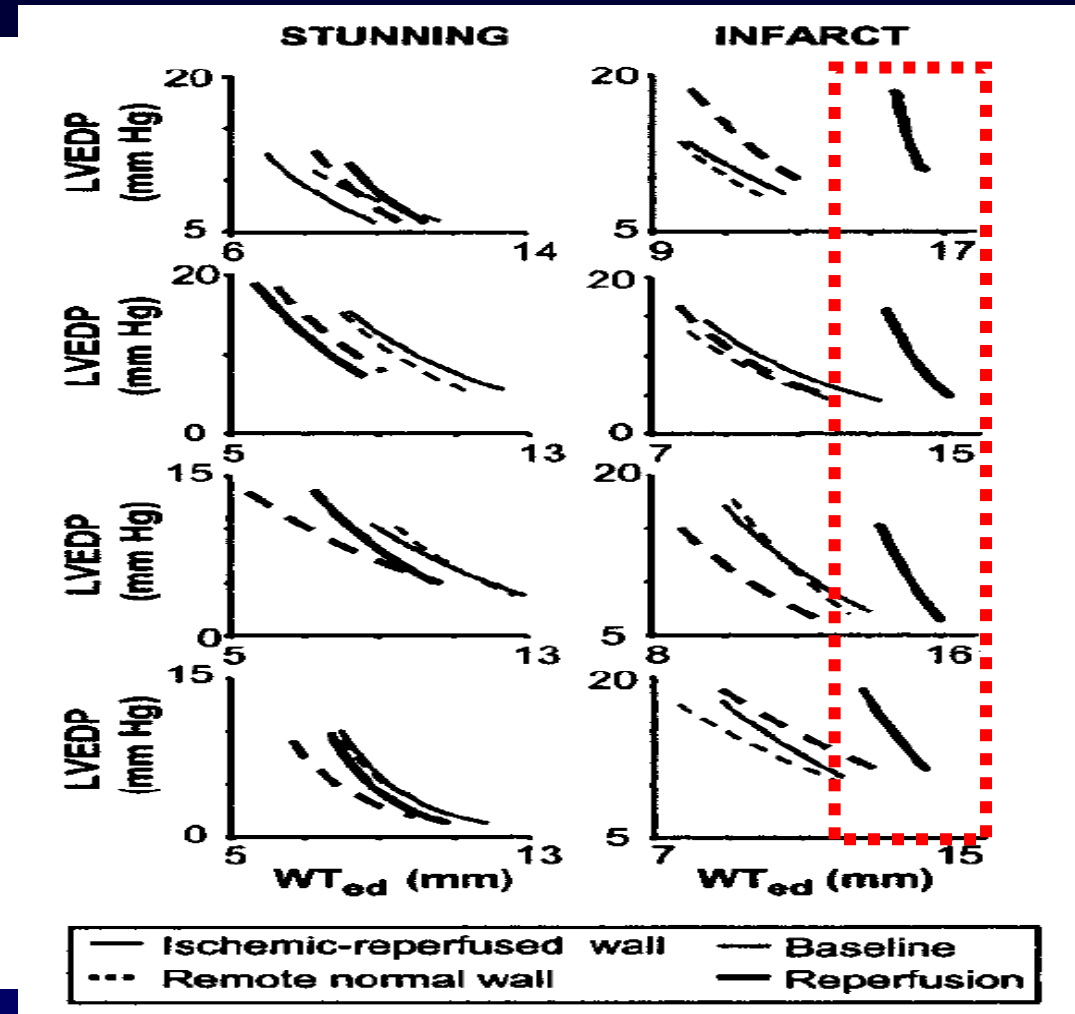
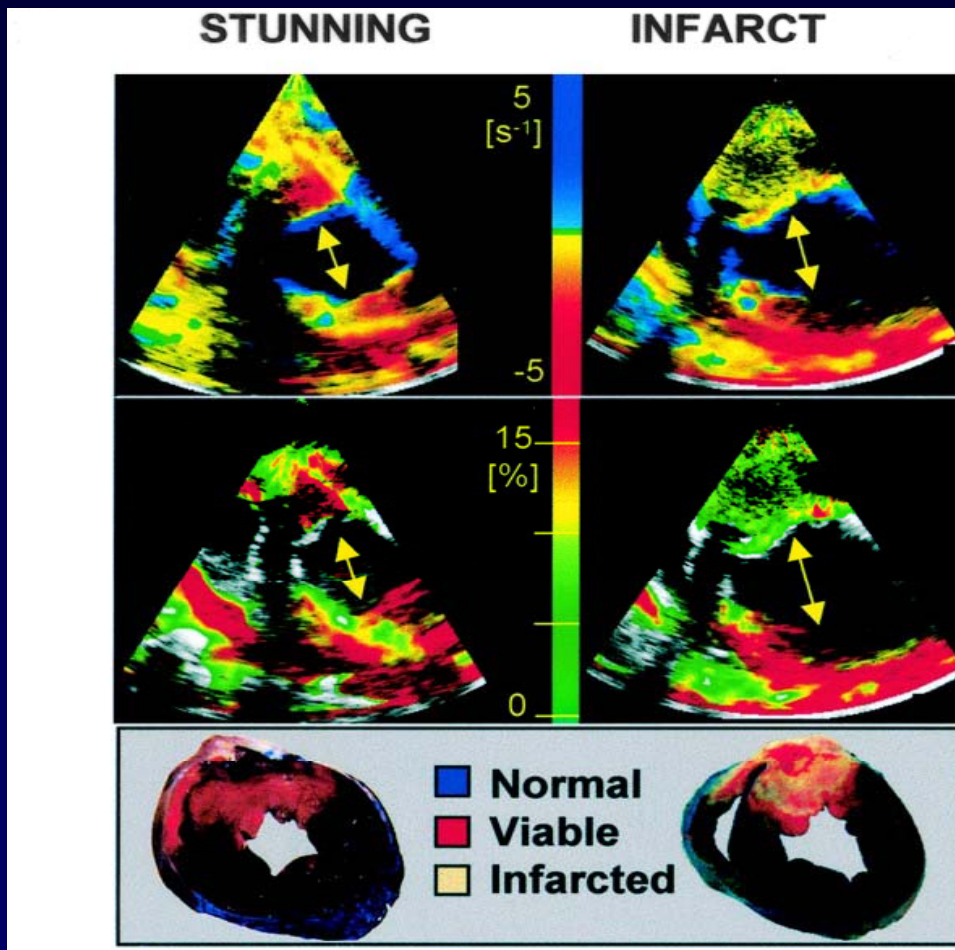


Pislaru et al. *Circulation* 2004;109:2905-10

24 farm pigs, diastolic Pr-WT relationship

Altered Myocardial Stiffness

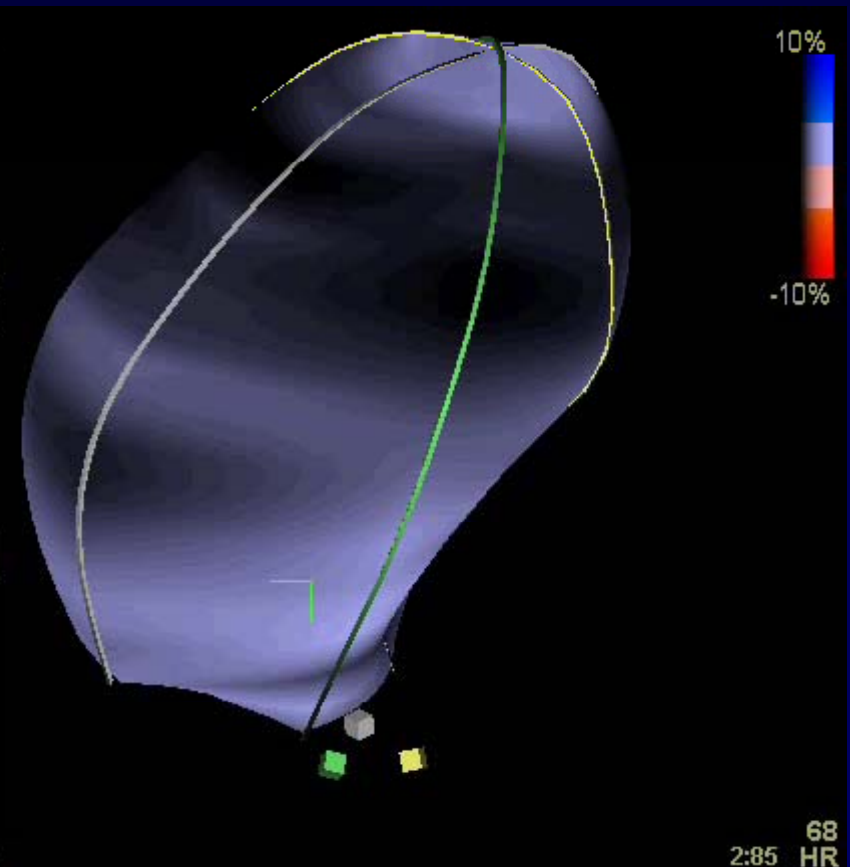
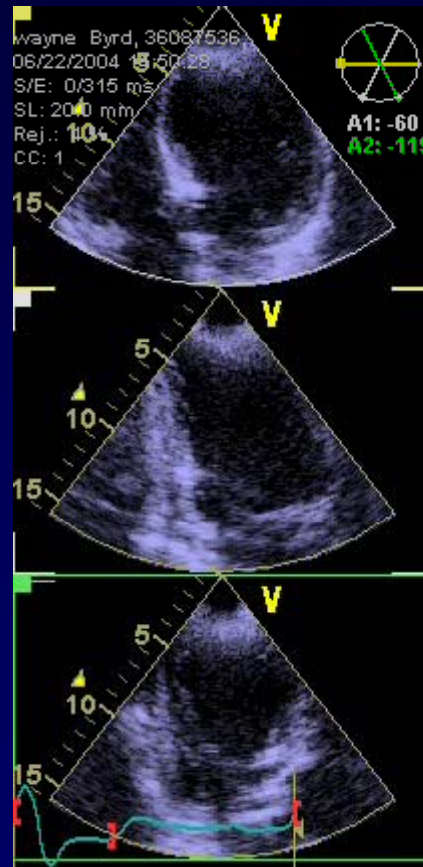
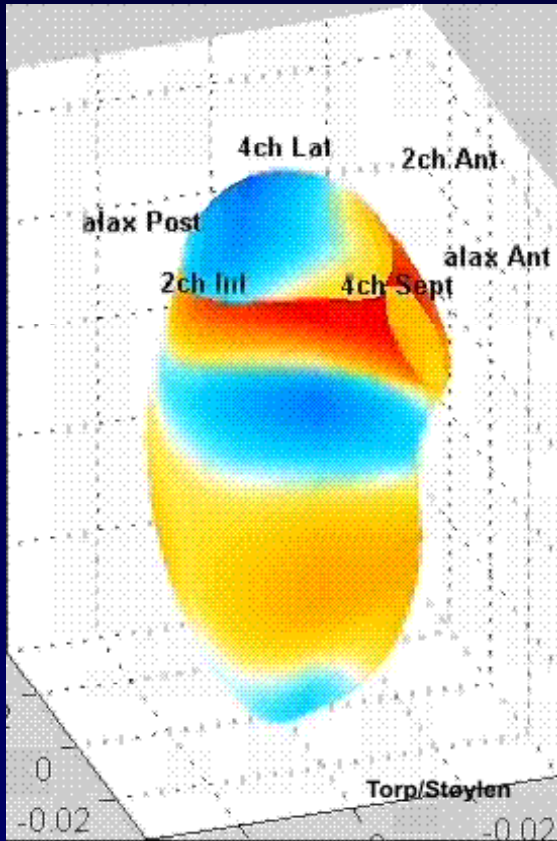
Stunned Vs. Transmural Infarct



Pislaru et al. Circulation 2004;109:2905-10

24 farm pigs, diastolic Pr-WT relationship

3D Strain

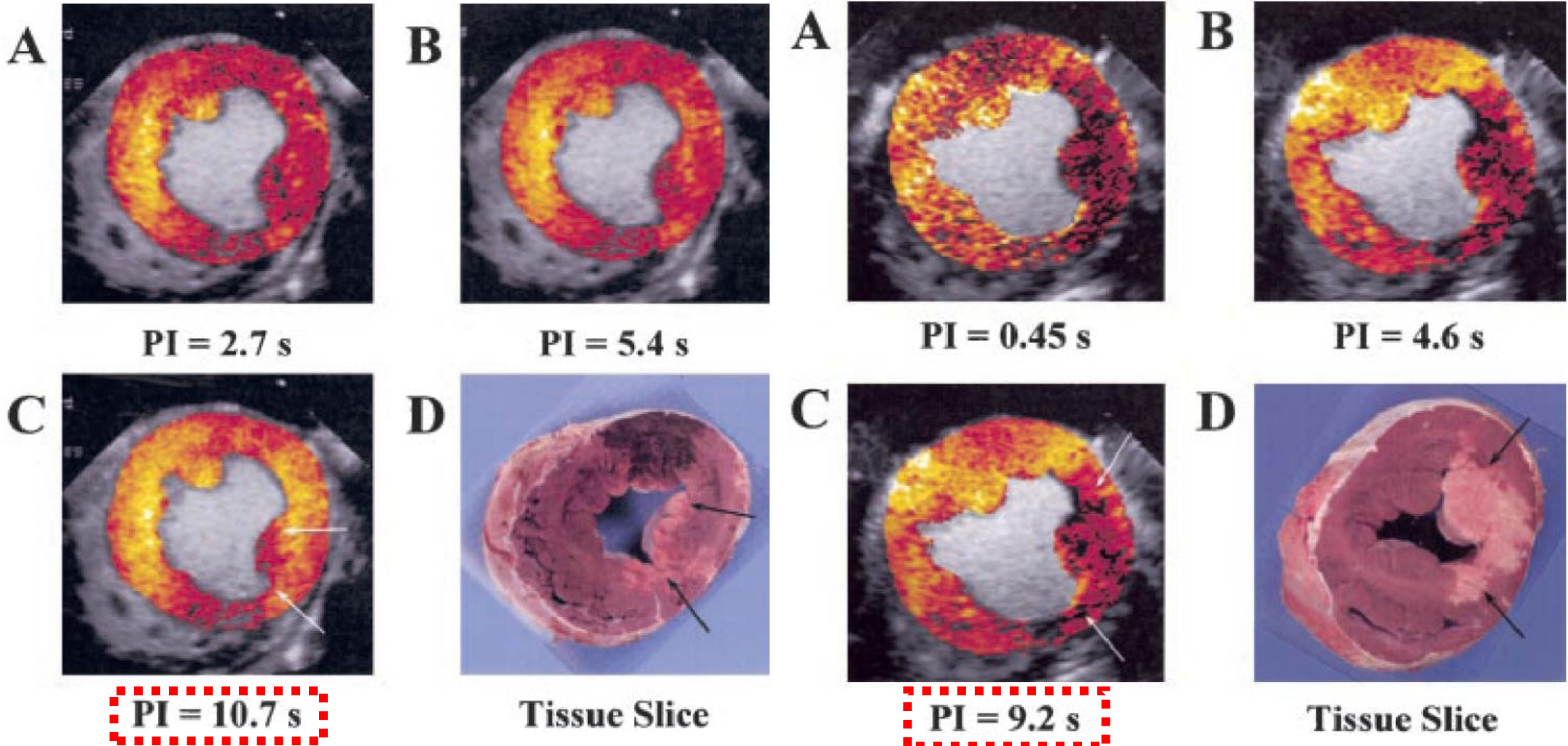


Tissue Characterization in Echo

- ✓ Qualitative – M-mode, 2D
- ✓ Integrated Backscatter (IBS)
- ✓ Tissue Doppler Imaging (TDI)
- ✓ Deformation Imaging (SRI)
- ✓ **Myocardial Contrast Echo (MCE)**

MCE

Perfusion defects after microbubble destruction and the ultimate infarct size (by tissue staining) in a dog undergoing 6 hours of LCX artery occlusion.



Myocardial Viability by MCE Predicts Survival

99 stable patients
low-power MCE
at 7 ± 2 days after AMI

Contrast Defect Index (CDI)

by adding contrast scores

1 = homogenous;

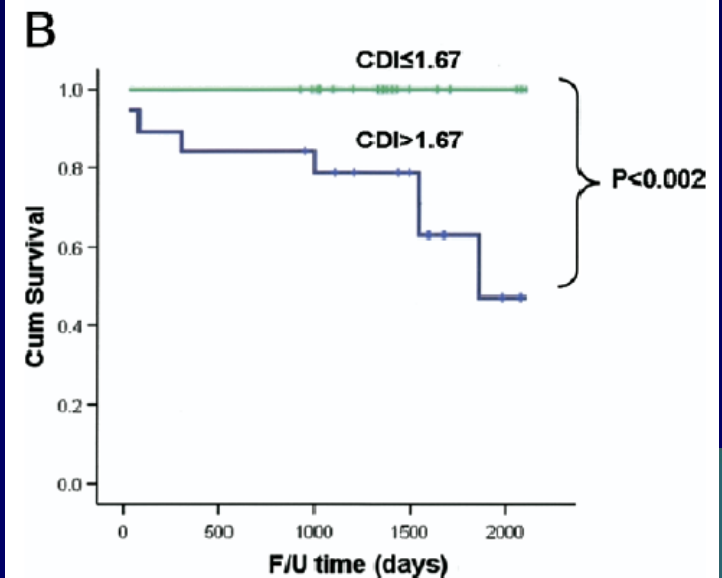
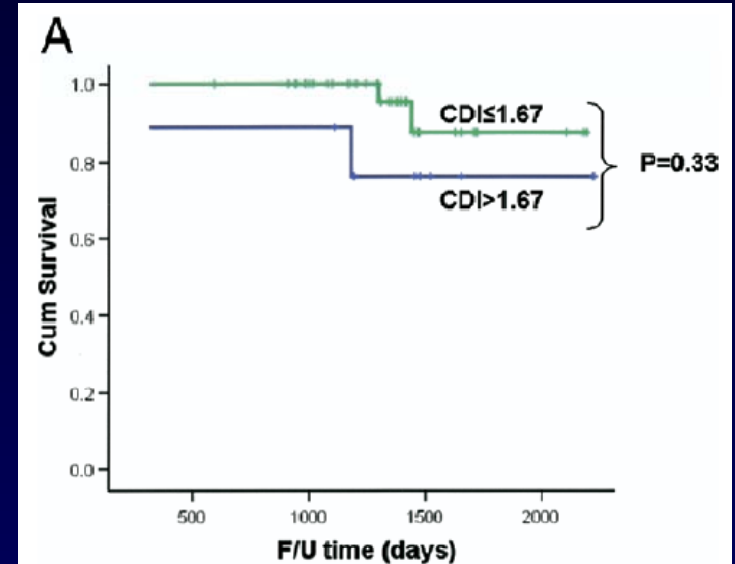
2 = reduced;

3 = minimal/absent opacification

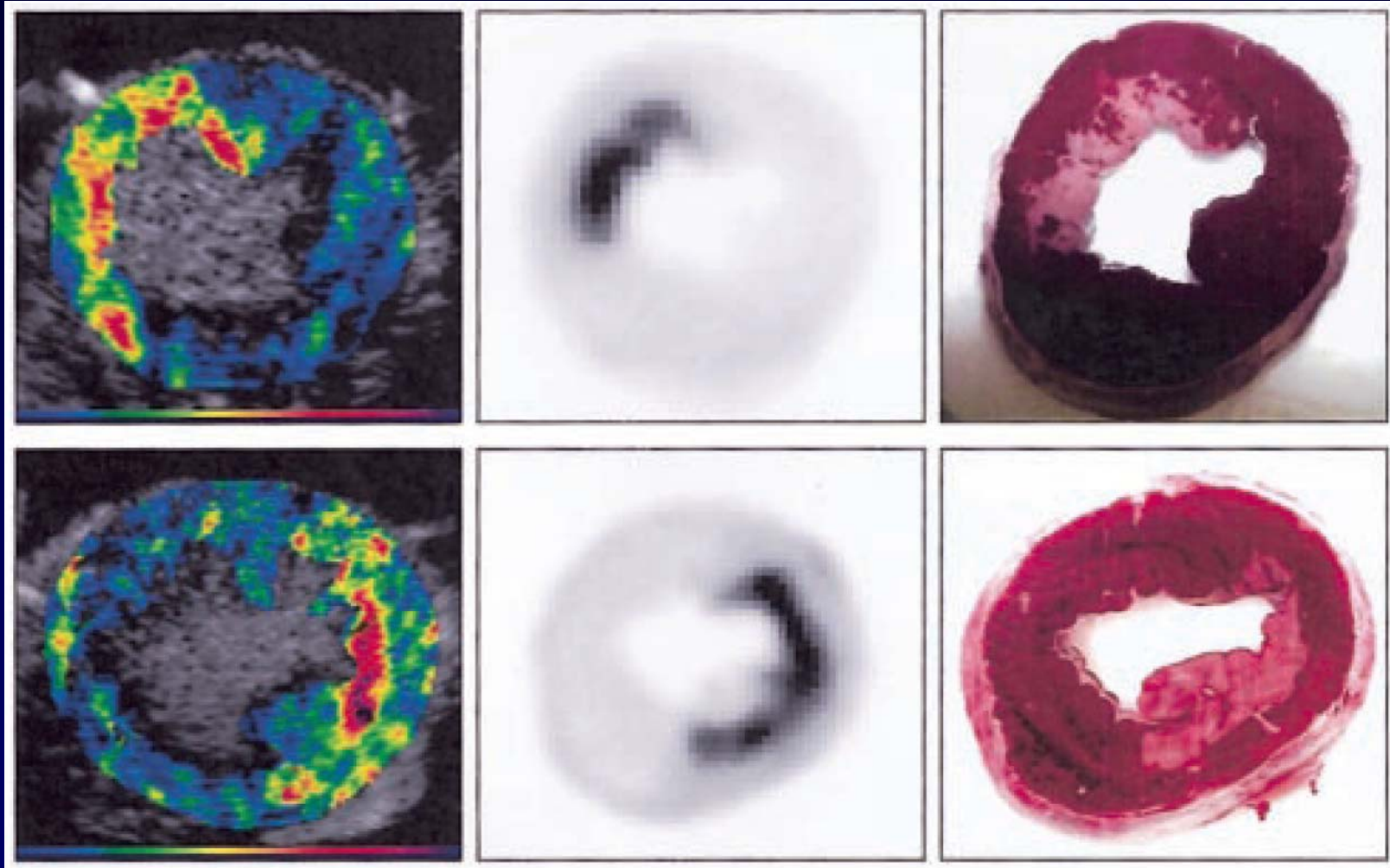
in all 16 LV segments

divided by 16

Dwivedi G, et al. *JACC*. 2007;50:327–34.



MCE with Leukocyte Labeled Imaging



Background-subtracted
Color-coded Contrast U

^{99m}Tc -RP517

triphenyl tetrazolium
chloride-treated

Christiansen JP, et al. *Circulation*. 2002;105:1764–67.

Take Home Message

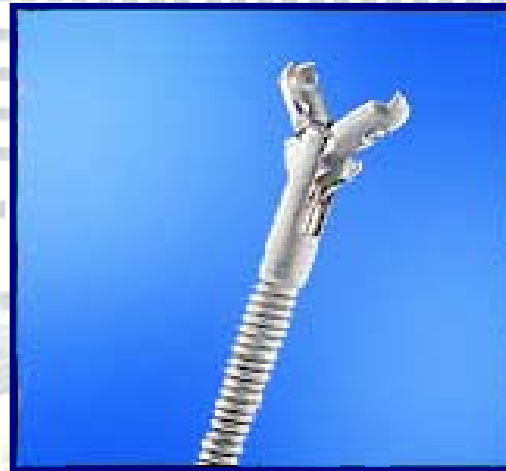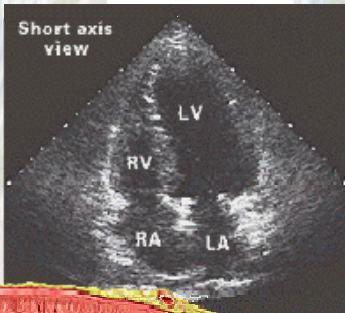
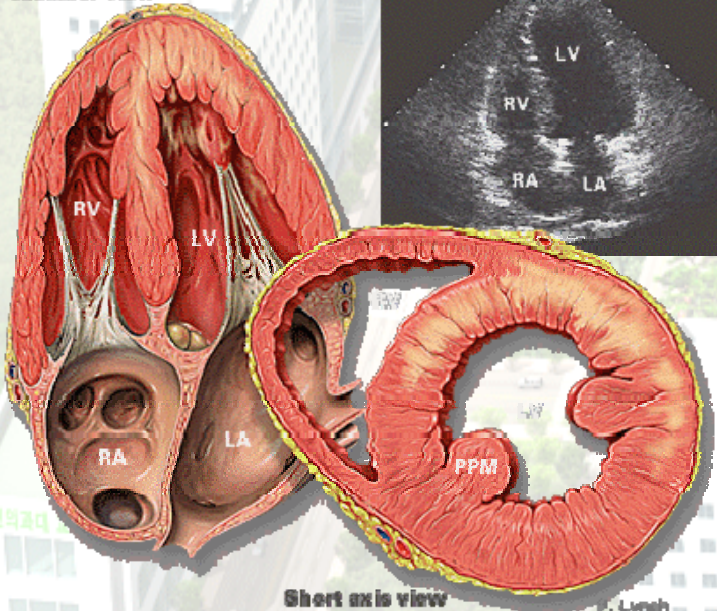
Tissue Characterization in Echo

1. Information on composition and structure of myocardial tissue could be of major importance to better characterize the onset and progression of several myocardial diseases in both clinical and research setting.
2. Its theoretical background is represented by the fact that ultrasound interacts differently with abnormal as compared to normal myocardium.
3. However, an ideal technique is still far from ready for clinical use. Different methods, using both qualitative and quantitative approaches have been suggested during the last decades.

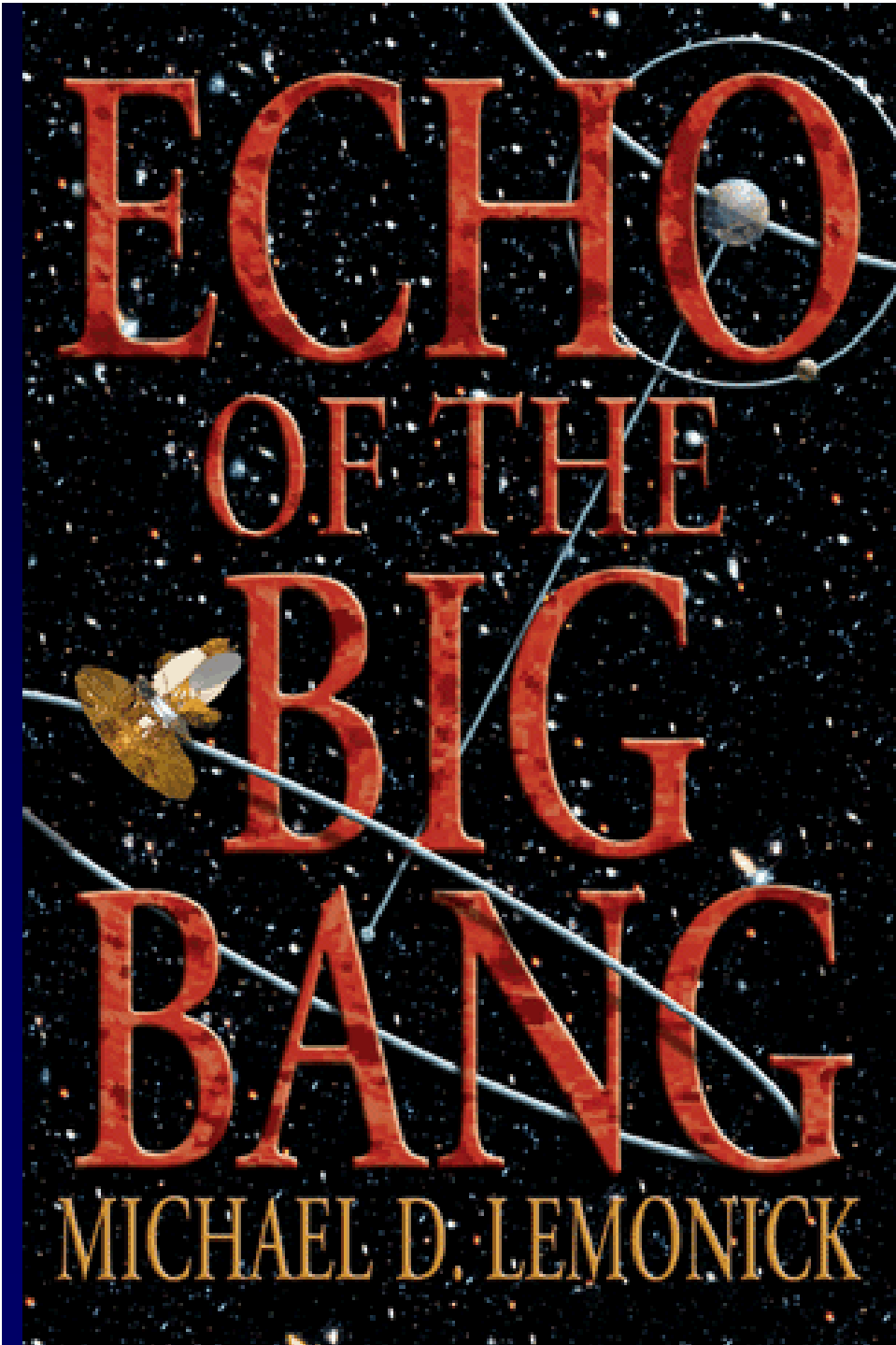
Take Home Message

Tissue Characterization in Echo

Apical four chamber view



- ✓ *Qualitative – M-mode, 2D*
- ✓ *Integrated Backscatter (IBS)*
- ✓ *Tissue Doppler Imaging (TDI)*
- ✓ *Deformation Imaging (SRI)*
- ✓ *Myocardial Contrast Echo (MCE)*



ECHO
OF THE
BIG
BANG
MICHAEL D. LEMONICK

*Thank You for
Your Attention !*

Wook-Jin Chung M.D.

Thank you for your attention !!!

Wook-Jin Chung, MD

heart@gilhospital.com

www.cyworld.com/cardiologist

Cardiology Division, Heart Center
Gachon University Gil Medical Center
Incheon, Korea



A person in a white long-sleeved shirt and a long orange skirt stands in the shallow, foamy waves of the ocean at sunset. The sky is a mix of deep blue and warm orange, with wispy clouds and a few streaks of light. The person is looking out towards the horizon, and their reflection is visible in the water. The overall mood is peaceful and serene.

Thank You for Your Attention !

Wook-Jin Chung M.D.



Relaxation

