



Problem Oriented Echo-Decision

Chest Pain

Heart Center, Konyang University Hospital

Ki-Young Kim, M.D. PhD.

**ACCF/ASE/ACEP/ASNC/SCAI/SCCT/SCMR APPROPRIATENESS CRITERIA**

## **ACCF/ASE/ACEP/ASNC/SCAI/SCCT/SCMR 2007 Appropriateness Criteria for Transthoracic and Transesophageal Echocardiography\***

A Report of the American College of Cardiology Foundation Quality Strategic Directions Committee Appropriateness Criteria Working Group, American Society of Echocardiography, American College of Emergency Physicians, American Society of Nuclear Cardiology, Society for Cardiovascular Angiography and Interventions, Society of Cardiovascular Computed Tomography, and the Society for Cardiovascular Magnetic Resonance  
*Endorsed by the American College of Chest Physicians and the Society of Critical Care Medicine*

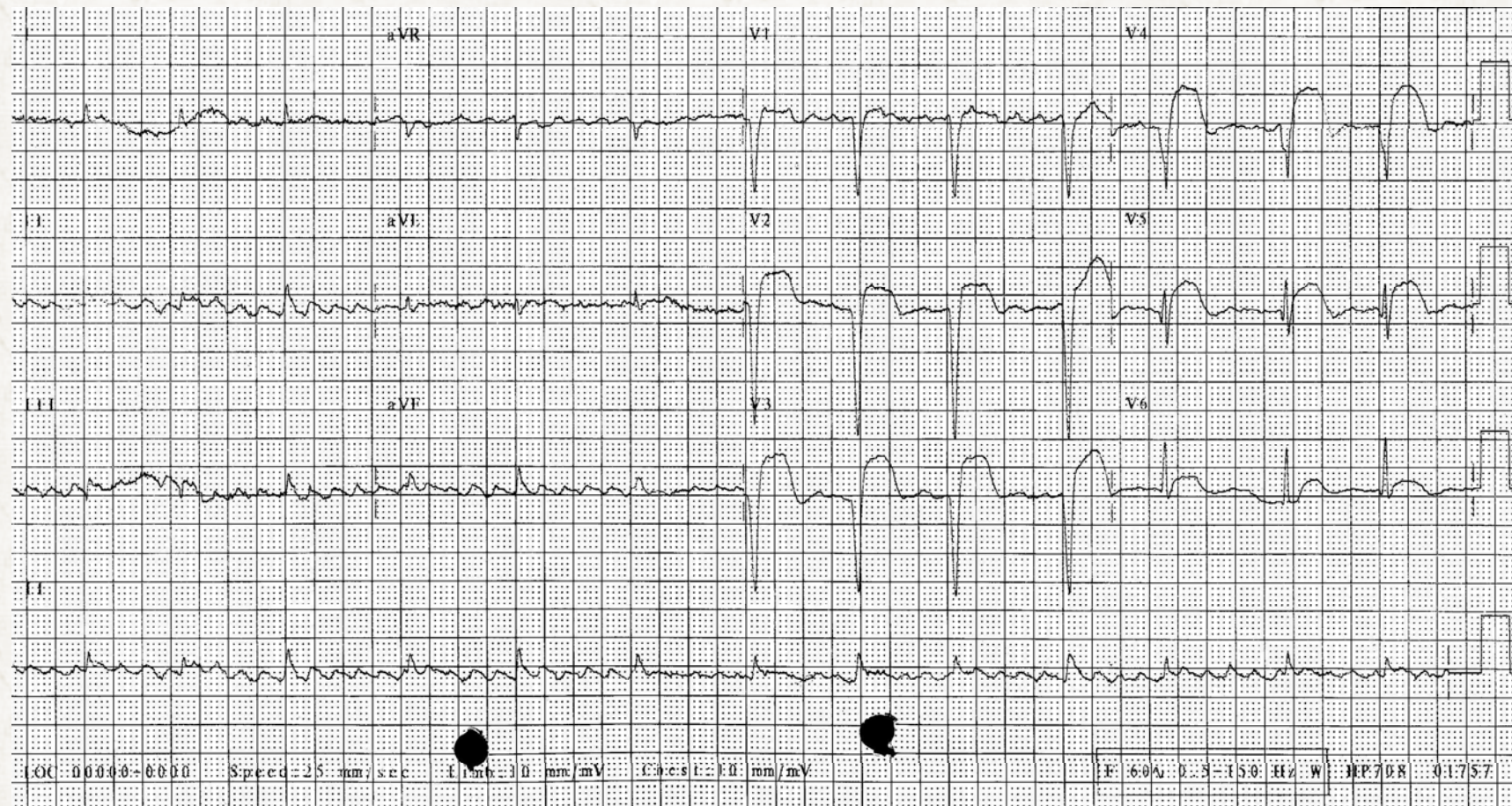
**Table 2. Cardiovascular Evaluation in an Acute Setting**

Indication		Appropriateness Score (1-9)
<b>Hypotension or Hemodynamic Instability</b>		
11.	Evaluation of hypotension or hemodynamic instability of uncertain or suspected cardiac etiology	A (9)
<b>Myocardial Ischemia/Infarction</b>		
12.	Evaluation of acute chest pain with suspected myocardial ischemia in patients with nondiagnostic laboratory markers and ECG and in whom a resting echocardiogram can be performed during pain	A (8)
13.	Evaluation of suspected complication of myocardial ischemia/infarction, including but not limited to acute MR, hypoxemia, abnormal chest X-ray, VSD, free-wall rupture/tamponade, shock, right ventricular involvement, heart failure, or thrombus	A (9)
<b>Respiratory Failure</b>		
14.	Evaluation of respiratory failure with suspected cardiac etiology	A (8)
<b>Pulmonary Embolism</b>		
15.	Initial evaluation of patient with suspected pulmonary embolism in order to establish diagnosis	I (3)
16.	Evaluation of patient with known or suspected acute pulmonary embolism to guide therapy (i.e., thrombectomy and thrombolytics)	A (8)

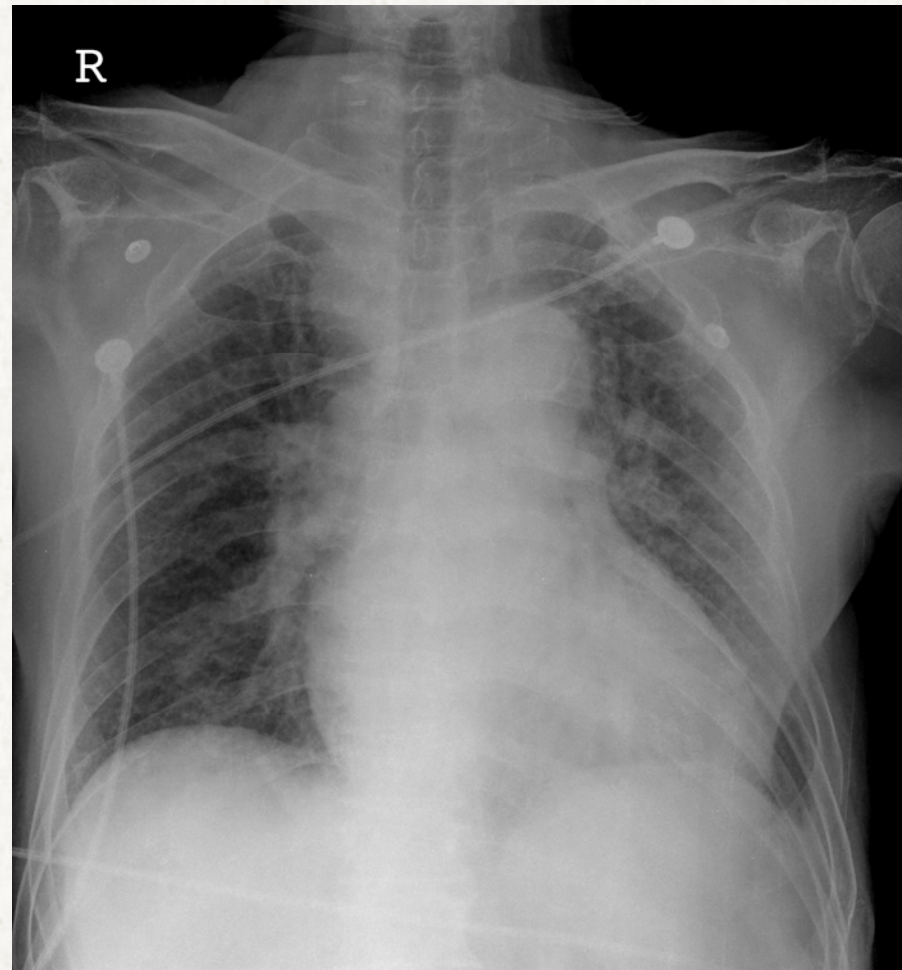# Case 1

- M/83
- C/C: dyspnea for 3 day
- P/I: chest pain 4 days ago (severe, resting onset, squeezing, 1 hr, radiating to Lt. arm)
- DM(+), HTN(+), Dyslipidemia(+), Smoker(-)
- BP 100/60 mmHg PR 105/min RR 25/min
- CK-MB 4.5 ng/mL, **Tnl 14.43**

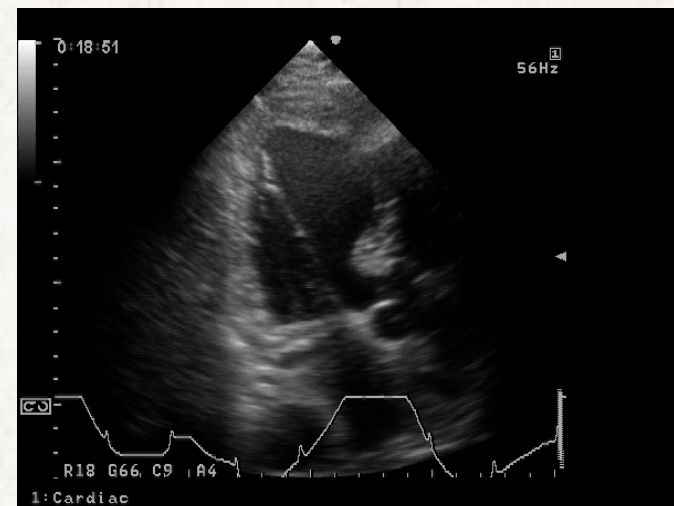
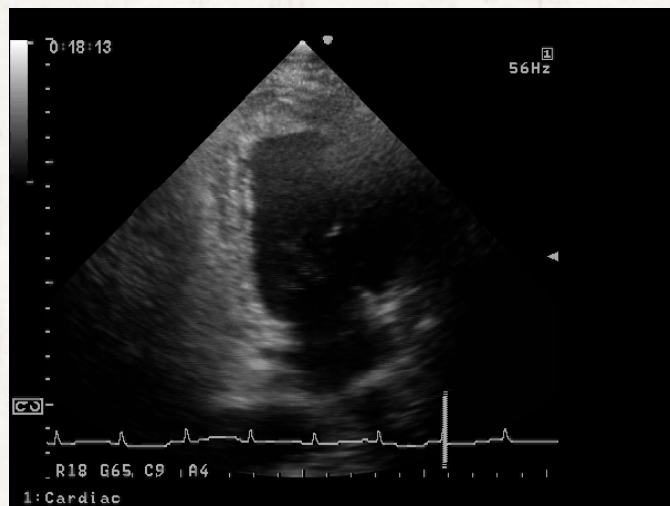
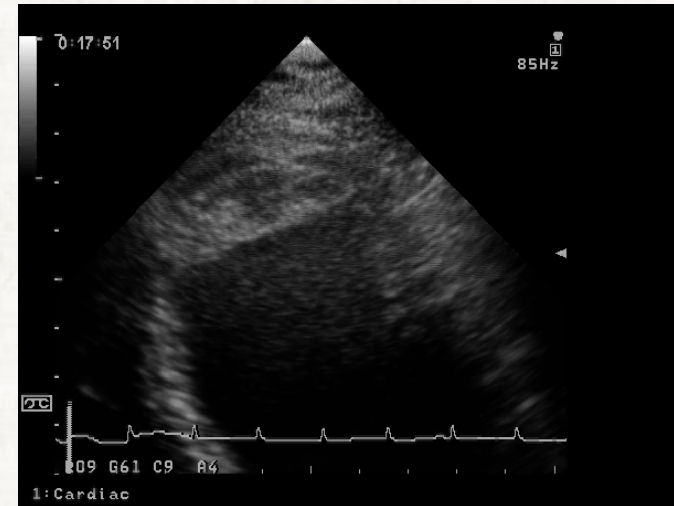
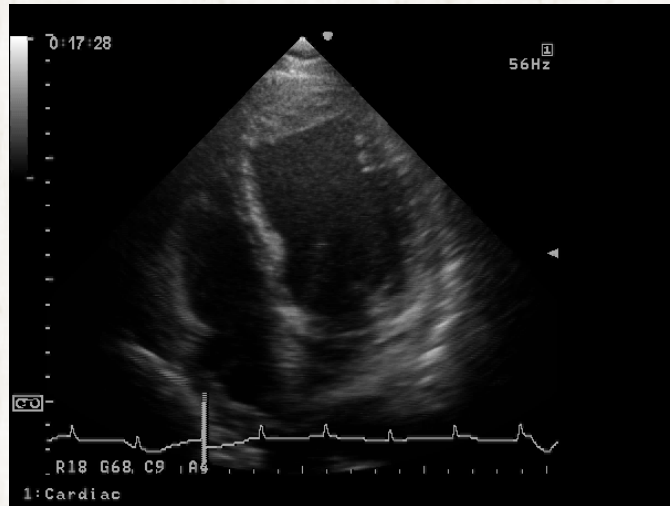
# ECG



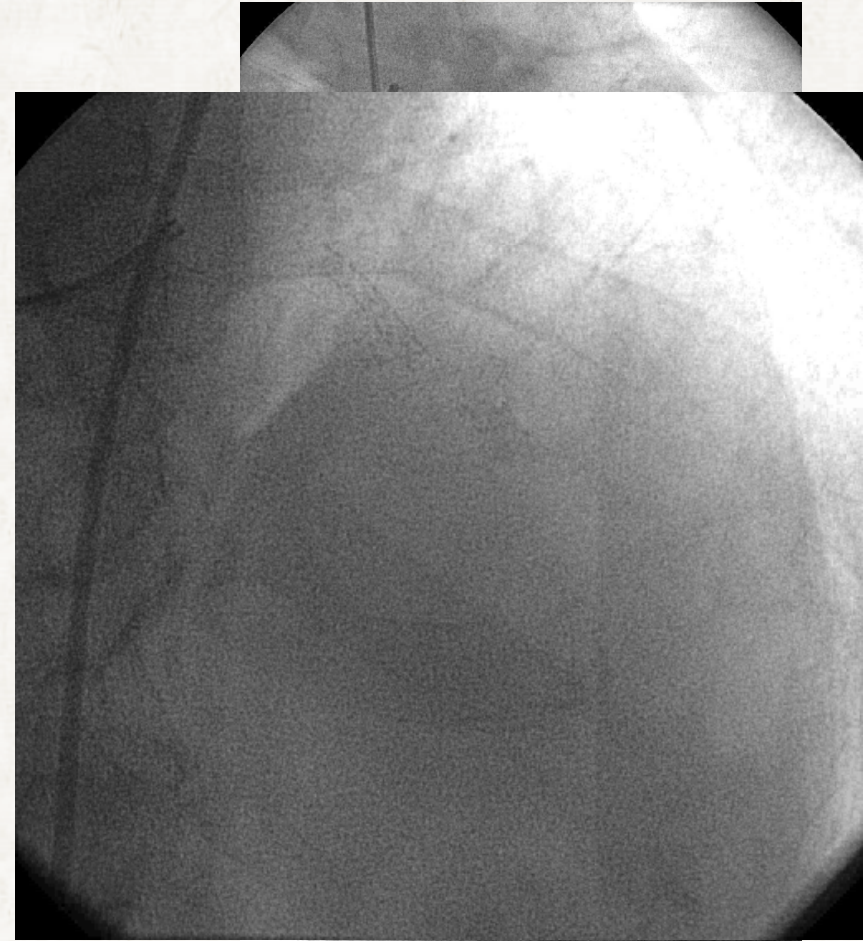
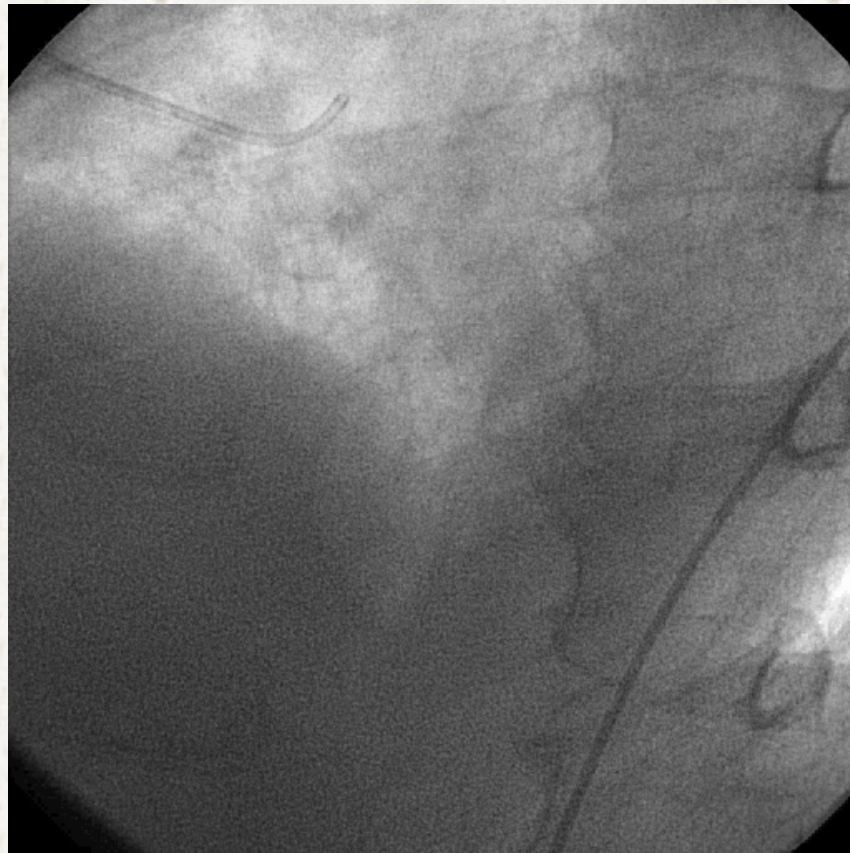
# CXR



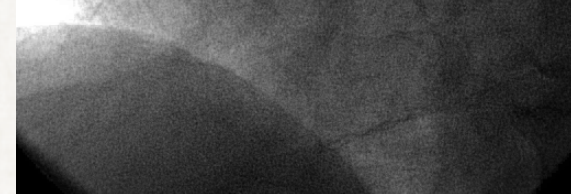
# Echo



# CAG & PCI



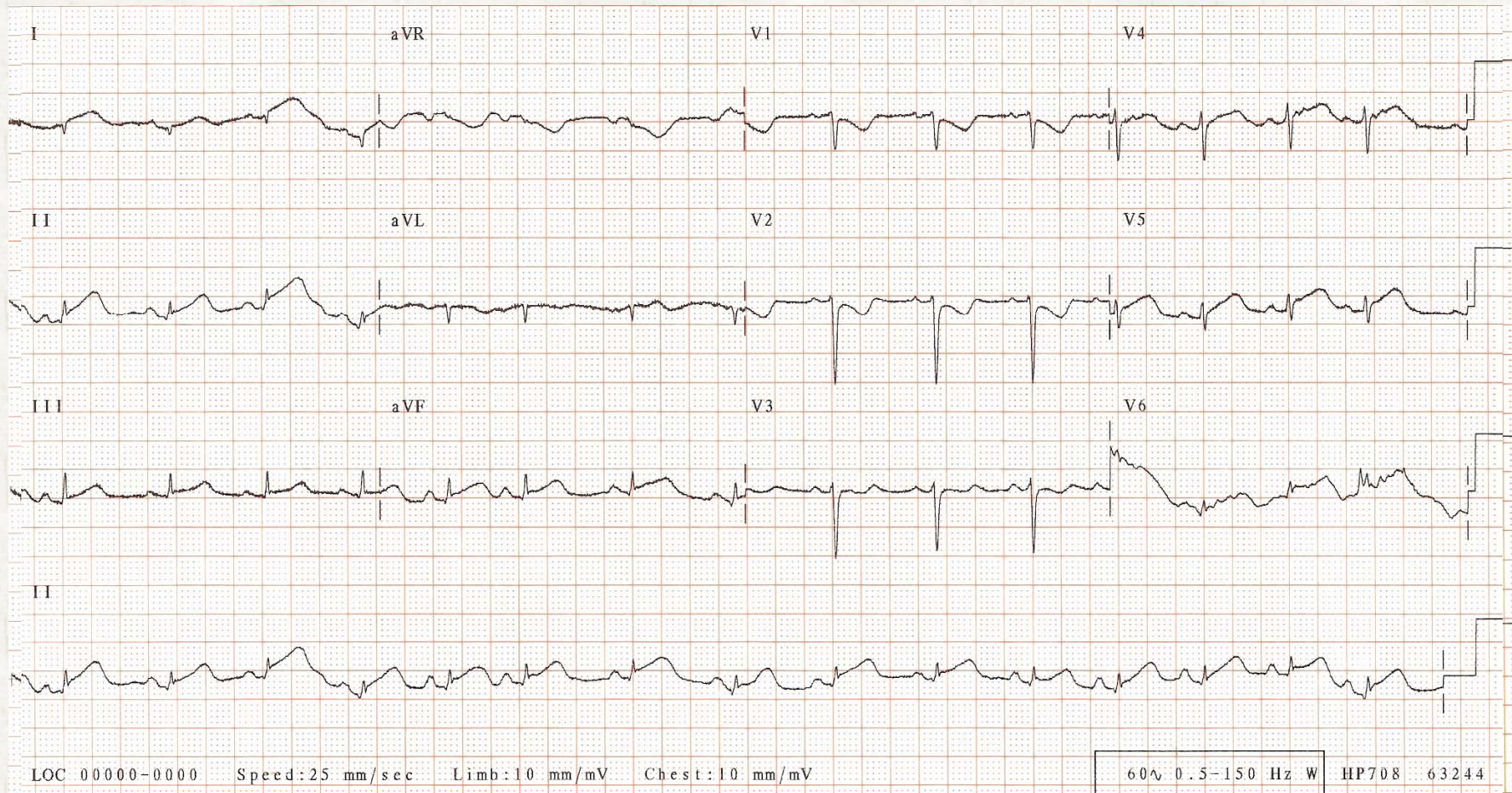
**STEMI with LV thrombi**



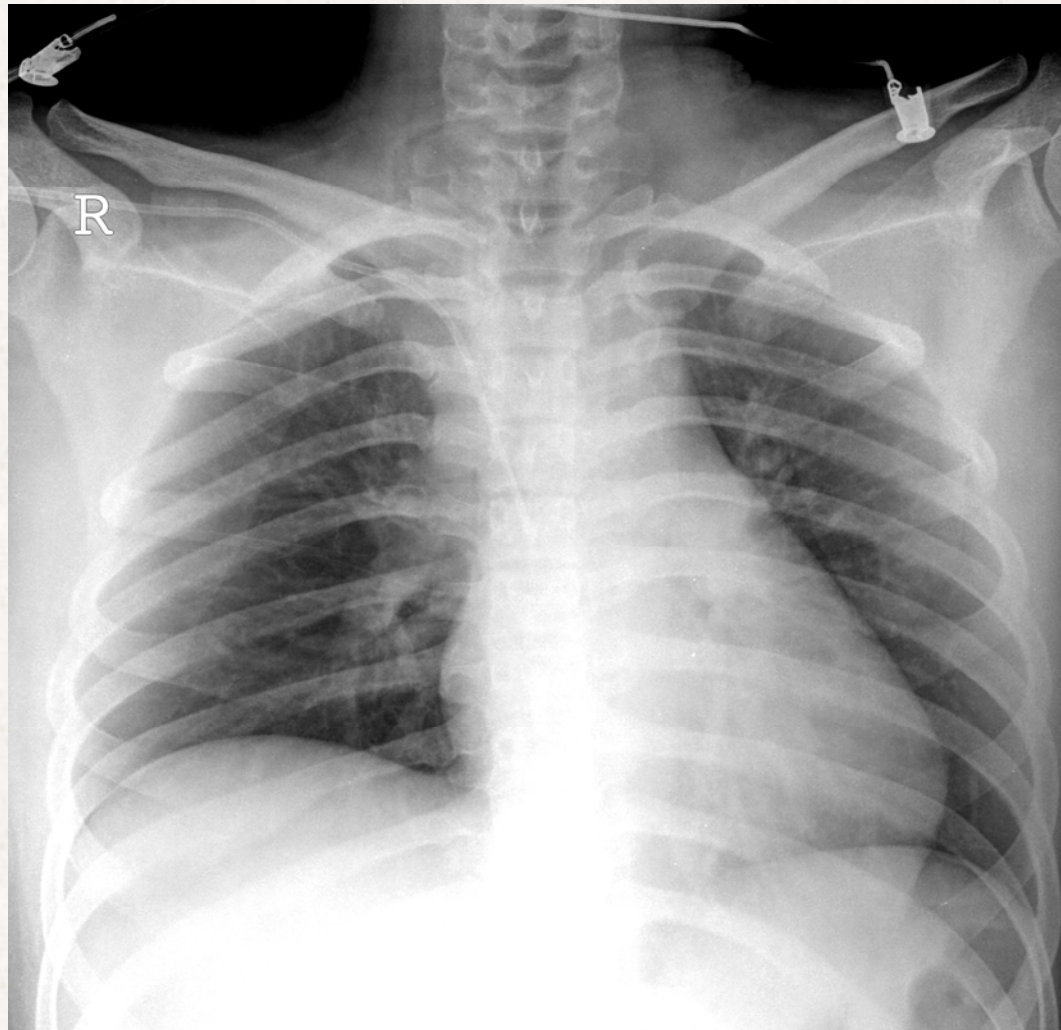
## Case 2

- F/27
- C/C: chest pain (stabbing, aggravated by deep breathing)
- P/I: febrile sensation for 1 wk  
parotid tenderness and enlargement
- DM(-), HTN(-), Dyslipidemia(-), Smoker(-)
- BP 120/70 mmHg PR 80/min BT 37.8°C
- CK-MB 53.8 ng/mL, Tnl 10.4 ng/mL

# ECG-Initial



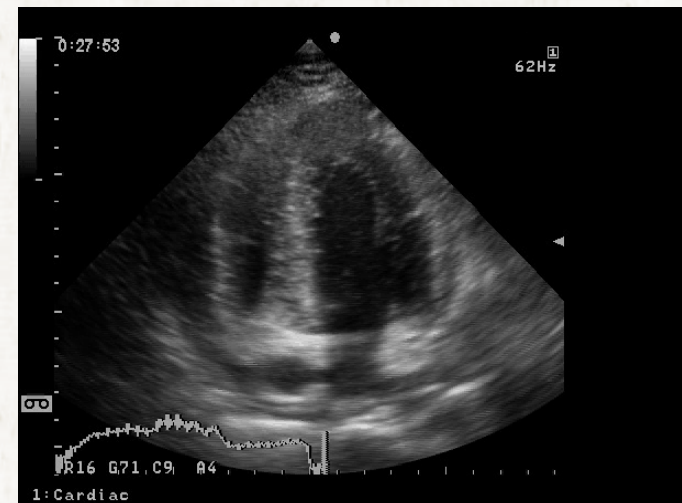
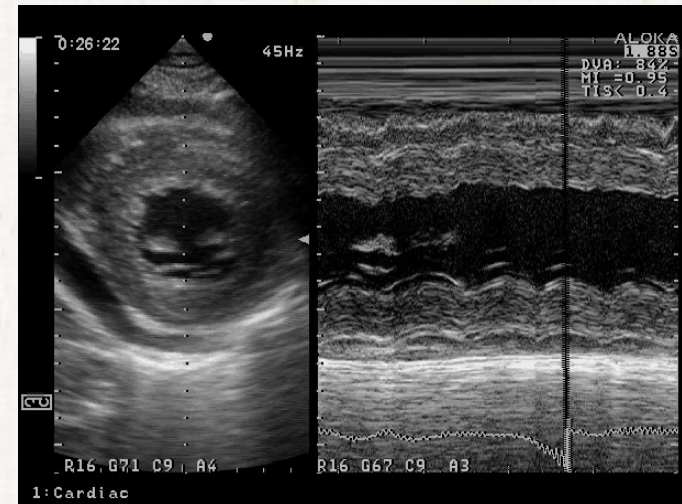
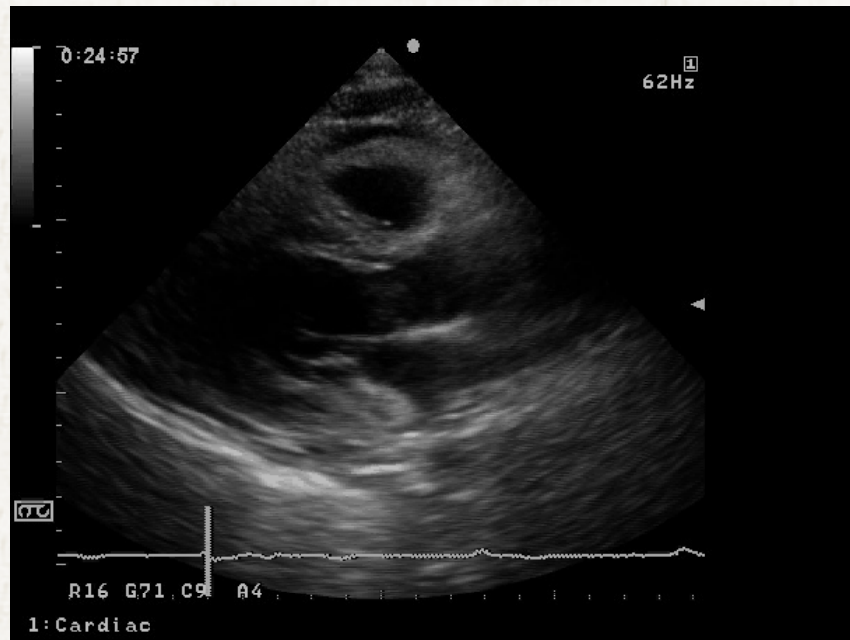
# CXR



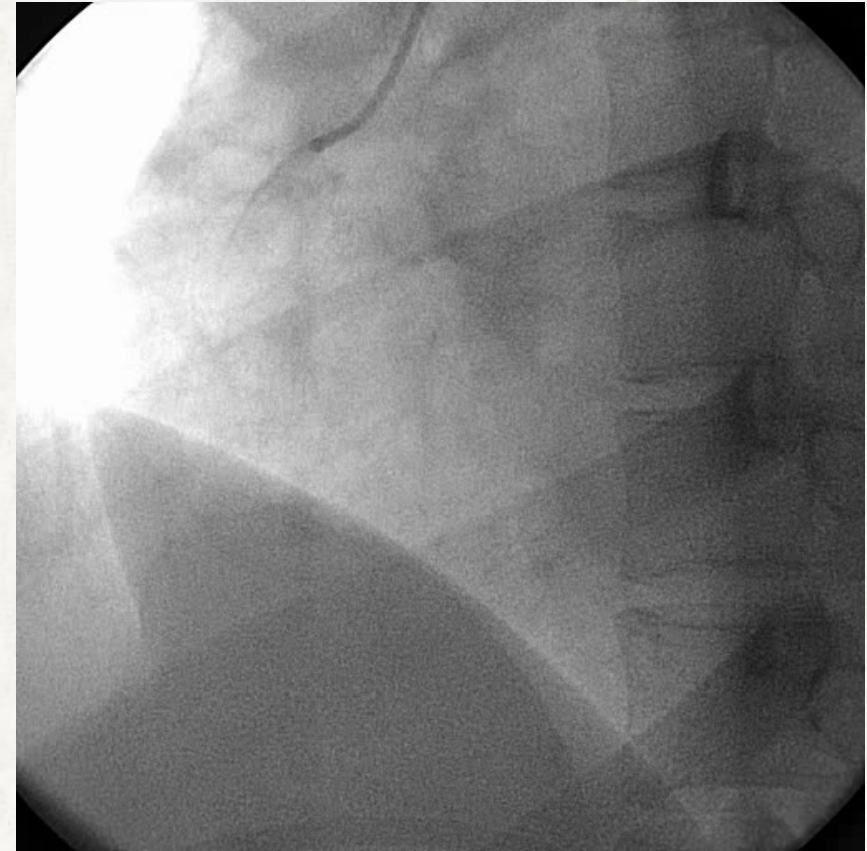
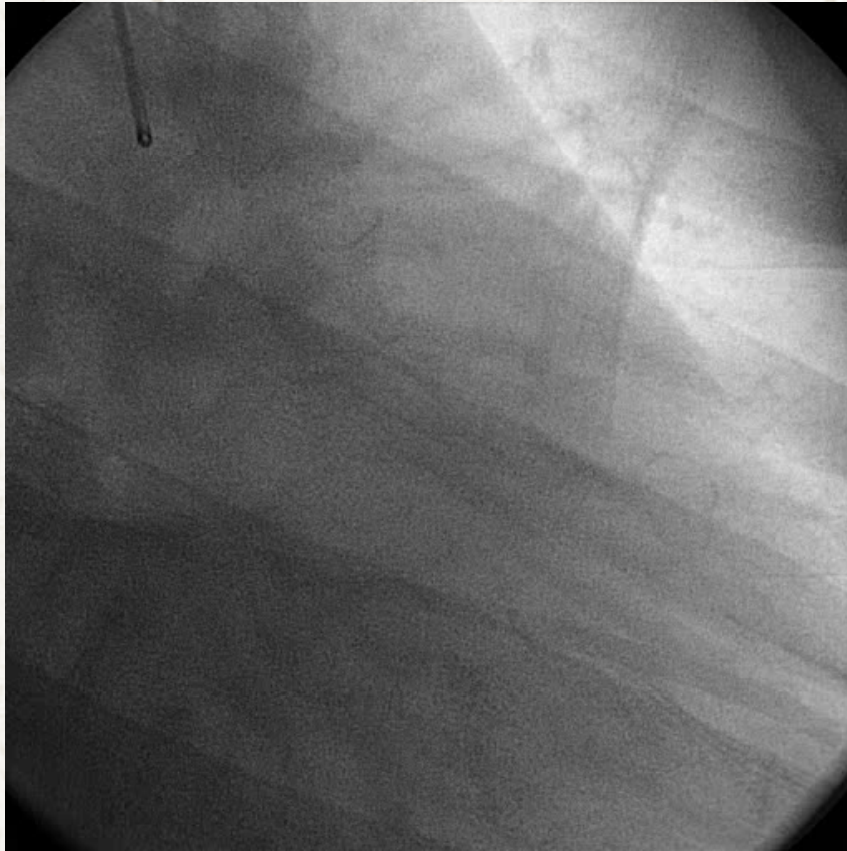# Next Procedure?

- 1. Thrombolytic therapy
- 2. Coronary angiography and primary PCI
- 3. Echo
- 4. Cardiac CT
- 5. MRI

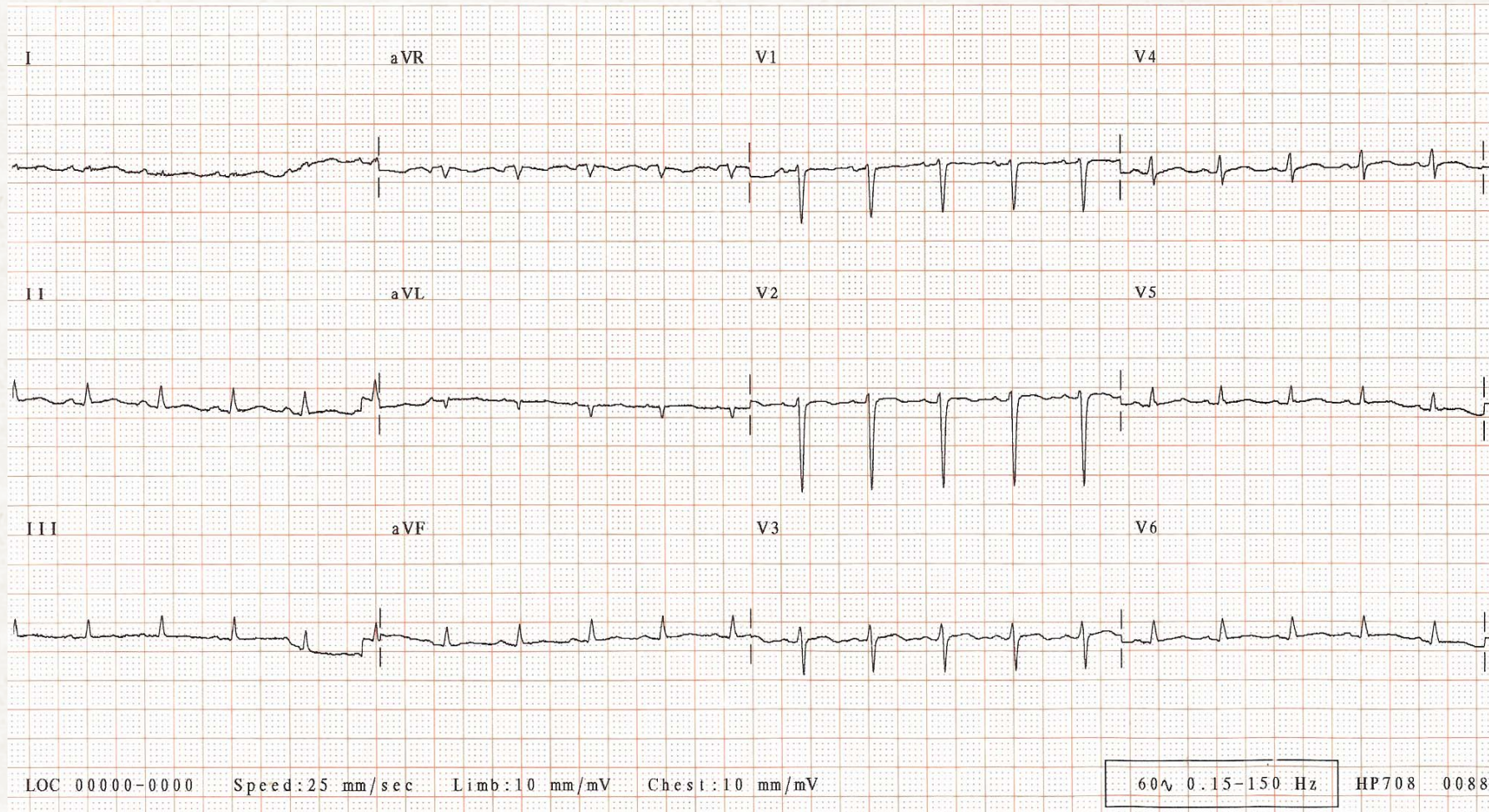
# Echo



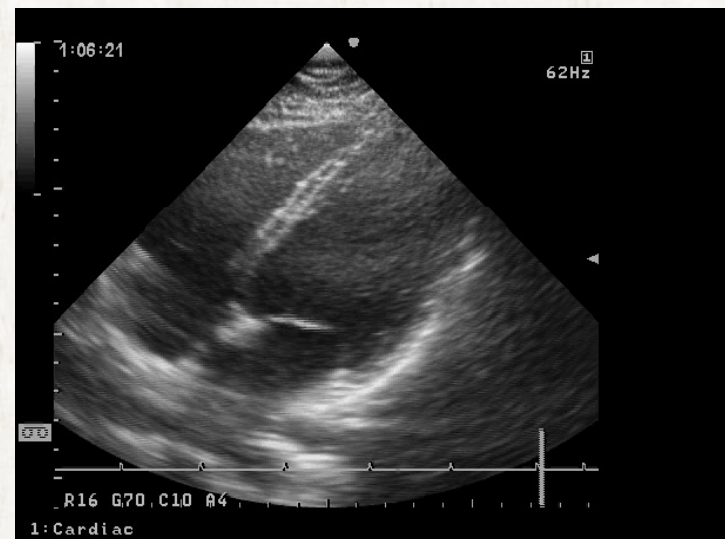
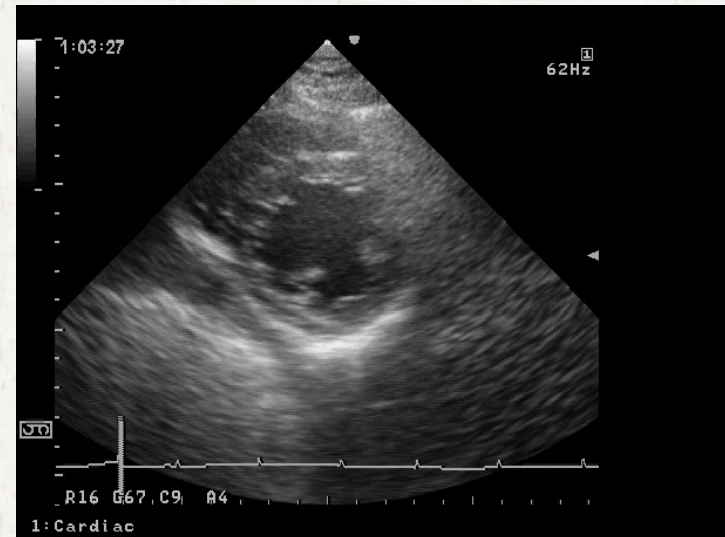
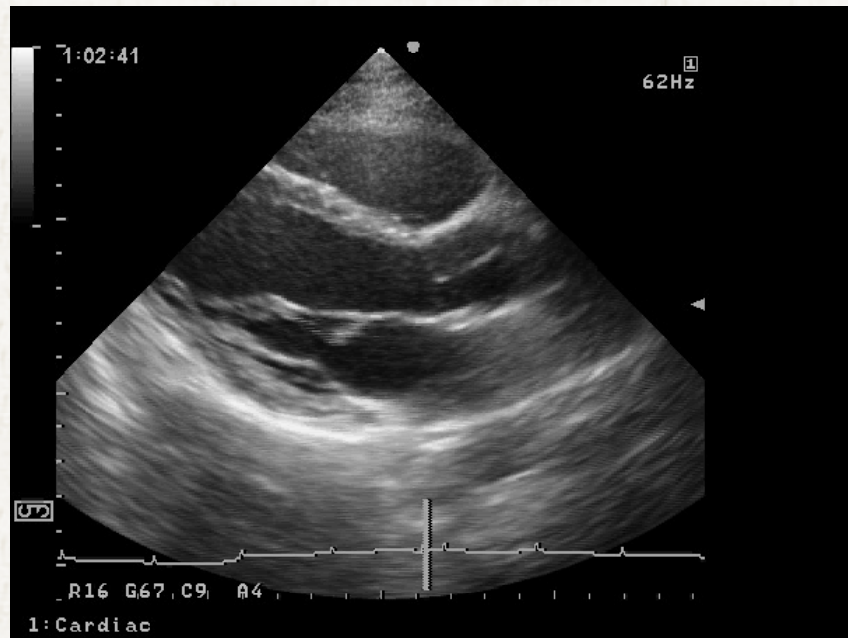
# CAG



# ECG- 1 Month FU



# Echo- 1 Month FU

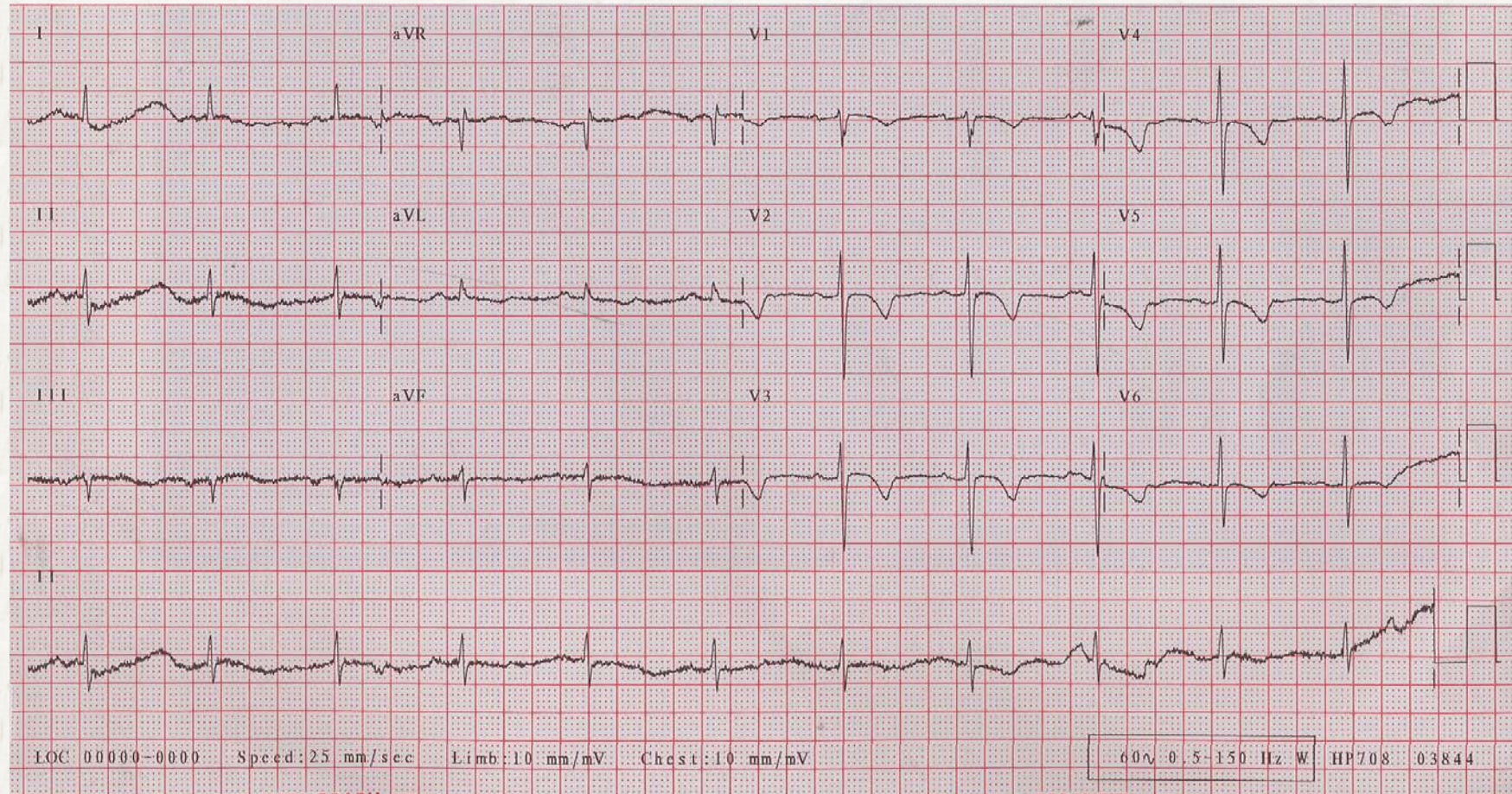


**Mumps Myopericarditis**

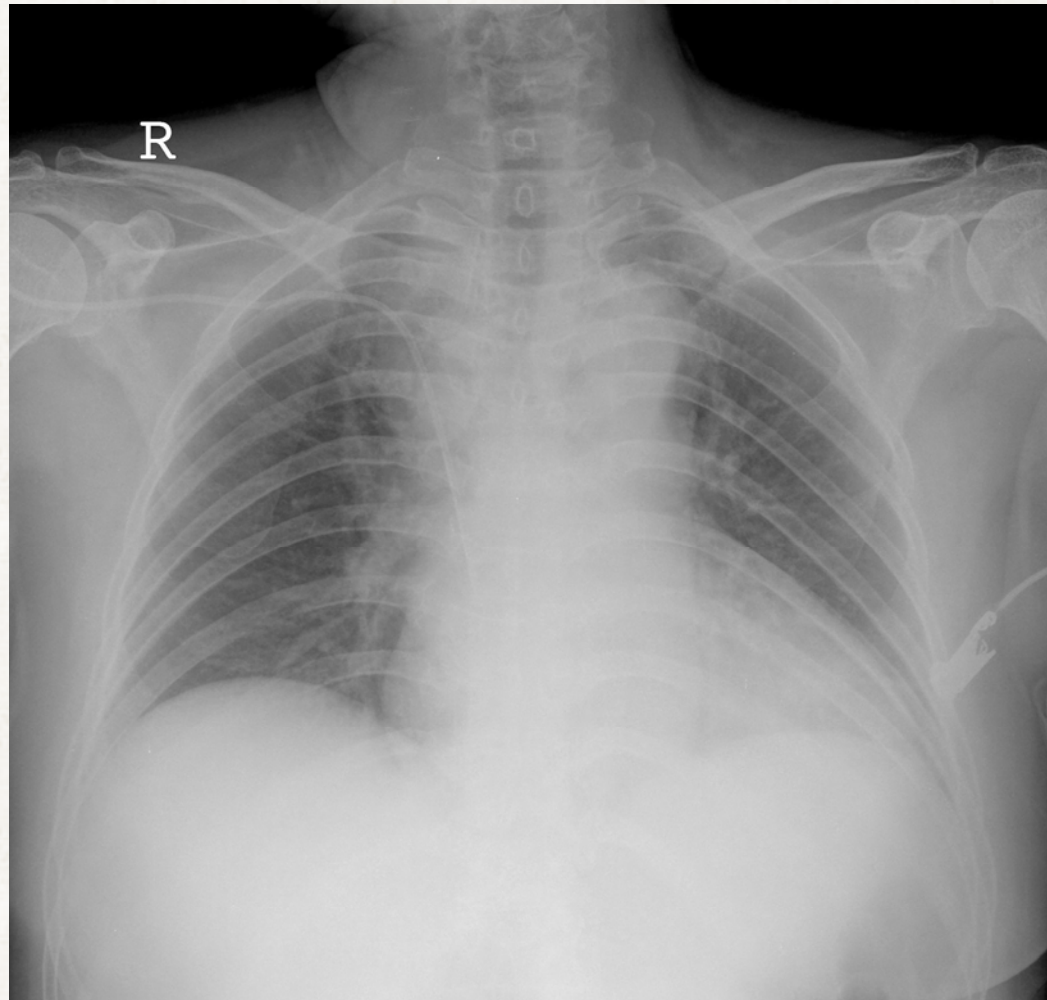
## Case 3

- F/56
- C/C: chest pain for 1 hr (sudden onset, tearing, radiating to back)
- DM(-), HTN(+), Dyslipidemia(-), Smoker(-)
- BP 100/60 mmHg PR 80/min RR 20/min
- CK-MB 7.4 ng/mL, Tnl <0.01 ng/mL

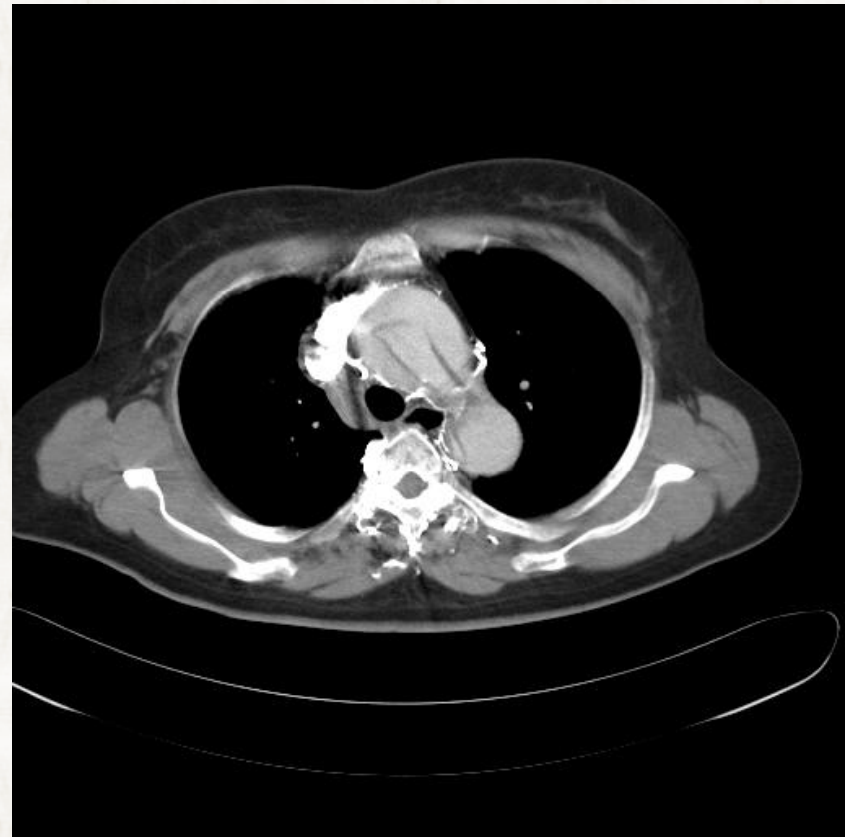
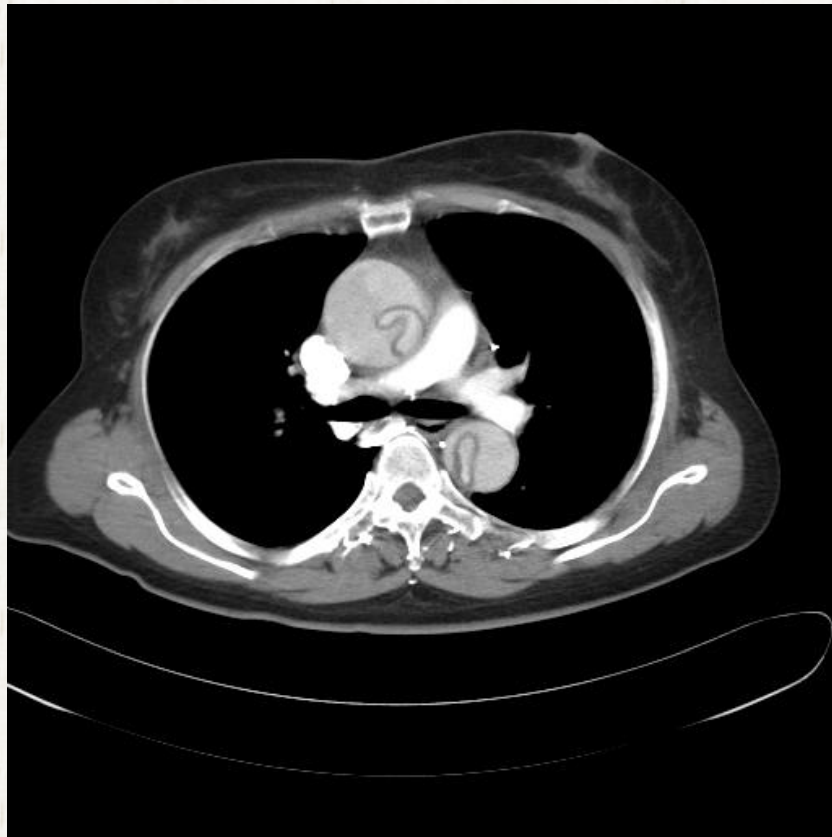
# ECG



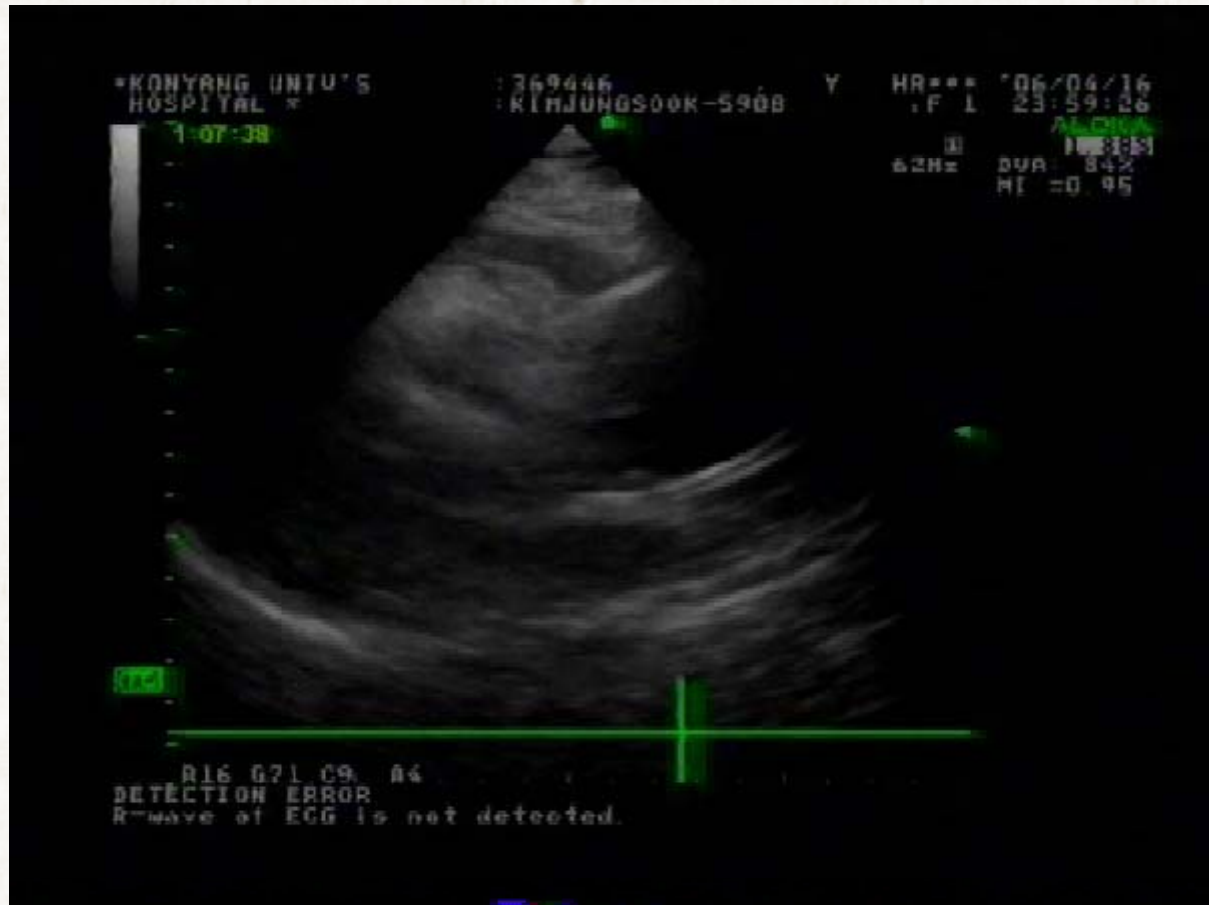# CXR



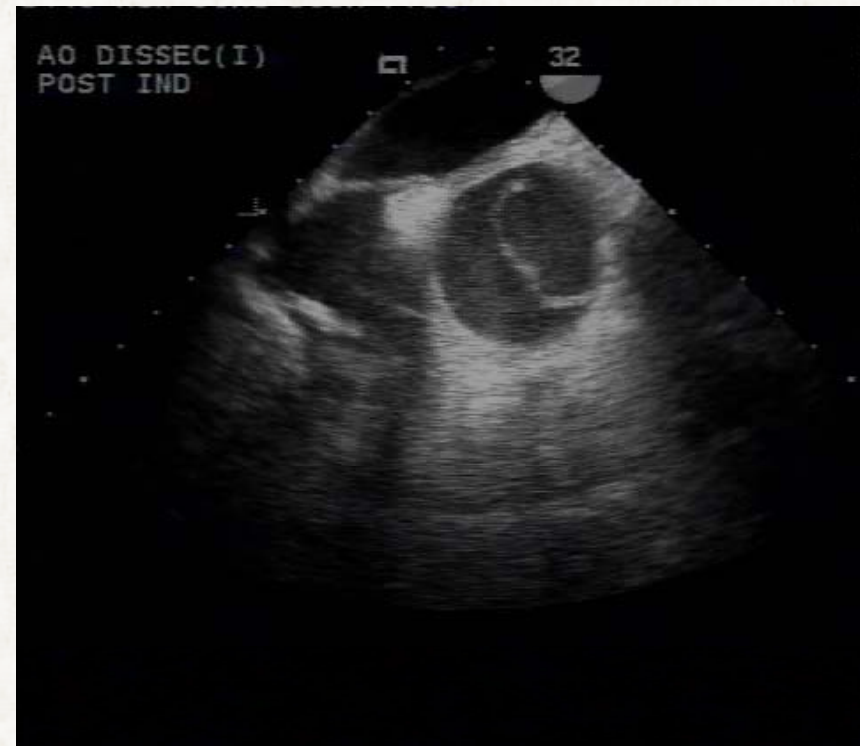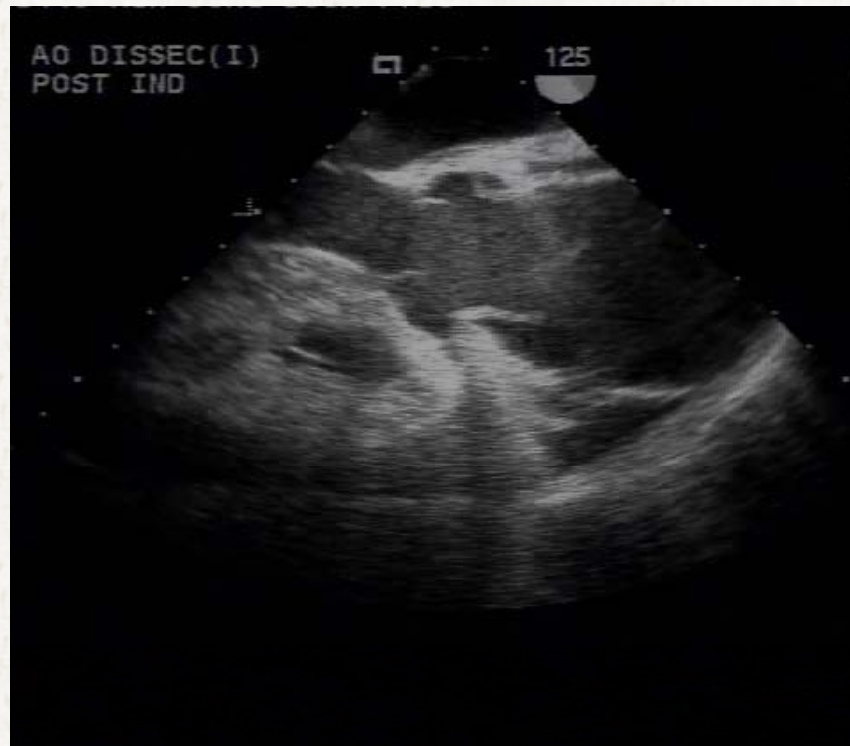# CT



# Echo



# Intra-op TEE

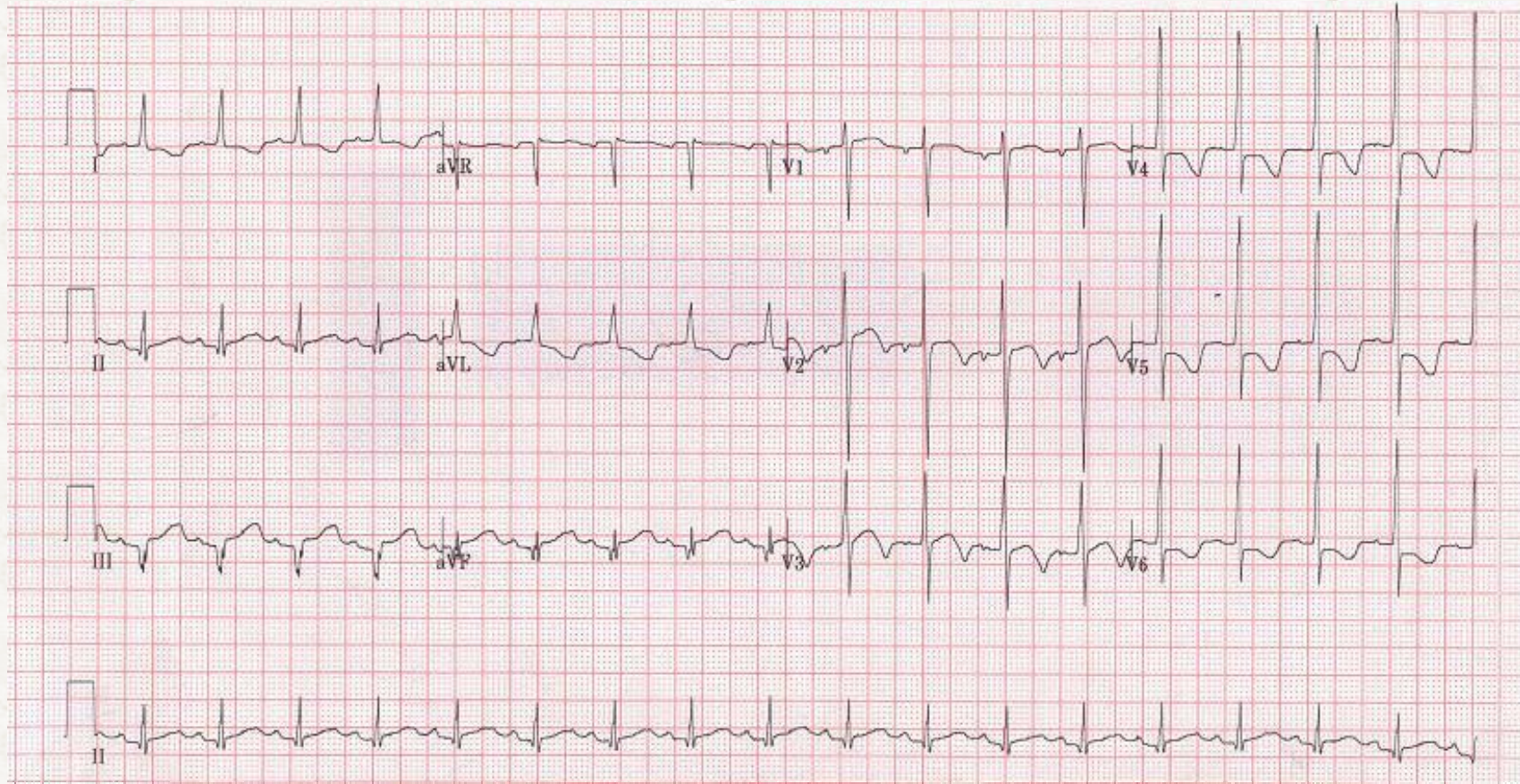


**Aortic Dissection-Type I**

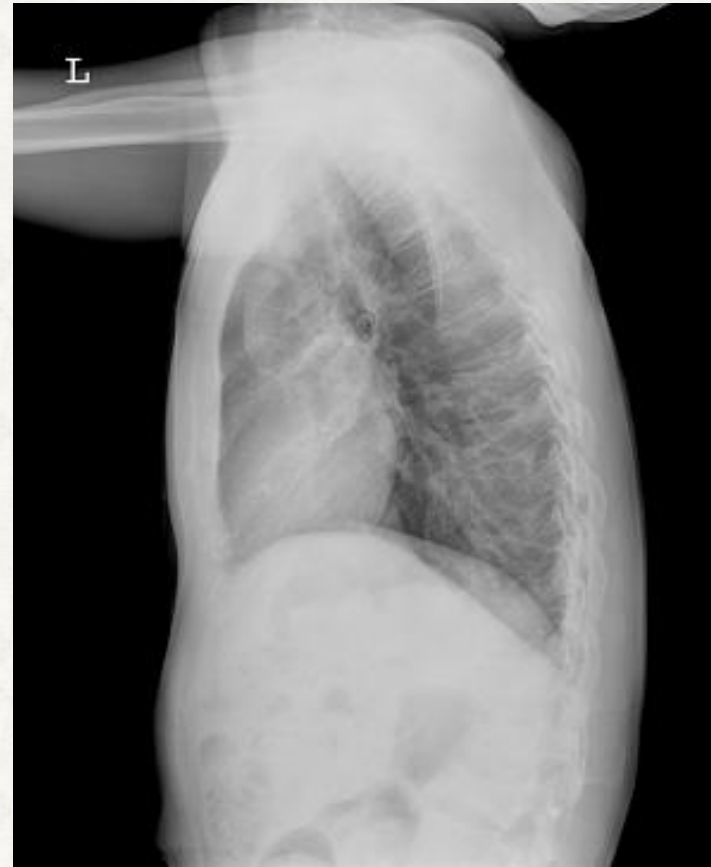
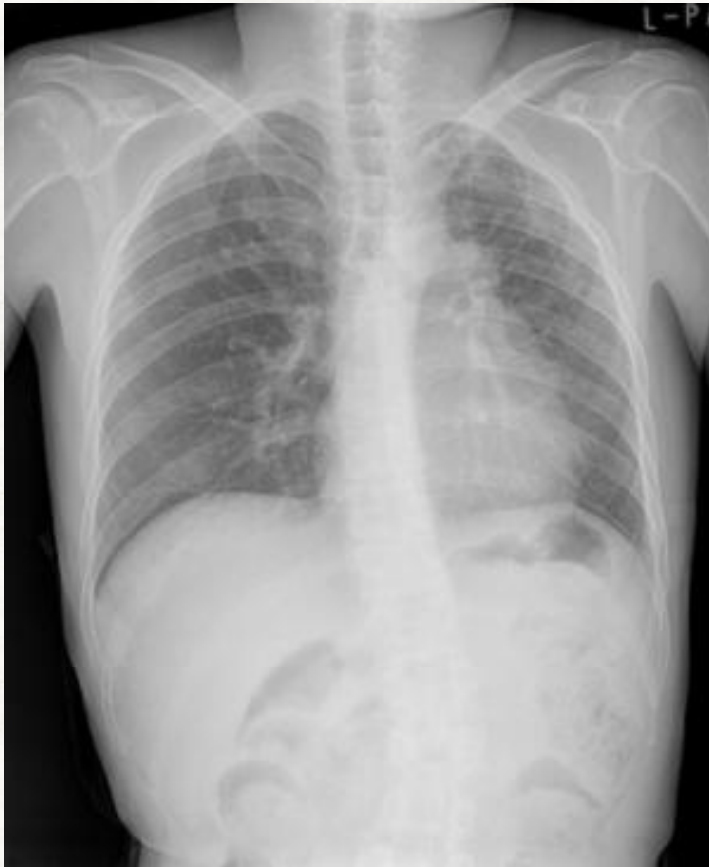## Case 4

- M/40
- C/C: substernal chest pain (effort, radiating to Lt. arm, relieved by rest)
- DM(-), HTN(-), Dyslipidemia(-), Smoker(+)
- BP 120/70 mmHg PR 70/min RR 15/min
- CK-MB 3.4 ng/mL Tnl <0.01 ng/mL

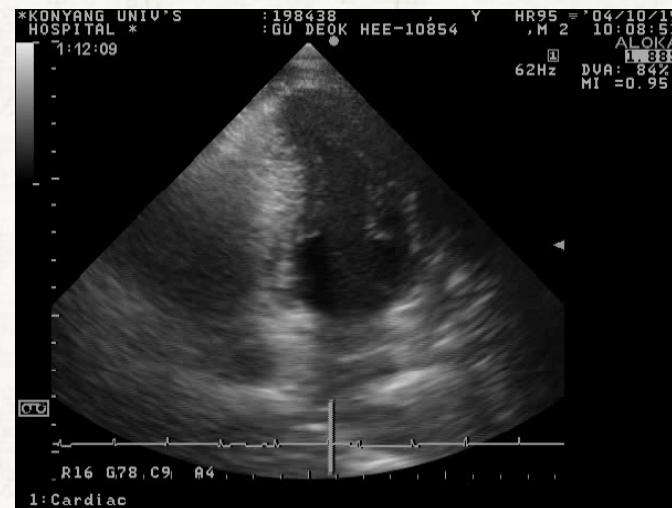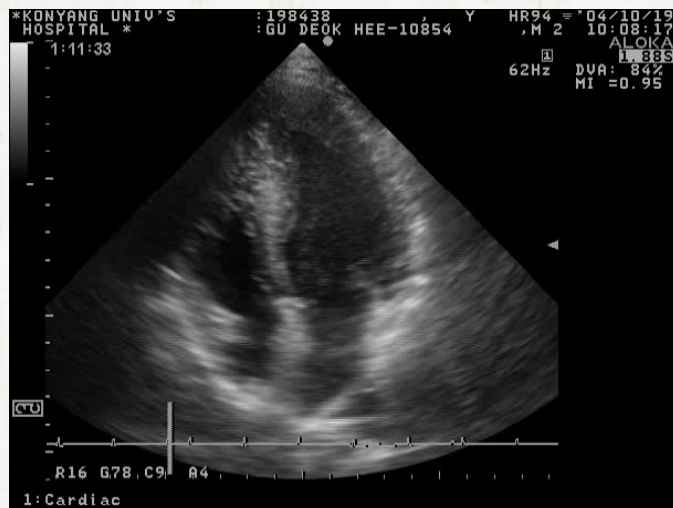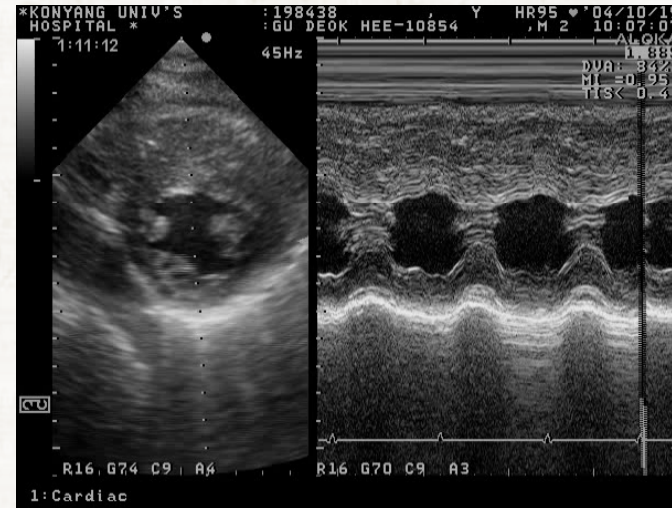
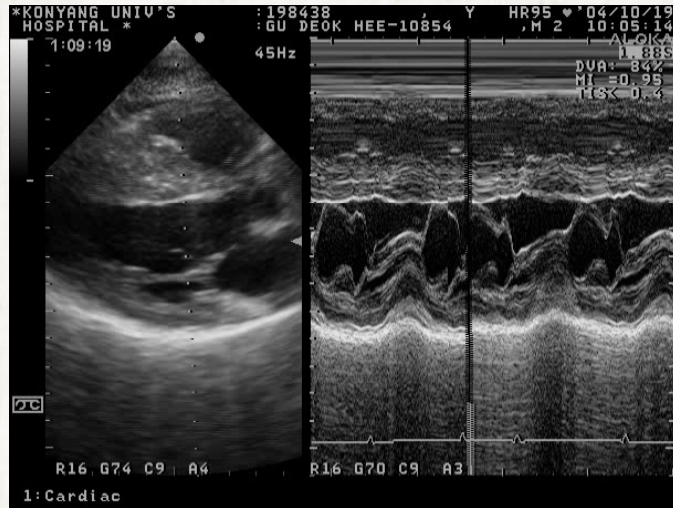
# ECG



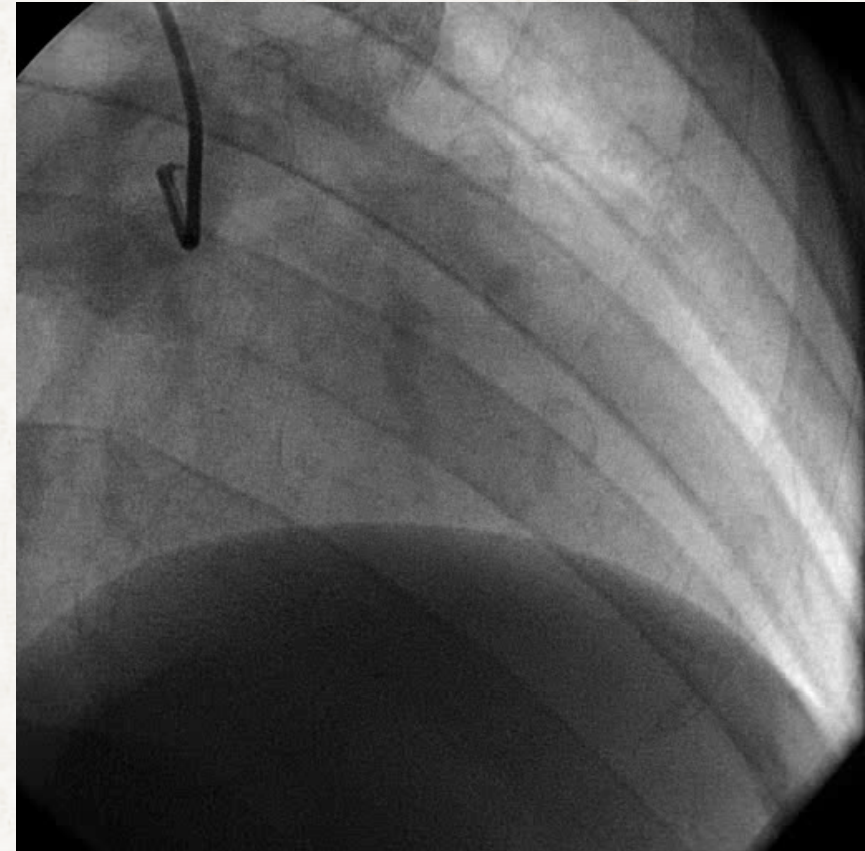
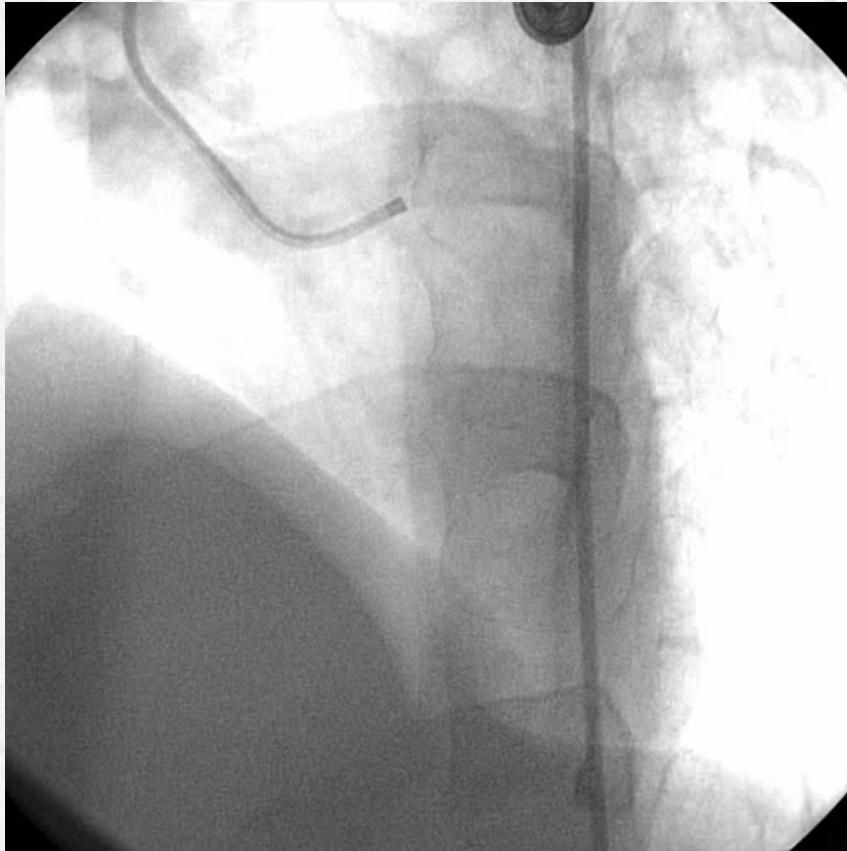
# CXR



# Echo



# CAG

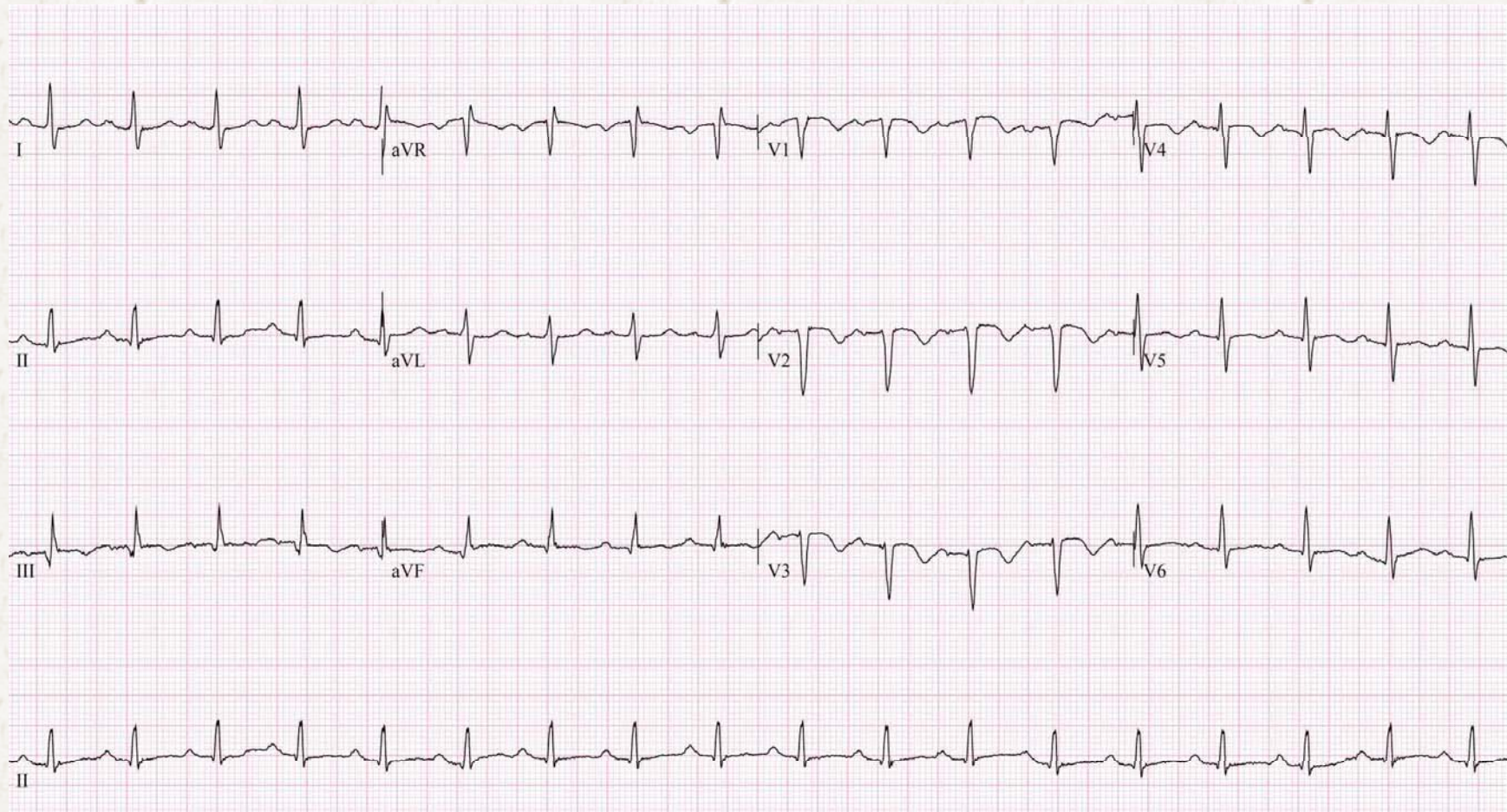


**Hypertrophic Cardiomyopathy & Myocardial Bridge**

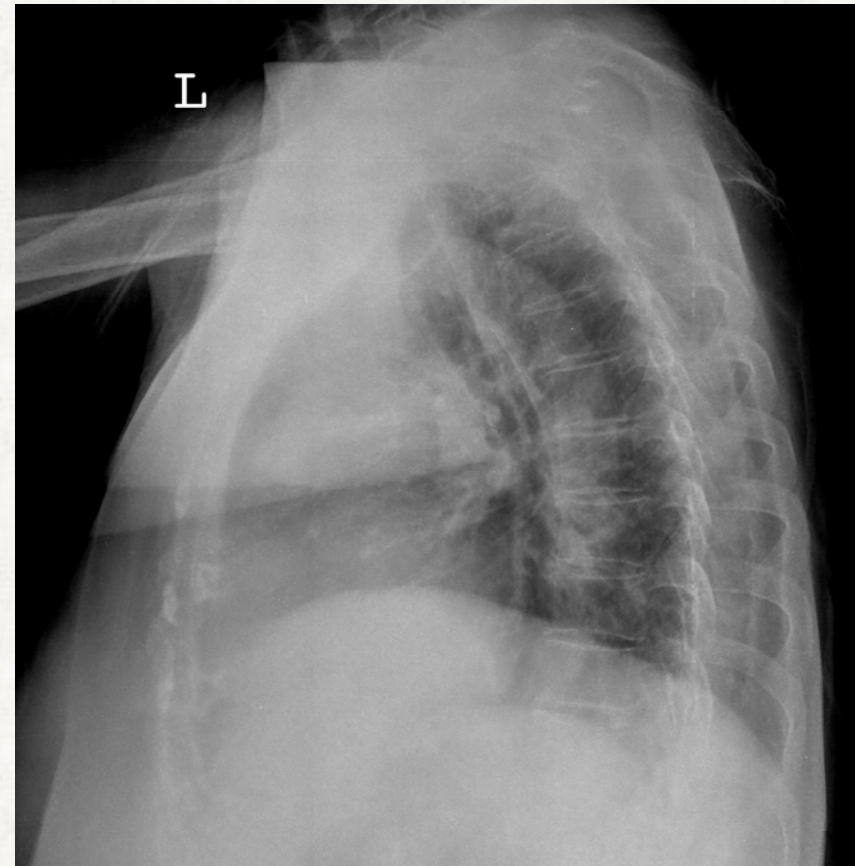
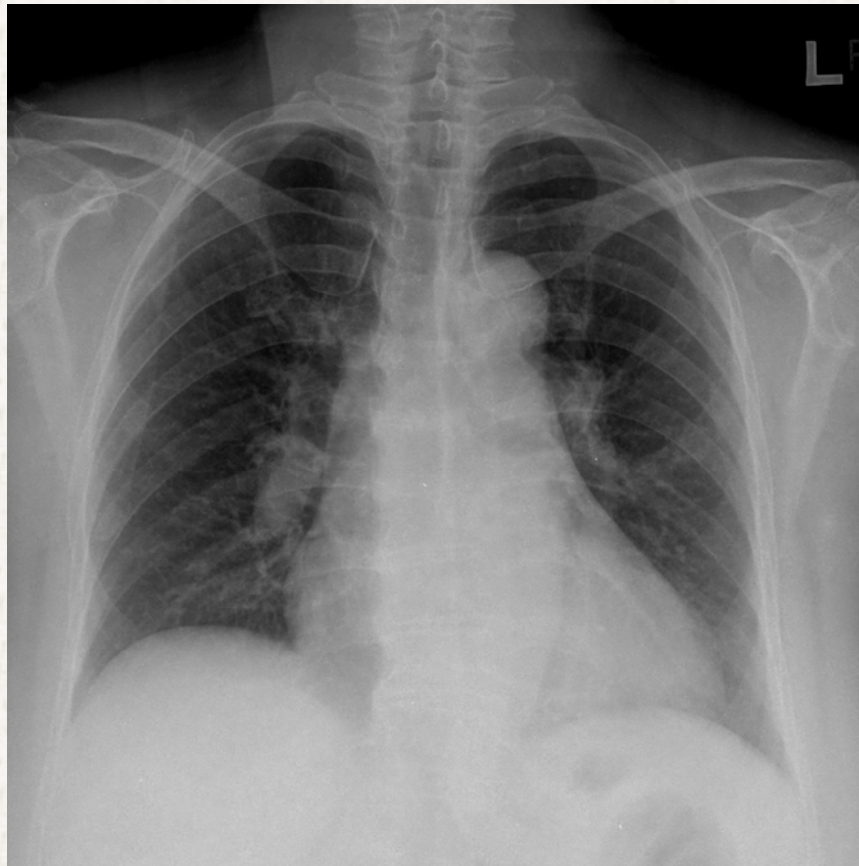
## Case 5

- F/61
- C/C: Lt. chest pain (sudden onset, pleuritic), combined dyspnea
- P/I: Both forearm fracture op. before 2 wks limited ambulation
- BP 100/65 mmHg PR 128/min RR 30/min
- CK-MB 2.1 ng/mL, Tnl 0.04 ng/mL
- BNP 1134 pg/mL, D-dimer 2.94 ug/mL

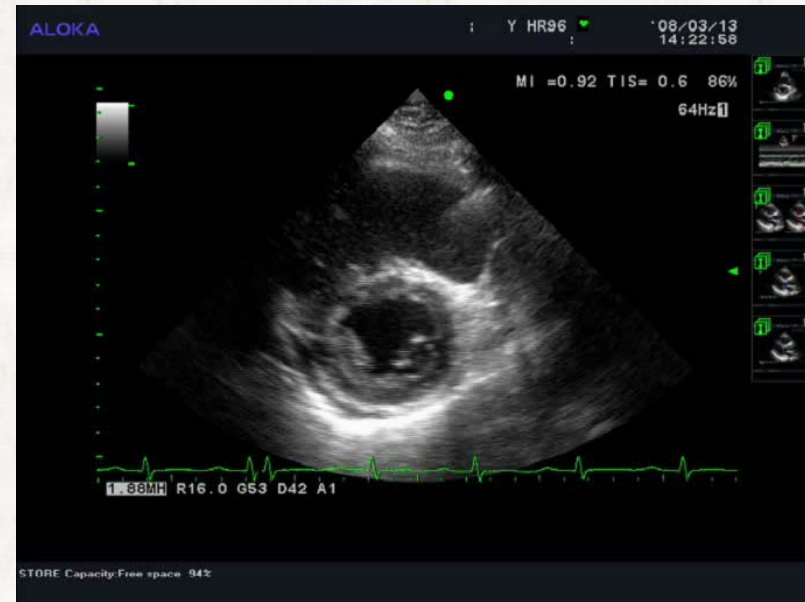
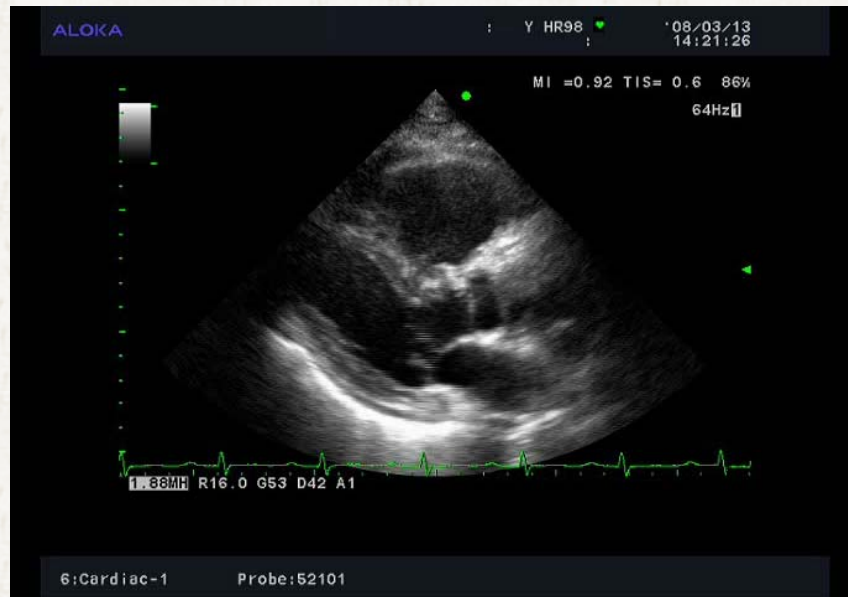
# ECG



# CXR

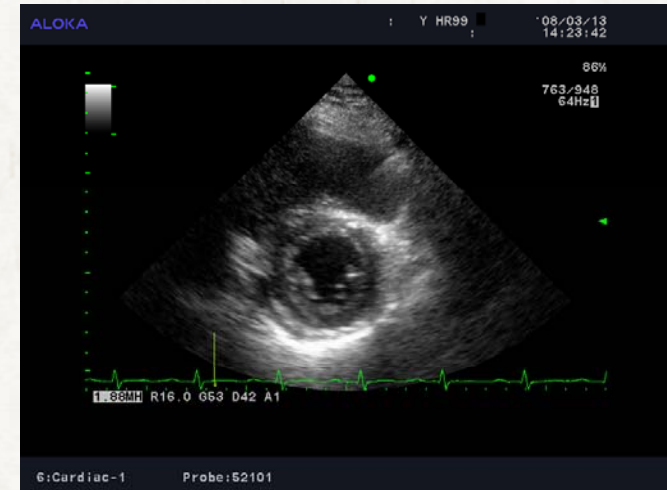
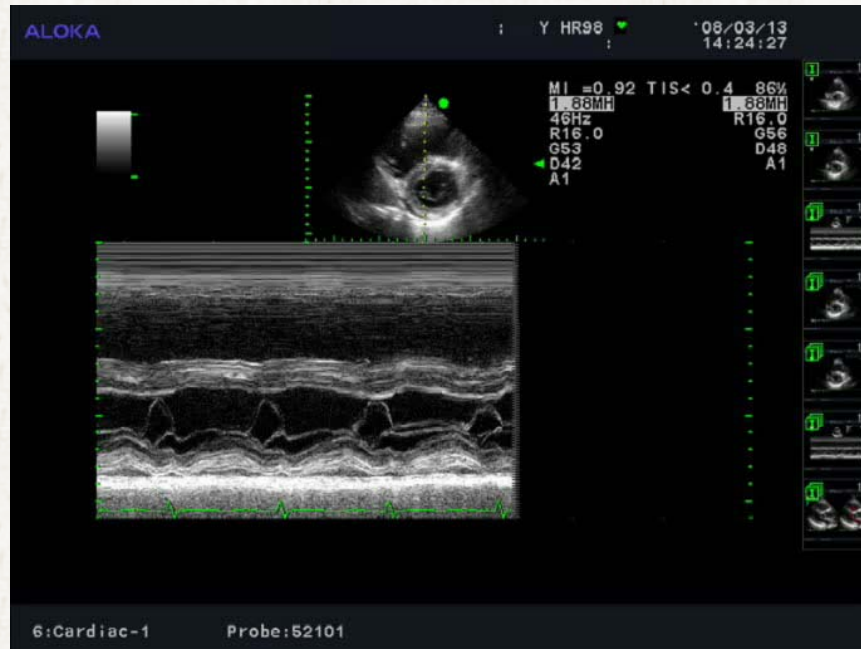


# Echo

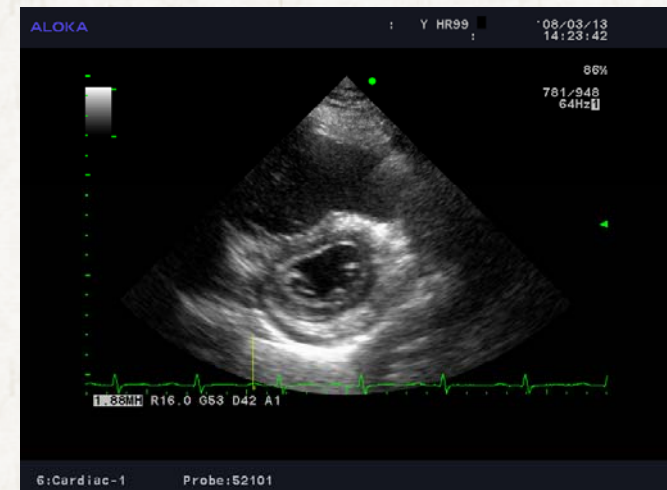


# Echo

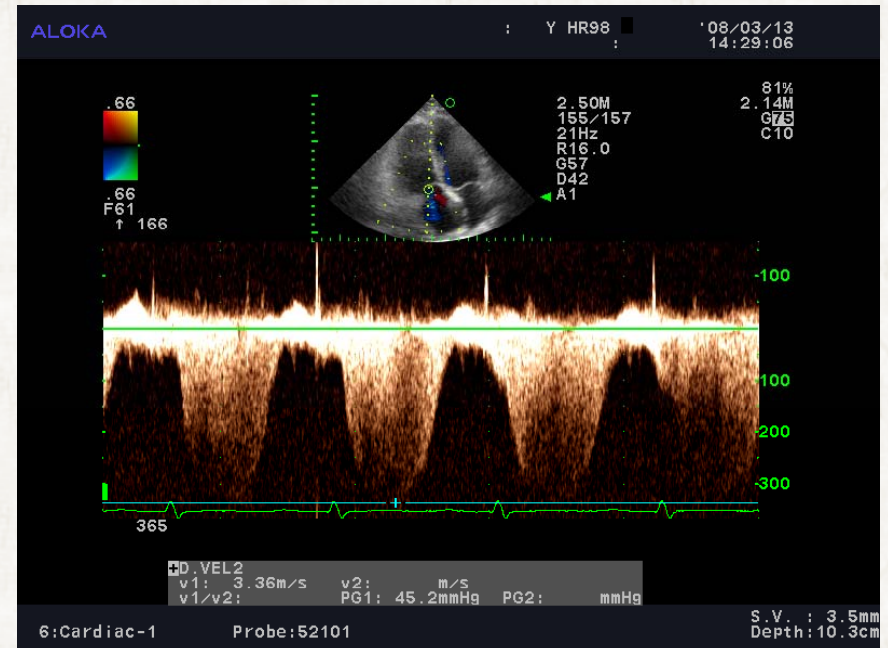
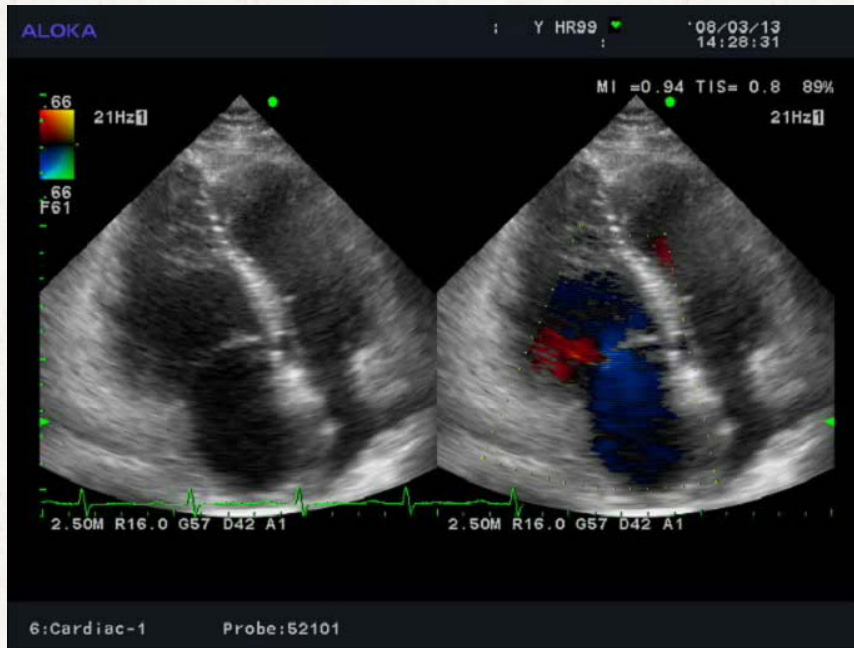
Systole



Diastole



# Echo

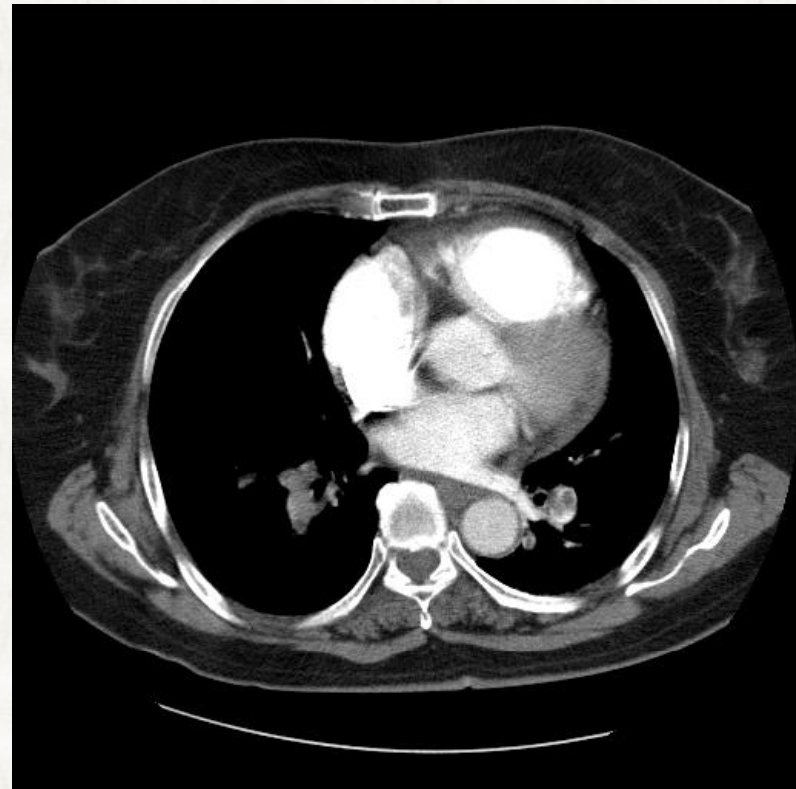
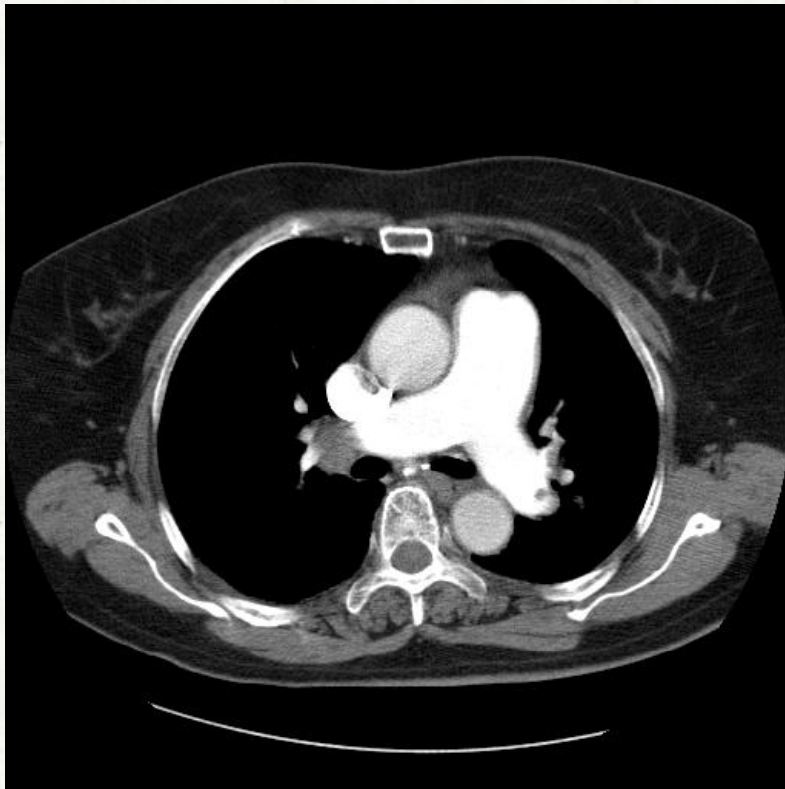



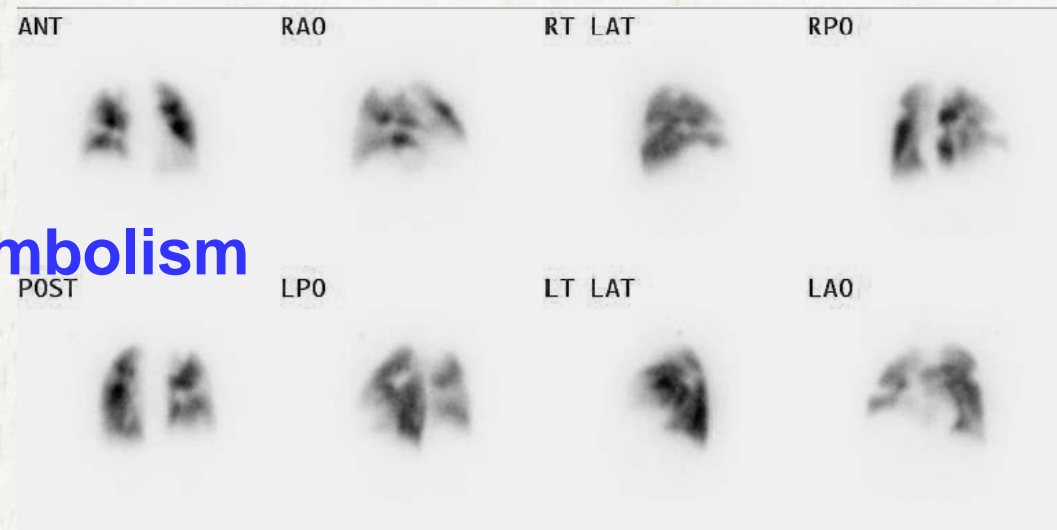
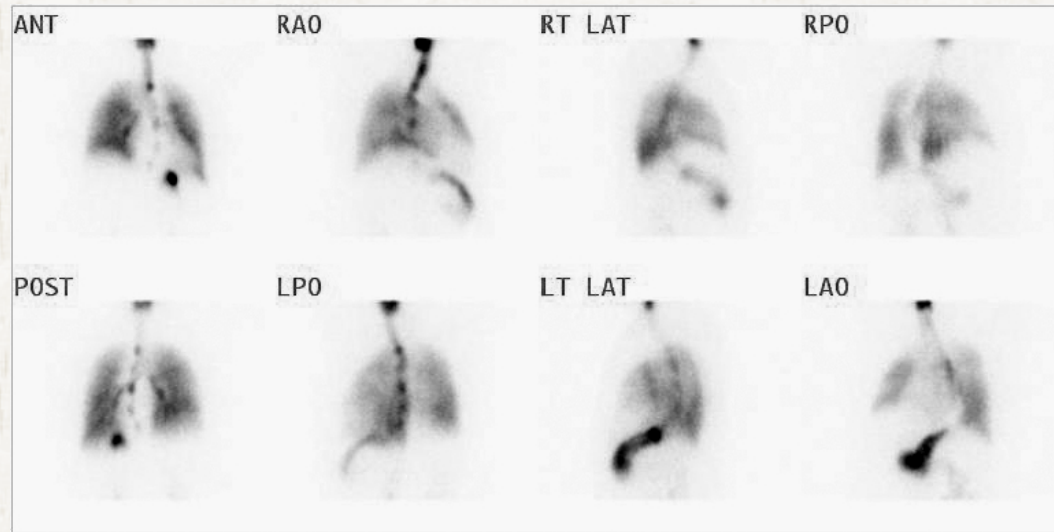
## • Next procedure?

1. Coronary angiography
2. CT scan
3. Ventilation/perfusion scan
4. Venography

# CT

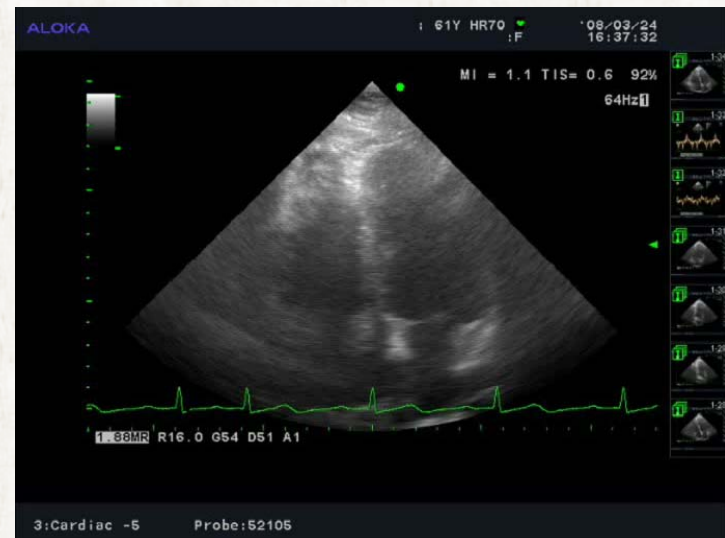
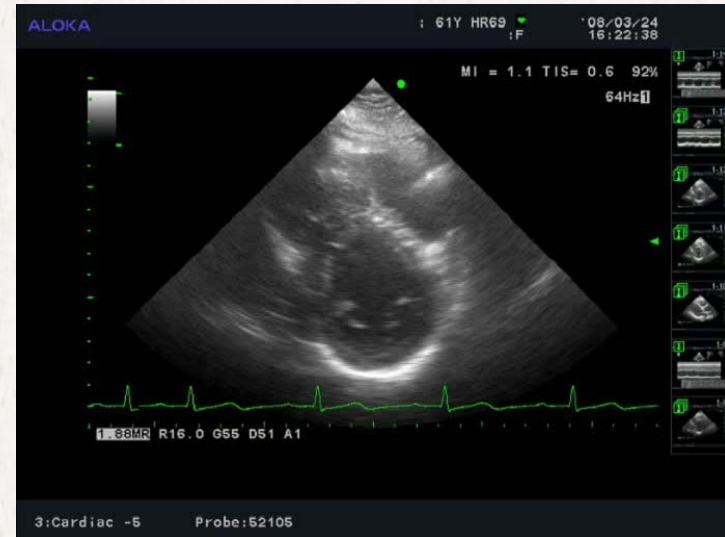
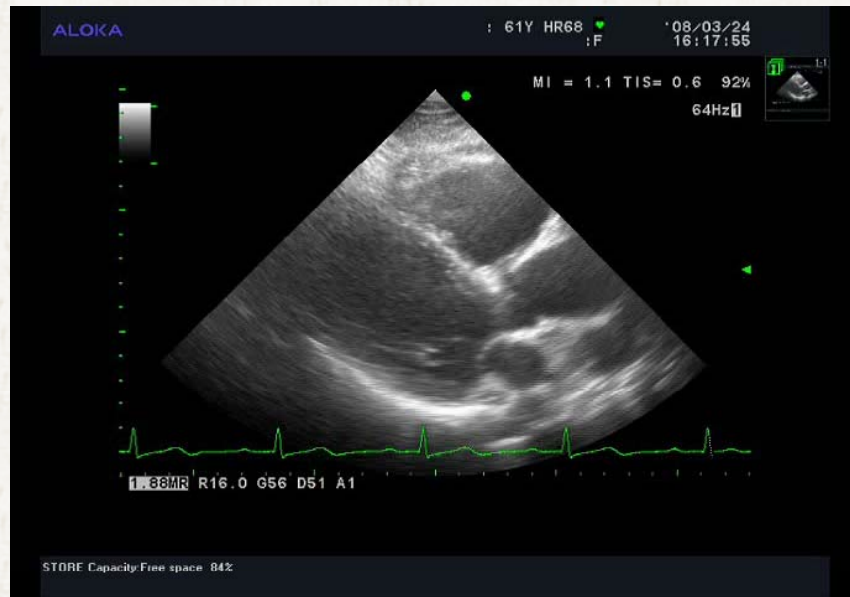


# V/Q Scan : Mismatch



**Pulmonary Thromboembolism**

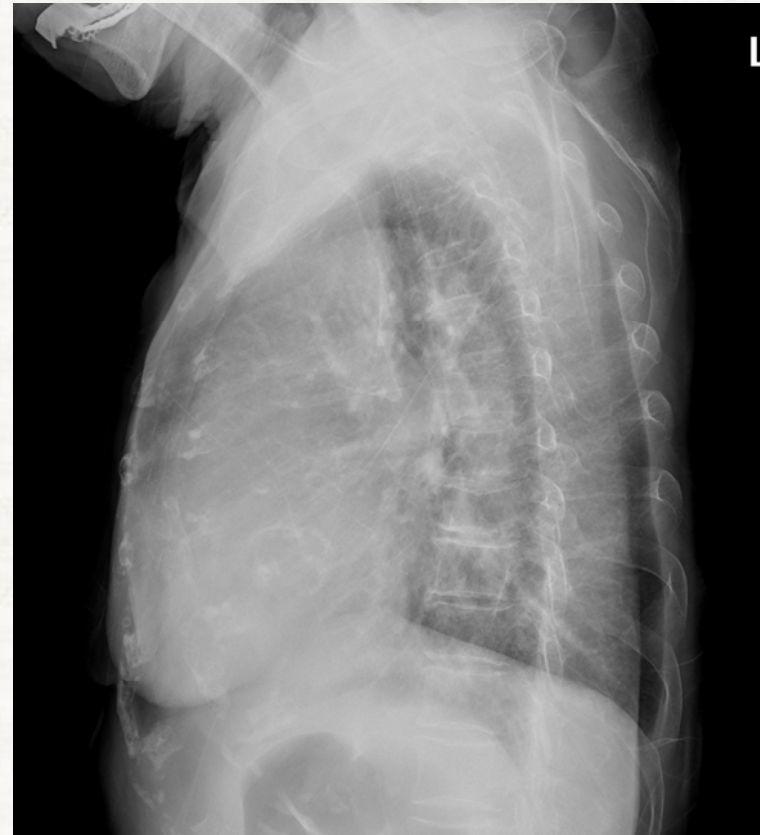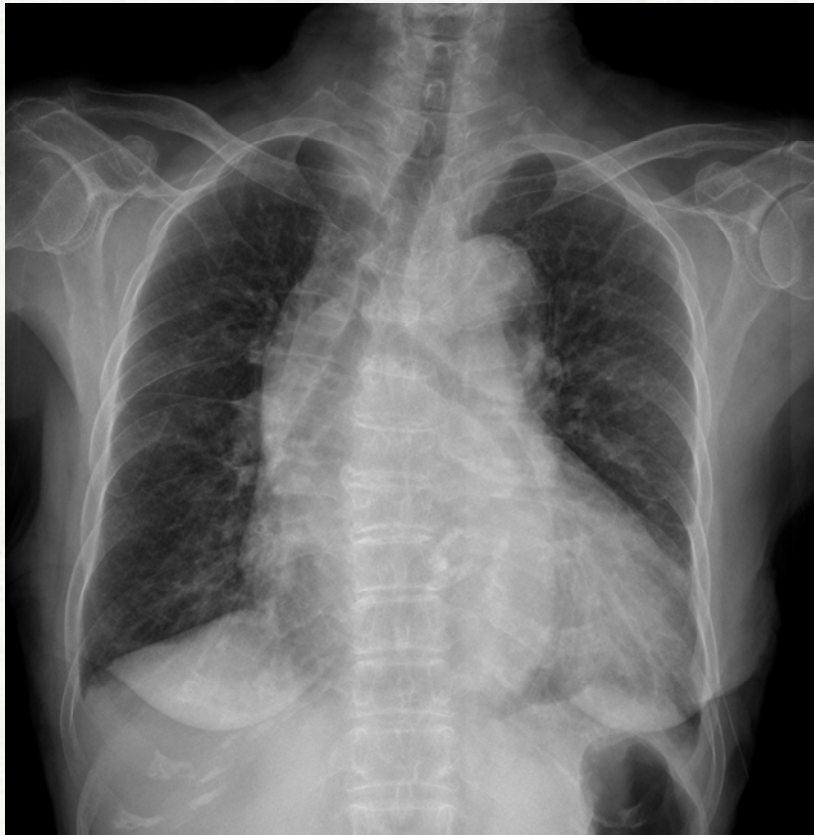# F/U Echo



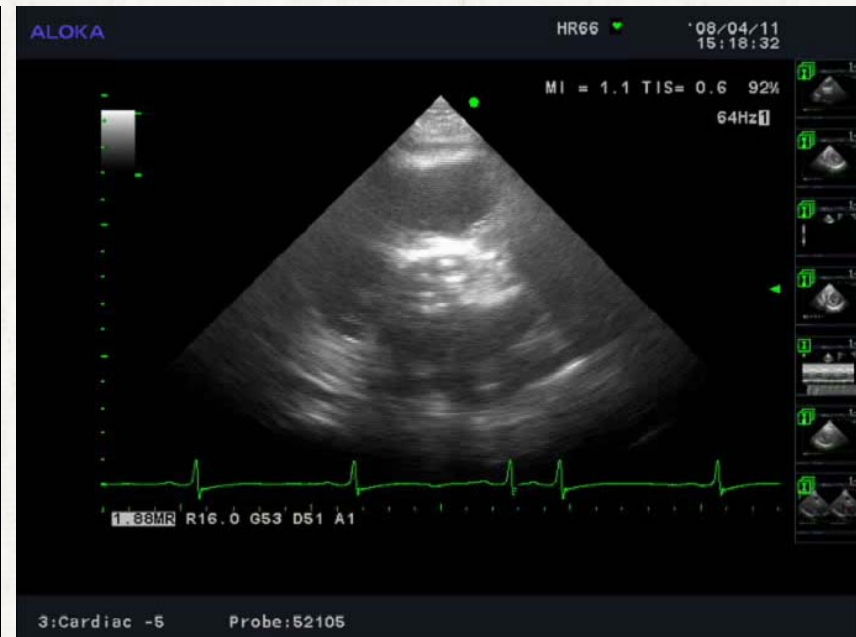
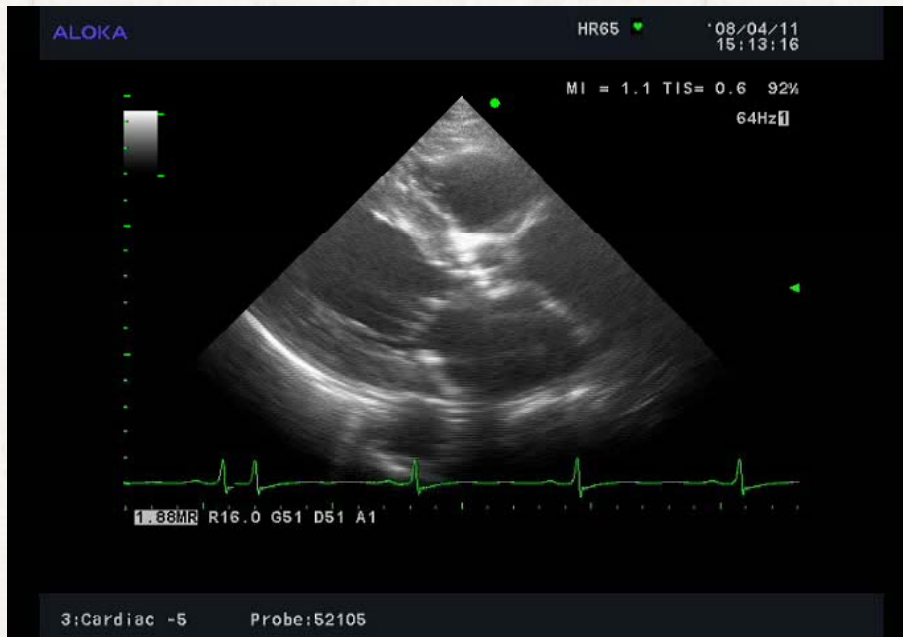
## Case 6

- F/83
- C/C: chest pain (effort, dull, radiating to both shoulder), combined DOE
- DM(-), HTN(-), Dyslipidemia(-)
- BP 100/60 mmHg PR 90/min RR 18/min
- CK-MB 3.2 ng/mL, Tnl <0.01 ng/mL
- **BNP 1015 pg/mL**

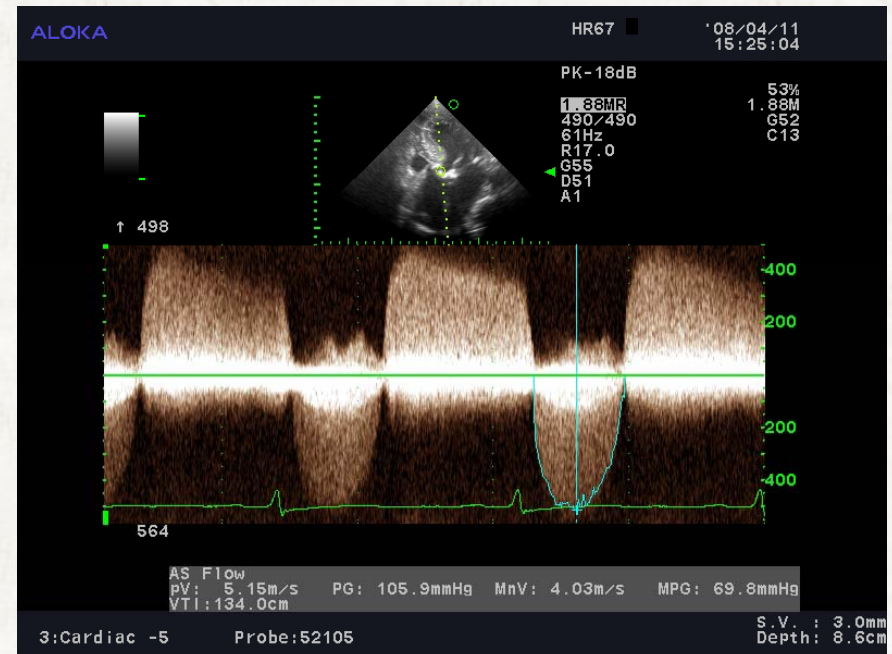
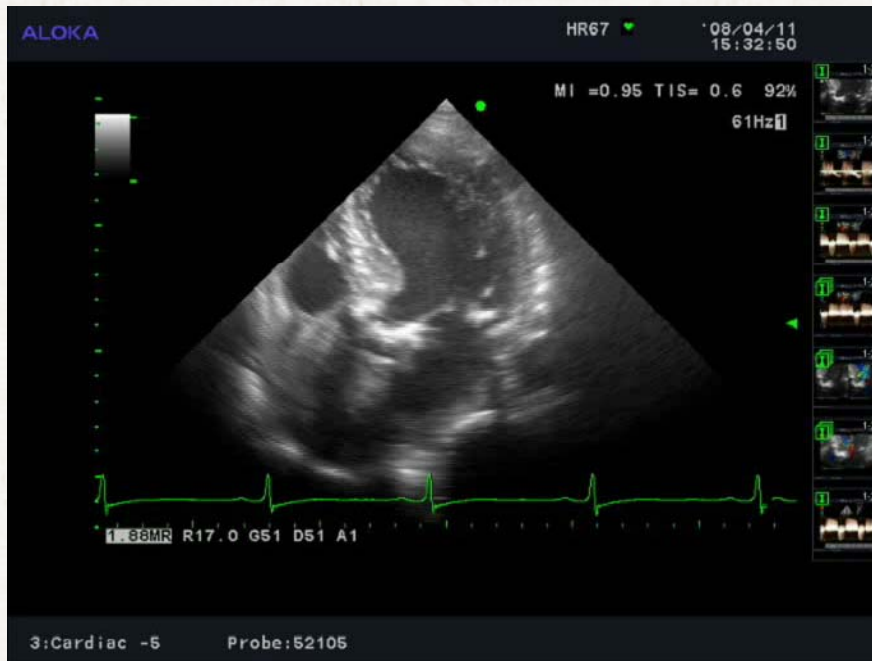
# CXR



# Echo



# Echo

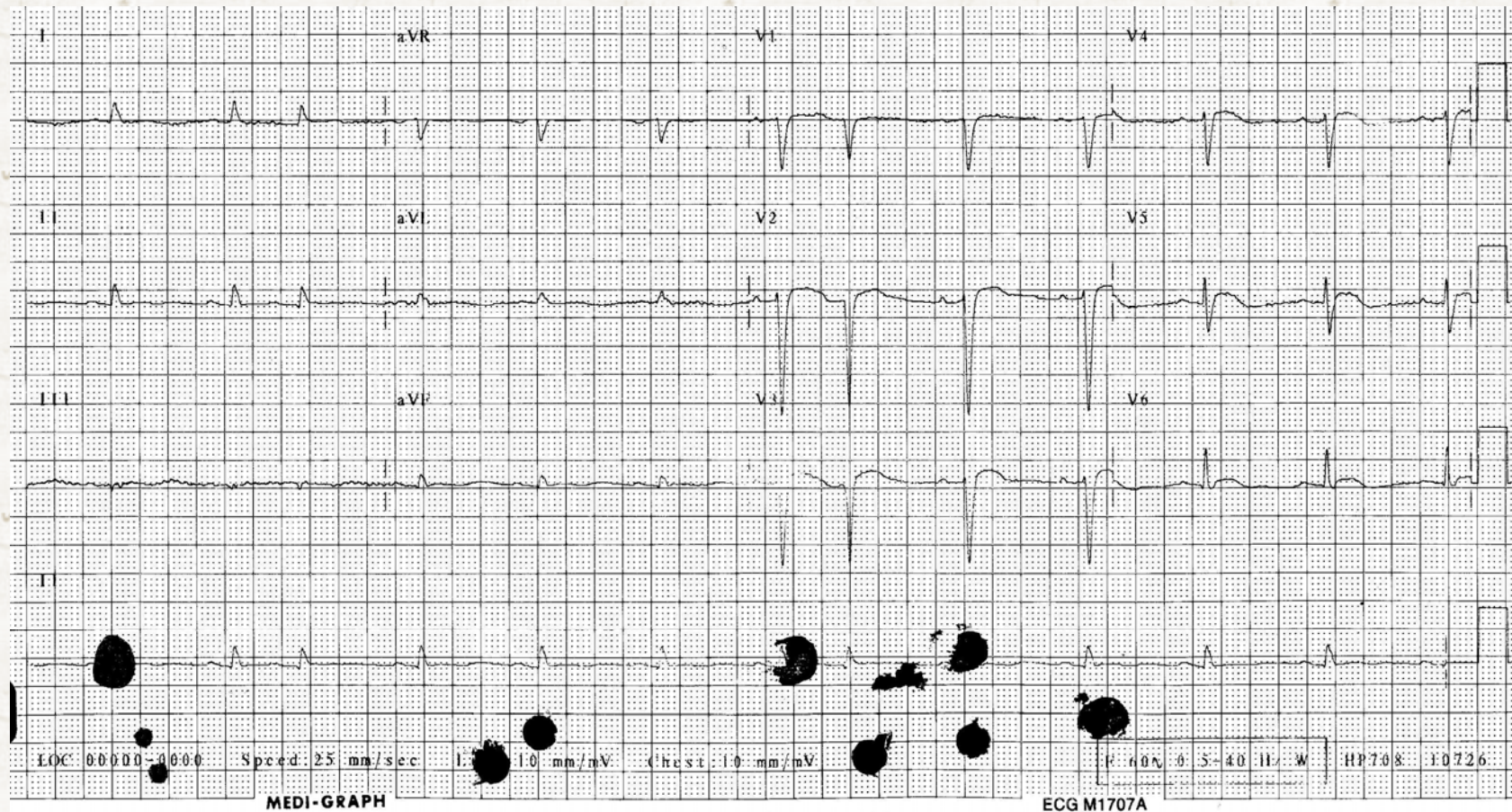


**Aortic Stenosis**

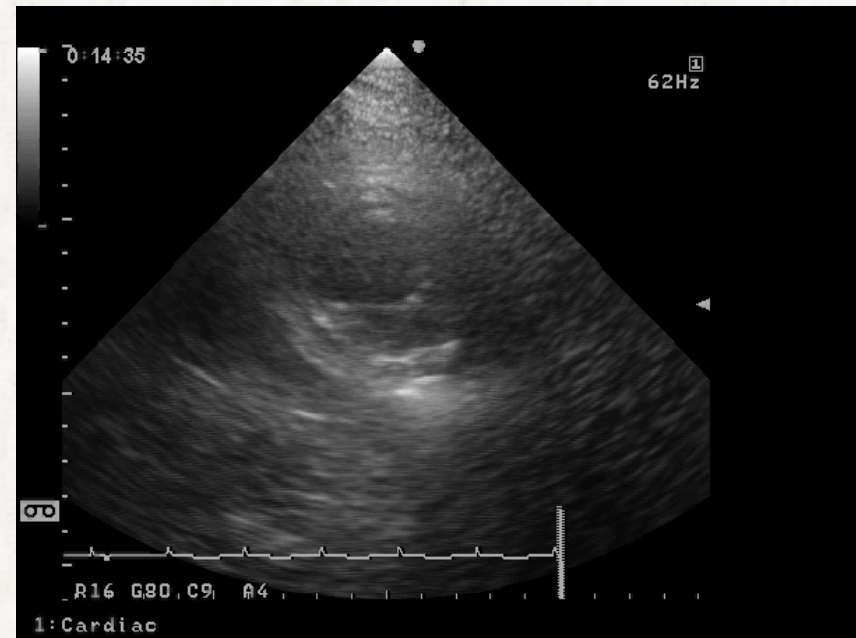
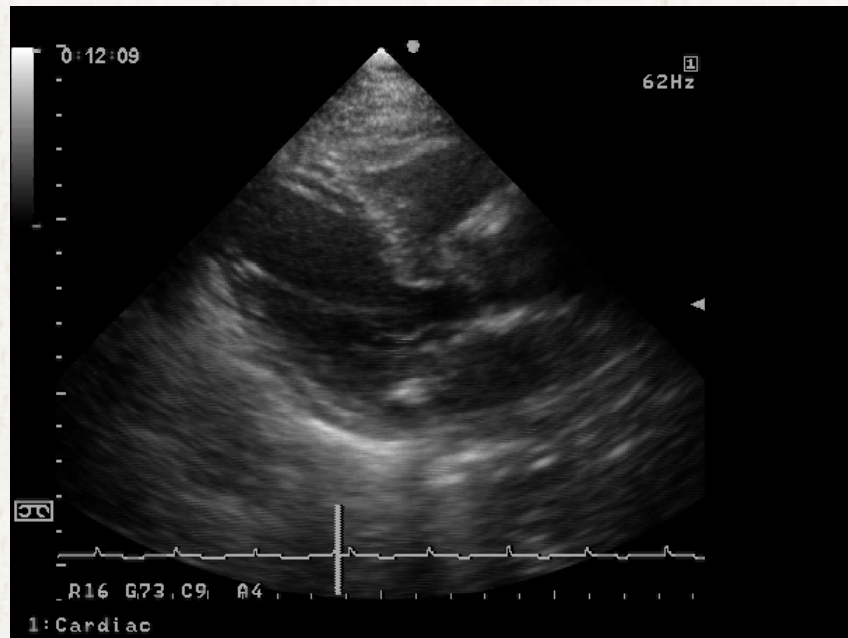
## Case 7

- F/51 yrs
- C/C: chest pain (resting, squeezing to burring, continuous)
- P/I: facial bone fracture d/t trauma
- BP 110/70 mmHg PR 98/min RR 18/min
- CK-MB 24.7 ng/mL, Tnl 4.3 ng/mL

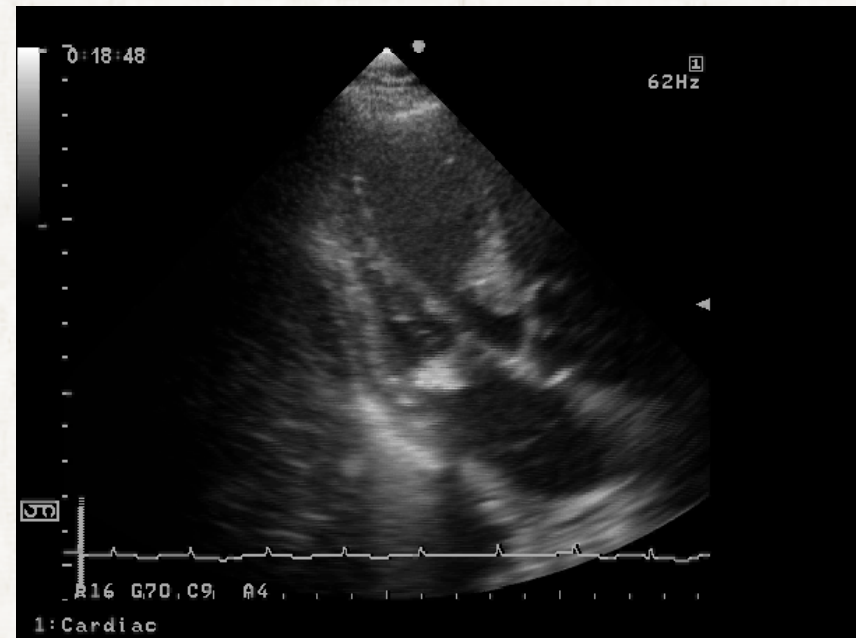
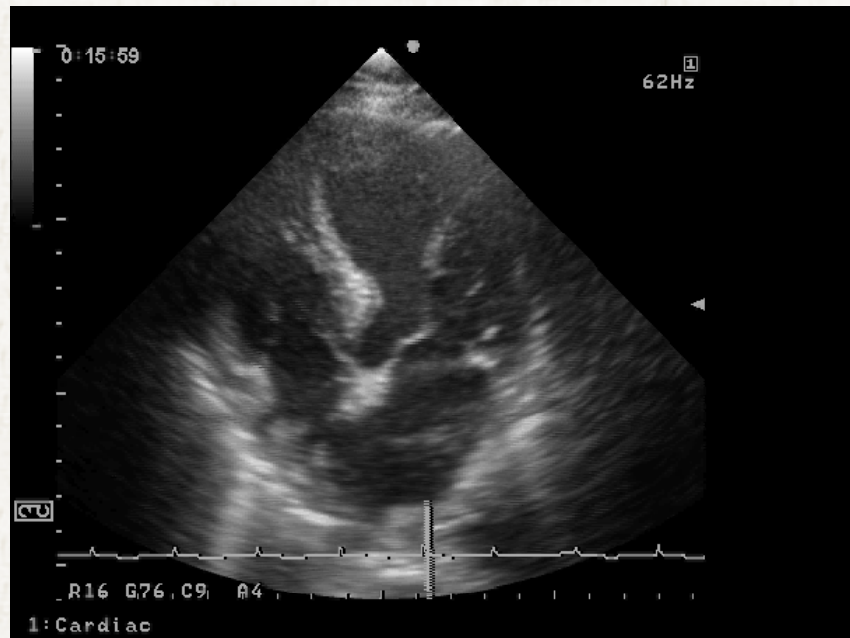
# ECG



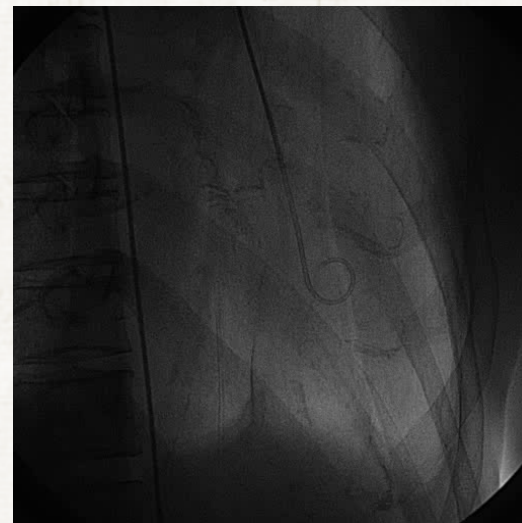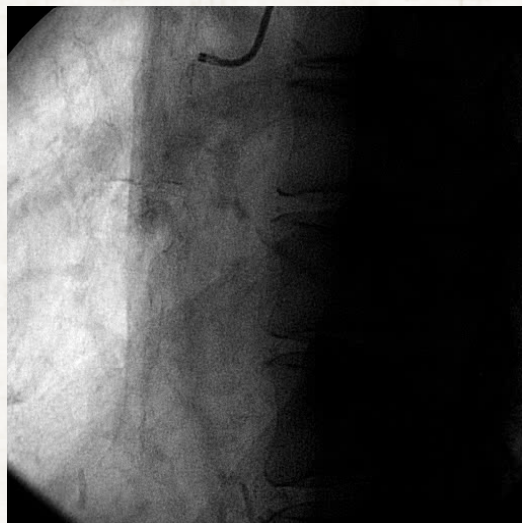
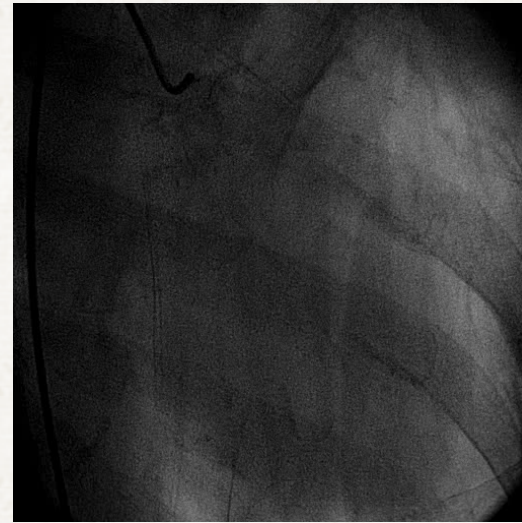
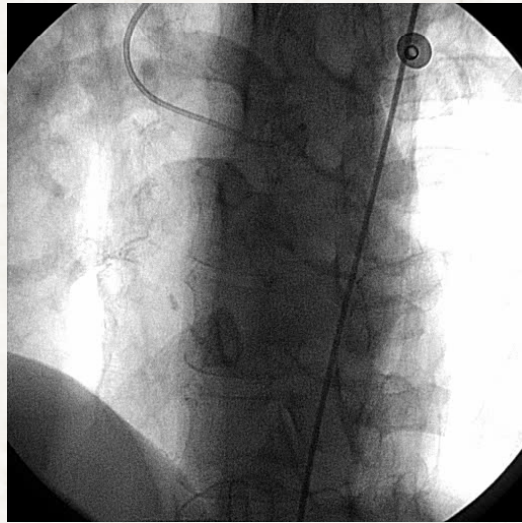
# Echo



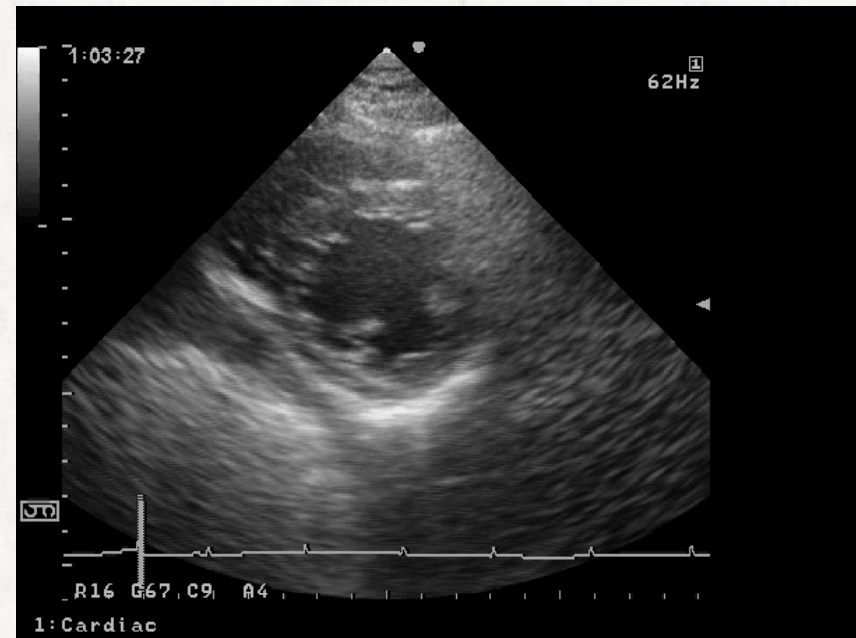
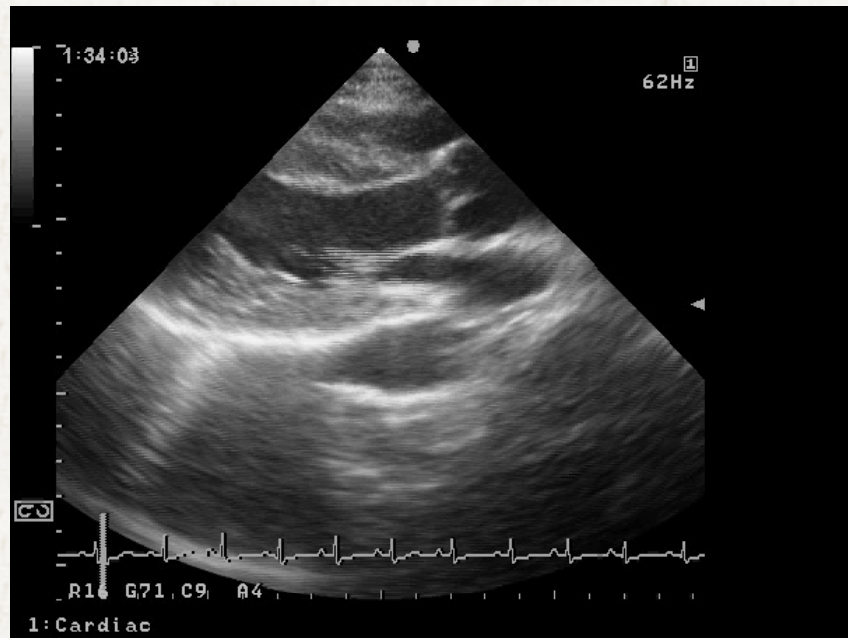
# Echo



# CAG

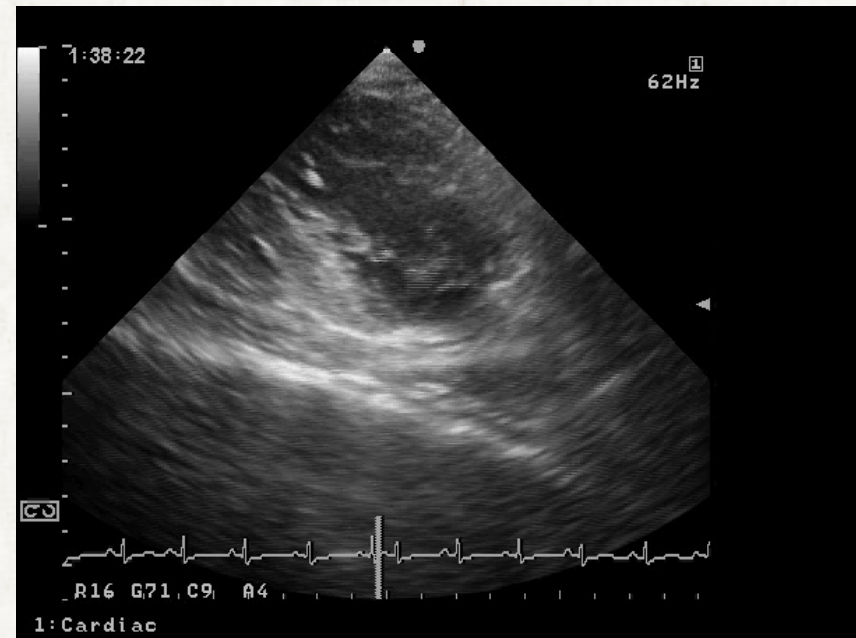
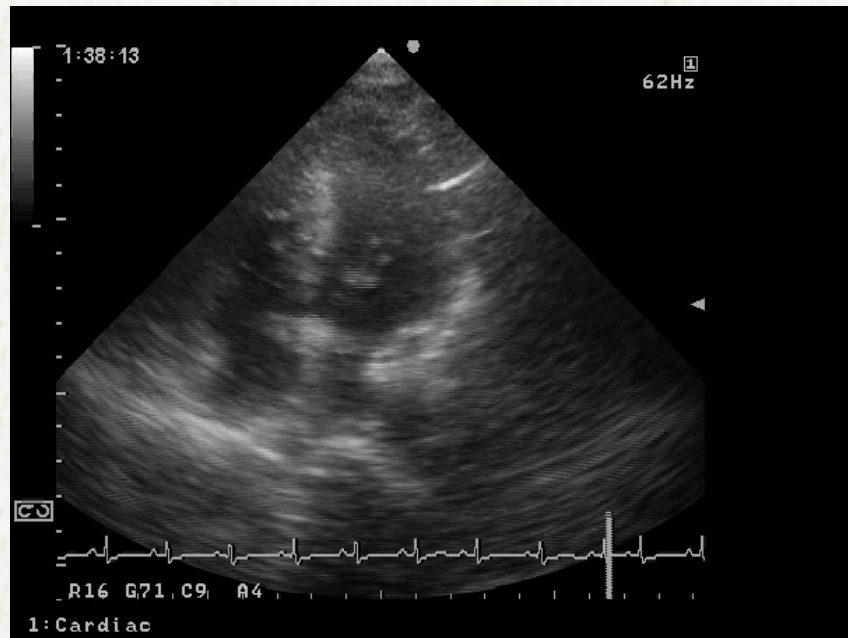


# Echo FU



**Stress Induced Cardiomyopathy**

# Echo-FU



# Cause of Chest Pain

- Coronary artery disease: SA, UA, AMI
- Acute aortic syndrome
- Myocarditis and pericarditis
- Stress induced cardiomyopathy
- Valvular heart disease: AS, MVP
- Hypertrophic cardiomyopathy
- Pulmonary thromboembolism/RV strain
- Noncardiac cause: GERD, pneumothorax  
H.zoster, costochondritis, emotional stress, etc

# DDX of Chest Pain

- History taking
- ECG, CXR
- Echocardiography
- Cardiac enzyme, BNP, D-dimer etc
- CT or MRI
- Coroanry angiography
- Cariatc cath

condition	location	quality	duration	Aggravating or relieving factors	associated symptoms or signs
<b>Angina</b>	retrosternal region; radiates or occasionally isolated to neck, jaw, epigastrium, shoulder, or arms—left common	pressure, burning, squeezing, heaviness, indigestion	<2-10min	Precipitated by exercise, cold weather, or emotional stress; relieved by rest or nitroglycerin; atypical (Prinzmetal's) angina may be unrelated to activity, often early morning	S4, or murmur of papillary muscle dysfunction during pain
<b>rest or unstable angina</b>	Same as angina	Same as angina but may be more severe	Usually <20min	Same as angina, with decreasing tolerance for exertion or at rest	Similar to stable angina, but may be pronounced. Transient cardiac failure can occur
<b>Myocardial infarction</b>	Substernal and may radiate like angina	Heaviness, pressure, burning, constriction	Sudden onset, 30min or longer but variable	Unrelieved by rest or nitroglycerin	Similar to stable angina, but may be pronounced. Transient cardiac failure can occur
<b>Pericarditis</b>	Usually begins over sternum or toward cardiac apex and may radiate to neck or left shoulder, often more localized than the pain of MI	Sharp, stabbing, knifelike	Lasts many hours to days, may wax and wane	aggravated by deep breathing, rotating chest, or supine position, relieved by sitting up and leaning forward	Pericardial friction rub
<b>Aortic dissection</b>	Anterior of chest; may radiate to back	Excruciating, tearing, knifelike	Sudden onset, unremitting	Usually occurs in setting of hypertension or predisposition such as Marfan's syndrome	Murmur of aortic insufficiency, pulse or blood pressure asymmetry; neurologic deficit
<b>Pulmonary embolism (chest pain often not present)</b>	Substernal or over region of pulmonary infarction	Pleuritic (with pulmonary infarction) or angina-like	sudden onset; minutes to <1hr	may be aggravated by breathing	Dyspnea, tachypnea, tachycardia; hypotension, signs of acute right heart failure, and pulmonary hypertension with large emboli; rales, pleural rub, hemoptysis with pulmonary infarction
<b>Pulmonary hypertension</b>	substernal	pressure, oppressive		Aggravated by effort	Pain usually associated with dyspnea; signs of pulmonary hypertension

## Question: chest pain at ER

• What's your choice?

1. Echo

2. Cardiac CT