

Edema

Jong-Min Song
Asan Medical Center

Case

□ 58 / F

- C.C.: 몸이 자주 붓는다.

몸이 허해서 몸보신이 필요한 것 같다.

혈액 순환이 잘 안 된다고 들었다.

콩팥이 나쁜 것 같다.

심장이 안 좋을까?

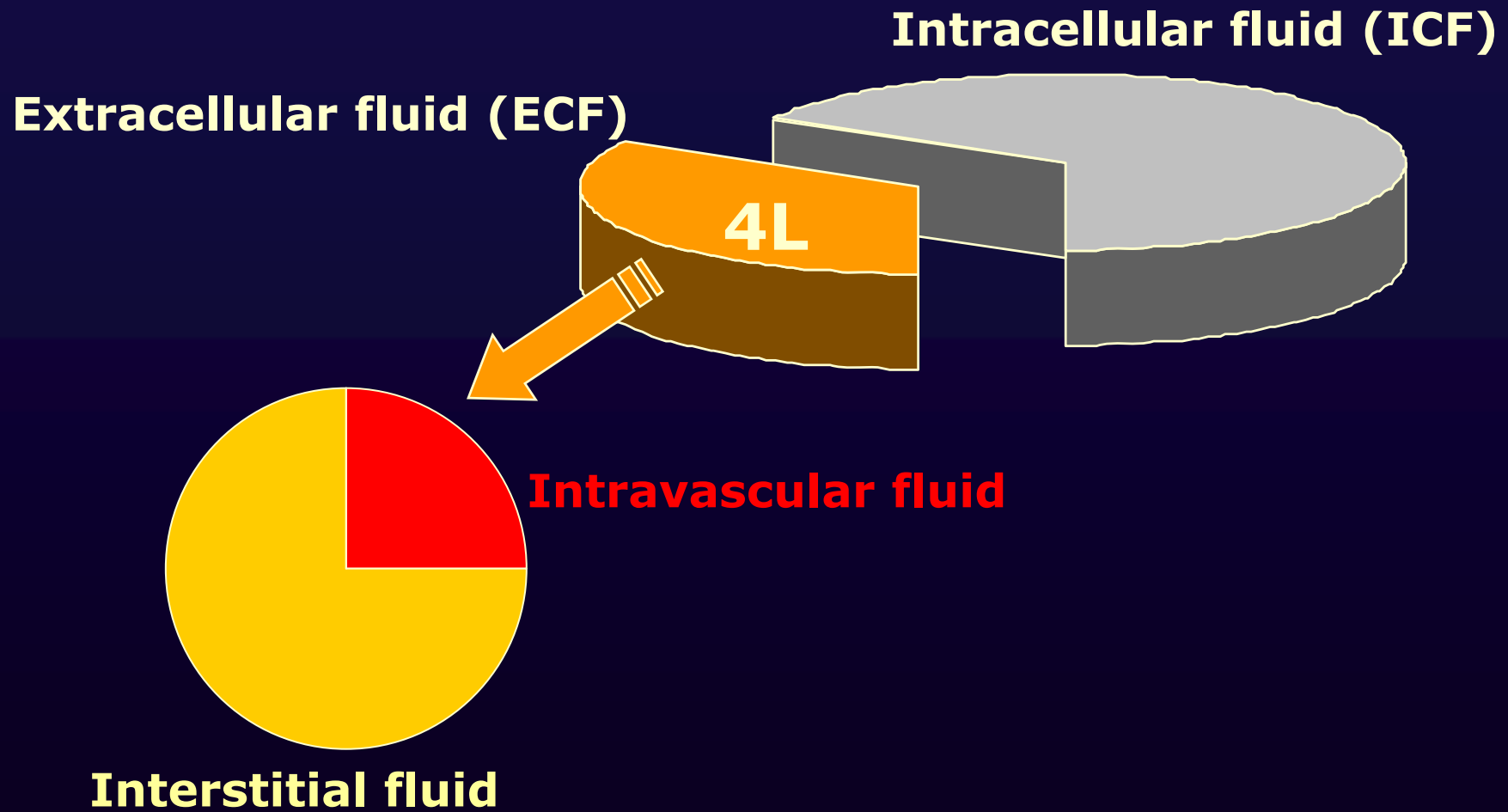


Edema

□ Definition

- Clinically apparent increase in the **interstitial fluid volume**
- **Anasarca**: gross generalized edema
- **Ascites**: excess fluid in the peritoneal cavity
- **Hydrothorax**: excess fluid in the pleural cavity

Total Body Water



Pathogenesis

□ Starling forces

- Increased **hydrostatic pressure** within the vessel
 - Obstruction in venous drainage
- Decreased **oncotic pressure**
 - Hypoalbuminemia
 - Saline expansion
 - Malnutrition
 - Liver disease
 - Nephrotic syndrome
 - Severe catabolic state

Pathogenesis

□ Capillary damage

- Inflammatory edema
 - Drugs
 - Viral or bacterial agents
 - Thermal or mechanical trauma

□ Reduced effective arterial volume

□ Reduced cardiac output

Pathogenesis

□ Renal factors

- Salt and water reabsorption
- Increased renin release
 - Diminished stretch of the juxtaglomerular cells
 - Low NaCl reaching the distal renal tubules
 - Activation of the β -adrenergic receptors by sympathetic nervous system

Pathogenesis

□ Renin-angiotensin-aldosterone system

- Angiotensin II
 - Renal vasoconstriction
 - Salt and water reabsorption
- Aldosterone
 - Na⁺ reabsorption and K⁺ excretion (collecting tubule)
 - “Mineralocorticoid escape”
 - Pressure natriuresis
 - Natriuretic substances
 - Edema
 - When deficit in effective arterial volume cannot be repaired

Pathogenesis

□ Arginine vasopressin (AVP)

- Secretion stimulated by
 - Increased intracellular osmolar concentration
 - Decreased effective arterial volume
- Reabsorption of free water
 - Renal distal tubule and collecting duct

□ Endothelin

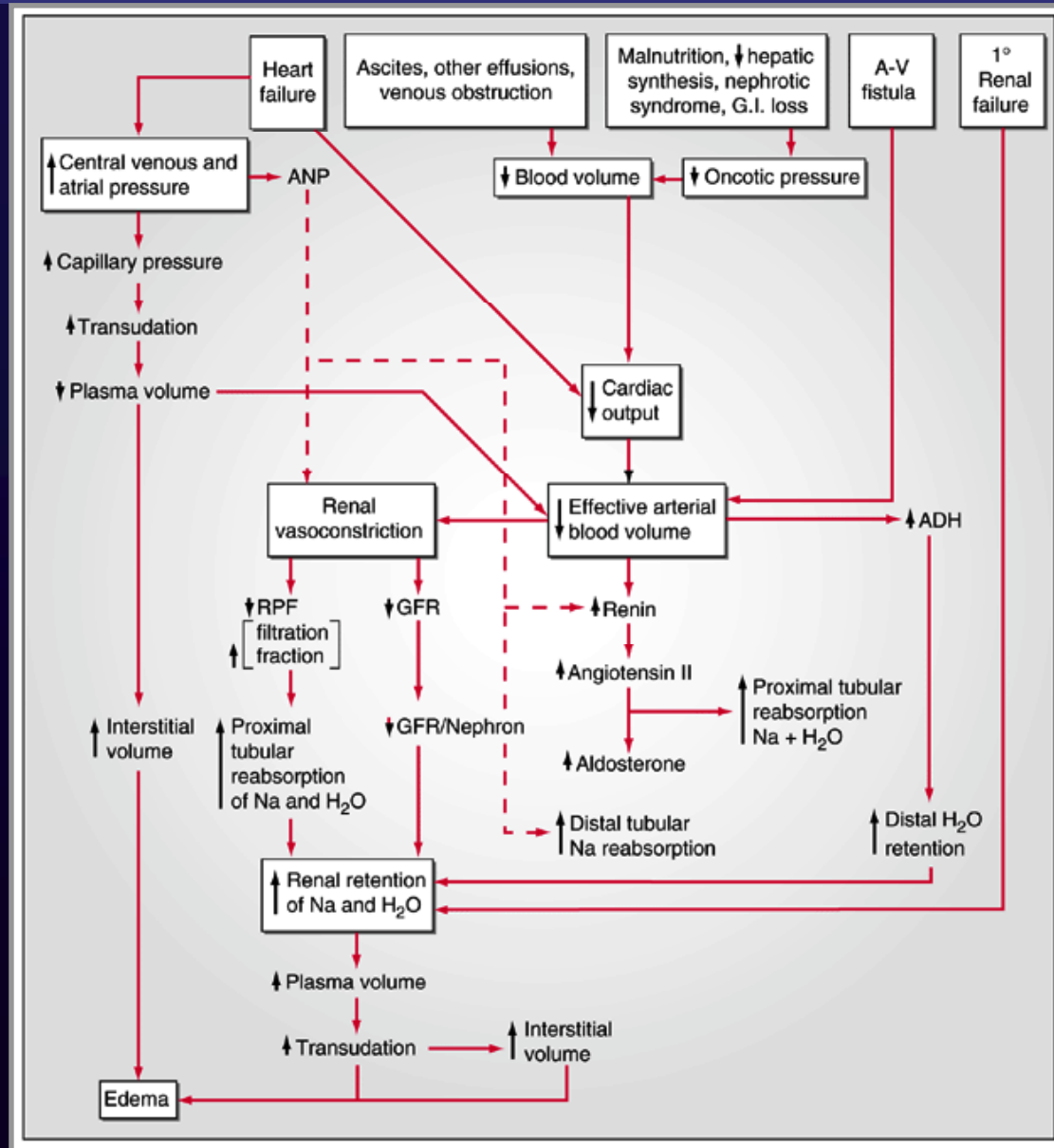
- Renal vasoconstriction
- Na⁺ retention

Pathogenesis

□ Natriuretic peptides

- Excretion of sodium and water
 - Augmenting GFR
 - Inhibiting sodium reabsorption (proximal tubule)
 - Inhibiting release of renin / aldosterone
- Arteriolar and venous dilatation
 - Antagonizing angiotensin II, AVP, sympathetic stimulus
- Elevated but not sufficiently increased secretion in CHF

Pathogenesis



Clinical Causes

□ Venous / lymphatic obstruction

- Local edema

□ Congestive heart failure

- Decreased cardiac output
- Increased central venous pressure
 - Exertional dyspnea, orthopnea, PND
 - JVP elevation, S3 gallop, cool extremities, small pulse pressure, displaced apical pulse
 - Cardiomegaly, pulmonary congestion, BNP elevation

Clinical Causes

- **Nephrotic syndrome**
 - Diminished colloid oncotic pressure
 - Impaired Na⁺ excretion

- Other hypoalbuminemic states
 - Severe nutritional deficiency
 - Severe chronic liver disease
 - Protein-losing enteropathy

Clinical Causes

□ Liver cirrhosis

- Hepatic venous outflow blockade
- Hypoalbuminemia
- Increased circulating aldosterone
 - Diminished metabolism by liver
- Excess production of prostaglandins (PGE₂, PGI₂)
 - Attenuates renal Na⁺ retention
 - Inhibited by NSAIDs

Clinical Causes

□ Drug-induced edema

- Renal vasoconstriction
 - NSAIDs, cyclosporin
- Arteriolar dilatation
 - Vasodilators
 - Minoxidil, hydralazine, Ca-channel blockers, α -antagonists
- Augmented renal sodium reabsorption
 - Steroid hormone
- Capillary damage
 - Interleukin 2

Clinical Causes

□ Idiopathic edema

- Almost exclusively in women
- Periodic episodes of edema (diurnal variation)
- Increased capillary permeability
- Aggravated by hot weather
- Treatment
 - Reducing salt intake
 - Rest in the supine position for several hours a day
 - Wearing of elastic stocking
 - ACE inhibitors, progesterone, bromocriptine, dextroamphetamine

Clinical Causes

□ Premenstrual edema

- Na^+ retention by excessive estrogen stimulation

□ Diuretic-induced edema

- Chronic hyperreninemia and juxtaglomerular hyperplasia
- Aggravated by acute withdrawal of diuretics

Approach to the Patient

- 1. Distribution of edema**
- 2. Venous pressure**
- 3. Hypoalbuminemia**
- 4. Urine output**

Approach to the Patient

□ Distribution of edema

- One arm or leg
 - venous / lymphatic obstruction
 - paralysis
- Eyelids and face
 - Hypoalbuminemia (especially in the morning)
 - Allergic reaction
 - Myxedema
- Dependent portion
 - Heart failure

Approach to the Patient

□ Venous pressure

- Generalized elevated venous pressure
 - **Increased JVP**
 - Advanced heart failure
 - Constrictive pericarditis
 - Tricuspid stenosis or severe regurgitation
- Lower extremities and ascites
 - Normal JVP
 - Liver cirrhosis

Approach to the Patient

□ Hypoalbuminemia

- Liver cirrhosis
- Severe malnutrition
- Protein-losing gastroenteropathy
- Nephrotic syndrome

□ Urine output

- Oliguria or anuria
 - Renal failure

IVC Physiology

□ Inspiration

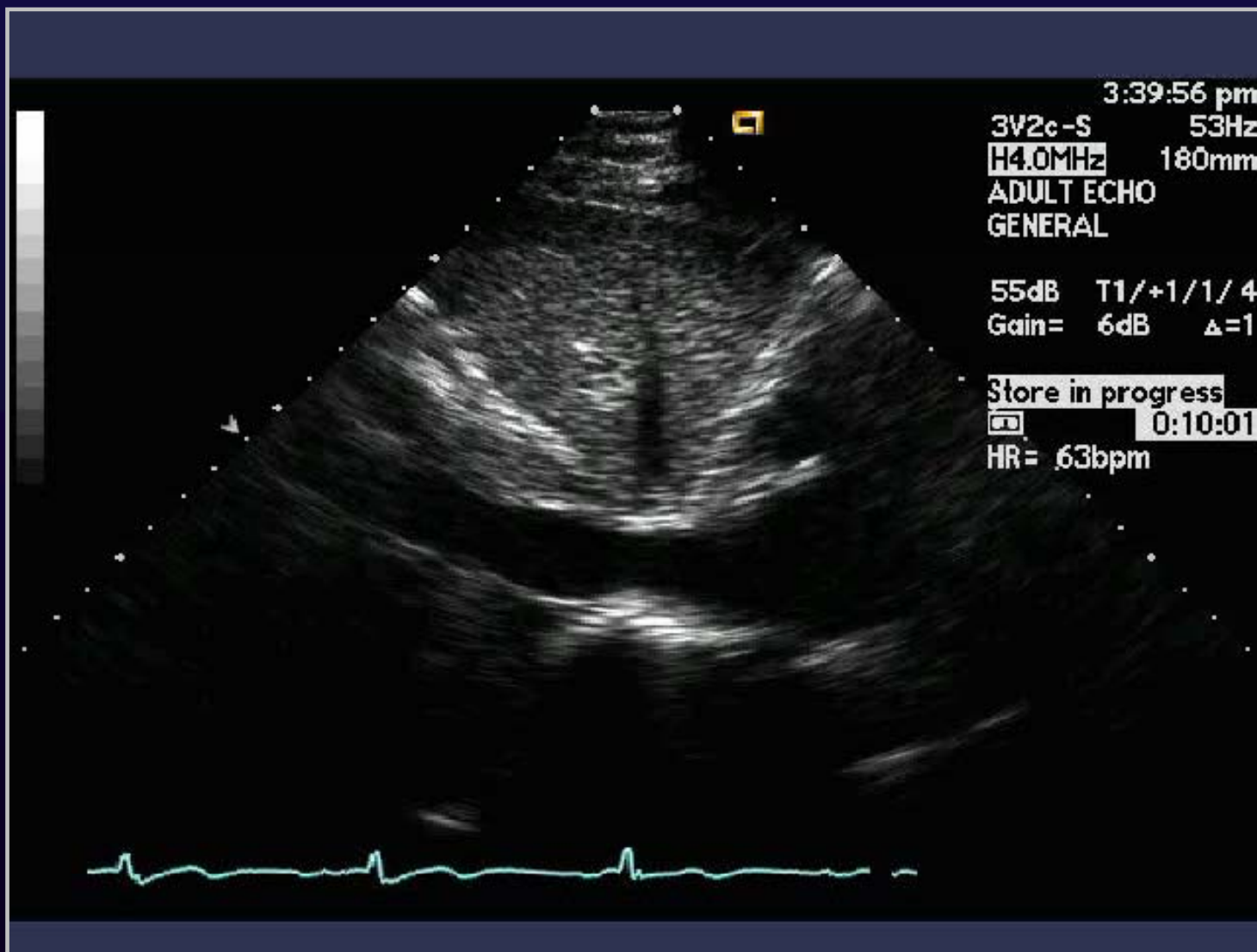
- ↓ intrathoracic pressure
- ↓ RA pressure
- ↑ return of blood to RA
- Caval emptying
 - Mean right atrial pressure
 - Chamber/vessel compliance

Inferior Vena Cava

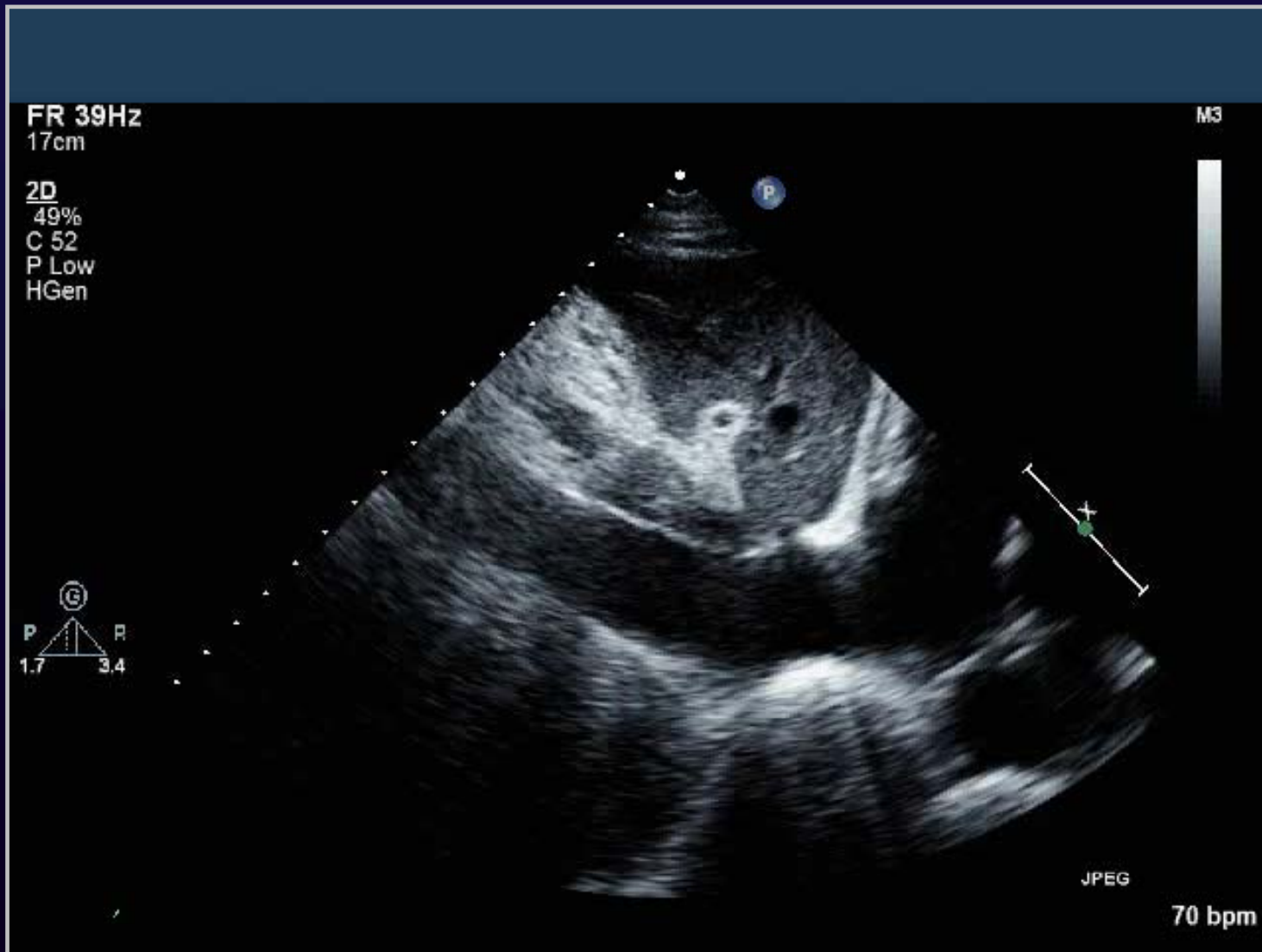
□ Inspiratory response & RA pressure

Diameter	Inspiratory collapse	RA pressure
< 1.7 cm	≥ 50 %	0-5 mm Hg
≥ 1.7 cm	≥ 50 %	6-10 mm Hg
≥ 1.7 cm	< 50 %	10-15 mm Hg
≥ 1.7 cm	0 %	> 15 mm Hg

Normal Respiratory Response of IVC



IVC Plethora



Case 1

□ 62 / M

- **C.C.:** abdominal distension and edema
- **P.I.**
 - 15 YA, hypertension
 - 7 YA, 4 YA, CVA로 한방병원에서 치료
 - 3 MA, depression으로 PSY에서 치료
 - 2 MA, abdominal distension & edema 발생
 - 인근 대학병원에서 work up
 - r/o chronic liver disease, pleural effusion, small amount of pericardial effusion
 - Diuretics 사용 후 azotemia 발생
 - Thoracentesis & paracentesis 시행하였으나 뚜렷한 원인 찾지 못하고 본원 응급실로 전원

Case 1

□ 62 / M

▪ P/E

• Neck

- LN enlargement(-) Palpation of cervical LN(-)
- Thyroid enlargement(-)

• Thorax

- Chest contour: ,normal Tenderness(-) Crackles(-)
- Wheezing(-) Heart beat: regular

• Abdomen

- **Abdominal contour: distended** Abdominal op scar(-)
- Abdominal tenderness(-) Abdominal rebound tenderness(-)
- Palpable liver(-) Palpable spleen(-)
- Abdominal palpable mass(-) **Fluid wave(+)**

• Back & Extremity

- CVA tenderness(-) Palmar erythema(-)
- **Pretibial pitting edema(+)** **Rt leg(++)** **Lt leg(++)**

Case 1

□ 62 / M

▪ Lab

- Hb: 13.2 g/dL, **WBC: 10,800 / mm³**, plt: 402K / mm³
- **PT: 53.5% (INR 1.40)**, aPTT: 29.9 sec
- **BUN / Cr: 23 / 1.5 mg/dL**, uric a: 7.1 mg/dL
- **AST / ALT: 458 / 251 IU/L**
- Prot / Alb: 6.8 / 3.7 g/dL
- **Bilirubin (T/D): 2.9 / 0.9 mg/dL**
- Amylase / lipase: 41 / 25 U/L
- Na-K-Cl: 139-3.9-99 mmol/L

Case 1

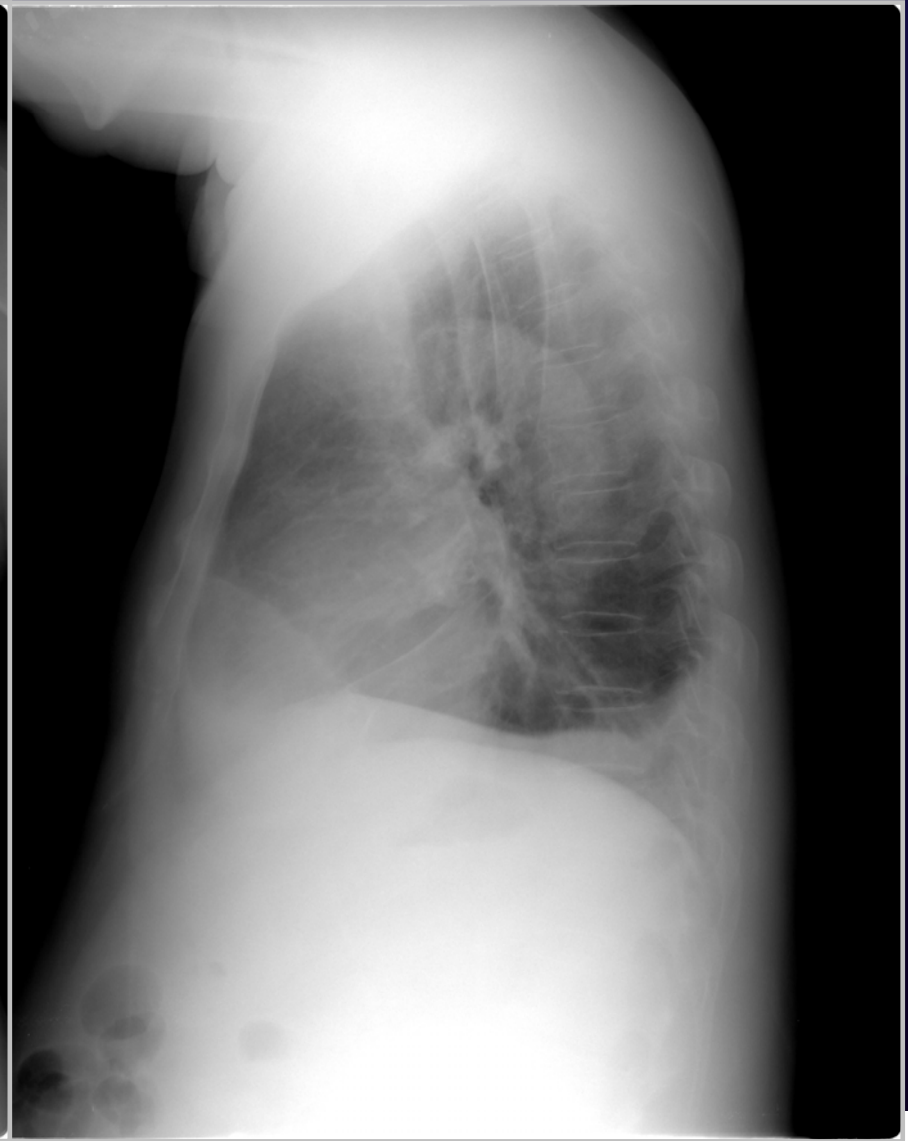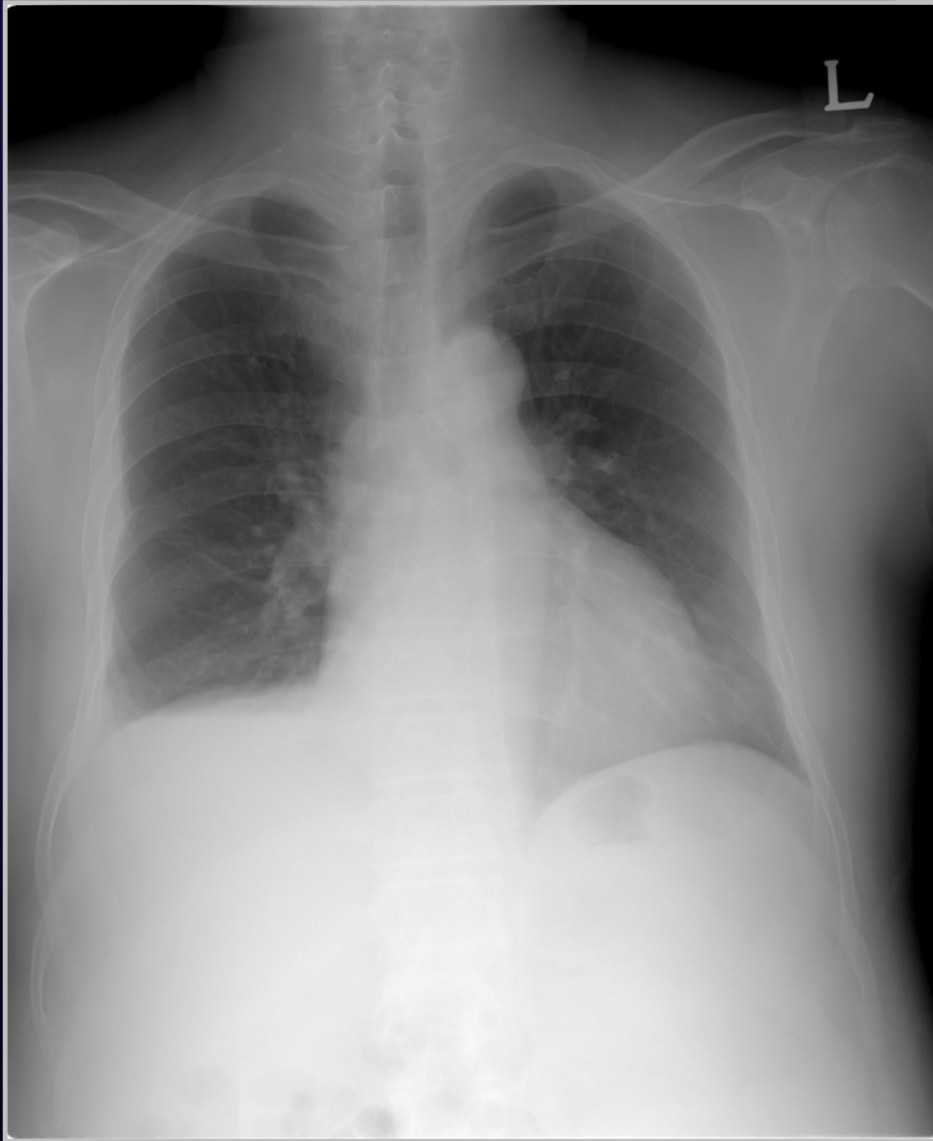
□ 62 / M

▪ Ascites

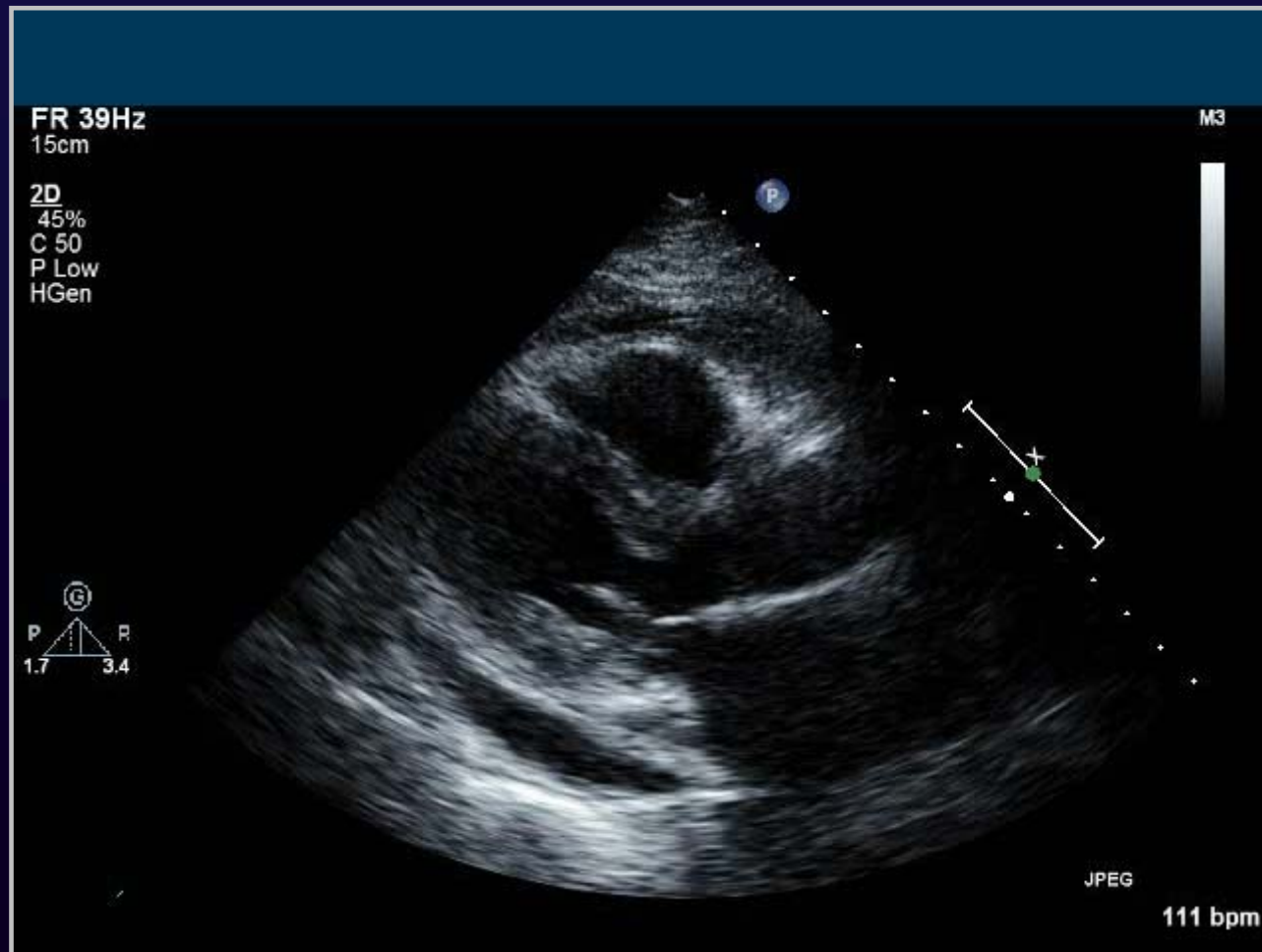
- TG: 77 mg/dL
- **Prot / Alb: 4.3 / 2.6 g/dL**
- Glucose: 121 mg/dL
- LD: 168

- AFB smear/culture: negative
- Cytology: no malignant cell

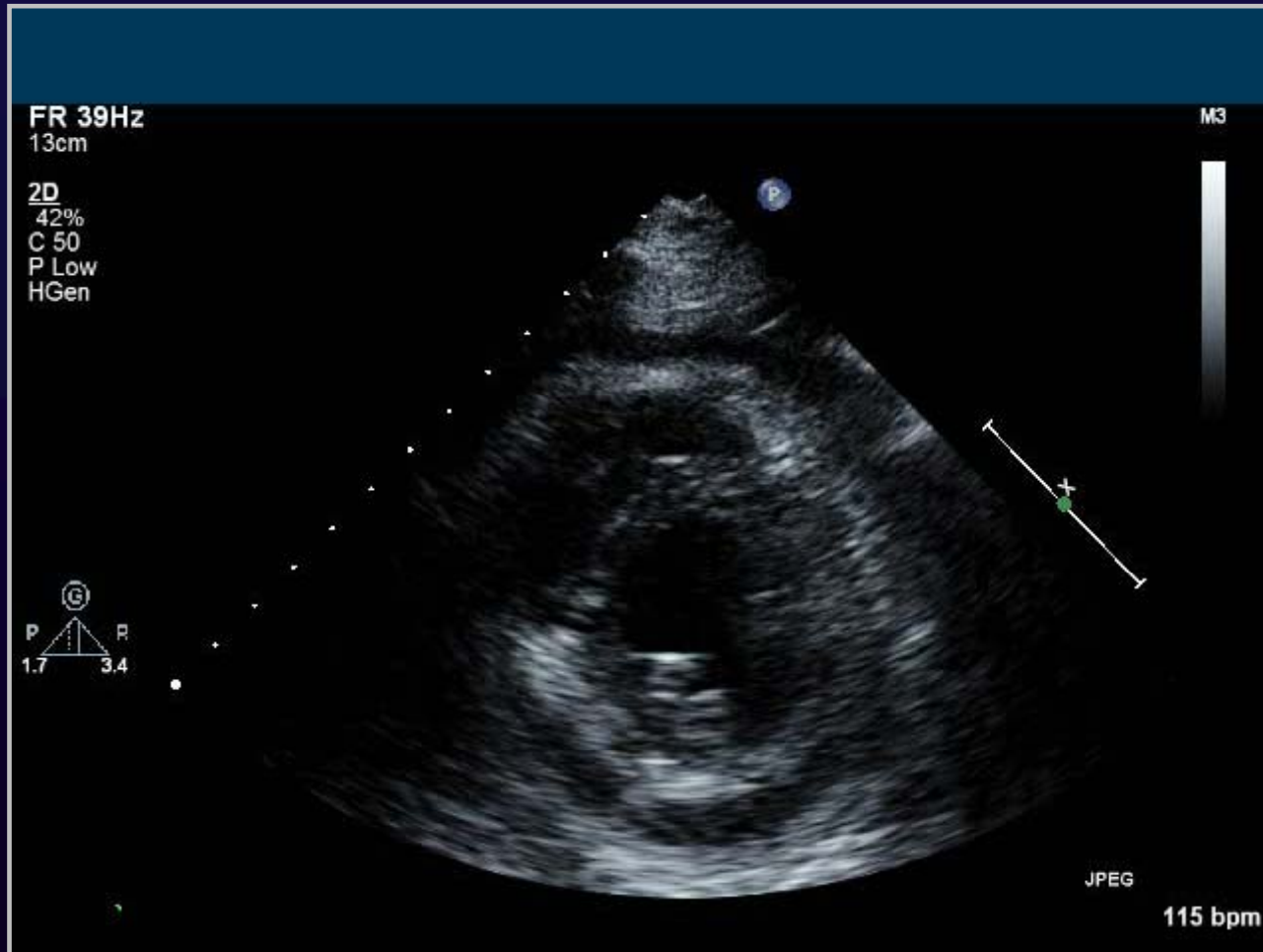Case 1



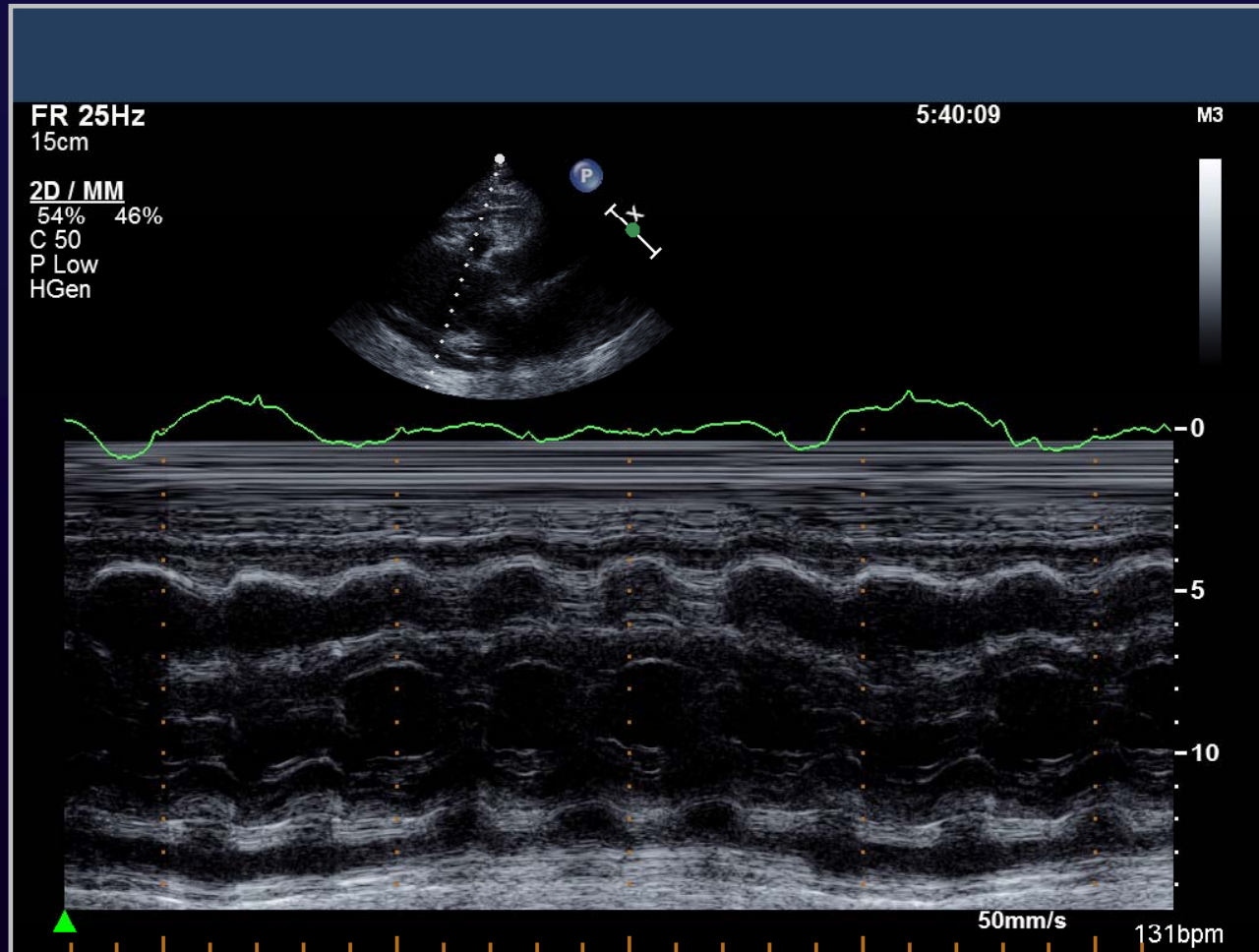
Case 1



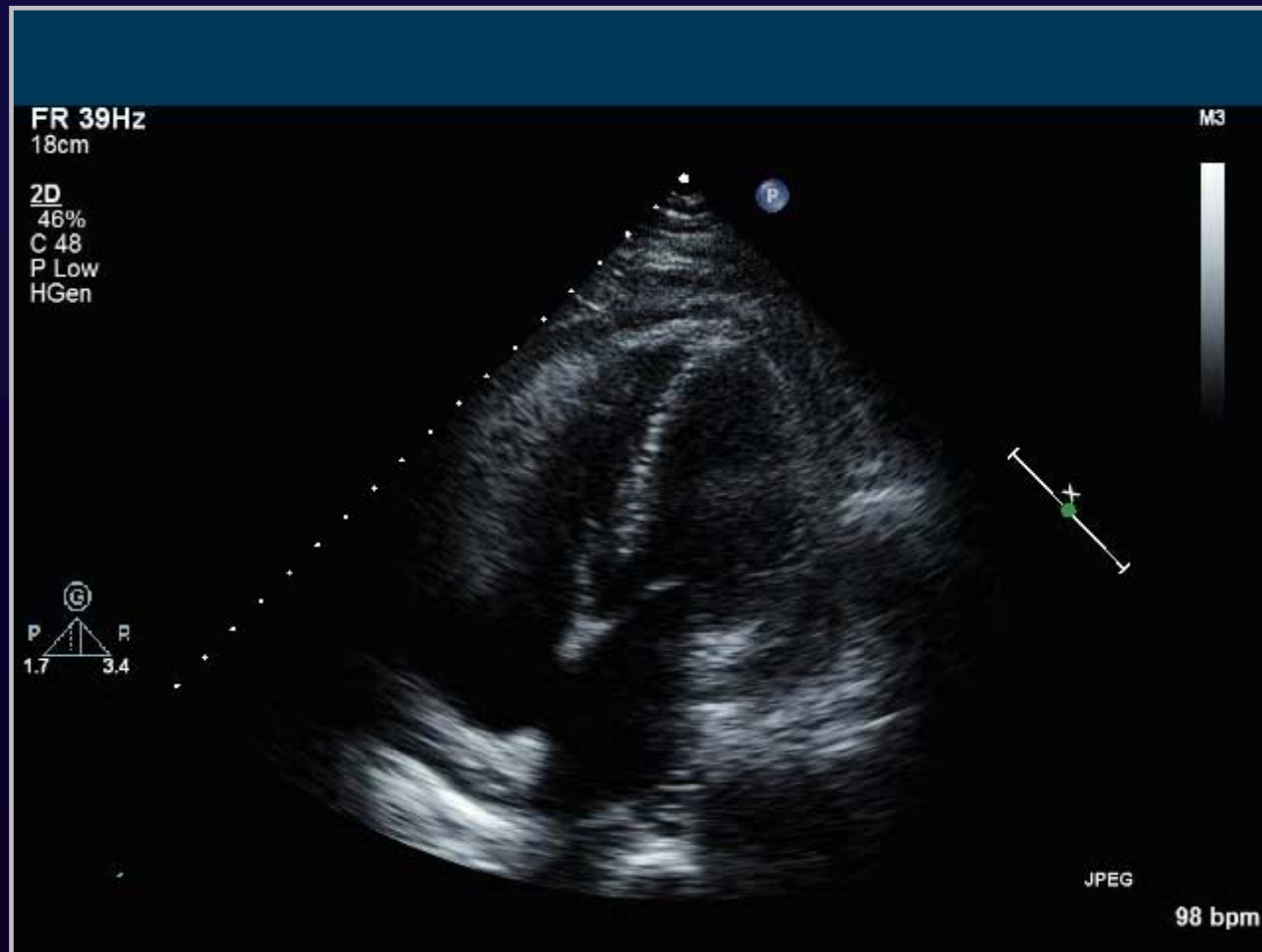Case 1



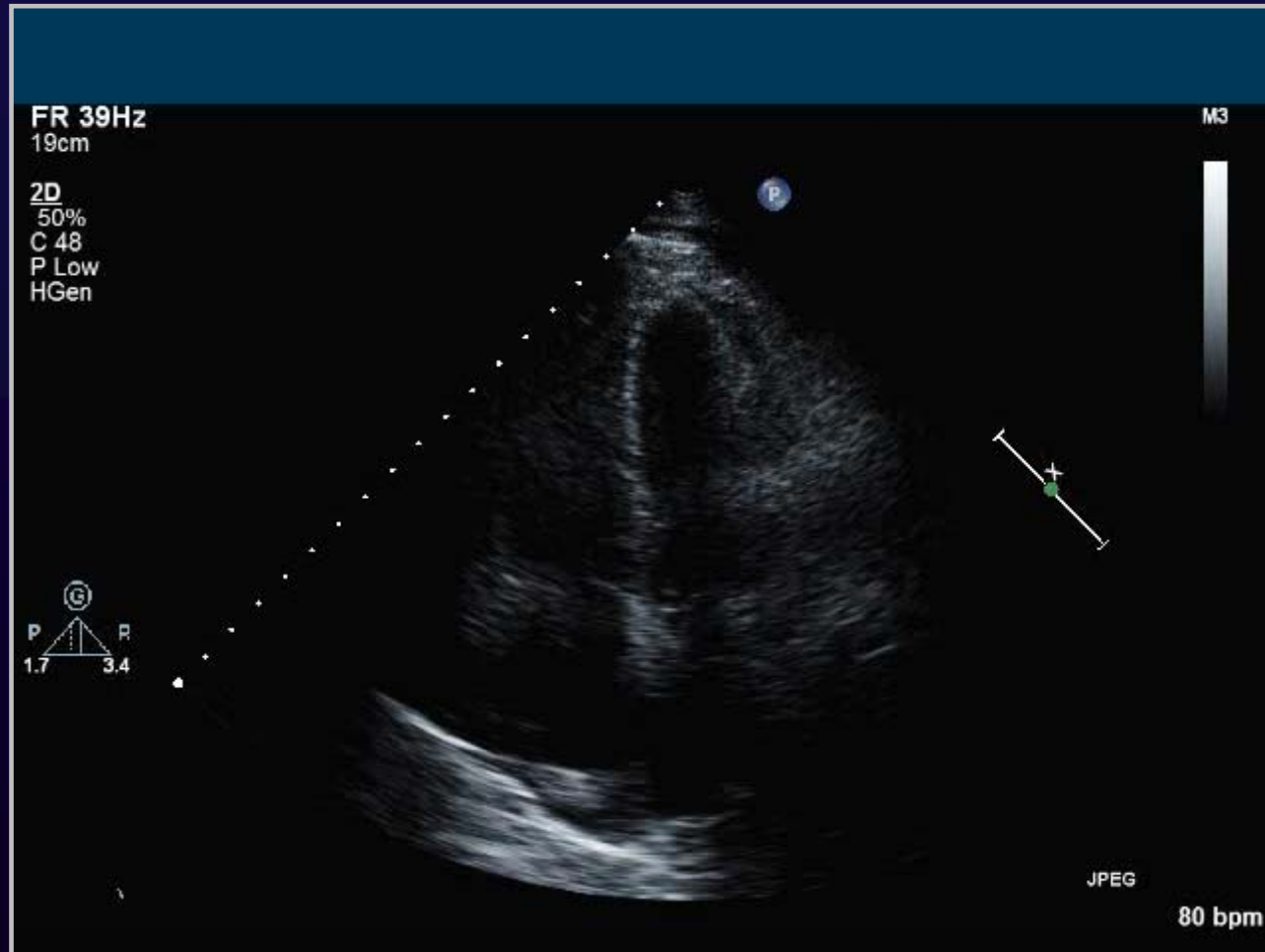
Case 1



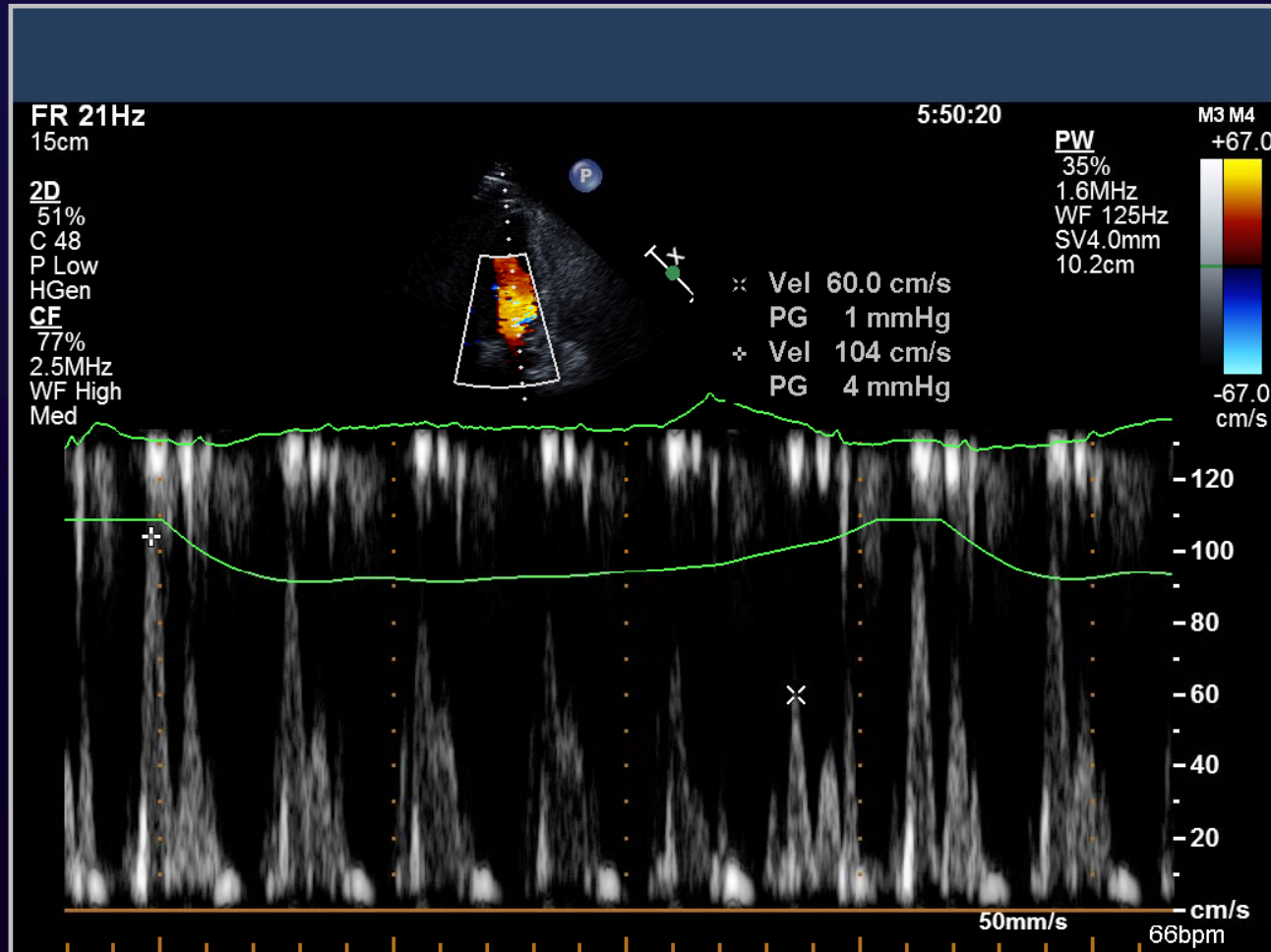
Case 1



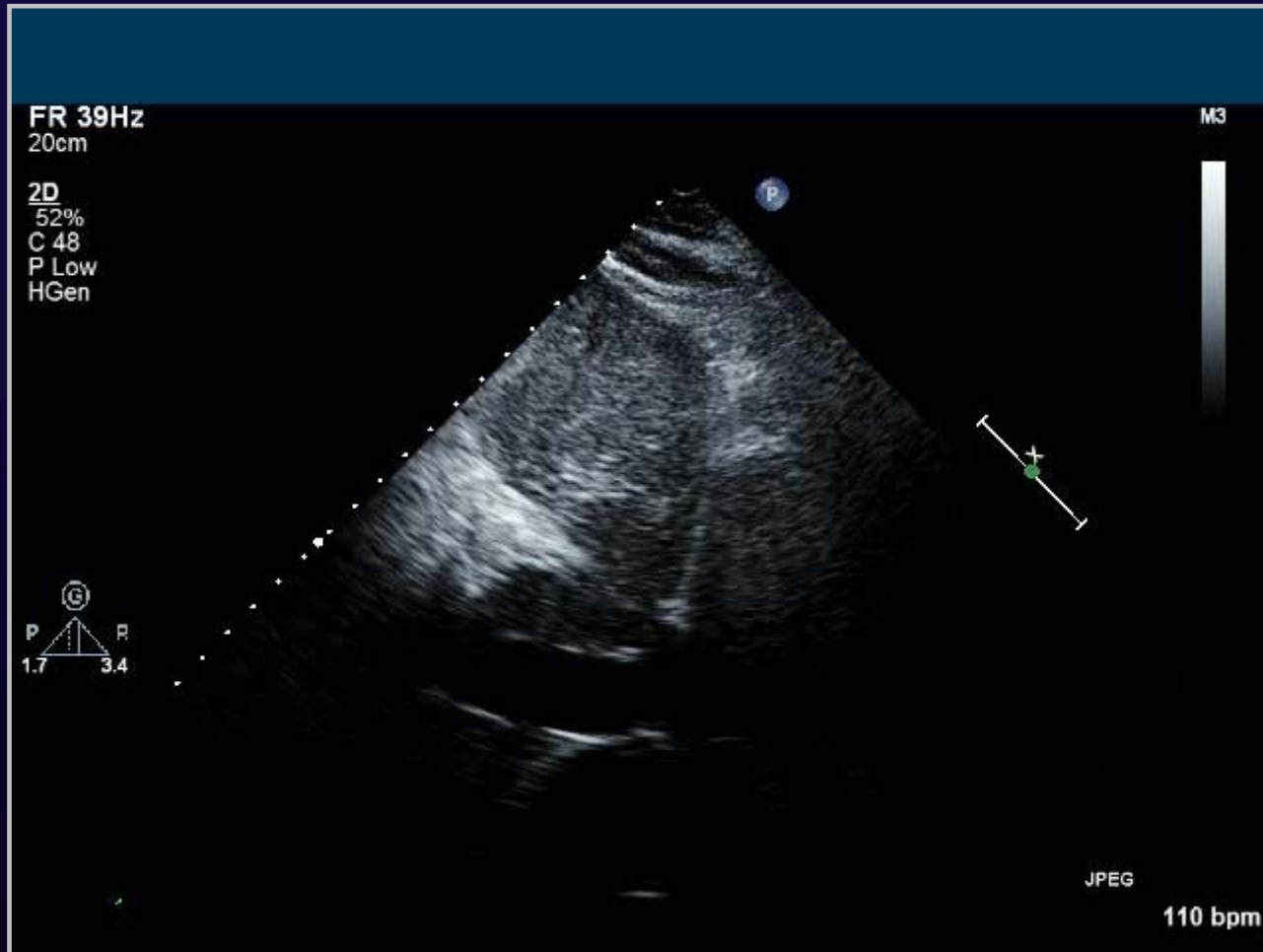
Case 1



Case 1



Case 1



Case 2

□ 42 / F

- **C.C.:** dyspnea and edema
- **P.I.**
 - 1년간 경구피임약 복용
 - 3 MA 생리가 없고 입맛이 없어 임신 여부 알기 위해 산부인과 방문, 초음파 상 myoma 발견
 - 2 MA DOE NYHA Fc II 발생
 - 1 MA lower extremity pitting edema 발생

Case 2

□ 42 / F

▪ P/E

- Mouth
 - Tongue ulcer(-)
- Throat
 - Tonsillar enlargement(-)
- Neck
 - Lymph nodes, palpable(-)
- Thorax
 - Chest dullness(-)
 - RHB without m, VBS without crackle
- Back & Extremity
 - CVA tenderness(-) Palmar erythema(-)
 - **Pretibial pitting edema(+)** **Rt leg(+)** **Lt leg(+)**

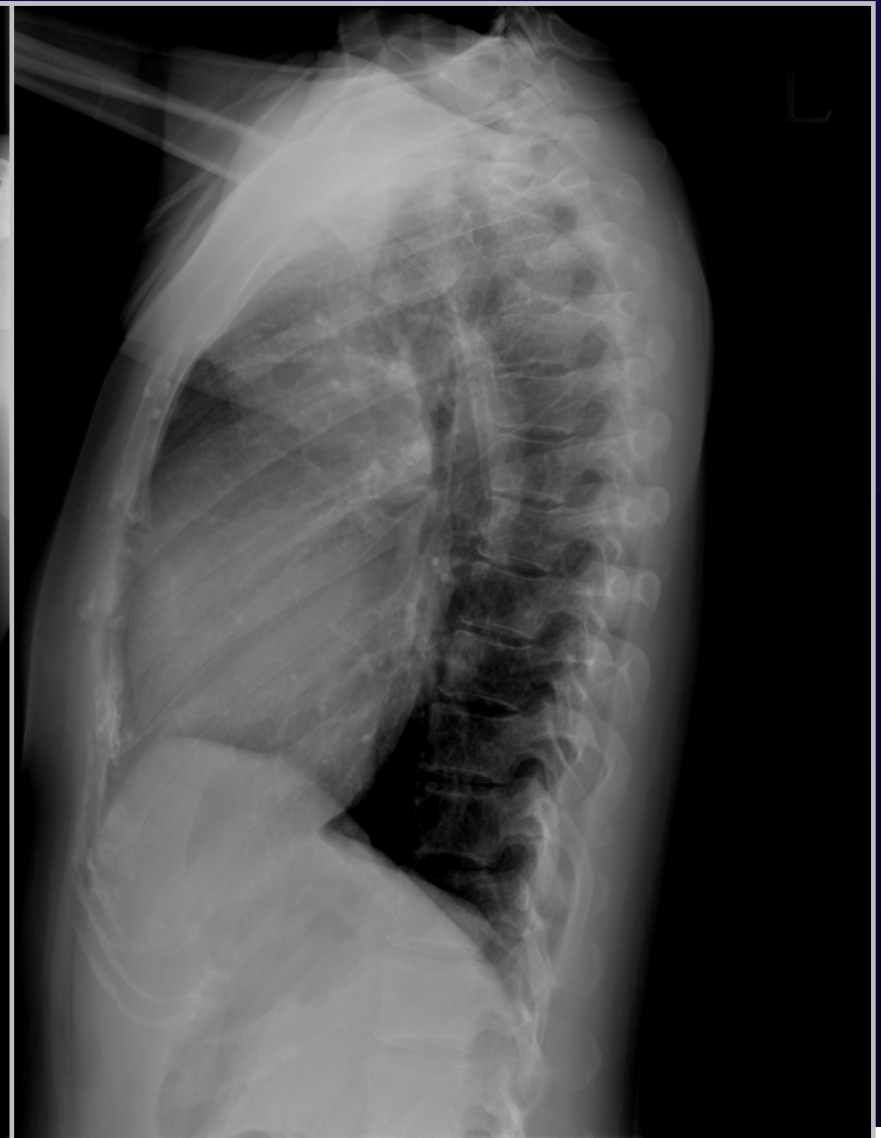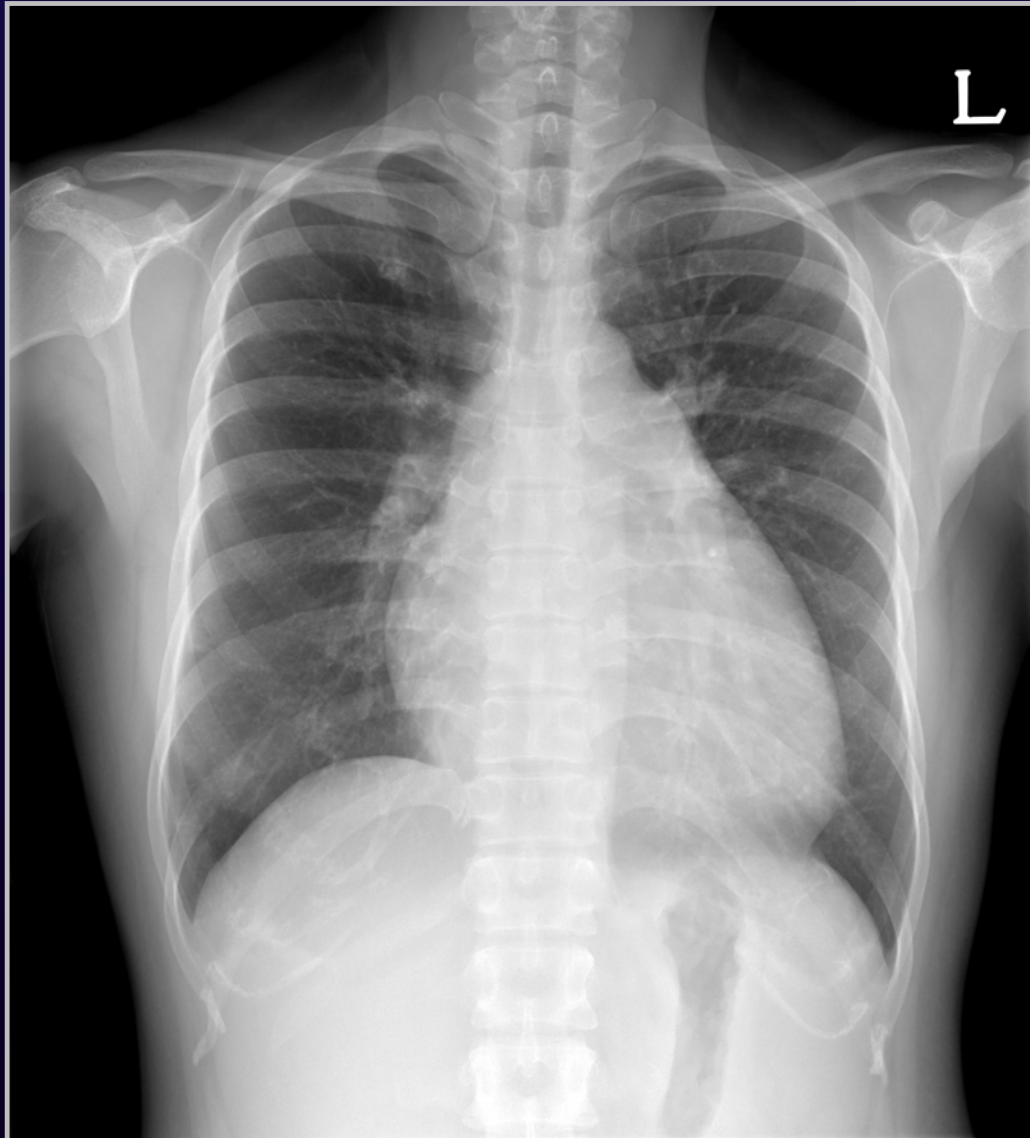
Case 2

□ 42 / F

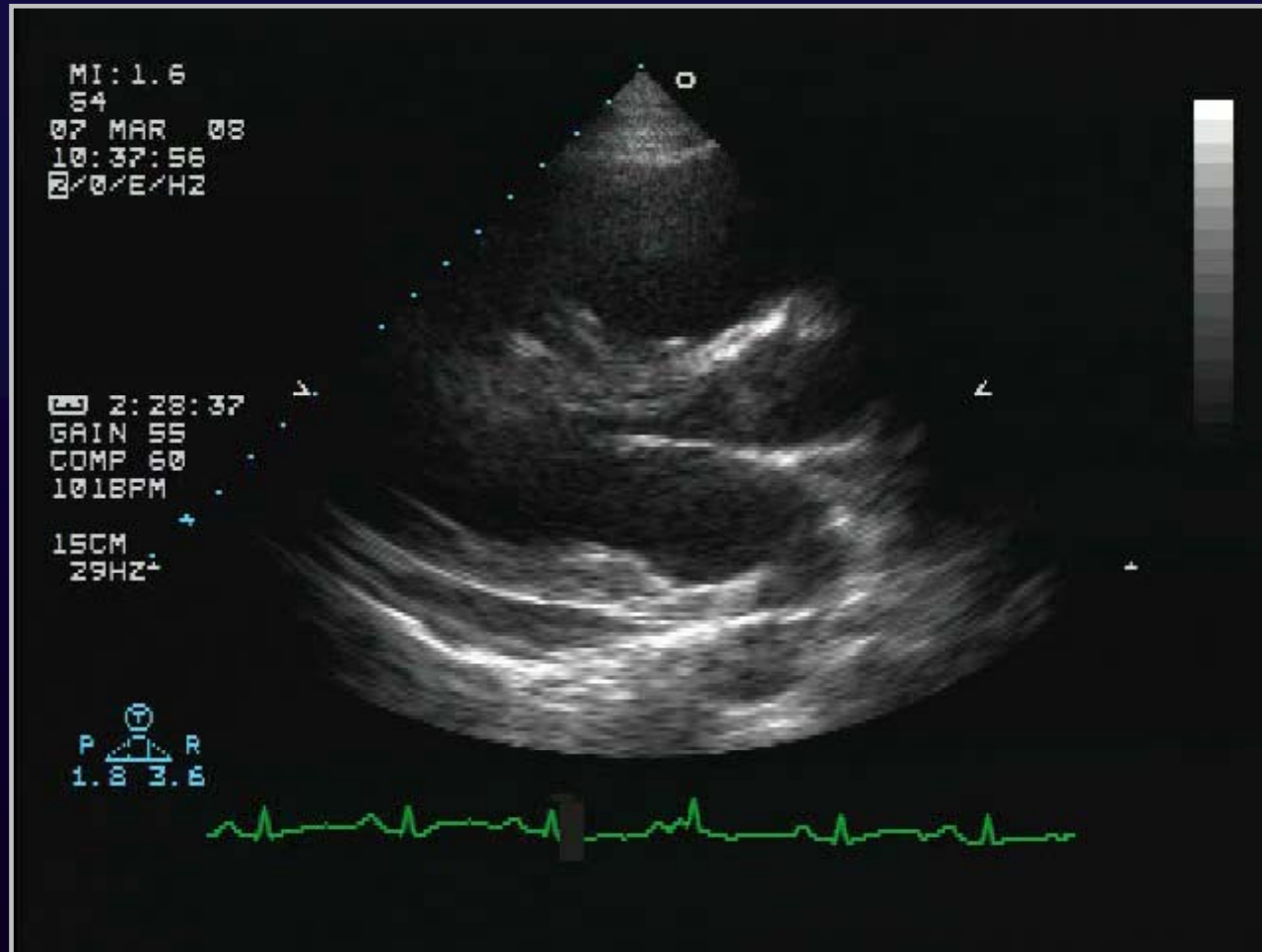
▪ Lab

- Glucose: 86 mg/dL
- BUN / Creatinine: 18 / 0.9 mg/dL
- Protein / Albumin: 6.2 / 3.7 g/dL
- AST (SGOT): 21 IU/L
- Bilirubin,direct: 0.7 mg/dL
- Na-K-Cl: 140-4.9-107 mmol/L;
- PT (INR) 52.7 % (1.36)
- activated PTT 29.2 sec

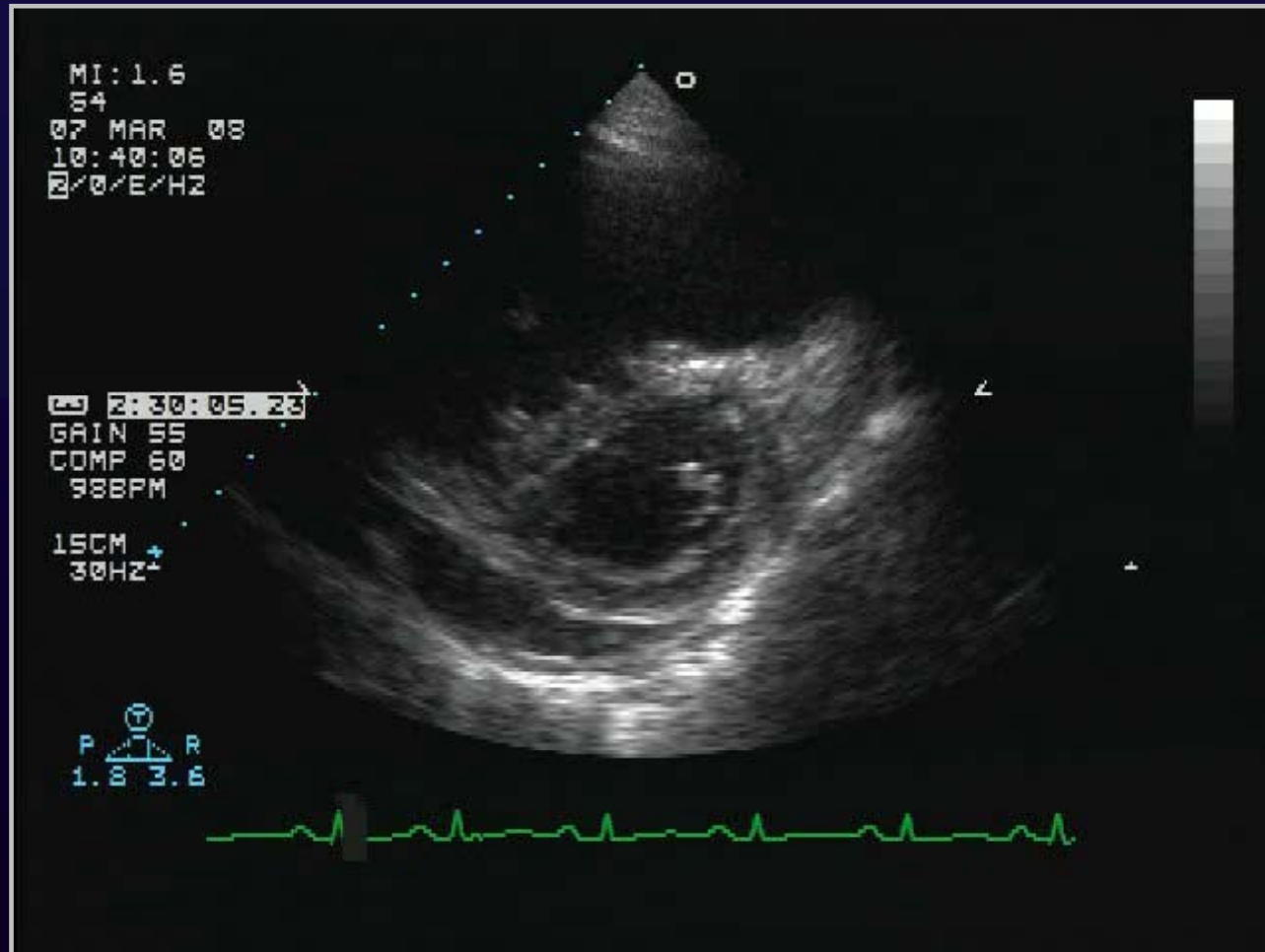
Case 2



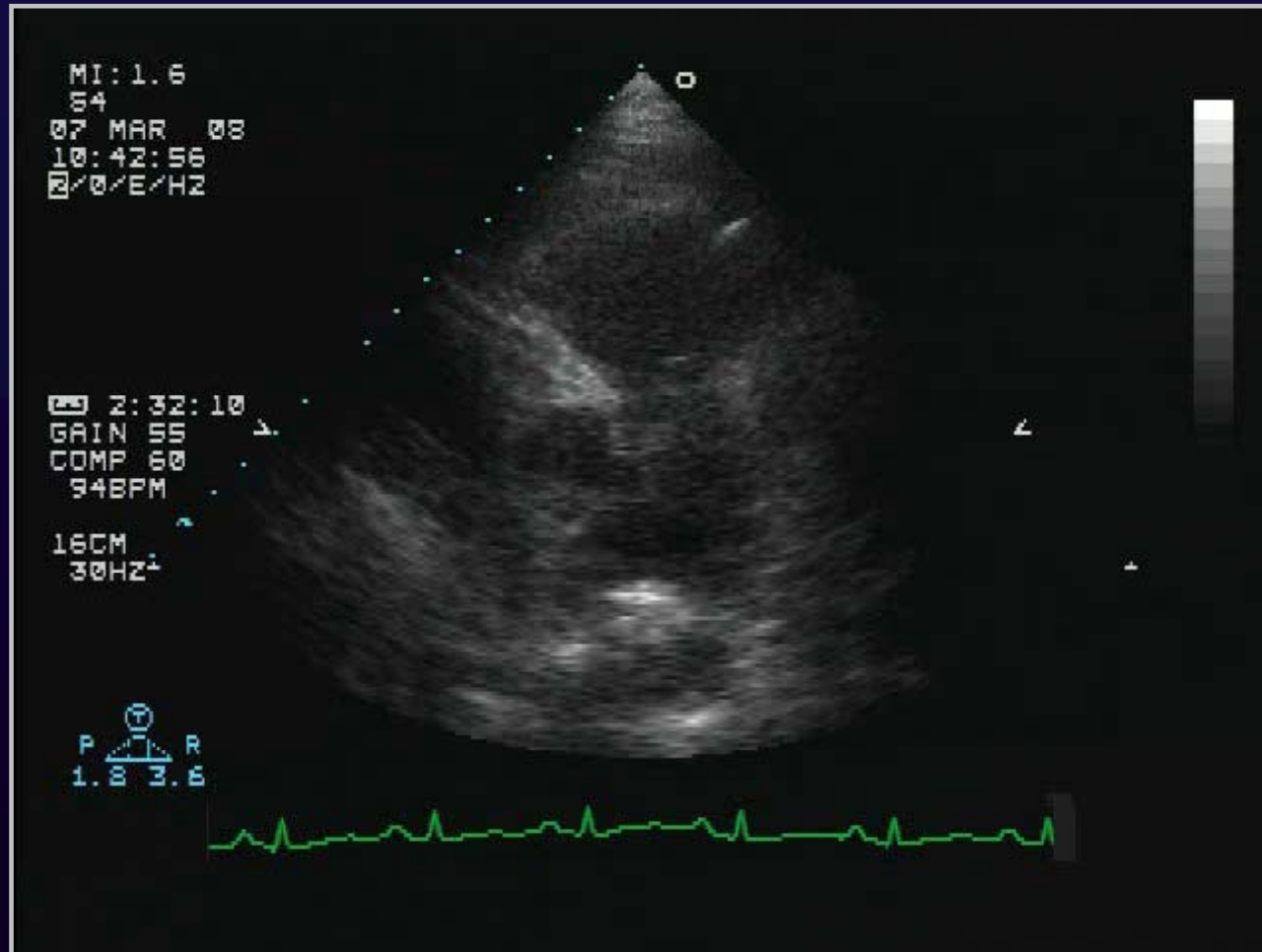
Case 2



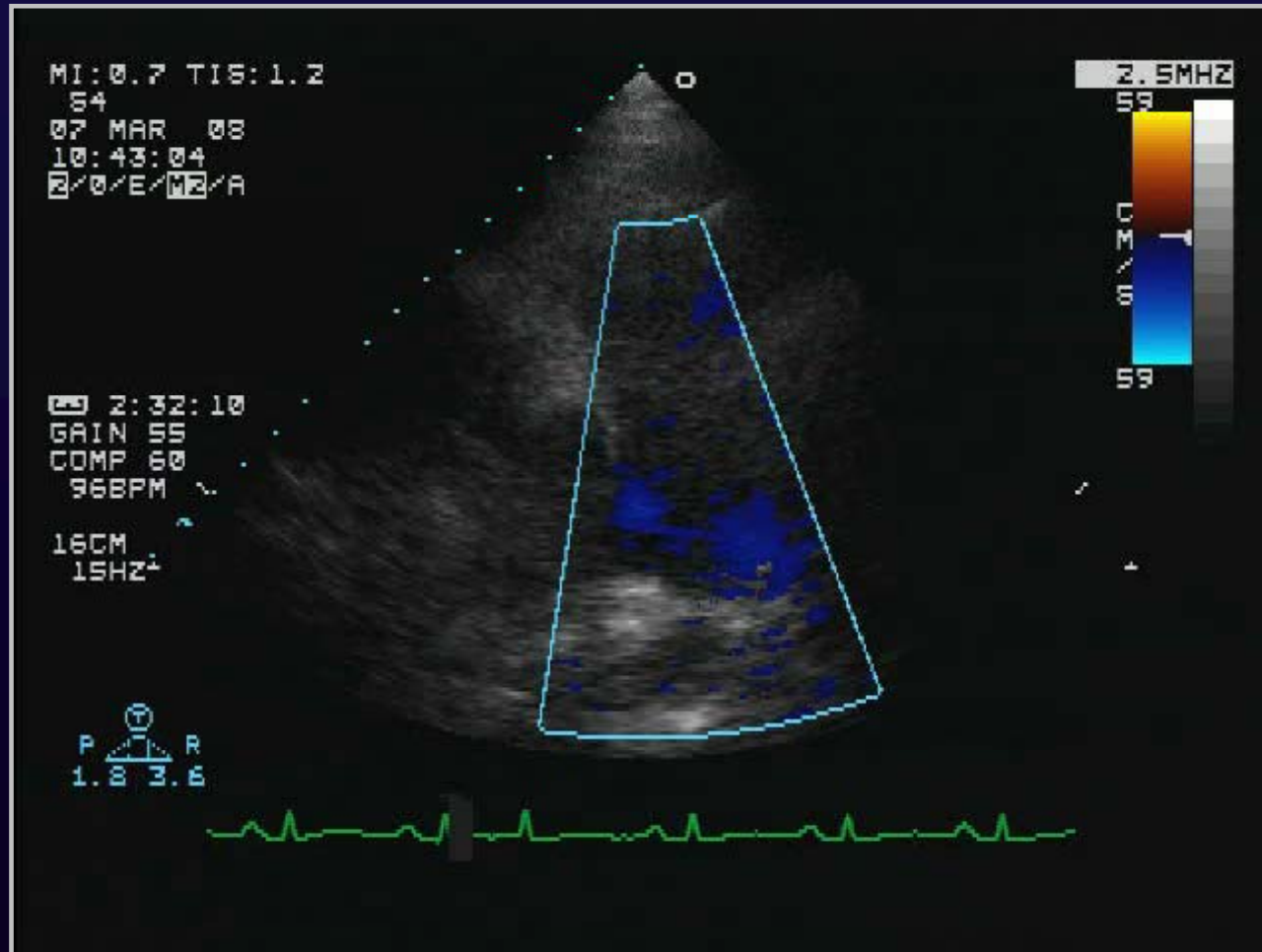
Case 2



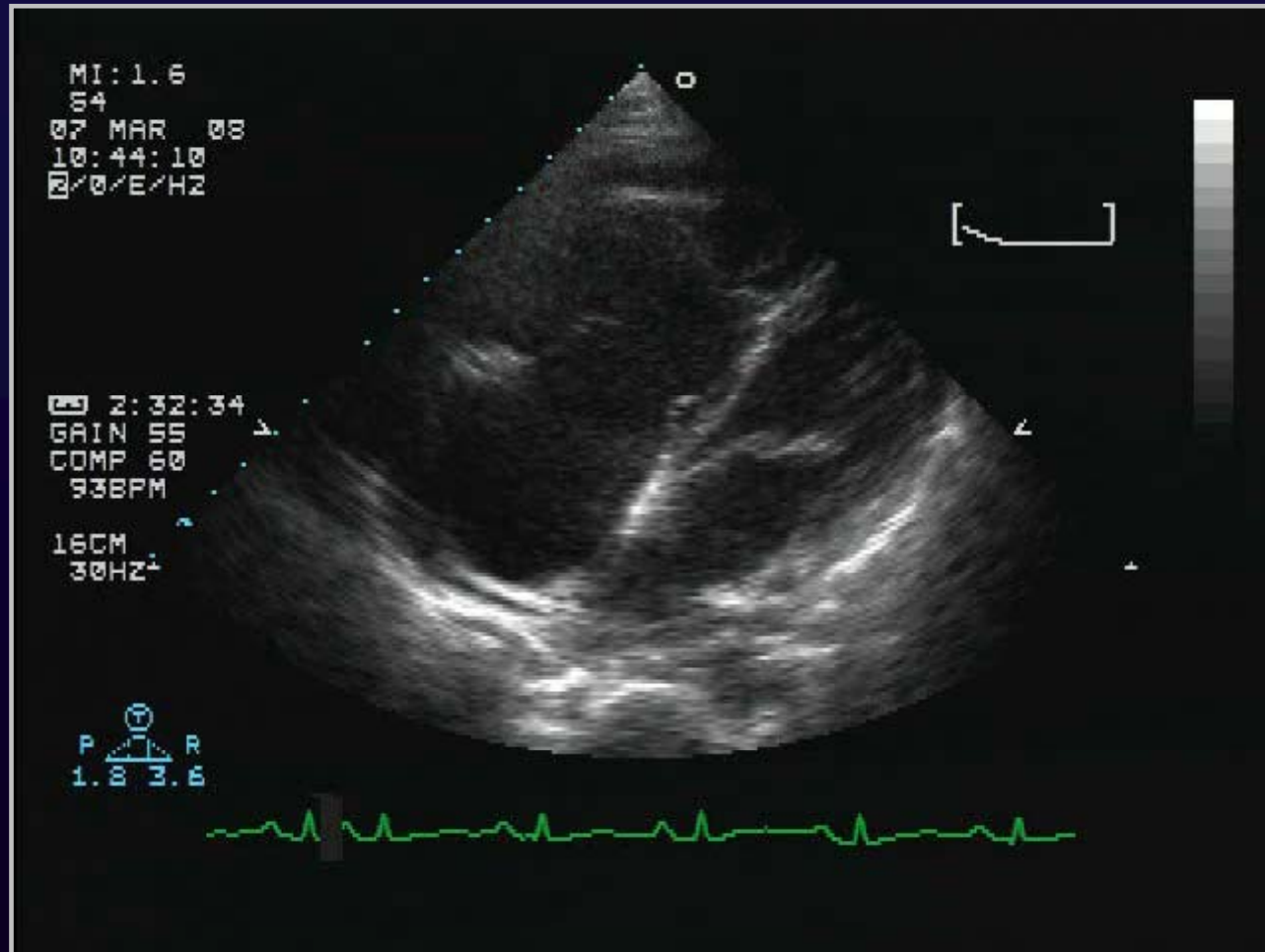
Case 2



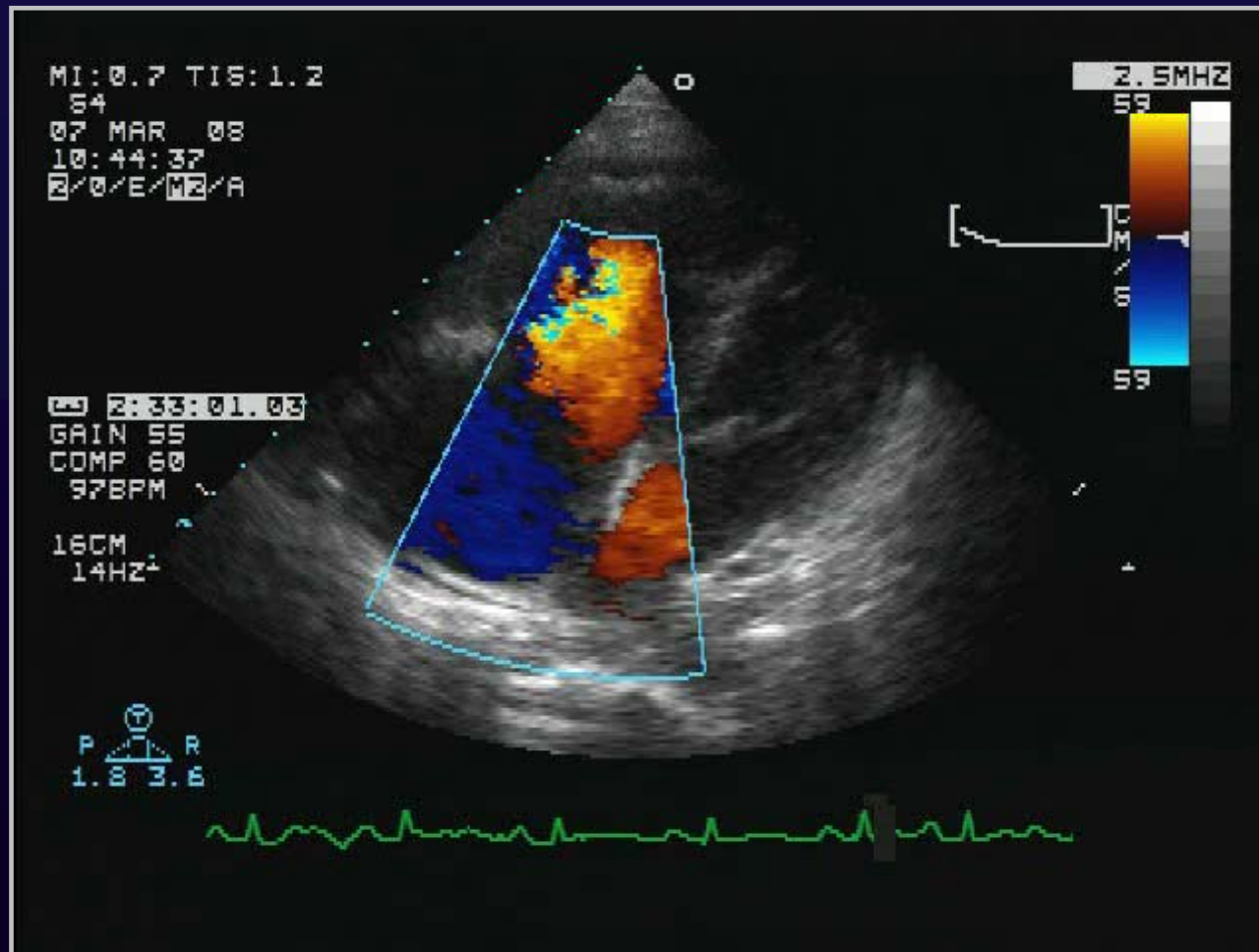
Case 2



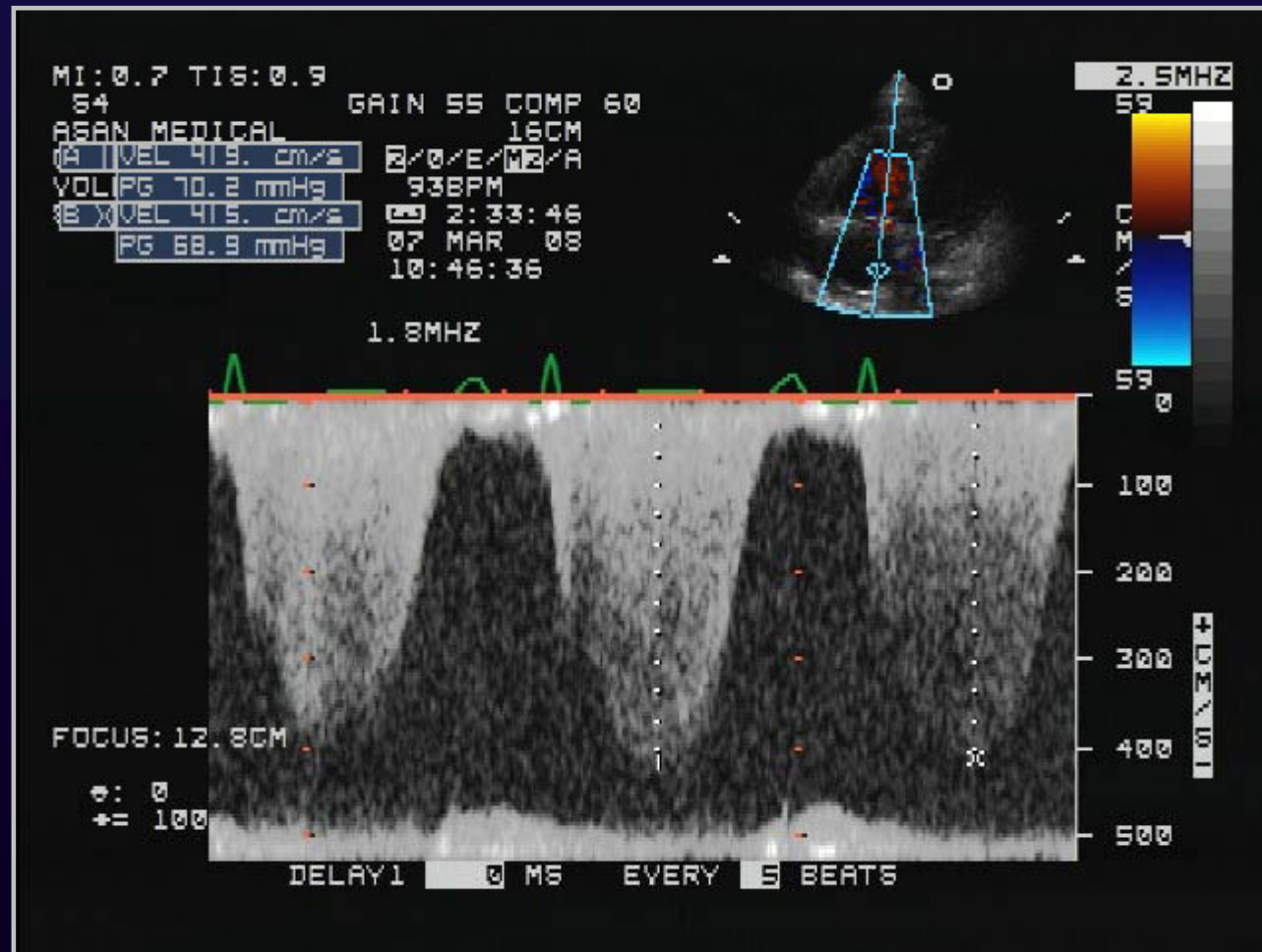
Case 2



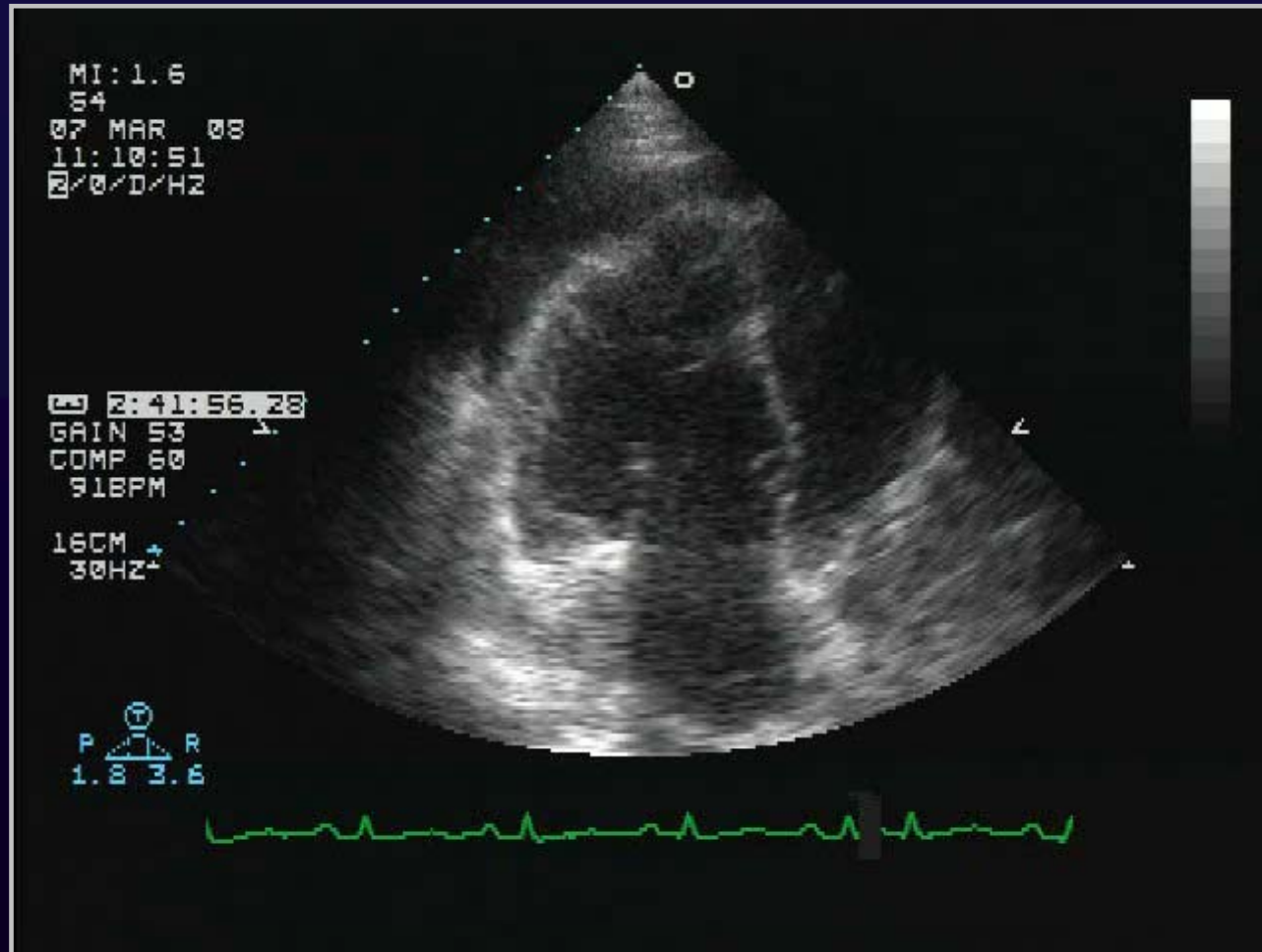
Case 2



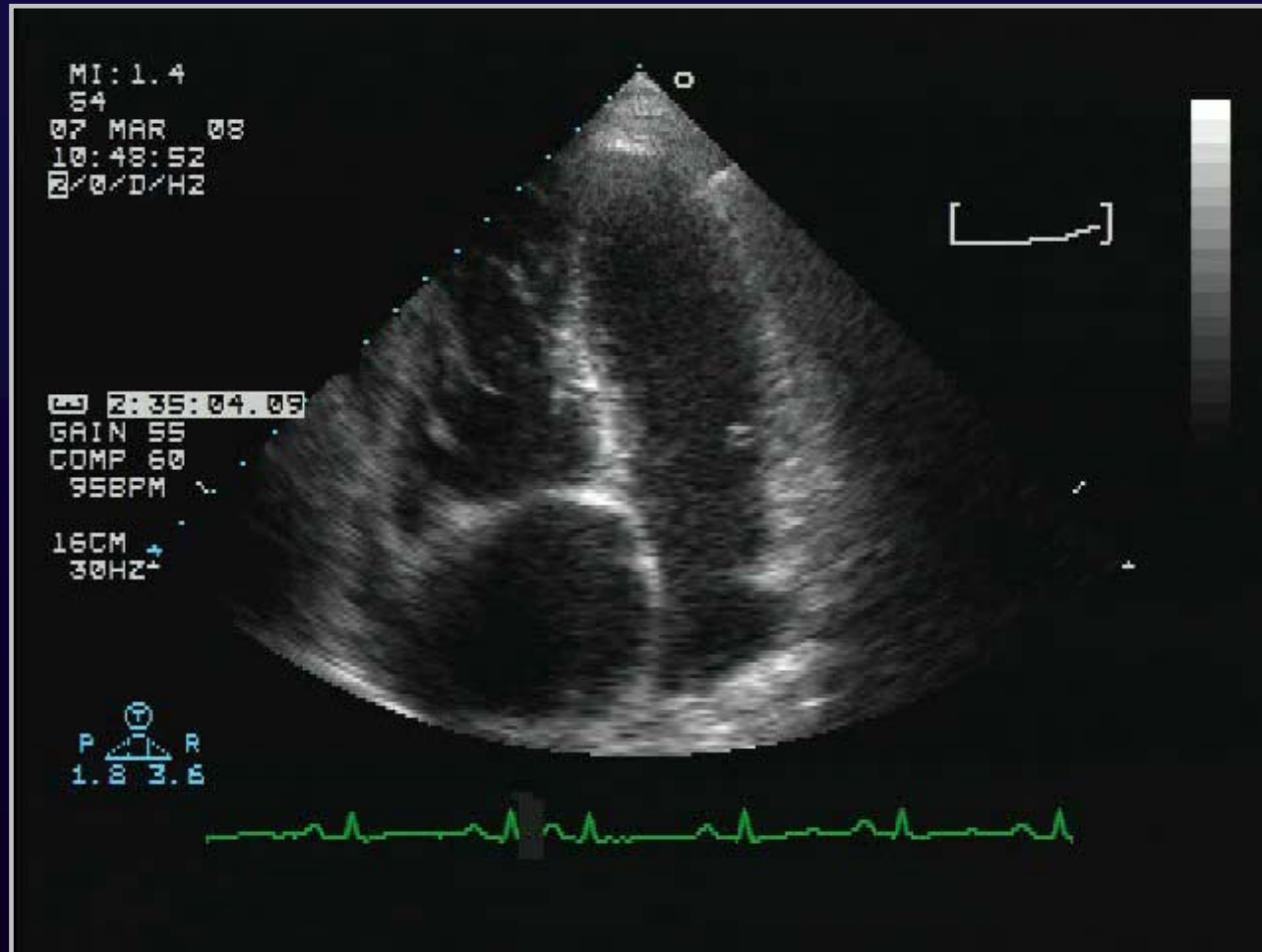
Case 2



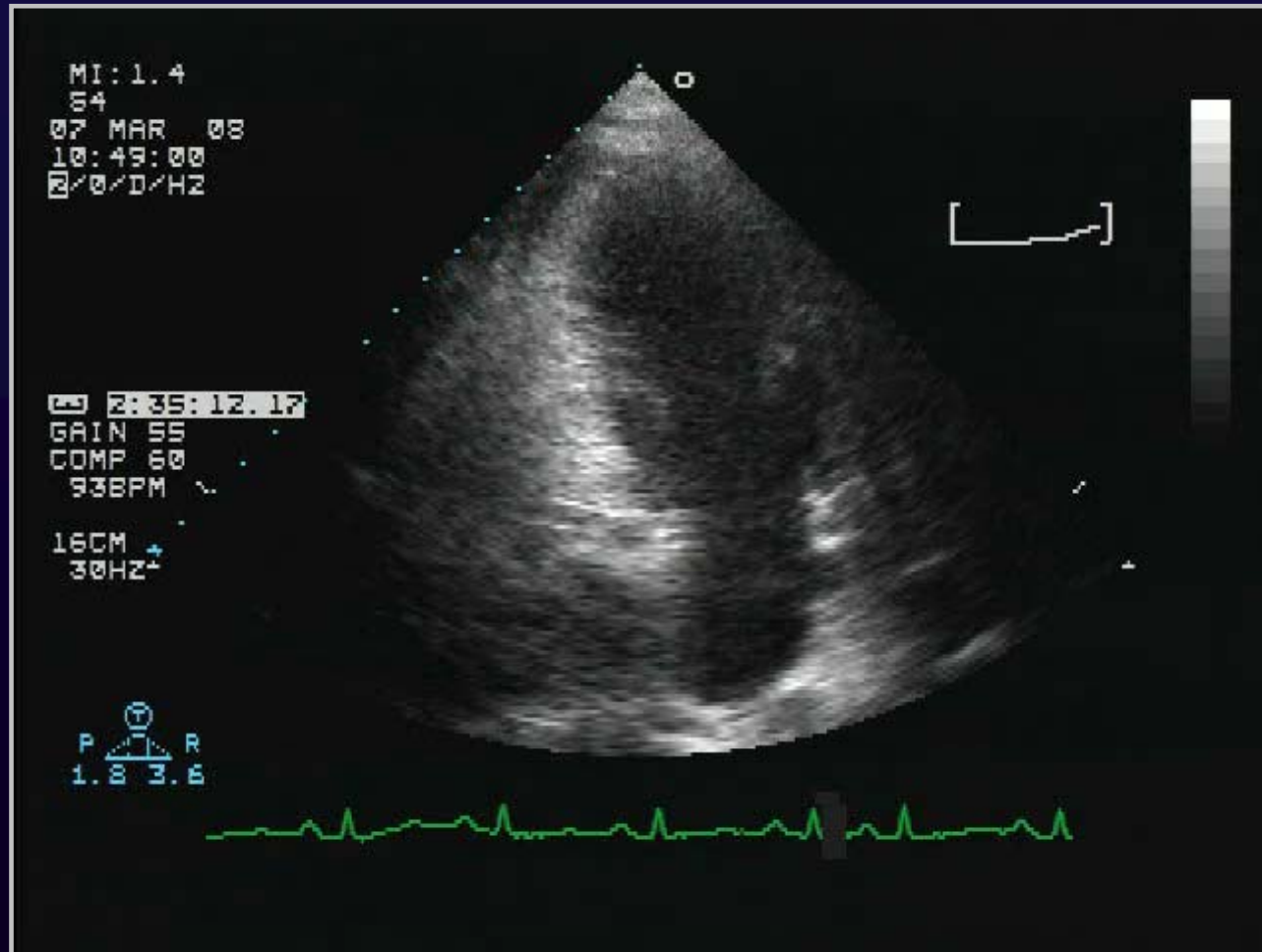
Case 2



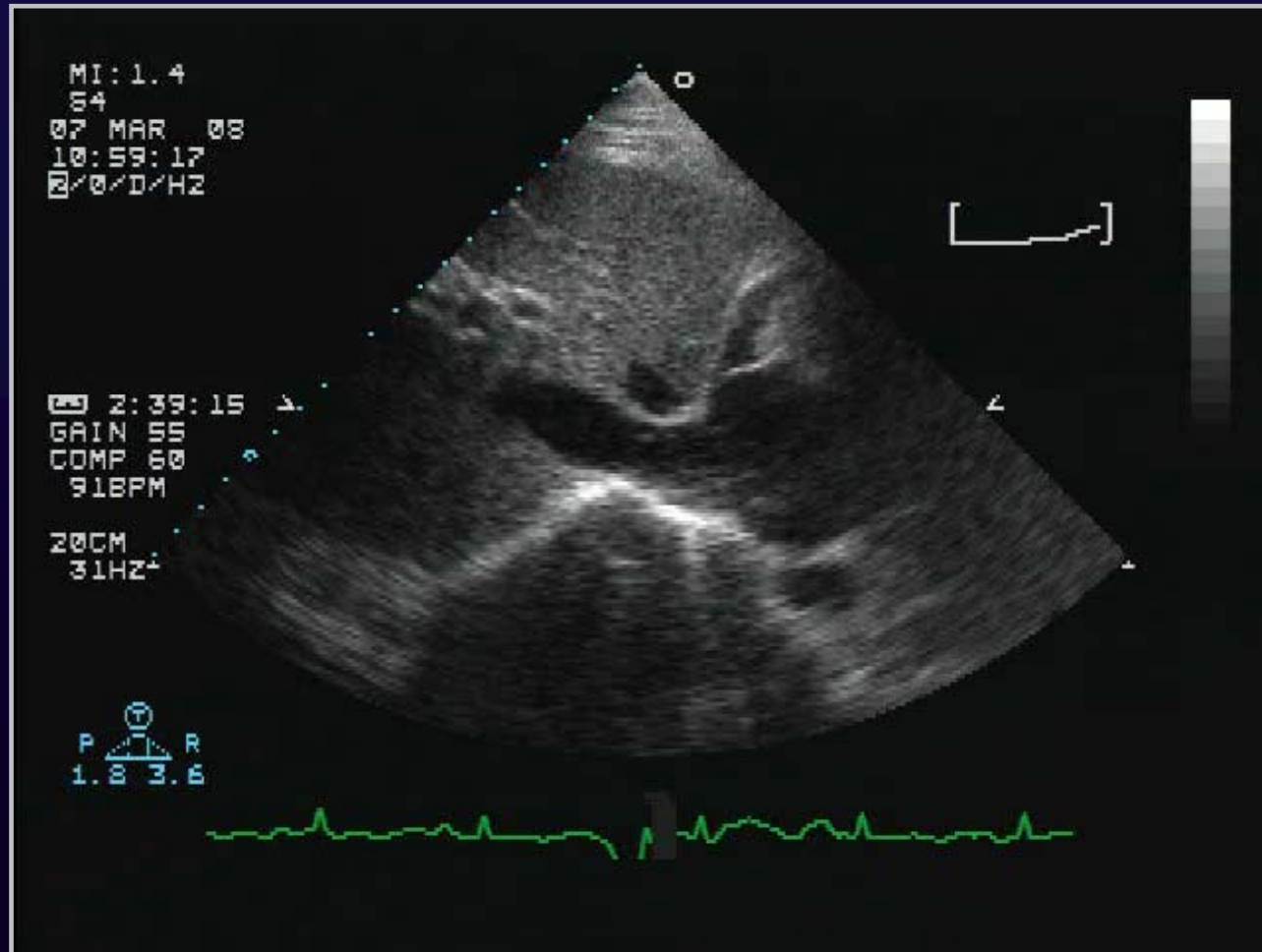
Case 2



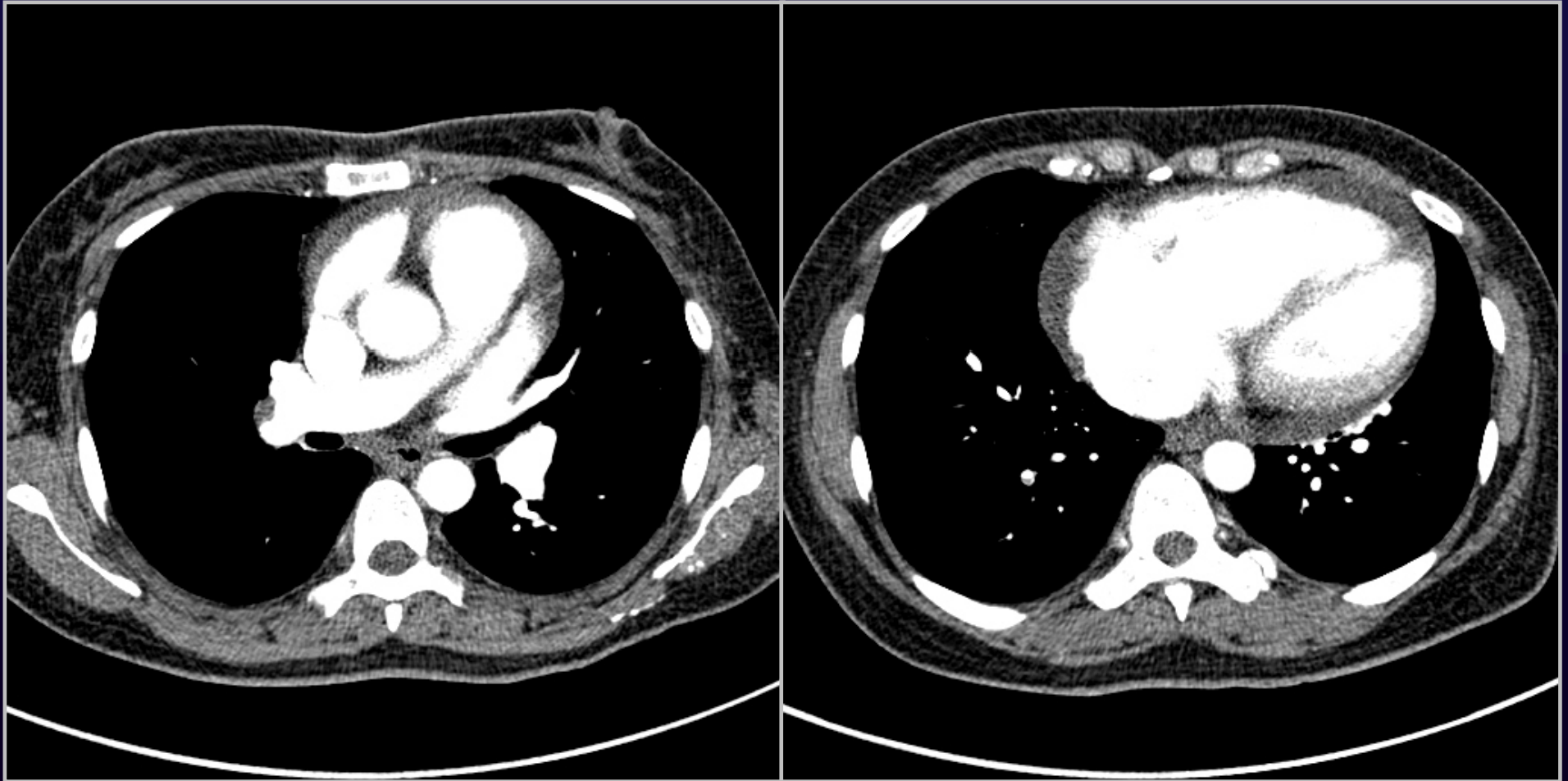
Case 2



Case 2



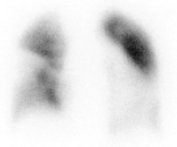Case 2



Case 2

Patient Name: SHIM, SOON JEONG, F42 Patient ID: 36242795 Study Name: Lung*Perfusion Scan
Study Date: 3/15/2008

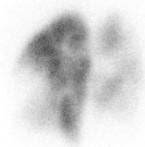Lung Perfusion Scan
99mTc-MAA



ANT



LAO




LPO



POST



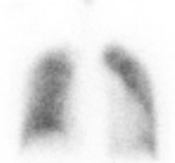RPO



RAO

Patient Name: SHIM, SOON JEONG, F42 Patient ID: 36242795 Study Name: Lung*Perfusion Scan
Study Date: 3/15/2008

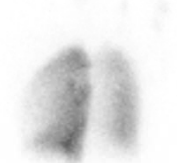Lung Inhalation Scan
Perthechnegas



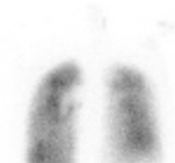ANT



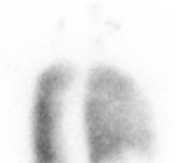LAO



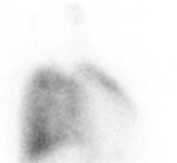LPO



POST



RPO



RAO

Cardiac Causes of Edema

□ **RV dysfunction**

- Acute pulmonary embolism
- Cor pulmonale
- Eisenmenger syndrome
- Primary pulmonary HT
- Arrhythmogenic RV dysplasia

□ **Constrictive pericarditis**

□ **Cardiac tamponade**

□ **Tricuspid valve diseases**

- Severe TR
- TS

Thank you for your attention!

