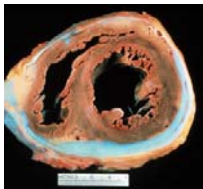




Constrictive Pericarditis: Diagnosis and Management 2016

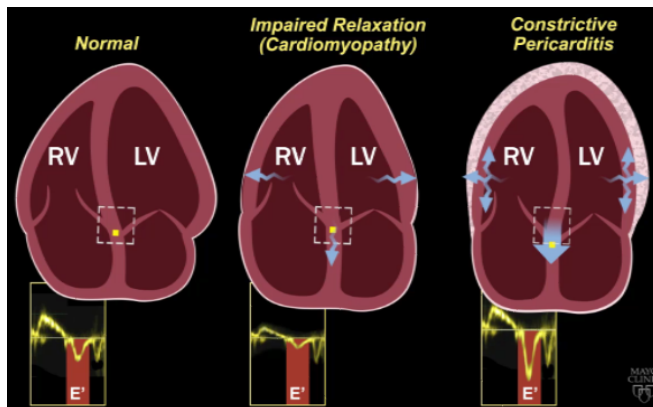
Jae K. Oh, MD

Constrictive pericarditis is a potentially curable condition caused by a variety of situations which result in inflamed, scarred, thickened, or calcified pericardium. (Figure)



When the abnormal pericardium limits diastolic filling, there are a series of hemodynamic consequences which manifest as fatigue, dyspnea, abdominal bloating, peripheral edema, or right heart failure. These clinical manifestations of constrictive pericarditis are similar to those due to a cardiomyopathy. Since their hemodynamic and clinical features are similar, it is often challenging to distinguish constrictive pericarditis from a myocardial disease. Even the traditional invasive hemodynamic criteria of "equalization of end-diastolic pressures" is not specific for constrictive pericarditis. Despite many similarities between myocardial and pericardial diseases, there are several unique features of constriction that allow a reliable diagnosis. *Those features are 1. Respiratory variation in ventricular filling 2. Interventricular dependence and 3. Augmented longitudinal motion of the heart. (1, 2)*

Respiratory variation in ventricular filling arises from the dissociation of intrathoracic and intracardiac pressure change and enhanced ventricular interaction in constrictive pericarditis. Inspiration reduces intrathoracic pressure which usually is fully transmitted to intracardiac pressures, but in constriction the intracardiac pressures falls much less than intrathoracic pressure because of the pericardial barrier. This difference in pressure change with inspiration results in reduced filling to left side of the heart. The reduction in left heart filling during inspiration causes a reduction in mitral inflow velocity and a shift of the interventricular septum toward the left ventricle. With expiration, left heart filling increases which



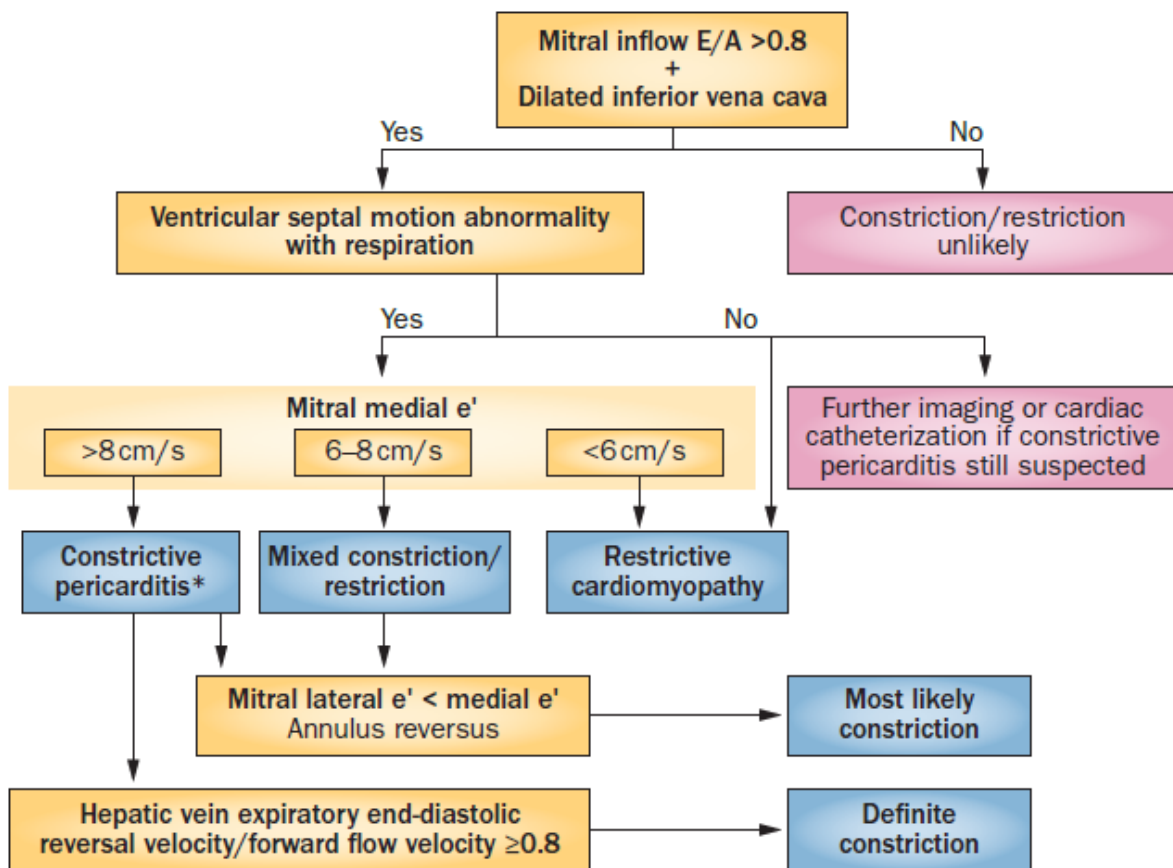
shifts the interventricular septum back toward the right ventricle, leading to reduced filling to right side of the heart and a late-diastolic reversal of flow in the hepatic veins.

The advent of tissue Doppler imaging has provided increased diagnostic confidence to separate constriction from a myocardial

disease. Tissue Doppler measures myocardial tissue velocity and provides a non-invasive evaluation of myocardial relaxation. The early diastolic mitral annular velocity (e') which reflects the status of LV myocardial relaxation is reduced in most forms of heart failure related to myocardial disease, including restrictive cardiomyopathy. The normal e' velocity from the medial mitral annulus is 9 cm/sec or greater, and it is usually 6cm/sec or less in patients with a myopathy. In contrast, e' is usually preserved or even increased in constrictive pericarditis since the lateral motion of the heart is limited by the constrictive pericardium. Furthermore, the medial mitral annular e' velocity is usually greater than the lateral mitral annular e' . This again stands in contrast to what is expected in other forms of heart failure, and may reflect tethering of the lateral annulus by the constrictive process.

Our group studied the test performance characteristics of these echocardiographic findings in a group of 130 patients with surgically confirmed constrictive pericarditis compared to 36 patients with restrictive cardiomyopathy or severe tricuspid regurgitation.(3) *Three variables were independently associated with constrictive pericarditis: 1) the presence of ventricular septal shift, 2) medial mitral e' velocity; and 3) the hepatic vein expiratory diastolic reversal ratio.* Each of these criteria was also significantly associated with constrictive pericarditis in the subset of patients with atrial fibrillation or flutter. The presence of ventricular septal shift in combination with either medial $e' \geq 9$ cm/s or hepatic vein expiratory diastolic reversal ratio ≥ 0.79 was 87% sensitive and 91% specific for the diagnosis of constrictive pericarditis.

Two other echocardiographic findings are expected in constrictive pericarditis as well as in restrictive cardiomyopathy. The first is a plethoric inferior vena cava, which may appear dilated or collapse insufficiently during inspiration. This is the echocardiographic marker for increased venous pressure. The second is a relatively "flat" Doppler profile of the systolic component of the superior vena cava. In contrast to normal patients and those with obstructive lung physiology, patients with constrictive pericarditis have restricted cardiac filling and exhibit little variation in the superior vena caval inflow velocity during the respiratory cycle. This finding is clinically useful because severe obstructive lung disease or other conditions associated with exaggerated respiratory effort may sometimes cause echocardiographic findings that mimic those of constrictive pericarditis.(4,5)



There are important roles of CT, MRI, and PET for the diagnosis and management of the patients with chronic, transient, and effusive constrictive pericarditis (6). We will discuss them at the end of my presentation, or in the ***AAE-APCHF Joint Session (Asian-Pacific Association of Echocardiography – Asian Pacific CHF)***

References

1. Oh JK, Hatle LK, Seward JB, Danielson GK, Schaff HV, Reeder GS, et al. Diagnostic role of Doppler echocardiography in constrictive pericarditis. *J Am Coll Cardiol.* 1994;23(1):154-62.
2. Hatle LK, Appleton CP, Popp RL. Differentiation of constrictive pericarditis and restrictive cardiomyopathy by Doppler echocardiography. *Circulation.* 1989;79(2):357-70.
3. Welch TD, Ling LH, Espinosa RE, Anavekar NS, Wiste HJ, Lahr BD, Schaff HV, Oh JK. Echocardiographic diagnosis of constrictive pericarditis: mayo clinic criteria. *Circ Cardiovasc Imaging.* 2014 May; 7(3):526-34.
4. Boonyaratavej S, Oh JK, Tajik AJ, Appleton CP, Seward JB. Comparison of mitral inflow and superior vena cava Doppler velocities in chronic obstructive pulmonary disease and constrictive pericarditis. *J Am Coll Cardiol.* 1998 Dec; 32(7):2043-8.
5. Syed FF, Schaff HV, Oh JK. Constrictive pericarditis--a curable diastolic heart failure. *Nat Rev Cardiol.* 2014 Sep; 11(9):530-44
6. Feng D, Glockner J, Kim K, Martinez M, Syed IS, Aroz P, Breen J, Espinosa RE, Sundt T, Schaff HV, Oh JK. Cardiac magnetic resonance imaging pericardial late gadolinium enhancement and elevated inflammatory markers can predict the reversibility of constrictive pericarditis after antiinflammatory medical therapy: a pilot study. *Circulation.* 2011 Oct 25; 124(17):1830-7